

Swab Me, I am Infected!

**Aya M. Mahros, Mohamed H Emara, Mohammed H. Ahmed,
Mohamed Said Radwan, Hassan E. Elbatee**

Department of Hepatology, Gastroenterology and Infectious Diseases, Faculty of Medicine, Kafrelshiekh University, Kafrelshiekh, Egypt

*Corresponding Author
Aya M. Mahros*

*Mobile:
00201119088009*

*E mail:
yoye_85@hotmail.com*

*Key words:
COVID-19; Cough;
Swabbing*

In the late December 2019 an outbreak of a novel coronavirus termed as SARS-CoV-2 has emerged in Wuhan city, China then spread worldwide to cause serious life threatening pandemic that seriously affect the economics and daily life. The classical picture of COVID-19 is described as fever, cough and dyspnea. However, different atypical presentations have been described in the literature. We confronted by a patient 49 years old without respiratory manifestation who sought medical advice for swabbing for COVID-19, with refusal from the local

governmental center for swabbing, two days later, the patient become dyspneic, desaturated with positive COVID-19 swab. We recommend that care givers should not wait the full typical respiratory manifestations of COVID-19. We also realize that there is a big shortage in swabbing and examination tools especially in the developing countries like ours, however, caregivers in swabbing center should have a high index of suspicion with patients who have persistent symptoms.

INTRODUCTION

In the late December 2019 an outbreak of a novel coronavirus termed as SARS-CoV-2 has emerged in Wuhan city, China [1] with many severe cases of pneumonia and then the disease spread worldwide to be recognized by WHO as a global pandemic in February, 2020 [2]. The clinical manifestations of this virus is termed COVID-19; it is associated with global life threatening health problem that is associated with global economy and daily life impairments. By the end of April 2020, more than 200,000 deaths and more than 3 million confirmed cases were reported.

The disease invaded our Middle East community and national emergency was announced nearly in all countries of the region facing this widely spreading infection. Different visual triage checklists were developed in each country to be applied by the national health care systems. These forms were available both in Arabic e.g. the Egyptian case definition sheet

(Figure 1) and also in English e.g. the Saudi visual triage checklist (Figure 2) to help both the health care givers (local with native Arabic and international with English languages) and patients as well.

During this pandemic, the classical picture of COVID-19 is described as fever, cough and dyspnea [3,4]. However, different atypical presentations have been described in the literature. Some authors described that, cases of COVID-19 may present as deterioration of the previously stable conditions with sudden hypoxemia in stable Alzheimer disease [5], syncope [6], sudden impairments of taste and smell sensations [7], lone GIT manifestations including anorexia, nausea, vomiting and diarrhea [8], although some patients were accidentally discovered upon on chest imaging [9].

CASE DESCRIPTION

We confronted by a 49 years male patient. He gave history started 10 days back with generalized fatigue, chills and bone pains, he claimed low grade fever, but he denied cough, dyspnea. He sought medical advice in a local governmental center for COVID-19 swabbing. Unfortunately, they refused to do the swab depending on the lack of the definition criteria described in the triage checklist (Figure 1 and 2). He was told that no history of exposure to a potential source of infection, no cough or dyspnea and the measured temperature is within normal. Two days later, the patient went gain to the same center due to persistent symptoms and was given the same advice. Three days later the patient noticed an increasing shortness of breath. At the triage area of another hospital the patient was not feverish nor coughing and hence was not shifted to the ER and was directed to the OPD. On examination the patient was mildly dyspneic, temperature 37.4 C. Bilateral medium sized wet crepitation were heard on chest auscultation. Chest x ray was done and showed bilateral diffuse lung opacities (Figure 3). The patient was admitted on isolation room and a swab for COVID-19 was obtained and the result was positive. Upon admission, he becomes more dyspneic, the patient was desaturated and was shifted to the ICU.

His investigations on admission included: Total leukocyte count (7.4×10^3), with relative lymphopenia (14.5%), relative monocytosis (15.3%), Hemoglobin 14.6 gm%, platelets 176×10^3 , CRP 9.7, Ferritin 90.2, D dimmer 0.1mg/L.

DISCUSSION

We intended to deliver multiple messages from this case. First, the absence of respiratory manifestations initially. Cough in particular is an annoying symptom not only for the patients but also for the contacts. In fact, different reports in the literature confirmed absence of cough as the presenting symptom of COVID-19 [5-9]. Consequently, we deliver the same message to care givers that typical respiratory manifestations may not be present among cases with COVID-19.

Second, swabbing: we realize that there is a big shortage in swabbing and examination tools especially in the developing countries like ours and also we noticed that even in the more developed and rich countries tools are not sufficient for the wide scale public examination. However, caregivers in swabbing centers should have a high index of suspicion with patients who have persistent symptoms. They should think out of the box. Following the visual triage implemented by local health authorities is very essential but this visual triage checklist was changing rapidly. For instance, some triage checklists were initially included flu, sore throat and runny nose that later omitted. In addition, the history of travel in the previous 14 days to an area of high transmission was changing very rapidly and in some countries, it was even changing daily. Furthermore, different countries affected had various hot spot districts within the same country (Figure 4).

Third, during an increased transmission rate within a locality with available testing facilities any person with changed medical condition and have an access to examination should be clinically evaluated and swabbed if possible.

Fourth, a message for patients rather than health caregivers. Unnoticed, unprotected contact with symptomatic or asymptomatic persons during the incubation period of the disease or exposure to potentially infected places e.g. markets, transportation means, within companies...etc., represent a real risk and hence whenever possible a policy of home stay and social distancing is very important.

Last, individuals are now minded with all aspects of COVID-19 infection and the different methods of protection. They should apply protective measures and insist on seeking the medical advice as soon as they develop new complains or experience persistence of symptoms

In conclusion, we recommend all health centers to swab whenever possible patients even in the absence of cough or other respiratory manifestations particularly when the local transmission is high. Waiting for full criteria of a visual triage may be a bomb that threatens the community.



وزارة الصحة والسكان
قطاع الطب الوقائي
الإدارة المركزية للشئون الوقائية
الإدارة العامة للصحة والسكان والترصد



تعريف مؤقت لحالة الإصابة بفيروس الكورونا المستجد (COVID-19)

(إصدار ٢٥ مارس ٢٠٢٠)

الحالة المشتبه

- أ. أي شخص يعاني من أي من الأعراض التنفسية الحادة مثل (كحة ، ضيق في التنفس) أو ارتفاع في درجة الحرارة $\leq 38^{\circ}\text{C}$ أو كلاهما مع عدم وجود أسباب أخرى
- مع وجود أي من الظروف التالية خلال ١٤ يوما قبل ظهور الأعراض:
١. له تاريخ سفر إلى أو إقامة بدولة / منطقة يثبت بها انتشار مجتمعي واسع أو انتقال محلي محدود للفيروس المسبب لمرض الكورونا المستجد COVID-19
 ٢. مخالط لحالة مؤكدة بمرض الكورونا المستجد COVID-19
 ٣. مخالط لشخص يعاني من أي من الأعراض التنفسية الحادة مثل (كحة ، ضيق في التنفس) أو ارتفاع في درجة الحرارة $\leq 38^{\circ}\text{C}$ و مرتبط وبانيا بمكان أو منطقة (محليا أو دوليا) بها تفشي وبائي لمرض الكورونا المستجد COVID-19 و لم يتم تأكيده معمليا
 ٤. أحد العاملين أو المترددين على أماكن تقديم الرعاية الصحية و التي تم الإبلاغ بها عن وجود حالات إصابة مؤكدة بعدوى الكورونا المستجد COVID-19

أو

- ب. مريض محجوز بأمراض تنفسية حادة شديدة (SARI) [يعاني من ارتفاع في درجة الحرارة $\leq 38^{\circ}\text{C}$ مع وجود واحد من أعراض الأمراض التنفسية الحادة مثل (كحة ، ضيق في التنفس)] و لم يمكن التعرف على المسبب للحالة المرضية له (مرفق توضيح بالفاكس المرسل لسيادتكم)

أو

- ج. أي شخص ينطبق عليه **جميع** الخصائص الأكلينيكية التالية:
١. حمى أو أعراض تنفسية حادة أو كلاهما
 ٢. أشعة عادية أو مقطعية على الصدر بها خصائص تشخيصية بعدوى الكورونا المستجد COVID-19 (مرفق ١)
 ٣. عد طبيعي أو منخفض لكرات الدم البيضاء (Total leukocyte count) مع انخفاض كرات الدم الليمفاوية (lymphocytopenia)

الحالة المؤكدة

هي حالة مشتبهة تم تأكيد إصابتها معمليا بعدوى فيروس الكورونا المستجد (COVID-19)

Figure 1: The Egyptian case definition checklist in Arabic early during the epidemic

APPENDIX 4
Visual Triage Checklist
Visual Triage Checklist for Acute Respiratory Illnesses

Date: _____ Time: _____ MRN: _____
Name: _____ ID#: _____ Hospital: _____

Circle the number reflecting the patient's condition (exposure and clinical picture) and calculate the final score:

Risks for Acute Respiratory Illnesses	Score		
A. Exposure Risks (in the past 14 days prior to symptom onset)	<i>Any Patient (Adult or Pediatric)</i>		
1. Had a history of travel to areas with presumed ongoing community transmission of COVID-19 (China, Iran, South Korea, Japan, Singapore, Hong Kong, or any updated information added on CCC website: ccc.gov.sa/CCC/health/regulations/Documents/SuspectedCOVID19Supplement.pdf) OR A close physical contact in the past 14 days prior to symptom onset with a confirmed case of COVID-19 OR Working in or attended a healthcare facility where patients with confirmed COVID-19 were admitted.	5		
2. Exposure to a confirmed MERS case in the last two weeks	3		
3. Exposure to camel or products (direct or indirect*) in the last two weeks	2		
4. Visit to a healthcare facility that had MERS case in the last two weeks	1		
B. Clinical Signs and Symptoms	<i>Patient with Exposure Risk No. 1</i>	<i>Patient with or without Exposure Risk No. 2, 3, or 4</i>	
		<i>Pediatric</i>	<i>Adult</i>
1. Fever	1	1	2
2. Cough (new or worsening)	1	1	2
3. Shortness of breath (new or worsening)	1	1	2
4. Sore throat and/or runny nose	1	-	1
5. Nausea, vomiting, and/or diarrhea	-	-	1
6. Chronic renal failure, CAD/heart failure	-	-	1
Total Score			

*Patient or household

A score ≥ 4 , place patient in an isolation room and inform MD for assessment. MERS-CoV testing should be done only according to case definition.

A score ≥ 6 , place patient in an isolation room and inform MD for assessment. COVID-19 testing should be done only according to case definition.

Staff name: _____ ID number: _____

Figure 2: The Saudi case definition checklist in English early during the epidemic

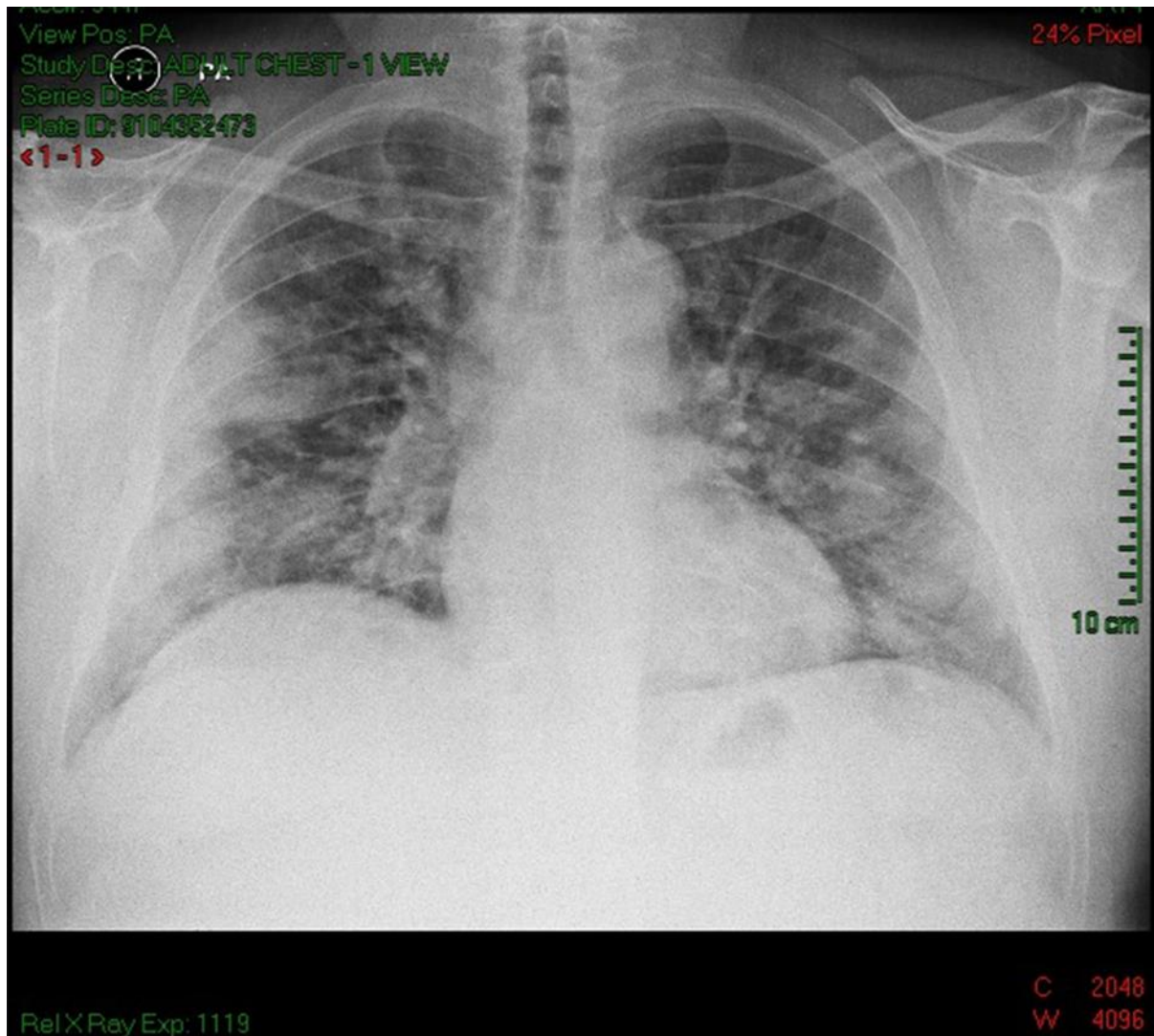
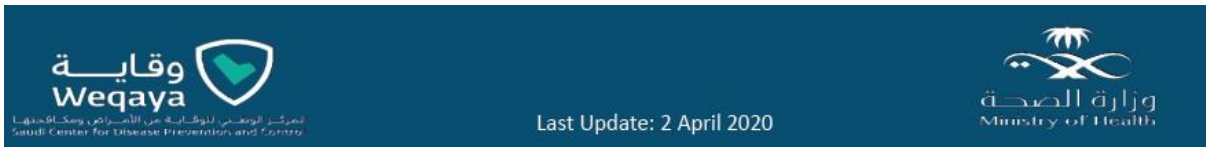

Figure 3: Chest X-ray of the chest on the day of admission showing bilateral consolidation opacities.



Respiratory Triage Checklist

Date: _____ Time: _____
 Name: _____ Hospital: _____

Circle the number reflecting the patient's condition (exposure and clinical picture) and calculate the final score:

Risks for Acute Respiratory Illnesses	Score	
A. Exposure Risks	Any Patient (Adult or Pediatric)	
A history of travel abroad during the 14 days prior to symptom onset. <u>OR</u> Visiting or being a resident of a high-risk area for COVID-19 in the kingdom during the 14 days prior to symptom onset*. <u>OR</u> A close physical contact with a confirmed case of COVID-19 or MERS-CoV in the past 14 days. <u>OR</u> An exposure to camel or camel's products (direct or indirect**) in the past 14 days. <u>OR</u> Working in a healthcare facility.	3	
B. Clinical Signs and Symptoms and Medical History	Pediatric	Adult
1. Fever or recent history of fever.	1	2
2. Cough (new or worsening).	1	2
3. Shortness of breath (new or worsening).	1	2
4. Nausea, vomiting, and/or diarrhea.	-	1
5. Chronic renal failure, CAD/heart failure, Immunocompromised patient.	-	1
Total Score		

* As determined and announced by the Ministry of Interior or Ministry of Health. Updated regularly on: www.covid19.cdc.gov.sa

** Patient or household

A score ≥ 4 , ask the patient to perform hand hygiene, wear a surgical mask, direct the patient through the respiratory pathway and inform MD for assessment.

MRSE-CoV OR COVID-19 testing should be only done according to case definitions.

Staff name: _____ Signature: _____

Figure 4: The modified Saudi case definition checklist in English later during the epidemic. Note that the list of countries with high transmission listed early in the epidemic was replaced later by history of travel abroad whatever the cautionary was. Also, note that upper respiratory manifestations e.g. sore throat and runny nose were not included in the latest triage checklist.

Ethics and Consent: This study was performed in accordance with the Declaration of Helsinki, Good Clinical Practice and applicable regulatory requirements. Written informed consent was taken from the patient.

ACKNOWLEDGMENT

The authors would thank all colleagues who helped to document this case

Conflict of interest: None

REFERENCES

1. Wu Y, Ho W, Huang Y, Jin DY, Li S, Liu SL et al. SARS-CoV-2 is an appropriate name for the new coronavirus. *Lancet*. 2020 Mar 21;395(10228):949-950.
2. Legido-Quigley H, Asgari N, Teo YY, Leung GM, Oshitani H, Fukuda K et al. Are high-performing health systems resilient against the COVID-19 epidemic? *Lancet*. 2020 Mar 14;395(10227):848-850.
3. Wang D, Hu B, Hu C, Zhu F, Liu X, Zhang J, et al. Clinical Characteristics of 138 Hospitalized Patients With 2019 Novel Coronavirus-Infected Pneumonia in Wuhan, China. *JAMA*. 2020 Mar 17;323(11):1061-1069.
4. Young BE, Ong SWX, Kalimuddin S, Low JG, Tan SY, Loh J, et al. Epidemiologic Features and Clinical Course of Patients Infected With SARS-CoV-2 in Singapore. *JAMA*. 2020 Apr 21;323(15):1488-1494.
5. Isaia G, Marinello R, Tibaldi V, Tamone C, Bo M. Atypical Presentation of Covid-19 in an Older Adult With Severe Alzheimer Disease. *Am J Geriatr Psychiatry*. 2020 Jul;28(7):790-791
6. Singhanian N, Bansal S, Singhanian G. An Atypical Presentation of Novel Coronavirus Disease 2019 (COVID-19). *Am J Med*. 2020 Jul;133(7):e365-e366.
7. Xydakis MS, Dehgani-Mobaraki P, Holbrook EH, Geisthoff UW, Bauer C, Hautefort C, et al. Smell and taste dysfunction in patients with COVID-19. *Lancet Infect Dis*. 2020 Sep;20(9):1015-1016.
8. Tian Y, Rong L, Nian W, He Y. Review article: gastrointestinal features in COVID-19 and the possibility of faecal transmission. *Aliment Pharmacol Ther*. 2020 May;51(9):843-851.
9. Asadollahi-Amin A, Hasibi M, Ghadimi F, Rezaei H, SeyedAlinaghi S. Lung Involvement Found on Chest CT Scan in a Pre-Symptomatic Person with SARS-CoV-2 Infection: A Case Report. *Trop Med Infect Dis*. 2020 Apr 7;5(2):56.