

Effect of the anti-inflammatory drugs Hostacortin (steroidal) or Vioxx (non-steroidal) on the liver of mice infected with *Schistosoma mansoni*.

Salah M. E. Soliman, Ismail M. Al-Sharkawi*, Kamal A. El-Shaikh** and Fatma E.Salem**.

Zoology Dep., Faculty of Science, Al-Azhar Ueeniv., Assiut, Egypt.

*Zoology Dep., Faculty of Science, Tanta Univ., Egypt.

** Zoology Dep., Faculty of Science, Helwan Univ., Egypt.

ABSTRACT

Background: The schistosome parasite induced granulomatous inflammation in the host following oviposition in the liver. **Aim:** The present study aimed to evaluate the efficacy of two anti-inflammatory drugs; Hostacortin (steroidal) and Vioxx (non-steroidal) in ameliorating the damaging effects of *S. mansoni* infection in mice. **Materials and methods:** The anti-inflammatory activity of the two drugs was evaluated at dose levels of 10, 50, 100 and 200 mg/kg body weight. Each drug was orally administered to mice infected with 80 *S.mansoni* cercariae / mouse for 10 consecutive days after 6-weeks of infection. Some biochemical parameters including the hepatic function as enzymatic activity of aminotransaminases; alanine aminotransferase (ALAT), aspartate aminotransferase (ASAT) and alkaline phosphatase (ALP) in liver as well as serum albumin and liver total protein were determined. In addition, some parasitological parameters as worm burden, liver egg count hepatic granuloma size and relative liver weight were performed to evaluate the possible anti-inflammatory effect of the two anti-inflammatory drugs in ameliorating the severity of the schistosomiasis disease.

Results: The results showed that Hostacortin treatment had no marked effect on the parasite burden and liver egg count. However, it caused a pronounced improvement with a high tendency for normalization in transaminases (ALAT and ASAT) and alkaline phosphatase (ALP) activities in liver tissue homogenate. In addition, serum albumin and liver total protein was observed to attain, to some extent, their normal levels by increasing dose regimens of Hostacortin. Also, a significant reduction in granuloma size by 22.2% and 31.6% was detected for doses of 100 and 200 mg/kg Hostacortin, respectively. On the other hand, Vioxx did not affect the parasite burden and liver egg count while it caused high reduction in the enzymatic activities of ASAT, ALAT and ALP in liver tissue homogenate. Also, a moderate increase in serum albumin and a significant reduction in liver total protein levels were observed in mice treated with Vioxx. In contrast to Hostacortin, Vioxx treatment induced a significant increase in the granuloma size by 29.3% at a dose level of 200 mg/kg.

Conclusion: The treatment with Hostacortin was found to ameliorate to some extent the severity of the disease, but Vioxx treatment caused additional hepatotoxicity in the *S. mansoni* infected mice.

Keywords: Anti-inflammatory drugs, Granuloma, Hostacortin, Mice, *S. mansoni*, Vioxx.

INTRODUCTION

Schistosomiasis is a parasitic disease caused by platyhelminth worms of the genus *Schistosoma*. The disease affects 207 million people in the developing world, with approximately 800 million, mostly children, at risk of the infection. Twenty million of the infected people implicated severe consequences from the disease and the others are symptomatic. Symptoms range from fever, headache and lethargy to severe sequelae including ascites, hepatosplenomegaly and even death [1-4]. More than 600 million people in the tropics are at risk for developing schistosomiasis. In Egypt, schistosomiasis is the major public health problems in rural

regions, with almost 7.2 million Egyptians infected [5-7].

Eggs laid by *Schistosoma mansoni* adult females in the mesenteric veins pass through the intestinal wall and then exit the host through the feces, or they are swept into the liver and trapped in the sinusoids, where they induce granulomatous lesions. However, accumulation of fibrotic tissue also obstructs blood flow through the liver, resulting in portal hypertension, extended periportal fibrosis and portal shunting [8]. In human, the blood schistosomal flukes have a life span of many years and daily produce large number of eggs. Mature eggs of *S. mansoni* have harmful to the host. These eggs are inducing granuloma

formation, vary among different mice strain and animal species ^[8]. The formed granuloma leads to fibrosis, giving rise the most serious symptoms of chronic infections. Progressive fibrosis can lead to fatal bleeding from oesophagogastric varices ^[9]. Transmission of schistosomiasis is usually associated with poor socioeconomic conditions. The best control strategies involve a coordinated approach that includes containment of the intermediate snail host by the environmental methods, molluscicides, chemotherapy, improved sanitation, health education and vaccination ^[10&11].

There have been great advances in chemotherapy of schistosomiasis during the last two decades. Compared to antimonials, which were the only available chemotherapeutic agents for schistosomiasis, new drugs are more consistently effective, less toxic and applicable to oral rather than parenteral administration, making field trials of mass chemotherapy feasible ^[12-16].

In schistosomiasis, even after successful treatment, no effective measure was found to improve the damaged liver after treating schistosomiasis with antischistosomal drugs, where liver inflammation precedes and promotes the progression of liver fibrosis. There is a positive correlation between the degree of sustained hepatic inflammation and the progression of fibrosis. Moreover, it had been proved that the substances inhibiting the inflammatory response of the liver also limit fibrinogenesis ^[17]. In liver diseases, corticosteroids have long been used as anti-inflammatory drugs. They also have hepatoprotective effects by inhibiting cytochrome P450 activity and reducing collagen deposition ^[18]. Hostacortin (Prednisone) is a synthetic glucocorticoid similar to cortisone, used in replacement therapy for adrenal insufficiency and as an immunosuppressant, antiallergic and anti-inflammatory drug in a wide variety of disorders. It is used safely and effectively to control the liver inflammatory process in treatment of patients suffering from autoimmune hepatitis ^[19&20].

On the other hand, there are other anti-inflammatory agents; their action is due to inhibition of cyclooxygenase enzymes (coxibs). These agents include non-steroidal anti-inflammatory drugs (NSADs) and specific Cox-2 inhibitors (coxibs), are all currently

recommended for the treatment of inflammation. Cyclooxygenase inhibitors are a class of anti-inflammatory drugs that inhibit the activity of two types of enzymes known as cyclooxygenase-1 (COX-1) and cyclooxygenase-2 (COX-2). However, COX-1 is necessary for maintaining the internal stability of the bodies such as protecting the lining of the stomach. The COX-2 is involved in the inflammatory process. Thereby, drugs that inhibit both COX enzymes produce unwanted side effects ^[21&22]. Vioxx (rofecoxib) is a potent and selective inhibitor of COX-2, which is indicated in treatment of osteoarthritis, rheumatoid arthritis and pain ^[23]. On the other hand, the NSADs have been associated with serious hepatotoxicity and different liver pathologies ^[24-26].

The aim of the present study is to evaluate the effect of two anti-inflammatory drugs (steroidal and non-steroidal) on the status of the liver in mice infected with *S. mansoni*. The efficacy of the two anti-inflammatory drugs; Hostacortin (steroidal) and Vioxx (non-steroidal) in schistosomiasis infection was evaluated by determination of aminotransferases (ALAT and ASAT) and alkaline phosphatase activities in liver as well as serum albumin and liver total protein in addition to worm burden, egg count and hepato-somatic index. Also, histopathological studies were performed to determine the effect of treatment on hepatic granuloma size.

MATERIALS AND METHODS

Experimental Animals

Adult male albino mice, *Mus musculus* (20 – 25 g. weight) were used as experimental animals throughout the study. Animals were obtained from Schistosome Biological Supply Center (SBSC), Theodor Bilharz Research Institute, Egypt. They were housed in especially designed cages and fed on a standard diet *ad libitum* with free access of water. All animals were maintained in the laboratory for one week before experimentation.

Chemicals

Anti-inflammatory Drugs

Hostacortin (Steroidal anti-inflammatory drug

Hostacortin (Prednisone) is a glucocorticoid drug. The drug was obtained as tablets, each containing 400 mg prednisone. It was suspended in distilled water and orally

administered to mice at daily oral dose levels of 10, 50, 100 and 200 mg / kg body weight for 10 days.

Vioxx (non-steroidal anti-inflammatory drugs)

Vioxx (Rofecoxib) belongs to the coxibs, which are a class of non-steroidal anti-inflammatory drugs (NSAID s). The drug was obtained as tablets, each containing 50 mg rofecoxib. It was prepared as a suspension in distilled water and orally administered to mice at daily oral doses of 10, 50, 100 and 200 mg / kg body weight for 10 days.

Schistosomal Infection of the

Experimental animals

Adult male Albino mice, *Mus musculus* (20 – 25 g weight), were infected separately, where each mouse was exposed by tail immersion technique ^[12] to a single dose of 80 *S. mansoni* cercariae shed by infected *Biomphalaria alexandrina* snails which were obtained from Theodore Bilharz Research Institute (TBRI) , Cairo , Egypt .The animals were left for 60 minutes to allow the penetration by the parasites and then transferred carefully to their prepared cages.

Experimental Design

Mice were infected with 80 *S. mansoni* cercariae / mouse were left for 6 weeks and then were divided into nine groups, each of 10 infected mice .Four groups were treated with 10 daily oral doses of Hostacortin at dose levels of 10, 50, 100 and 200 mg / kg . Another four groups were treated with 10 daily oral doses of Vioxx. The last group was left without treatment and served as a control group. In addition, a normal healthy group of 10 mice was used normal non-infected one.

$$\text{Hepato-somatic index} = \frac{\text{Liver weight (g)}}{\text{Total body weight (g)}} \times 100$$

Oogram Determination

Fragments of the liver tissue weighing 0.1 g were transferred to clean slides. Slides were then, covered with their cover slips and pressed to spread the liver tissues homogeneously.

All viable and dead eggs were counted in 1 g of liver under microscope and expressed as number of eggs / g tissue as described by the method of **Prata ^[28] and Pellegrino *et al.* ^[29]**.

Sample Preparations

One day after the last treatment, mice of all groups were weighed and sacrificed. Blood samples were collected and sera were separated for subsequent analysis. Livers of mice were perfused for worm recovery according to the method described by **Christensen *et al.* ^[27]**. The liver was excised, blotted, weighed and its relative weight was determined. Fragments of liver were used for quantitative egg count according to the method of **Prata ^[28] and Pellegrino *et al.* ^[29]**.

Another piece of liver was saved for the histological preparation. The remaining liver was weighed and 10% homogenate was prepared for determination of total protein and enzymatic activities of aspartate aminotransferase (ASAT), alanine aminotransferase (ALAT) and alkaline phosphatase (ALP).

Determination of Worm Burden

The portal blood system of the dissected animals was perfused with saline solution according to the method described by **Christensen *et al.* ^[27]**. Perfusion continued until the fluid coming from animals was free of blood; the adult worms were transferred to a clean *Petri* dish containing saline .The viscera were also transferred to an another *Petri* dish containing saline for additional worm recovery. All worms whether male or female or couples from perfusion fluid intestine and mesenteries were counted.

Hepato-somatic Index

After perfusion, the livers were excised, cleaned, blotted dry using filter papers and then weighed. The Hepato-somatic index was calculated according to the following formula:

Serum Preparation

Blood was allowed to clot for 1 to 2 h at room temperature. Serum was collected after centrifugation for 15 minutes and frozen at – 20°C until use.

Preparation of the Tissue Homogenate

The remaining liver tissue of each animal was rapidly and accurately reweighed and homogenized in ice cold distilled water using Potter-Elvehjem homogenizer to give final dilution of 10% tissue homogenate and frozen at – 20°C until use.

Histopathological Preparation

For histopathological examination, selected liver specimens of animals of each group were fixed in 10% neutral formalin for 24 hours. Tissue specimens were then washed in running tap water. After dehydration, paraffin sections of 5 μ thickness were prepared and stained with the usual Hematoxylin and Eosin according to the method of **Drury and Wallington** ^[30].

Granuloma Measurements

Lesions containing eggs in their centers were selected for measurement and the diameter of each liver granuloma was obtained by measuring two diameters of the lesions at right angles to each other using an ocular micrometer. The mean diameter of all slide lesions from each mouse of each group was determined and the volume of each lesion was calculated, assuming a spherical shape ^[31] from its mean diameter using the following formula:

$$\text{Granuloma volume} = R \times 22/7 \times 4/3$$

Where R: is the radius of the granuloma.

Biochemical Assays

The enzymatic activities of aminotransferases; alanine aminotransferase (ALAT) and aspartate aminotransferase (ASAT) were determined in liver tissue homogenate according to **Schmidt** ^[32]. Also, alkaline phosphatase activity in liver tissue homogenate was determined according to **Tietz** ^[33]. In addition, serum albumin was determined according to the method described by **Dumas and Bigges** ^[34]. The total protein content in the liver tissue homogenate of mice was also determined ^[35&36]. Biomarker kits were used in all biochemical assays.

Statistical Analysis of the Data

Data were analyzed using Statistical Program for Social Science (SPSS) version 18.0. Quantitative data were expressed as mean \pm standard deviation (SD). The obtained data were presented as mean \pm standard deviation (M \pm S.D). The significance of the difference between the means was calculated according to Student's *t* test at $p \leq 0.05$.

The study was approved by the Ethics Board of Al-Azhar University.

RESULTS

Worm Burden

Infection of mice with *S. mansoni cercariae* resulted in 38.2 ± 3.2 worm / mouse. Hostacortin treatment induced slight non-

significant reduction percentages by 14.7 , 13.6 , 11.5 and 17.32, while the reduction percentages with Vioxx treatment were 7.8 , 12.04 , 7.9 and 15.6 at dose levels of 10 , 50 100 and 200 mg / kg respectively, compared to infected control animals (Tab. 1).

Ova Count

Compared to control animals, data obtained in Table (1) showed a marked decrease in total liver ova count in *S. mansoni* infected mice treated with Hostcortin. The number of live eggs showed a further significant decrease with increasing the dose. In contrast, dead ova increased with increasing the dose regimens. On the other hand, treatment of infected mice with Vioxx showed non-significant changes in total ova count compared to control mice (Table1).

Hepato-somatic Index

Infection of mice with *S. mansoni* cercariae resulted in a marked enlargement in the liver with a significant increase in its Hepato-somatic index by 81.2% as compared to normal healthy mice. Treatment of mice with anti-inflammatory drugs Hostacortin and Vioxx showed no significant change in the Hepato-somatic index compared with the control mice (Table 2).

Granuloma Measurements

Treatment of *S. mansoni* infected mice with Hostacortin showed a marked reduction in granuloma size. The reduction was found to be a highly significant at dose levels of 100 and 200 mg / kg. In contrast, treatment of infected mice with Vioxx a marked increase in granuloma volume and diameter which were increased by increasing the doses. The increase in size was found to be a highly significant at a dose level of 200 mg / kg (Table 3).

Histopathological examination of hepatic granuloma showed that Hostacortin administration induced a marked reduction in the volume of hepatic granuloma. In contrast with Hostacortin, hypertrophoid granuloma was observed on Vioxx treatment (Figs.1-3).

Biochemical Findings

The results of the present study showed a moderate decrease of serum albumin in *S.mansoni* infected mice as compared to normal healthy animals. Treatment of the infected mice with Hostacortin and Vioxx resulted in slight increase in serum albumin as compared to the control mice. Compared to the normal healthy mice, the liver total protein of

infected mice showed a highly significant increase by 79.4%. Treatment of infected mice with Hostacortin was found to induce a moderate decrease in total protein, while Vioxx treatment showed a significant decrease compared to the control mice (Table 4).

Liver Enzymatic Activities

The changes in the liver enzymatic activities in *S. mansoni* infected mice showed an increase by 64.8 % in the activity of ALP and reduction percentages by 7.6 and 14.1 in transaminases activities of ALAT and ASAT, respectively compared to the normal healthy mice. Treatment of infected mice with the anti-

inflammatory drugs resulted in a significant reduction in the elevated ALP activity which showed a high tendency for normalization at a dose level of 200 mg/kg. Hostacortin treatment was found to induce slight and concomitant increases in the decreased transaminases activities by increasing dose regimens of the drug where the enzymes attained, to some extent, their normal levels at 200 mg/kg dose level. However, Vioxx treatment resulted in further and highly significant decreases in the liver enzymatic activities of ALAT and ASAT of the infected mice compared to the control ones (Table 5).

Table 1- Effect of Hostacortin and Vioxx treatments on worm burden and ova count in *S.mansoni* infected mice.

Treatment	Worm Burden (worm/mouse)		Ova Count (Ova/g liver tissue x 10 ²)					
	M±SD	%Change	Live Ova	%Change	Dead Ova	%Change	Total Ova	%Change
Positive Control	38.2±6.2		51.8±10.7		21.1±4.8		72.9±13.2	
Hostacortin (mg/kg)								
10	32.6±3.4	-14.7	26.3±5.7*	-49.2	18.5±3.7	-12.3	44.8±10.5	-37.9
50	33±4.3	-13.6	22.7±4.6*	-56.2	28.2±3.6	+33.6	50.9±8.2	-29.7
100	33.8±3.9	-11.5	18.5±3.9*	-64.2	29±6.3*	+39.8	47.5±11.5	-34.4
200	31.6±6.3	-17.2	17.8±3.6*	-65.6	30.3±6.7*	+43.6	48.1±5.1	-34.1
Vioxx (mg/kg)								
10	35.2±3.6	-7.8	53.2±12.2	+2.7	22.5±4.2	+6.6	75.7±17.2	+3.7
50	33.6±5.4	-12.04	45.3±6.5	-12.2	26.2±5.8	+24.2	71.5±14.3	-1.6
100	35.2±5.4	-7.9	48.4±12.7	-6.6	27.6±5.6	+30.8	79.9±15.01	+9.6
200	32.4±4.6	-15.6	49.1±8.5	-5.2	29.3±4.1	+38.9	78.4±13.7	+7.6

Mice (n=10) were exposed to 80 *S.mansoni* cercariae/mouse. *p < 0.05.

Hostacortin and Vioxx treatment started after 6 weeks of infection for 10 days.

The number of worms was the sum of male and female worms in the liver and intestinal mesenteries.

Table 2- Effect of Hostacortin and Vioxx treatments on hepato-somatic index in *S.mansoni* infected mice.

Treatment	Hepato-somatic Index (M±SD)	%Change
Negative Control	4.3±0.93	.
Positive Control	8.7±1.82*	+102.3
Hostacortin (mg/kg)		
10	8.5±1.7	(-2.3)
50	8.3±1.8	(-4.6)
100	8.0±1.5	(-8.1)
200	8.1±1.7	(-6.9)
Vioxx (mg/kg)		
10	7.9±0.99	-9.1
50	8.3±1.13	-4.1
100	8.26±1.2	-4.6
200	8.22±0.75	-5.7

Mice (n=10) were exposed to 80 *S.mansoni* cercariae / mouse. *p < 0.05.

Hostacortin and Vioxx treatment started after 6 weeks of infection for 10 days. Values without brackets were calculated compared to normal non-infected mice; values between brackets () were calculated compared to control infected mice.

Table 3- Effect of Hostacortin and Vioxx treatments on liver granuloma size in *S.mansoni* infected mice.

Treatment	Granuloma Measurements		
	Diameter (μm) (M \pm SD)	Volume (μm^3) (M \pm SD)	%Change
Positive Control	191.5 \pm 42.7	402.2 \pm 102.1	
Hostacortin (mg/kg)			
10	180.3 \pm 40.2	400.7 \pm 144.6	-0.37
50	172.3 \pm 38.1	361.8 \pm 76.4	-10.04
100	149.03 \pm 30.3	312.9 \pm 84.6*	-22.2
200	131.1 \pm 33	275.3 \pm 40.6*	-31.6
Vioxx (mg/kg)			
10	193.7 \pm 40.3	406.8 \pm 88.5	+1.1
50	200.9 \pm 42.4	421.9 \pm 98.4	+4.9
100	225.2 \pm 32.59	473.3 \pm 68.4	+17.8
200	247.6 \pm 57.45	519.9 \pm 121.6*	+29.3

Mice (n=10) were exposed to 80 *S.mansoni* cercariae / mouse. *p < 0.05
Hostacortin and Vioxx treatment started after 6 weeks of infection for 10 days.

Table 4- Effect of Hostacortin and Vioxx treatments on serum albumin and liver total protein in *S.mansoni* infected mice.

Treatment	Biochemical Parameters (M \pm SD)			
	Albumin (g /100 ml serum)	%Change	Total protein (mg/g x 10 ⁻⁷ liver tissue)	%Change
Negative Control	2.8 \pm 0.5		3.4 \pm 1.3	
Positive Control	2.6 \pm 0.3	-7.1	6.1 \pm 1.6*	+79.4
Hostacortin (mg/kg)				
10	3.1 \pm 0.4	(+19.2)	3.3 \pm 0.7*	(-45.9)
50	2.9 \pm 0.5	(+11.5)	4.1 \pm 1.1	(-32.8)
100	2.5 \pm 0.6	(-6.8)	4.5 \pm 0.9	(-26.2)
200	2.9 \pm 0.5	(+11.5)	4.1 \pm 1.3	(-32.8)
Vioxx (mg/kg)				
10	2.3 \pm 0.3	(-11.2)	3.3 \pm 0.7*	(-44.3)
50	2.2 \pm 0.4	(-15.4)	2.5 \pm 0.5*	(-59.01)
100	2.9 \pm 0.4	(+11.5)	2.3 \pm 0.9*	(-62.3)
200	3.3 \pm 0.2*	(+26.9)	2.9 \pm 0.6*	(-52.4)

Mice (n=10) were exposed to 80 *S.mansoni* cercariae / mouse. *p < 0.05.
Hostacortin and Vioxx treatment started after 6 weeks of infection for 10 days.
Values without brackets were calculated compared to normal non-infected mice; values between brackets () were calculated compared to control infected mice.

Table 5- Effect of Hostacortin and Vioxx treatments on the enzymatic activities of alkaline phosphatase (ALP) and aminotransferases (ALAT and ASAT) in the liver tissue homogenate of *S.mansoni* infected mice.

Treatment	Biochemical Parameters (M±SD)					
	ALP	%Change	ALAT	%Change	ASAT	%Change
Negative Control	26.4±9.2		113.1±21.5		117.8±21	
Positive Control	43.5±10.2*	+64.8	104.6±20.8	-7.6	101.2±21.2	-14.1
Hostacortin (mg/kg)						
10	26.5±5.1 *	(-39.1)	94.0±13.7	(-10.1)	92.8±6.6	(-8.3)
50	31.9±7.2	(-26.7)	96.8±15.6	(-7.5)	96.7±10.1	(-4.5)
100	25.4±8.0*	(-41.6)	98.2±18.6	(-6.1)	94.5±15.6	(-6.6)
200	23.2±5.20*	(-46.7)	106.0±20.7	(+1.4)	109.0±23.5	(+7.7)
Vioxx (mg/kg)						
10	34.6±6.8	(-20.4)	83.5±15.7	(-20.2)	84.8±16.2	(-16.2)
50	33.8±6.0	(-22.3)	93.0±20.2	(-11.1)	93.3±19.5	(-7.8)
100	26.2±5.4*	(-39.8)	88.2±18.9	(-15.7)	60.0±13.8*	(-40.7)
200	26.3±4.1 *	(-39.5)	83.2±15.3	(-20.5)	64.0±14.1*	(-36.8)

Mice (n=10) were exposed to 80 *S.mansoni* cercariae / mouse. *p< 0.05

Hostacortin and Vioxx treatment started after 6 weeks of infection for 10 days.

Values without brackets were calculated compared to normal non-infected mice; values between brackets () were calculated compared to control infected mice.

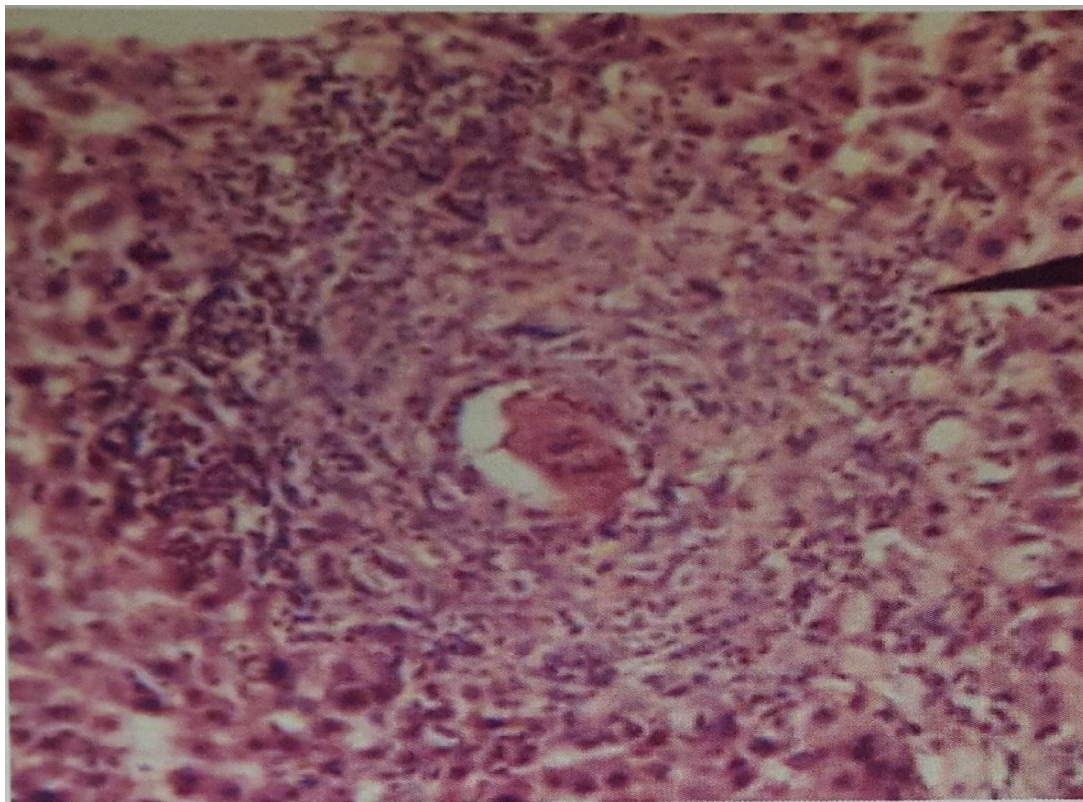


Fig. 1- A photomicrograph of liver section of mice infected with 80 cercariae of *S.mansoni* (Control group) showing granulomatous reaction formed of lymphocytes, histocytes and eosinophils surrounding bilharzial egg. (Hx &Ex250).

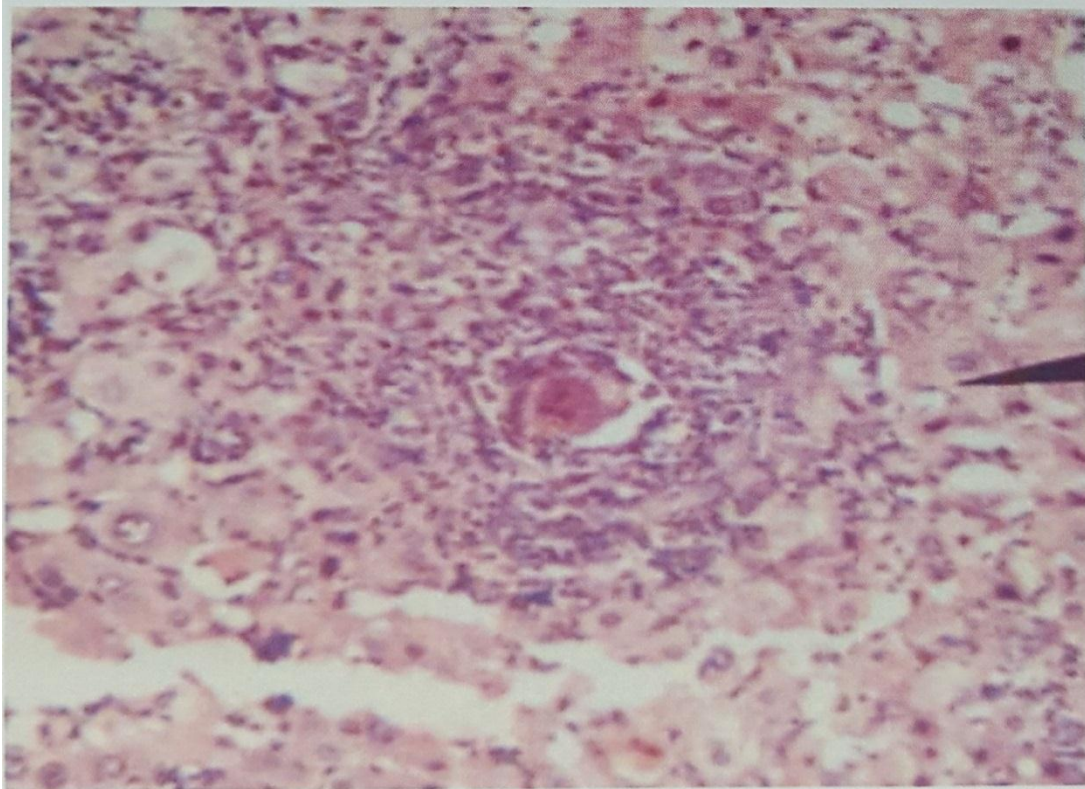


Fig.2- A photomicrograph of liver section of mice infected with 80 cercariae of *S. mansoni* and treated with 200 mg/ kg Hostacortin showing reduced granuloma. (Hx&Ex250).

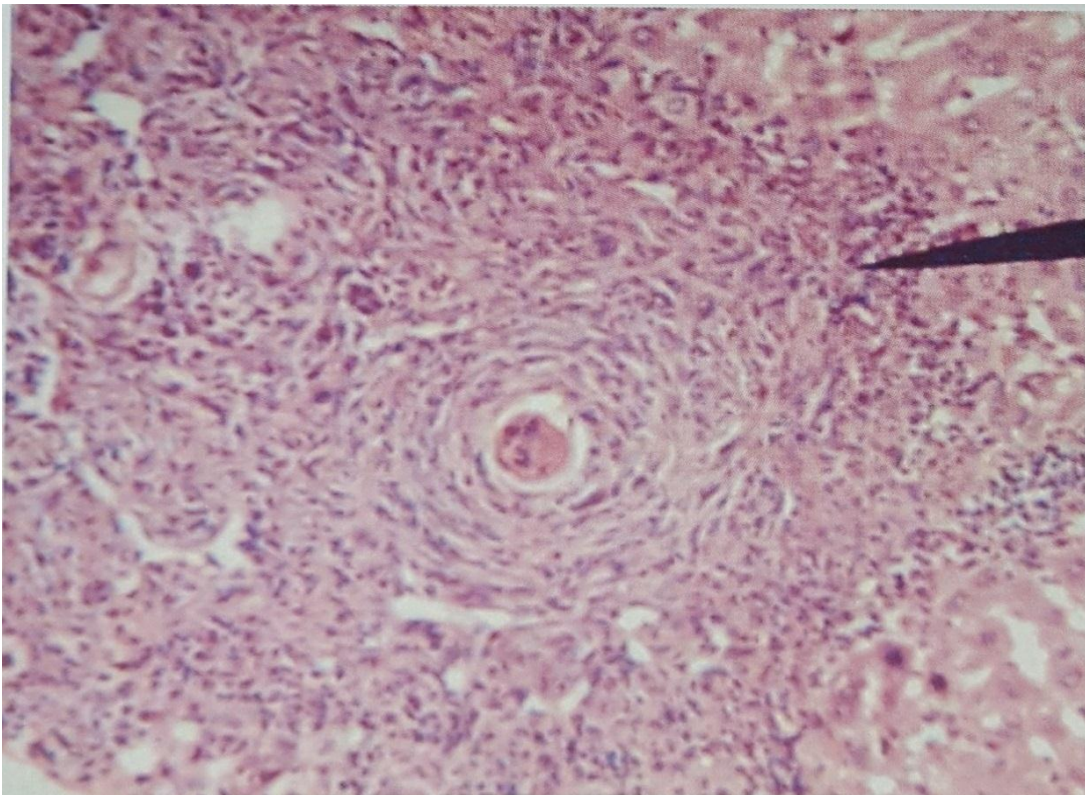


Fig. 3- A Photomicrograph of liver section of mice infected with 80 cercariae of *S. mansoni* and treated with 200 mg/ kg Vioxx showing hypertrophied granuloma. (Hx& Ex250).

DISCUSSION

The present study showed no significant decrease in the worm burden and egg count in *S. mansoni* infected mice treated with low dose of Hostacortin, but the treatment with high dose (200 mg/kg) resulted in a slight reduction in the worm burden. In addition, Hostacortin treatment induced a highly significant reduction in granuloma size. This reduction was found to be increased with increasing Hostacortin doses (Dose-dependent). In contrast, the dead eggs showed highly increased level with increased Hostacortin dose regimens.

Treatment of *S. mansoni* infected mice with Vioxx showed no significant changes in the total liver eggs. Also, Vioxx treatment caused a very slight reduction in the worm burden at the high doses. Regarding the granuloma, the results obtained showed a significant increase in its volume at high doses of Vioxx in *S. mansoni* infected mice. Many authors observed an appreciable decrease in the parasite burden due to the treatment with high doses of Dexamethasone (A type of hydrocortisone) in *S. mansoni* infected mice which are in agreement with the present results. Also, they found that treatment of infected mice with cortisone induced a moderate decrease in the number of eggs in the hepatic tissues, reduced granuloma size, reduced level of granuloma maturation and reduced collagen contents [37-44]. On the other hand, treatment of bilharzial infected mice with Vioxx at high doses resulted in a significant increase in the granuloma volume. This increase in the volume may be attributed to the hepatotoxic effects of Vioxx that lead to increased soluble egg antigens with an increase of all granuloma components followed by augmentation in the size.

The decreased worm burden observed in the present study may be attributed to the decreased activity of the worms that may lead to their death due to increased permeability of the worms in the infected mice by treatment with high doses of Hostacortin. This observation confirmed the results obtained by **Lambertucci et al** [41] who observed a reduction in the worm activity by using high doses of cortisone.

In parallel with the present findings, several studies have proven that NSAIDs treatment induced serious hepatotoxicity and caused

fulminate hepatic failure in patients with HCV [45&46]. Also, Coxibs treatment was found to induce an increase in the volume of granulomatous hepatitis [46]. These concepts are obviously confirmed by the present results that showed a significant increase in the granuloma size due to Vioxx treatment. In contrast to the present results, **Mahmoud et al.** [47] reported a reduction in the granuloma diameter and collagen deposition due to NSAIDs treatment.

In the same respect, comparable findings have been reported by **Chensue et al.** [48] who observed that liver fibrosis in schistosomiasis develops as an inflammatory reaction to tissue injury around the schistosomal eggs and characterized by accumulation and proliferation of reticulo-endothelial cells and collagen deposition. It should be noted that the inflammatory reaction around the schistosome eggs tend to be similar in man and in most infected hosts [49].

Also, it was found that liver fibrosis in schistosomiasis *mansoni* is associated with a pattern of collagen increase resembling that of liver cirrhosis [50]. In the present study, Hostacortin treatment of the infected mice showed a highly significant reduction in the granuloma size. This reduction may be attributed to the decrease in collagen synthesis. These results are supported by many investigators who reported that treatment of *S. mansoni* infected mice with corticosteroids induced a reduction in granuloma size and formation of incomplete granulomas around the eggs with improvement of hepatocellular damage [51-54].

In the present study *S. mansoni* infection of mice caused marked enlargement of infected liver as manifested by the increase in the relative liver weight. These results are supported by the work conducted by **Warren** [55] who found liver enlargement that reached its least level at 10 and 20 weeks, a stage in which necrosis and inflammatory cell infiltration were seen in the liver of *S. mansoni* infected mice. Similar findings were reported by **Warren et al.** [56]; **Fernanda et al.** [57] and **Al-Sharkawi** [58].

In *S. mansoni* infected mice, the present results showed a moderate decrease in serum albumin. Similar findings were reported by **Amal et al.** [59] and **El-Zayadi et al.** [60]. In the

present study, treatment of infected mice with Hostacortin resulted in a very slight increase in serum albumin. On the other hand, treatment of infected mice with Vioxx showed no significant change in the level of serum albumin. The present data are confirmed by the results of **El-Zayadi *et al.***^[60] who reported that short term treatment of *S. mansoni* infected mice with corticosteroids resulted in marked increase in serum albumin. They attributed the increase in serum albumin to improvement in the synthetic ability of the hepatocytes due to glucocorticoid treatment. In contrast, **Beck**^[61] reported a reduction in the level of serum albumin due to Rofecoxib (Vioxx) treatment. The author attributed the reduction to the unstable state of the hepatocytes due to the used drug.

In the present study, *S. mansoni* infection was found to induce significant abnormalities in the activities of the hepatic enzymes in liver tissue homogenate. The infection caused a marked liver dysfunction as observed by the increased total protein content. This increase in liver total protein content could be attributed to the effect of hepatotoxic agents produced by the parasite and/or by stimulating the protein synthetic machinery and therefore enhancing various enzymatic processes that share in protein synthesis. A reduction in transaminases activity in the liver tissue homogenate was recorded in *S. mansoni* infected mice. The reduction in transaminases activity recorded in this study may be due to liver fibrosis or due to the impairment of the cell membrane permeability leading to release of transaminases from the damaged hepatocytes into the circulation as a result of increased cell membrane permeability. These results are supported by the findings of **Awadalla *et al.***^[62]; **El-Merzabani and EL-Aaser**^[63]; **Abdel-Salam**^[64] and **Al-Sharkawi**^[58]. They observed a significant decrease in transaminases activity in schistosomiasis liver tissue homogenate. They attributed the decreased enzymatic activity of transaminases to the decrease in the number of hepatic cell population in bilharzial liver. Meanwhile, Hostacortin treatment of *S. mansoni* infected mice resulted in a gradual increase in the activity of transaminases by increasing dose regimens of the drug. These results are in accordance with those obtained by **Penchas *et al.***^[65]; **El-Zayadi *et al.***^[60] and **Schiano *et al.***^[66].

Considering the enzymatic activity of alkaline phosphatase, the present data showed increased levels of ALP in *S. mansoni* infected mice. These observations are in accordance with those obtained by **Awadalla *et al.***^[62]; **Al-Sharkawi**^[58] and **El-Hawey *et al.***^[67] who reported that the increase in the enzyme production might be due to the irritation of the hepatocytes by toxins or metabolic products of the schistosome eggs and this would act as a stimulus for the synthesis of more enzymes.

The present results showed that treatment of the infected mice with Hostacortin resulted in a pronounced decrease in the elevated ALP activity and normalize, to some extent, the enzyme activity at dose level of 200 mg/kg. These results could be attributed to the improvement of the hepatocytes by glucocorticoid treatment. Similar findings were reported by **Pyrrho *et al.***^[44]. On the other hand, the results revealed that the treatment of bilharzial infected mice with Vioxx resulted in deleterious harmful in both biochemical and histopathological status of the liver.

In conclusion, the present results obtained in this study showed that Hostacortin treatment of bilharzial mice caused an improvement to some extent, in the state of the liver especially in the histopathological parameters. However, Vioxx treatment in the infected mice resulted in marked hepatotoxicity and this was very clear in the marked increase in the size of granuloma.

REFERENCES

- 1- **El-Morshedy H, Bergquist R, Abou El-Ela NE, Eassa SM, Elsakka EE and Barakat R (2015):** Can human schistosomiasis *mansoni* control be sustained in high-risk transmission foci in Egypt? *Parasit. Vector*, 8:372–380.
- 2- **El-Khoby T, Galal N, Fenwick A, Barakat R, Elhawy A and Nooman Z (2012):** The epidemiology of schistosomiasis in Egypt: summary findings in nine governorates. *Am. J. Trop. Med. Hyg.*, 62:88–99.
- 3- **Hotez PJ, Savioli L and Fenwick A (2012):** Neglected tropical diseases of the Middle East and North Africa: review of their prevalence, distribution and opportunities of control. *PLoS. Negl. Trop. Dis.*, 6: 1475–1482.

- 4- Waine GJ and Manus DP (1997): Schistosomiasis vaccine development – the current picture. *Bio. Essays*, 5: 435-443.
- 5- Hotez PJ, Alvarado M, Basanez M-G, Bolliger I, Bourne R and Boussinesq M (2014): The Global Burden of Disease Study 2010: interpretation and implications for the neglected tropical diseases. *PLoS. Negl. Trop. Dis.*, 8: 2865–2873.
- 6- Barakat RMR (2013): Epidemiology of schistosomiasis in Egypt: travel through time: review. *J. Adv. Res.*, 4: 425–432.
- 7-El-Khoby T, Galal N and Fenwick A (1998): The USAIP/Government of Egypt's Schistosomiasis Research Project (SRP). *Parasitol/Today*, 14:92-96
- 8- Cheever AW, Jankovic D, Yap GS, Kull beg MC, Sher A, and Wynn (1998): Role of cytokines in the formation and down regulation of hepatic circumoval granulomas and hepatic fibrosis in *Schistosoma mansoni* infected mice. *Mem. Inst. Oswaldo Cruz.*, 93 (Supl. 1): 25-32.
- 9- Butterworth AE, Curry AJ, Dunne DW, Fulford AJ, Kimani GH, Kariuki C, Klumpp R, Koech D, Mbuguaa G and Ouma JH (1994): Immunity and morbidity in human *Schistosomiasis mansoni*. *Trop. Geogr. Med.*, 46:197-208.
- 10- WHO (1985): The control of schistosomiasis. First report of a WHO expert committee. World Health Organization, Geneva, Tech. Rep., 728: 1 – 113.
- 11- Dunne DW, Hagan P and Abath FGC (1995): Prospects for immunological control of schistosomiasis. *Molecular and cellular Biology, Ann. Trop. Med. Parasit.*, 345: 1488 – 1492.
- 12- Nahed HA, Hoda AT and Yomna IM (2009): Effects of garlic on albino mice experimentally infected with *Schistosoma mansoni*: a parasitological and ultrastructural study. *Trop.Biomed.*, 26(1):40-50.
- 13- El-Lakkany NM, El-Din SHS, Sabra ANAA, Hammam OA (2011): Pharmacodynamics of mefloquine and praziquantel combination therapy in mice harbouring juvenile and adult *Schistosoma mansoni*. *Mem. Inst. Oswaldo Cruz.*, 106:814–822.
- 14- Aly HF and Mantawy MM (2013): Efficiency of ginger (*Zingbar officinale*) against *Schistosoma mansoni* infection during host-parasite association. *Parasitol.Int.*, 62(4):380-389.
- 15- Hams E Aviello G and Fallon PG (2013): The *Schistosoma* granuloma: friend or foe? *Front. Immunol.*, 89:1–8.
- 16- WHO (2015): Schistosomiasis. <http://www.who.int/schistosomiasis/en>.
- 17- Friedman SL (2000): Molecular regulation of hepatic fibrosis, an integrated cellular response to tissue injury. *J. Biol. Chem.*, 275: 2247-2250.
- 18- Rambaldi A and Gluud C (2000): colchicine for alcoholic and non-alcoholic liver fibrosis and cirrhosis. *Liver*, 20:262-266.
- 19-Porta G (2000): Autoimmune hepatitis. *J.Pediatr.*, 76:5181-5186.
- 20-Alvarez F (2004): Treatment of autoimmune hepatitis, current and future therapies. *Curr. Treat. Options Gastroenterol.*, 7(5):413-420.
- 21- Claria J, Kent JD and Lopez- Parr M. (2005): Effects of celcoxib and naproxen on renal function in non azotemic patients with cirrhosis and ascites. *Hepatol.*, 41(3):579-87.
- 22- John CM (2005): Some anti-inflammatory drugs safe cirrhotic patients. *Hepatol.*, 41(3):215-222.
- 23- Bombardier A, Laine L, Reicin A, Shapiro D, Burgos-Vargas R, Davis B, Day R, Bosi Ferraz M, Hawkey CJ and Hoeborg MC (2000): Comparison of upper gastrointestinal toxicity of rofecoxib and naproxen in patients with rheumatoid arthritis. *N. Engl. J. Med.*, 343:1520-1528.
- 24- Beirne JP and Cairns SR (2002): Cholestatic hepatitis in association with rofecoxib. *BMJ.*, 323: 789-795.
- 25- Bolesterli UA (2002): Mechanisms of NSAIDs- induced hepatotoxicity: focus on nimesulide. *Drug Saf.*, 25(9):633-48.
- 26- George MM, Li SD, Mindikoglu AL and Baluch MH (2004): Platelet sparing effect of COX-2 inhibition used with pegylated interferon alfa -2a for the treatment of chronic hepatitis C: a short term pilot study. *Cytokine*, 27(6): 159-65.
- 27- Christensen NO, Gatshe G and Frandsen F (1984): Parasitological Technique for Use in Routine Laboratory Maintenance of Schistosomes and for Use in Studies on the Epidemiology of Human and Bovine Schistosomiasis. Teaching Notes, Danish Bilharzias Laboratory, Denmark Manual, pp.:112.
- 28-Prata A (1957): Biopsia retal na esquistosoma *mansoni* Base de aplicacoes

diagnosticoe tratamento. Thesis, Servico Nacional de Educacao Sanitaria, Rio de Janeiro. pp.: 197-205.

29- Pellegrino JJ, Oliveira CA, Faria J and Cunha AS (1962): New approach to the screening of drugs in experimental schistosomiasis *mansoni* in mice. Am. J. Trop. Med. Hyg., 11:201-215.

30- Drury RAB and Wallington EA (1980): Carleton's histological technique 4thEd. Oxford, NewYork, Toronto, Oxford University Press. pp.: 41-54.

31- Cheveer AW, Duvall RH and Hillack TA (1983): Hepaticmfibrosis in *S. haematobium* infected mice. Trans. R. Soc. Trop. Med. Hyg., 77(5):673-679.

32- Schmidt E (1963): Colorimetric determination of SGOT. Enzyme. Boil. Clin., 3:1-10.

33-Tietz NW (1976): Determination of alkaline phosphatase. Clin. Chem.W. B. Saunders Co., Philadelphia.

34- Doumas BT and Bigges HG (1972): Determination of serum albumin. New York, Academic press, pp.: 175 – 179.

35- Henry R (1964): Determination of total protein. Clin. Chem. Principles and Technics. Harper and Row, New York, 182: 525 - 531.

36- Peters T (1968): Determination of total protein. Clin. Chem., 14: 1147-1151.

37- Nasr Eldeen SK, Salem ML, Ibrahim WM and Salama AF (2017): Evaluation of the role of some Toll-like receptor ligands as adjuvant for *Schistosoma mansoni* vaccination. Res. J. Pharm. Biol. Chem. Sci., 8(3): 2087-2103.

38- Coker C (1957): Effect of cortisone on natural immunity to *Schistosoma mansoni* in mice. Proc. Soc. Exp. Biol. Med., 96:1-3.

39- Newsome J (1963): Observations on corticosteroid treatment of schistosomiasis in hamsters and baboons. Trans. R. Soc. Trop. Med. Hyg., 57:425-432.

40- Doenhoff M, Musallam R, Bain J and McGregor A (1973): Studies on the host parasite relationship in *Schistosoma mansoni* infected mice: the immunological dependence of parasite egg excretion. Immunology, 35:771-778.

41- Lambertucci JR, Modha JR, Curtis FK and Doenhoff M (1989): The association of steroids and schistosomicides in the treatment of experimental schistosomiasis . Trans. R. Soc. Trop. Med. Hyg., 83:354-357.

42- Hermeto MV, Melo RS, Bicalho AP, Vargas FJ, Favaretto and Pereira L H (1993): Dexamethasone does not reduce the worm burden in mice infected with *in vivo* obtained schistosomules of *Schistosoma mansoni*. Rev. Inst. Med. Trop., 35:389-390.

43- Lenzi HL, Kimmel E, Schechtman H, Pelajo – Machado M, Romanha WS, Pacheco RG, Mariano M and Lenzi JA (1998): Histoarchitecture of schistosomal granuloma development and involution: morphogenetic and biomechanical approaches. Mem. Inst. Oswaldo Cruz., 93 (1): 141 – 151.

44- Pyrrho ADS, Ramos JA, Neto RM, Silva CSD, Lenzi HL, Takiya CM and Gattass CR (2002): Dexamethasone, a drug for attenuation of *Schistosoma mansoni* infection morbidity. Antimicrobial Agents and Chemotherapy, 46(11): 3490-3498.

45- O'connor , Dargan PI and Jones AL (2003): Hepatocellular damage from non-steroidal anti-inflammatory drugs . Q. J. Med., 96: 787-791.

46- Farrel GC (1998): Liver disease caused by drugs, anesthetics, and toxins. In Gastrointestinal and Liver Disease: Pathophysiology, Diagnosis, Management. 6th Ed. Philadelphia: WB Saunders.USA., pp.: 1221 – 1253.

47- Mahmoud MR, Zhciry MM and Nosseir MM (2002): Effect of combined chemotherapy and anti-inflammatory drugs on murine schistosomiasis. Arzneimittelforschung, 52 (4):294-301.

48- Chensue SW, Terebuh PD, Warmington KS, Hershey SD, Evanoff HL, Kunkel SL and Higshi GL (1992): Role of IL. 4 and IFN- in *Schistosoma mansoni* egg- induced hypersensitivity granuloma formation: Orchestration relative contribution and relationship in macrophage fuction. J. Immunol., 148:900-906.

49- WHO (1974): Immunology of schistosomiasis. Geneva.Tech. Rep., 51: 553-595.

50- Dun MA,Rojkind M and Warren KS (1977): Liver collagen synthesis in murine schistosomiasis. J. Clin. Invest., 59: 666-674.

51- Palme G, Kochen M and Leonhardt H (1975): Changes of blood flow in patients with chronic liver disease. Clin. Chim. Acta., 61(2): 163 –169.

52- Boros P Bobrowska E, Prokopowicz D Borzuchowska A Sz Pakowick T, Raczmarska A, Nowak HF, Kuraszs SZ and

- Adkowska D (1986):** Histopathologic and biochemical evaluation of the effect of cortisone on the liver in experimental post-alcoholic liver damage in the rabbit. *Zentralbl. Allg. Patol.*, 131(40):363-370.
- 53- Kenneth R, Cutroneo F, Keneth M and Sterling JR (2004):** How do glucocorticoids compare to oligo decoys as inhibitors of collagen synthesis and potential toxicity of these therapeutics; *J.Cell. Biochem.*, 92(1): 6-15.
- 54- Aoki CA, Bowlus CL and Rossaro L (2005):** An adult case of acute lymphoblastic leukemia presenting as hepatic dysfunction. *Dig. Liver Dis.*, 37(3):206-210.
- 55- Warren KS (1967):** A Comparison of Puerto Rican, Barazilian, Egyptian and Tanzanian strains of *S.mansoni* in mice , penetration of cercariae. Maturation of schistosomes and production of liver disease. *Trans. R. Soc. Trop. Med. Hyg.*, 61:795 -807.
- 56-Warren KS, Pelleg RP and Mahmoud AF (1977):** Immunity and immunopathology following reinfection of mice cured of chronic schistosomiasis *mansoni*. *Am. J.Trop.Med.Hyg.*, 26 (5):957-961.
- 57- Fernanda FM, Costa L, Roche RS and Katz N (1984):** Comparative study of *S. mansoni* isolated from patients with hepatospelenic and intestinal clinical forms of schistosomiasis . *Am. J. Trop. Med. Hyg.*, 33(5): 918 – 923.
- 58- Al-Sharkawi IM (1985):** Studies on the effect of thiola on bilhrzial liver treated with antibilharzial drug. *Ph.D. Thesis, Fac. Sci., Tanta Univ., Tanta, Egypt.*
- 59- Amal IM, Raga AW, Guirgis NH, El-Gazayrlli IM and Hamza S (1979):** Biochemical studies on bilharzial liver in expermintal animals. *Egypt. J. Physiology*, 6(1/2):37-44.
- 60- El-Zayadi A, Mohran Z, Hasseb N, Hasseb N, Nagy N and Dabbour H (1991):** Short term course of corticosteroids in the treatment of resistant ascites complicating schistosomal liver disease. *Am. J. Gastroenterol.*, 86(1): 53 – 56.
- 61- Beck PL (2000):** Mechanisms of NSAIDs-induced gastrointestinal injury defined using mutant mice- *Gastrentrol.*, 119:690-705.
- 62- Awadallah HN, Sherif AF, Shafei AZ, Khalil HA and Guirgis FK (1975):** Enzyme levels in homogenates of liver from mice infected with *Schistosoma mansoni* and from uninfected mice. *Inter. J. Parasitol.*, 5: 27-31.
- 63- El-Merzabani MM and El-Aaser AA (1977):** Simultaneous determination of transaminases and alkaline phosphatase activities in serum. *Z. Klin. Chem. Biochem.*, 13: 453 – 459.
- 64- Abdel-Salam IM (1983):** Biochemical studies on bilharzial liver in the experimental animals. *Ph. D. Thesis, Faculty of Science, Ain Shams University, Cairo, Egypt.*
- 65- Penchas S, ligumski M and Elikim M (1978):** Idiopathic granulomatous hepatitis with a prolonged course: effect of corticosteroid therapy. *Diges.*, 17(1): 46-55.
- 66- Schiano TD, Te HS, Thomas RM, Hussein H, Bond K and Black M (2001):** Results of steroid-based therapy for the hepatitis C-autoimmune hepatitis overlap syndrome. *Am. J. Gastroenterol.*, 96(10): 2984-2991.
- 67- El-Hawey AM, Massoud A, El-Badrawy N, El-Garem A, Khalil A and Metwally A (1985):** Hepatic histochemistry and electron microscopy of hamsters infected with *S. mansoni* and treated with praziquantel therapy. *J. Egypt. Soc. Parasit.*, 15(1): 249-262.