

Effects of Nutrition on Persimmon and Pomegranate Croissants on The Health of Hypertensive Rats

Hanan S. Shalaby and Hanan El-Sayed

Food Science Department (Rural Home Economics), Faculty of Agriculture, Zagazig University, Zagazig, Egypt



مجلة البحوث في مجالات التربية النوعية

معرف البحث الرقمي DOI: 10.21608/jedu.2020.50061.1126

المجلد السابع العدد ٣٢ – يناير ٢٠٢١

الترقيم الدولي


P-ISSN: 1687-3424 E- ISSN: 2735-3346

موقع المجلة عبر بنك المعرفة المصري <https://jedu.journals.ekb.eg/>

<http://jrfse.minia.edu.eg/Hom>

موقع المجلة

العنوان: كلية التربية النوعية – جامعة المنيا – جمهورية مصر العربية



تأثير التغذية على كرواسونات الكاكي والرمان على صحة الفئران المصابة بارتفاع ضغط الدم

د. حنان سعيد شلبي ، د. حنان السيد

قسم علوم الأغذية (شعبة اقتصاد منزلي ريفي) - كلية الزراعة - جامعة الزقازيق

المستخلص:

أجريت الدراسة الحالية لمعرفة تقييم تأثير مساحيق الكاكي والرمان على التركيب الكيميائي والمركبات الفينولية والفلافونيد والنشاط المضاد للأكسدة للمساحيق المضافة للكرواسون. وتمت الدراسة علي خمس مجاميع من فئران التجارب حيث ست فئران بكل مجموعه. المجموعة الأولى وهي مجموعة المقارنة السلبية بينما المجاميع الأربعة الأخرى تم أصابتها برفع ضغط الدم. والمجموعة الثانية هي مجموعة المقارنة الإيجابية والمجموعة الثالثة تم تغذيتها على كرواسون بدون إضافات بينما المجموعة الرابعة والخامسة تم تغذيتهم علي وجبات تكميلية من الكرواسون المحتوى على مساحيق الكاكي والرمان بنسبه ١٥% على التوالي. أوضحت النتائج أن الكرواسون المحتوى على ١٥% من مسحوق الرمان أعلى في نسب البروتين والرماد والألياف. وأوضحت النتائج البيولوجية أن أقل ضغط الدم وجد بمجموعه الفئران المغذاة على الكرواسون المحتوى على ١٥% رمان مع وجود دلالة معنوية يليها مجموعه الفئران المغذاة على كرواسون محتوى علي ١٥% للكاكي وكذلك انخفاض مستوي ليبيدات بيروفيل الدم مع ملاحظه ارتفاع الليبوبروتينات مرتفعه الكثافة بالمجاميع المغذاة علي كرواسون محتوى علي ١٥% رمان أو كاكي. وفي النهاية بفحص القطاعات الهستولوجية وجدت عاديه أكثر لمجاميع الفئران المغذاة على ١٥% من الكاكي أو الرمان. وتوصي الدراسة باستخدام المنتجات التكميلية من الكاكي أو الرمان لمعالجه ومنع الاصابه بضغط الدم.

الكلمات المفتاحية: المركبات الفينولية، وظائف الكبد، وظائف الكلى، ليبيد بيرو فيل الدم .

Effects of Nutrition on Persimmon and Pomegranate Croissants on The Health of Hypertensive Rats

Hanan S. Shalaby and Hanan El-Sayed

Food Science Department (Rural Home Economics), Faculty of Agriculture, Zagazig University, Zagazig, Egypt

Corresponding authors: Shalaby Hanan31@yahoo.com.

Abstract:

The present work was carried out to investigate the effect of chemical composition, phenolic compounds (PC), flavonoids and radical scavenging activity (RSA%) of persimmon (Pr) and pomegranate (Pg) powders with croissant on hypertensive rats were considered. Five groups of rats were studied with 6 rats each. The first group was negative control. The other rats were inflicted with hypertension and distributed on 4 groups. The second group was the positive control, the third, fourth, fifth and 5 groups were fed on diets supplemented with croissant either with no additives or with 15% for persimmon and pomegranate croissant powders, respectively. The results obtained that evaluated croissant containing of 15% pomegranate powder (T4) had the highest protein, ash and fiber percent compared to all other treatments. Biological data indicated that the lowest blood pressure was observed in group rats fed on croissant containing 15% pomegranate, where was the significant ($p \leq 0.05$) different lowering than group rats fed on croissant containing 15% persimmon. The group rats fed on croissant containing 15% persimmon or pomegranate showed lowering of blood lipid profile and considerably improved of the HDL. Also, positive control group demonstrated significantly high liver enzymes and kidney parameters comparing with groups fed croissant containing 15% persimmon or pomegranate. Finally, the histopathological assessment were consistent more or less normalizations for rats fed on croissant containing 15% persimmon or pomegranate. These findings provide a basis for the use of persimmon or pomegranate supplemented products for the prevention and early treatment of hypertension.

Keywords: Phenolic compound, liver functions, kidney functions, blood lipid profile.

Introduction

The consumption of fruit food showing the converse relation to heart diseases (**Genkinger et al., 2004**). Also, fruits has medical effects such as, hypertension by vital bioactive (**Oksuz et al., 2015**). Hypertension can causes the death of a lot of persons by end-organ damage such as stroke, heart failure (**Steckelings et al., 2007**).

The annual production of persimmon in Egypt is probable at 14810 tons and the harvested area is 1787 faddans as documented in **Statistics of the Ministry of Agriculture (2014)**. Persimmon can be excellent source of antioxidants, dietary fibers, vitamins, and polyphenols (**Tuba et al., 2015**). In persimmon fruit pulp, the central phenolic acids have coumaric acid, ferulic acid and carotenoids, gallic acid (**Yaqub et al., 2016**). Persimmon peel has high contents of antioxidants, counting vitamin C, total phenolics, and total carotenoids (**Gorinstein et al., 2001**). Persimmon fruit had excellent source of its bioactive properties, antioxidant and health defensive actions properties (**Karaman et al., 2014**). Eating of persimmon lowing risk of many diseases because of bioactivephenolics for their therapeutic properties (**Yaqub et al., 2016**).

Pomegranate fruits have vital for human health as to higher antioxidant and a rich source of anthocyanins and polyphenols (**Gil et al., 2000**). They have commonly eating by fresh fruit, like beverages (for instance, juices), or nutritional products (for instance, jams) and as extracts where can be using components in herbal medicines and food additions (**Elfalleh et al., 2012**). Pomegranate peel, seed and juice have of phenolic compounds of antioxidant activity (**Derakhshan et al., 2018**). Pomegranate peel and its extracts are tested in several products (**Al-Zoreky et al., 2009**). Pomegranate pronounced level by-productsare used a lot for purpose as functional food components(**Jalal et al., 2018**).The total phenolics of peel extract had almost 10-fold more than the pulp extract (**Iqbal et al., 2008**). Antioxidant action of pomegranate proved to be three times more than those of green tea (**Schubert et al., 1999**). Phenolic compounds are antioxidant phytochemicals with important properties because of free radical scavenging behaviors (**Elfalleh et al., 2011**). Antioxidants have

leading role in health preservation by decreased of the oxidation processes in the body as rich sources of natural antioxidants (Lee *et al.*, 2006). Pomegranate juice may be decreasing blood pressure through a direct interaction (Aviram *et al.*, 2001). Pomegranate juice had the hypotensive properties as antioxidant properties of phytochemicals. Oxidative stress had important in pathogenesis of hypertension, and (Griendling and FitzGerald, 2003).

Persimmon fruits including simply an extremely restricted shelf-life and similar to a lot of fruits like a juice, jam, dried fruit, ice cream, additive of bakery such as croissant and other products and may be have good health effects.

Croissant is a popular bakery product generally consumption for breakfast or lunch in a lot of the world countries (Massoud *et al.*, 2016). It is aerated-flaky product with characteristic laminated structure (Slavica *et al.*, 2007). Also, croissant shaped according to the classic formula should have gold-yellow color. Croissant is known as 'laminated' or 'leafy' products, yeast in dough, identified as 'croissants' and Danish pastries produced using (Cauvain and Young, 2000).

The present study aimed to produce croissant supplemented with persimmon or pomegranate powder and investigate their chemical and phytochemical composition, antioxidant activities and sensory evaluation. Also, the effects of eating such types of croissants on hypertensive rats will be in the scope of this investigation.

Materials and Methods

Materials

Persimmon and pomegranate fruits have been collected from local market, Zagazig city, Egypt. Chemicals and Kits were purchased from local distributors (Sigma chemical), El-Gomhoria company for Trading Drugs, Chemicals and Medical Equipments.

Methods

Preparation of persimmon and pomegranate fruits

Persimmon and pomegranate fruits and pomegranate peels were washed, slashed cautiously to little slices as rings and after that dehydrated in air oven at 40°C for 48 h to moisture content, 8% and milled to powder.

Preparation of croissant

Croissant was prepared according to **Shalaby and Yasin (2013)** with some modifications. Wheat flour (100 g), sugar (4 g) and powder milk (12g) packing powder (2 g), yeast (2g), vanilla (0.5g) and salt (0.5g) were mixed for 3-4 min in a Hobart mixer and the amount of water was added gradually during constant mixing until a slightly firm dough was complete and left to ferment for 15 min. The dough was divided into 5 portions. The first portion was supplied like control without additives. In other, portions croissant persimmon was added at percentages of 7.5% (T1) and 15% (T2) and the three portion croissant pomegranate was added at ratio 7.5%, (T3) and 15%, (T4). The dough divided into 4 pieces, then rolled up. The rolled pieces were put on baking tray brushed with the milk and baked in oven for 10-15 min at a temperature of 200°C. After preparation the croissant were allowed to cool, wrapped with foil paper and stored at 4°C.

Determination of chemical composition

Crude protein, ash and moisture contents were evaluated as described by the techniques outlined in AOAC (2001) in raw materials and croissant.

Determination of phenolic compounds (PC)

The absorption of total phenolic compounds (TPC) in persimmon and pomegranate was determined UV spectrophotometer (Jenway-UV-VIS Spectrophotometer), (**Skerget et al. 2005**) with Folin-Ciocalteu reagent. Total phenolic contents, presented as GAE (galic acid equivalent, GAE g/L).

Radical scavenging activity (RSA) for extracts

The extracts can be calculate with lightening of the wave highlighted solution of DPPH described by the way of **Hanato et al. (1988)**. Persimmon or pomegranate (10 mg extract/10 mL solvent) was using by 3 mL of 0.1 mM DPPH in ethanol. Then incubation period was 60 min at room temperature. The absorbance was measured at 517 nm (**Gulcin et al., 2004**). Antioxidant activity of DPPH was considered by

DPPH scavenging effect (%) = $[(A_0 \text{ (absorbance control)} - A_1 \text{ absorbance samples}) / A_0] \times 100$.

Sensory evaluation of croissant

Ten panelists from Food Science Department, Zagazig University, Faculty of Agriculture, Egypt, were asked to sensory evaluate croissant according to AACCC(1996).

Biological design

Thirty 30 male adult rats 120 -130g each divided into five groups, six rats for each. The adaptation period was seven days. Group one fed on the basal diet and forenamed negative control group(G₁). Next four groups were hypertensive rats and divided into group (G₂) was hypertensive rats fed on basal diet and known a positive control. The other groups fed on croissant, being hypertensive rats fed on 10% croissant without any additives (G₃) and fed on 10 % croissant containing 15% persimmon powder (G₄) and fed on 10% croissant containing 15% pomegranate powder (G₅). All groups were fed for six weeks.

Induction and assessment of blood pressure

Blood pressure was tempted with a single subcutaneous injection of Isoproterenol (ISO) by an amount of 20 mg/kg body weight in 1ml sterile control saline, subcutaneously twice for 2 successive days at an interval of 24 h (Saravanan and Pakash 2004).

Blood sampling and analysis

Blood samples were obtains after the scarified rats and centrifuged at 3200 rpm for 15 min for separated on the serum. Total cholesterol, HDL-C and triglyceride have estimated in serum according to Devi and Sharma (2004). LDL -cholesterol was essayed the method of Johnson *et al.*, (1997). Liver enzymes, alanine amino transferase (ALT), aspartate amino transferase (AST) and total protein, creatine kinase(CK) , CK-MB and lactate dehydrogenase (LDH) were determined as Young (2001). Kidney functions were also, assessed as (Young,2001).

Measurements of blood pressure

Blood pressure was recorded by the method of Shen, (2008). The animals were set in a house holder, the tail hit and beat aerial was positioned on the tail and linked to a louse holder blood pressure watch (Harvard Apparatus) after the rats were warmed at 35°C for 5minutes. The computer showed pressure beat by blood

pressure screen. Heart rate (HR), systolic blood pressure, (SBP), diastolic blood pressure (DBP), and mean arterial pressure (MHP), beats were slowed at the point. The average of three pressure reading was recorded for each measurement.

Histological examination

Specimens from heart, lung and liver were collected after scarified of rats, from different treatments. Sections were scanned for circulatory conflict , inflammatory modifies, degenerations, necrosis, apoptosis and any extra pathologic injury declared by **Suvarna *et al.*, (2013)**.

Statistical examinations

The results were statistically analysed by multi variance ANOVA, and discriminative test by 0.05 meaning values were exploited as Unitarian statistical way to calculate significant differences between treatments significant (**Steel and Torrie, 1980**).

Results

Chemical composition persimmon or pomegranate powder and croissant:

Tables (1) shows the chemical composition powder persimmon and pomegranate and croissant. Results obtained that croissant containing of 15% pomegranate powder (T4) had the highest protein, ash and fiber and this increase might be attributed to increase the concentration fruit powder. While croissant containing 15% persimmon powder (T2) showed the increasing fat content compared with other samples. Also, control croissant(C) was recorded high decrease within fiber content compared with the other samples. Results showed that the increasing peels powder of croissant containing persimmon and pomegranate (T2, T4) due to the decreasing the carbohydrates content and increases the protein content of this products.

These results agree with **Jyoti (2020)** who, reported that persimmon fruit is rich in vitamin A and rich of containing 0.4% protein, 0.7% pectin, 79% water and crude fiber and various bioactive components. Also, **Jung *et al.*, (2005)**, reported that dry persimmon residue had 0.64-1.3 g/ 100 g proteins. **Lee *et al.* (2006)** demonstrated that dehydrated persimmon leaves have

helpful results because of conations of phenolic components (1.15 g/100g) and fiber (63.48 g/ 100g) contents.

In similar results, **Rowayshed *et al.*, (2013)**, described that the pomegranate seed powder can be also, a rich supply of fiber, fat and protein while, pomegranate fruits peel powder is presented a rich source of carbohydrates, ash and crude fiber. **Ozgul-Yucel (2005)** indicated that the pomegranate seeds have a high source of total lipids. **Fadavi *et al.*,(2006)** cleared that pomegranate seed oil can be demonstrate with a rise percent of polyunsaturated (n-3) fatty acids.

The highest moisture content was persimmon and pomegranate croissant because of increase starch and dietary fiber contents of the dough these results agree with **Shahbazadeh *et al.*, (2014)**.

Table (1): Chemical composition of persimmon or pomegranate powder and croissant treatments

Sample	Moisture (%)	Protein (%)	Fat (%)	Ash (%)	Fiber (%)	Carbohydrates (%)
Ps	19.22±0.27 ^e	3.02±0.12 ^f	4.34±0.12 ^c	8.55±0.13 ^b	6.29±0.69 ^c	67.87±0.31 ^a
Pg	14.83±0.27 ^g	4.03±0.15 ^e	3.39±0.10 ^f	12.97±0.09 ^a	11.74±0.13 ^a	64.78±0.09 ^b
C	18.47±0.33 ^f	11.16±0.43 ^d	6.58±0.19 ^d	1.26±0.01 ^g	1.43±0.11 ^d	55.89±0.11 ^c
T1	20.91±0.38 ^d	11.24±0.43 ^d	7.82±0.22 ^{bc}	1.71±0.01 ^f	9.17±0.09 ^b	54.84±0.12 ^d
T2	22.81±0.45 ^b	12.75±0.41 ^b	8.21±0.20 ^a	2.64±0.03 ^e	10.22±0.09 ^b	51.59±0.10 ^e
T3	21.91±0.38 ^e	12.01±0.42 ^c	7.63±0.25 ^c	2.76±0.03 ^d	11.85±0.14 ^a	56.69±0.25 ^c
T4	25.11±0.45 ^a	13.93±0.42 ^a	8.09±0.20 ^{ab}	3.19±0.03 ^c	12.25±1.59 ^a	56.32±1.10 ^c
L.S.D	0.62	0.63	0.35	0.11	1.2	0.81

*Ps, Persimmon peels powder; Pg, Pomegranate peels powder; C, Control croissant; T1, Croissant containing 7.5% persimmon powder; T2, Croissant containing 15% persimmon powder; T3, Croissant containing 7.5% pomegranate powder; T4, Croissant containing 15% pomegranate powder. Mean values followed by different letters in the same column are significantly different at $P \leq 0.05$.

Total phenolic compounds, flavonoids and radical scavenging activity (RSA%) of persimmon and pomegranate

Phenolic compounds (PC), flavonoids and radical scavenging activity (RSA%) of persimmon(Ps) and pomegranate (Pg) are presented in table (2).The results showed that persimmon powder (Ps) had 120.3 mg/100g of TPC and 124.25mg/100g of flavonoids. The radical scavenging activity of persimmon powder (Ps) showed 34.32%. These results agree with **Sun *et al.*, (2011)** who cleared that persimmon fruits showed increased antioxidant

activity and had high of PC as 112.09 ± 4.60 mg GAE/100 g FW. **Chen et al., (2008)** indicated that the persimmon phenolic content was at the highest level (168.15 ± 0.12 mg GAE/100g DW) and radical scavenging activities were 23.575 micromtroloxeq/g f.w. Furthermore, **Jyoti (2020)** showed that persimmon is a beneficial fruit and led potent antioxidant activity because it is enriched by a lot of bioactive compounds. Additionally, **Sakanaka et al., (2005)** showed that the total polyphenols for fresh persimmon are 1.45 mg / 100 g being as gallic acid contents 190.2– 252.2 μ g / 100 g. In similar study, **Jung et al., (2005)** assessed the polyphenols for arid persimmon remains which were 0.16-0.25 g / 100 g polyphenols and 0.002g / 100 g carotenoids. Also, results showed that pomegranate powder (Pg) had 280.7 mg/100g of TPC, 136.91 mg/100g of flavonoids and radical scavenging activity was 36.44%. These results agree with **Abderrezak et al., (2019)** reported that the pomegranate peel extracts had total phenolic content varied from 242.05 ± 7.99 to 638.17 ± 10.59 mg GAE/g , and total flavonoid content (varied from 11.5 ± 0.54 to 53.85 ± 1.95 μ g QE/mg of dry extract) also, the highest scavenging activity was recorded for the ethanolic extract (76.75 ± 2.59 μ g/mL). Phenolic compounds in pomegranate show their beneficial effects by scavenging free radicals (**Lansky et al., 2007**).

Table (2): Total phenolic compounds (TPC), flavonoids and radical scavenging activity (RSA%) of persimmon and pomegranate(Ps and Pg)

Parameter	Persimmon (Ps)	Pomegranate (Pg)
TPC (mg/100g)	120.3	280.7
Flavonoids (mg/100g)	124.25	136.91
Radical scavenging activity (RSA %)	34.32	36.44

*Ps, Persimmon powder; Pg, Pomegranate powder.

Sensory evaluation of persimmon and pomegranate croissant

Sensory evaluation was presented to study the receipt of the persimmon and pomegranate croissant powder. As shown in table (3) the samples indicated that croissant persimmon containing 15% powder is the maximum favorite scores every sensory

assessment panelists. The highest significant persimmon powder in croissant sources high in panelist scores conversing that croissant pomegranate. The addition better croissant property and universal suitability. These consequences agree with that exposed with **Slavica et al., (2007)**, **Massoud et al., (2016)** and **Slavica et al., (2008)**.

Table (3): Sensory evaluation of persimmon and pomegranate croissant.

Sample	Appearance (10)	External (10)	Flavor (10)	Internal (10)	Mat (10)
C	8.80±0.447 ^{ab}	8.80±0.447 ^{ab}	8.80±0.447 ^{ab}	8.80±1.095 ^{ab}	9.00±0.000 ^{ab}
T1	8.00±0.707 ^{bc}	8.00±1.000 ^b	8.40±1.140 ^{ab}	8.60±1.140 ^{ab}	8.00±8.366 ^{ab}
T2	9.40±0.547 ^a	9.40±0.547 ^a	9.20±0.836 ^a	9.20±0.447 ^a	9.00±5.477 ^a
T3	8.40±0.547 ^b	8.20±0.447 ^b	8.40±0.547 ^{ab}	8.20±0.836 ^{ab}	8.00±8.366 ^{bc}
T4	7.20±0.836 ^c	6.60±1.140 ^c	7.80±0.836 ^b	7.40±0.547 ^b	7.00±8.366 ^c
LSD	2.023	2.559	1.272	1.669	15.582

*C, Control croissant; T1, Croissant containing 7.5% persimmon powder; T2, Croissant containing 15% persimmon powder; T3, Croissant containing 7.5% pomegranate powder ; T4, Croissant containing 15% pomegranate powder .Mean values followed by different letters in the same column are significantly different at $P \leq 0.05$.

Blood pressure measurements of rats fed on persimmon and pomegranate croissant

Blood pressure measurements of rats are presented in table (4). Blood pressure measured 2 weeks previous to initiate of the croissant diet, was 140.1 mm Hg for all of the rats groups used in the experiment that was hypertension diseases. Hypertension can be definite like blood pressure 140/90 (**John and Nancy, 2001**). At the end experiments modifies in blood pressure and heart speed were recorded for systolic blood pressure (SBP), diastolic blood pressure (DBP), mean arterial pressure (MHP), and heart rate (HR) beats.

Results indicated that the positive rats group was at significant increase with SBP, DBP, MHP, HR of blood pressure contrasting to negative rats and all samples. Data showed that the decreasing blood pressure changes was in group rats fed on croissant containing 15% pomegranate powder (G_5), while, the significant different lowering then group rats fed on croissant containing 15%

persimmon powder (G₄). These results agree with **Ancos et al., (2000)**, reported that group rats fed on persimmon fruit revealed decreasing blood pressure. **Jyoti (2020)**, demonstrated that the bioactive components specially tannin and carotenoids have benefits in inducing decreasing of free radicals, lowering cardiovascular danger factors (blood pressure). **Giordani et al., (2011)** and **Sakanaka et al., (2005)**, illustrated that persimmon can be use for medicinal reasons against paralysis, coughs, and hypertension.

Mohan et al., (2010), showed that pomegranate juice for four weeks lowed activity of angiotensin converting enzyme (ACE), in addition to reduced mean arterial blood pressure by contrast with non-treated animals. On the other hand. Taking daily of pomegranate juice for two weeks lowed the systolic blood pressure nearly 5% (**Aviram and Dornfeld, 2001**). Drinking of pomegranate juice for three years with patients condensed their blood pressure, LDL oxidation (**Aviram et al., 2004**). Drinking pomegranate juice was lowering systolic with diastolic blood pressure of hypertensive patients (**Asgary et al., 2014**). Pomegranate juice and seed oil are accompanied with efficiently lesser blood pressure (**Asgary et al., 2017**). Pomegranate has vasodilators changes with declining blood pressure that include lowering of oxidative stress (**Wang et al., 2018**).

Table (4): Blood pressure measurements of rats fed on persimmon and pomegranate croissant.

Group	SBP(mmHg)	DBP (mmHg)	MHP (mmHg)	HR (pbm)
G ₁	108.10 ±0.21 ^e	93.10±0.15 ^e	105.50±0.11 ^e	226.20±0.25 ^c
G ₂	154.50±0.23 ^b	126.70±0.33 ^a	136.60±0.12 ^a	286.10±0.31 ^a
G ₃	144.20±0.36 ^a	117.10±0.14 ^b	123.60±0.31 ^b	237.70±0.28 ^b
G ₄	120.20±0.19 ^c	100.60±0.21 ^c	114.90±0.21 ^c	210.50±0.32 ^d
G ₅	109.60±0.17 ^d	99.60±0.12 ^d	112.60±0.25 ^d	202.40±0.36 ^e
L.S.D	0.44	0.37	0.39	0.98

*G₁, Negative control group feeding normal all experiment period; G₂, Positive control hypertensive rats; G₃, Hypertensive rats fed on croissant without any additives; G₄, Hypertensive rats fed on croissant containing 15% persimmon powder; G₅, Hypertensive rats fed on croissant containing 15% pomegranate powder. Mean values followed by different letters in the same column are significantly different at P≤ 0.05.

Creatine kinase (CK), and Creatine kinase MB, (CK-MB) and Lactate dehydrogenase (LDH) measurements of rats fed on persimmon and pomegranate croissant

Results in table (5) showed that rats fed croissant containing 15% pomegranate powder (G₅), were characterized by decreasing significantly serum creatine kinase, CK-MB and lactate dehydrogenase (LDH) compared to with the positive control rats. Such raising accompanied blood pressure in this group. The results demonstrated that the best groups was croissant containing 15% pomegranate powder (G₅), then croissant containing 15% persimmon powder (G₄). These results agree with **Maghamiour and Safaie (2014)**, reported that high serum values of lactate dehydrogenase, creatine kinase and CK-MB and attached to immunoglobulin which due to vessels disease and tumors. **Chinnery et al., (2011)**, explained the stress to muscle tissue or the heart, can be associated with increased total CPK levels.

Table (5): Creatine kinase (CK), creatine kinase MB, (CK-MB) and lactate dehydrogenase measurements of hypertensive rats fed on persimmon and pomegranate croissant

Feeding period	Group	CK (U/L)	CK-MB(U/L)	LDH(U/L)
The initial	-Ve	419.667±30.501 ^e	54.333±7.234 ^e	525.000±106.887 ^e
	+Ve	768.667±98.459 ^d	76.000±11.135 ^e	562.667±71.842 ^e
The end	G ₁	481.667±67.50 ^e	59.667±7.51 ^e	493.667±113.50 ^e
	G ₂	1566.333± 66.01 ^a	476.333±15.56 ^a	2536.333±97.04 ^a
	G ₃	1156.667±36.11 ^b	303.333±15.27 ^b	1433.333±80.82 ^b
	G ₄	915.000±27.00 ^c	263.000±11.00 ^c	1208.000±32.00 ^c
	G ₅	748.333±65.52 ^d	180.333±18.50 ^d	1039.000±93.18 ^c
LSD		106.310	22.659	155.422

*G₁, Negative control group feeding normal in all study period; G₂, Positive control hypertensive rats; G₃, Hypertensive rats fed on croissant without any additives; G₄, Hypertensive rats fed on croissant containing 15% persimmon powder; G₅, Hypertensive rats fed on croissant containing 15% pomegranate powder. Mean values followed by different letters in the same column are significantly different at P ≤ 0.05.

Effects of feeding persimmon and pomegranate croissant on blood lipid profile of hypertensive rats.

Results in table (6) illustrated that groups rats fed on croissant containing 15% persimmon or pomegranate demonstrated lowering in blood lipid profile (T.G, T.C and LDL-c levels) and significantly raised the value of HDL cholesterol. While, triglycerides with positive control rats was significantly rising comparing to rats groups that fed on croissant containing 15% persimmon or pomegranate groups according ($p < 0.05$). Also, results showed that HDL-cholesterol was significantly improved increase in rats fed on croissant containing 15% persimmon or pomegranate groups contrast to positive group ($p < 0.05$). Also, results indicated significant differences in LDL and VLDL-cholesterol between groups.

These results agree with **Jyoti (2020)** indicated that the bioactive components acting a vital function in low arterial stiffness and stop oxidation of LDL therefore resultant in the avoidance of atherosclerotic plaque configuration. The previous studied shows that persimmon phenolics had really influence lipid levels. The dry persimmon had hypolipidemic effects by antioxidant (**Gorinstein et al., 2000**). More than vitro and vivo experiments indicated that the persimmon fruit and its extracts have high potential antioxidant property and the consumption of persimmon can decrease the lipid values and atherosclerotic aorta wounds of rats (**Tian et al., 2012**). These results agree with **Butta et al., (2015)**, showed that persimmon reduce of hypertension where efficiency against free-radical production and rich photochemistry. These results agree with **Al-Sayed et al., (2019)** and **Gorinstein et al. (2001)** reported that persimmon peel lowered, blood glucose, plasma triglycerides and total cholesterol value in diabetics.

Also, drinking of pomegranate juice reduced the LDL to collective and improved the activity of serum paraoxonase (**Aviram et al., 2000**), an esterase connected with HDL and protected lipids via prevent oxidation (**Chistiakov et al., 2017**). Pomegranate juice reserved the oxidations of taken LDL and cholesterol (**Fuhrman et al., 2005**). Pomegranate leaves extract reduced energy intake, body weight, and lipid profile and glucose values (**Lei et al., 2007**) and improved blood pressure and LDL oxidation (**Aviram et al., 2004**).

Table (6): Effect of feeding persimmon and pomegranate croissant on blood lipid profile of hypertensive rats

Feeding period	Group	T.C (mg/dl)	T.G (mg/dl)	HDL(mg/dl)	LDL (mg/dl)	VLDL(mg/dl)
The initial	-Ve	130.103±8.568 ^d	97.520±2.507 ^c	55.333±1.154 ^a	55.267±6.105 ^{ef}	19.503±0.502 ^c
	+Ve	158.583±1.396 ^d	120.780±9.332 ^b	51.316±0.932 ^b	83.111±2.710 ^d	24.156±1.864 ^b
The end	G ₁	112.163±12.192 ^c	81.330±2.770 ^d	52.787±0.91 ^b	43.110±12.65 ^f	16.266±0.56 ^e
	G ₂	260.240±3.980 ^a	191.513±7.476 ^a	42.363±1.67 ^e	179.575±14.14 ^a	38.302±0.81 ^a
	G ₃	192.667±2.305 ^b	118.013±2.571 ^b	45.217±1.59 ^d	123.848±4.14 ^b	23.607±1.16 ^b
	G ₄	159.203±11.045 ^c	94.183±4.025 ^c	48.450±0.70 ^c	91.917±10.94 ^c	18.836±0.81 ^c
	G ₅	132.923±7.285 ^d	89.343±3.205 ^{cd}	52.580±0.42 ^b	62.475±6.23 ^{de}	17.868±0.65 ^{cd}
LSD		174.277	113.543	13.992	174.906	22.932

*-Ve, Negative control group; +Ve, Positive control group; G₁, Negative control group feeding normal all experiment period; G₂, Positive control hypertensive rats; G₃, Hypertensive rats fed on croissant without any additives; G₄, Hypertensive rats fed on croissant containing 15% persimmon powder; G₅, Hypertensive rats fed on croissant containing 15% pomegranate powder. Mean values followed by different letters in the same column are significantly different at P≤ 0.05.

Effect of feeding persimmon and pomegranate croissant on liver and kidney function of hypertensive rats

Effect of feeding persimmon and pomegranate croissant on liver and kidney functions of hypertensive rats is presented in table (7). Results illustrated that the rats groups fed croissant containing 15% persimmon or pomegranate were described with rising means serum total protein contrast with the positive rats. These raise might be high protein contents of croissant. Data in results demonstrated of positive group proved significant high in liver enzymes (ALT, AST) and (uric acid and creatinine) kidney functions comparing to groups fed croissant containing 15% persimmon or pomegranate that was decreased. Where, croissant containing 15% persimmon or pomegranate contains many bioactive agents like polyphenols. The greatest groups was croissant containing 15% pomegranate where was decreasing levels of ALT, AST and creatinine then groups croissant containing 15% persimmon. The feeding rats on croissant containing 15% persimmon or pomegranate against the increase of signify ALT, activities and creatinine. This study are agree with previous studies **Khalil, (2005)** pomegranate extract decreasing the AST, ALT, and ALP.

Table (7): Effect of feeding persimmon and pomegranate croissant on liver and kidney functions of hypertension rats

Feeding period	Group	ALT (U/L)	AST (U/L)	T.P (g/dl)	Creatinine (mg/dl)	Urea (mg/dl)
The initial	-Ve	27.580±2.290 ^{de}	75.153±5.726 ^e	6.043±0.191 ^{cd}	0.5533±0.040 ^d	19.180±0.943 ^f
	+Ve	34.000±2.000 ^d	73.666±17.616 ^e	6.803±0.551 ^{ab}	0.7467±0.032 ^c	23.720±2.977 ^e
The end	G ₁	22.043±2.11 ^e	90.030±7.13 ^e	6.960±0.11 ^a	0.560±0.01 ^d	20.300±2.80 ^{ef}
	G ₂	127.403±11.55 ^a	242.920±6.08 ^a	4.443±0.41 ^e	0.977±0.06 ^a	74.690±2.49 ^a
	G ₃	88.487±1.22 ^b	180.300±8.34 ^b	5.583±0.31 ^d	0.853±0.04 ^b	58.677±2.14 ^b
	G ₄	73.983±1.53 ^c	156.303±8.08 ^c	6.353±0.11 ^{bc}	0.830±0.02 ^b	50.780±1.33 ^c
	G ₅	67.583±2.59 ^c	137.293±13.87 ^d	6.780±0.04 ^{ab}	0.753±0.02 ^c	40.303±2.13 ^d
LSD		155.592	189.875	2.704	0.470	0.470

*-Ve, Negative control group; +Ve, Positive control group; G₁, Negative control group feeding normal all experiment period; G₂, Positive control hypertensive rats; G₃, Hypertensive rats fed on croissant without any additives; G₄, Hypertensive rats fed on croissant containing 15% persimmon powder; G₅, Hypertensive rats fed on croissant containing 15% pomegranate powder. Mean values followed by different letters in the same column are significantly different at P ≤ 0.05.

Histological assessment

The improving effects of hypertensive rats feeding on croissant persimmon or pomegranate 15% powder were established by histopathological analysis of the heart, lung and liver are revealed in photo.(1-14).

Heart sections

Photo (1), shows heart of negative control group (G₁), serial sections revealed apparently normal vascular structures (coronary and intramuscular blood vessels and capillaries). The contractile and conducting structures of the heart including the cardiomyocytes and the Purkinje fibers respectively were histomorphologically normal. The sarcolemmal cells and the interstitial tissue were in a good histological appearance Photo (1). While in Photo. (2), positive control group (G₂), indicated cardiac lesions were represented by marked congestion of coronary and intramuscular blood vessels, arterioles and capillaries together with focal atrophic and apoptotic changes in a variable number of cardiomyocytes (3-5%) and degenerative changes in some vascular walls, mostly of hypoxic origin Photo. (2). On the observed also Photo (3), group fed on croissant without any additives (G₃), heart sections of this group exposed modest

overcrowding of coronary and intramuscular blood vessels , focal atrophic, degenerative and apoptotic effects in a little of cardiomyocytes (2-4%) beside focal hyperplasia and hypertrophy of the sarcolemmal cells. While Photo (4), group rats fed on croissant containing 15% persimmon powder (G₄), appeared that heart changes in this group were cardiac changes in this group was mild and represented by mild dilatation of some coronary and intramuscular blood vessels. Most of the cardiomyocytes and the sarcolemmal cells were apparently normal and in a good morphological appearance. Photo (5), group rats fed on croissant containing 15% pomegranate powder (G₅), showing, heart sections apparently normal histo-morphology of the coronary and intramuscular blood vessels beside normal cardiomyocytes, sarcolemmal cells and interstitial tissue.

Lung sections

Lung sections of rats in negative control group (G₁) of Photo (6), denoted normal bronchial wall, free of any pathological changes, usually lined by columnar or pseudo-stratified epithelium, the alveolar ducts and walls were apparently normal with a well structural morphology of the simple squamous pneumocyte type I and the cuboidal-like pneumocyte type II and the spindle to ovoid alveolar macrophages. Photo (7) lung sections positive control group (G₂) exposed pulmonary changes in this group were characterized by moderate to severe congestion and dilatation of blood vessels (pulmonary veins, parabronchial vessels and interalveolarvenules and capillaries), proliferative changes in the parabronchial lymphoid aggregates and vital thickening of the interalveolar septa with hyperplastic and hypertrophic pneumocytes kind 2 and alveolar macrophages beside focal compensatory alveolar emphysema. Photo (8), group fed on croissant without any additives (G₃), lung sections of this group revealed apparently normal histo-morphology in all anatomical counterparts, however some sections pointed out mild to moderate congestion of some pulmonary venules, residual emphysematous changes and mild peri-bronchial round cells infiltration. Photo (9), group rats fed on croissant containing 15% persimmon powder (G₄), demonstrated that pulmonary changes in this group were very mild, all structures were hiso-morphologically

normal apart of mild dilatation of some peri-bronchial arterioles and residual emphysematous changes. On the experiential also Photo (10),lung sections in group fed on croissant containing 15% pomegranate powder (G₅) revealed pulmonary investigation of this group pointed out normal structures regarding the bronchial walls, vascular diameters and structures and alveolar histomorphology. A remnant mild emphysematous changes were recorded.

Liver sections

Liver segments of rats in positive group (G₂) of Photo (11),showed marked dilatation and overcrowding of hepatic blood vessels (entry blood vessels, central veins and hepatic sinusoids), biliary proliferative changes in large number of bile ducts and ductless beside focal atrophic and apoptotic changes in variable numbers of hepatic cells (5-8% A few round cells were seen infiltrating the portal area. Photo (12) group fed on croissant without any additives (G₃), examined liver sections of this group exposed gentle to modest dilatation of hepatic blood vessels (mainly central veins) and sinusoids, centro-lobular degenerative changes probably, fatty degeneration and hypertrophied Von Kupffer cells. Photo (13) group fed on croissant containing 15% persimmon powder (G₄), all examined liver sections demonstrated apparently normal hepatic parenchyma and stroma. Some liver sections revealed mild congestion of hepatic central veins and sinusoids, and hypertrophied Von Kupffer cells. Photo (14) group fed on croissant containing 15% pomegranate powder (G₅), appeared serial sections from liver of this group revealed apparently normal hepatic parenchyma and stroma with normal arrangement of portal areas hepatic lobules, hepatic cords, central veins , sinusoids and Von-Kuffer cells. The later were moderately hypertrophied.

Several phytochemical have anti-mutagenic changes and control and activate the immune system therefore important in the normal performance of the metabolism. They also provide while chemo defensive, anti-cancer, anti-inflammatory and immune modulator (**Butt et al., 2015**). The useful effects of pomegranate

ingestion on the vasculature was moderately with urolithin A glucuronide (Gimenez- Bastida *et al.*, 2012).

As a result, the plan of this research can be assess the produce of the croissant persimmon or pomegranate on chemical composition sensory properties and blood pressure and serum lactate dehydrogenase (LDH) and creatine kinase , CK-MB of rats. Impact of eating croissant persimmon or pomegranate on serum lipid profile and potential healthiness useful of hypertension rats.

Heart sections

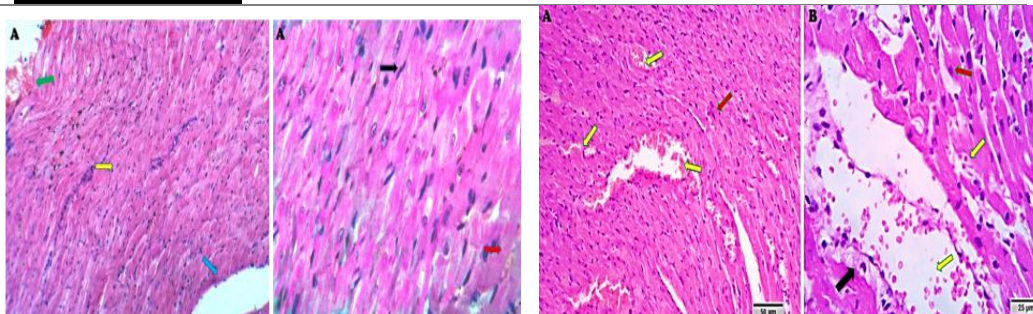


Photo (1). Heart negative control group rats (G_1), showing apparently normal vascular structures (coronary and intramuscular blood vessels and capillaries, blue and red arrows) the cardiomyocytes appear histomorphologically normal (yellow arrow). The sarcolemmal cells are in a good histological appearance. (black arrow). Scale bars 50 μ m, 25 μ m.

Photo (2). Heart positive control group rats (G_2), Heart of (B1) rats showing marked congestion of coronary and intramuscular blood vessels, arterioles and capillaries (yellow arrows) together with focal atrophic and apoptotic changes in a variable number of cardiomyocytes (red arrows) and degenerative changes in some vascular walls (black arrow). Scale bars 50 μ m , 25 μ m.

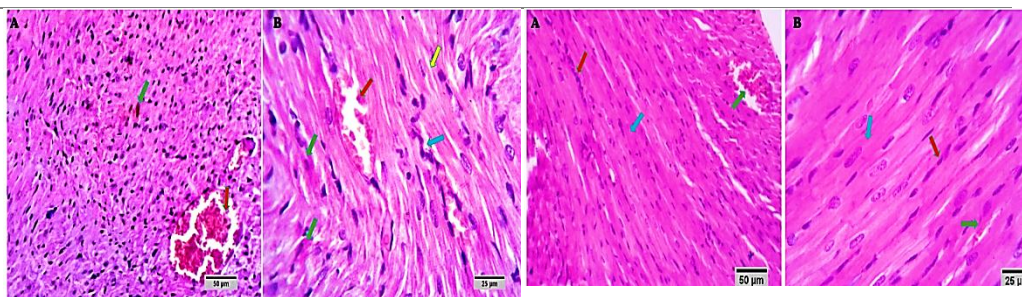


Photo (3). Heart of group rats fed on croissant without any additives (G₃), (D1) showing congestion of coronary and inter muscular blood vessels (red arrows), focal atrophic, degenerative and apoptotic changes in a few cardiomyocytes (green arrows) beside focal hyperplasia and hypertrophy of the sarcolemmal cells (blue arrows). Normal cardiomyocytes are seen (yellow arrow). scale bars 50 um , 25 um.

Photo (4). Heart group rats fed on croissant containing 15% persimmon powder (G₄), (D2) showing mild dilatation of some coronary and intramuscular blood vessels (green arrows).The cardiomyocytes and sarcolemmal cells appears normal and in a good morphological appearance (blue and red arrows) . Scale bars 50 um , 25 um.

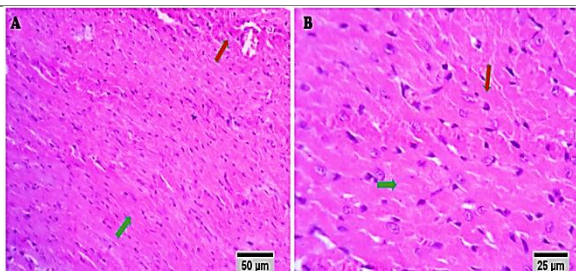


Photo (5). Heart group rats fed on croissant containing 15% pomegranate powder (G₄), showing apparently normal histomorphology of the coronary and intramuscular blood vessels (red arrows) beside normal cardiomyocytes , sarcolemmal cells and interstitial tissue (green arrows) . Scale bars 50 um , 25 um .

Lung sections

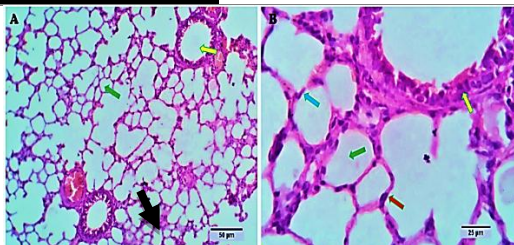


Photo (6).Lung negative control group rats (G_1), showing normal bronchial wall, lined by columnar or pseudo-stratified epithelium (yellow arrow), the alveolar ducts and walls are apparently normal (green arrows) with a well structural morphology of the simple squamous pneumocyte type I (blue arrow) and the cuboidal-like pneumocyte type II (red arrow) and the spindle to ovoid alveolar macrophages (black arrow), Scale bars 50 μ m , 25 μ m.

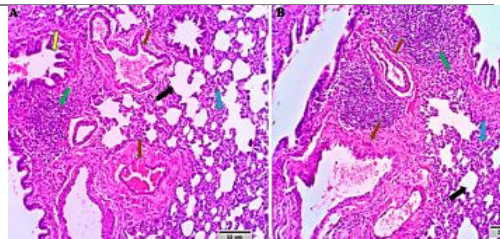


Photo (7). Lung positive control group (G_2), showing congestion and dilatation o pulmonary f blood vessels (red arrows), proliferative changes in the parabronchial lymphoid aggregates (green arrows) and focal condensing of the interalveolar septa by hyperplasic and hypertrophic pneumocytes type 2 and alveolar macrophages (blue arrows) beside focal compensatory alveolar emphysema (black arrows). Apparently normal bronchioles are seen (yellow arrow) Scale bars 50 μ m , 25 μ m.

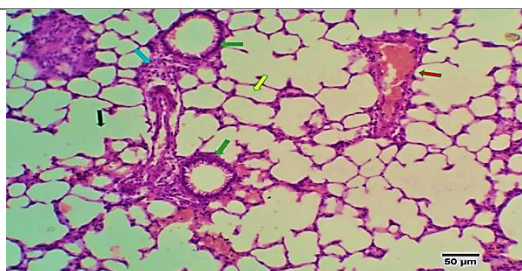


Photo (8).Lung of group fed on croissant without any additives (G_3), showing congestion of some pulmonary venules (red arrow), residual emphysematous changes (black arrow) and mild peribronchial round cells infiltration (blue arrow). Apparently normal bronchioles and alveoli are seen (green and yellow arrows). Scale bar 50 μ m.

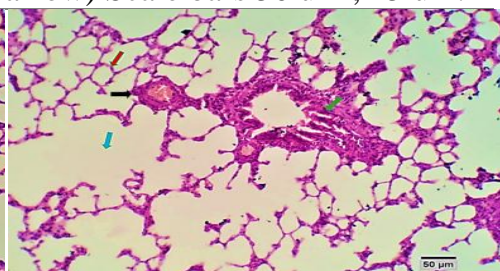


Photo (9).Lung of group fed on croissant containing 15% persimmon powder (G_4), showing mild dilatation of some peribronchial arterioles (black arrow) and residual emphysematous changes (blue arrow). Apparently normal bronchiol is seen (green arrow) .Scale bar 50 μ m.

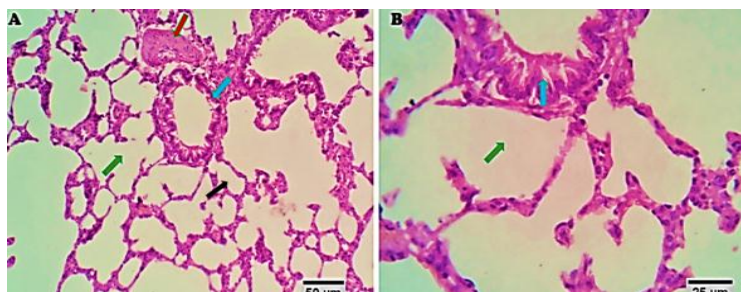


Photo (10). Lung of group fed on croissant containing 15% pomegranate powder (G_5), showing normal structures including the bronchial walls (blue arrows), vascular diameters and structures (red arrow) and alveolar histo-morphology (black arrow). A remnant mild emphysematous changes are seen, (green arrows).

Liver sections

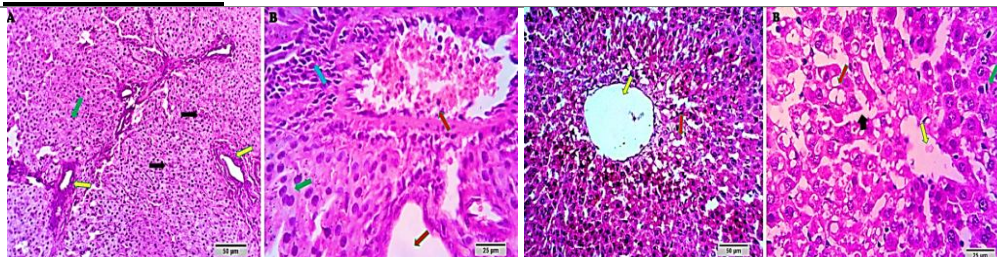


Photo (11). Liver positive control group (G_2), showing marked dilatation and congestion of portal blood vessels (red arrows), biliary proliferative changes in large number of bile ducts and ductulus (yellow arrows) beside focal atrophic and apoptotic changes in variable numbers of hepatic cells. (black arrows). A few round cells are seen infiltrating the portal area (blue arrow). The remaining hepatic parenchyma appears normal (green arrows). Scale bars 50 μ m, 25 μ m.

Photo (12). Liver of group fed on croissant without any additives (G_3), showing dilatation of hepatic blood vessels mainly central veins and sinusoids (yellow and black arrows) centro-lobular degenerative changes probably, fatty degeneration (red arrows) and hypertrophied Von Kupffer cells (green arrow). Scale bars 50 μ m, 25 μ m .

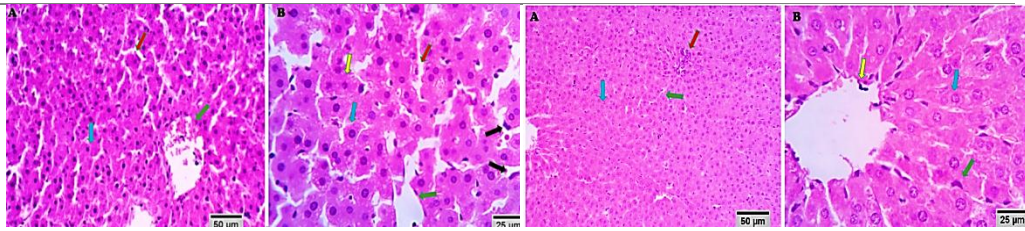


Photo (13). Liver of group fed on croissant containing 15% persimmon powder (G₄), rats showing apparently normal hepatic parenchyma and stroma (blue and yellow arrows). Mild congestion of hepatic central veins and sinusoids (green and red arrows), and hypertrophied Von Kupffer cells (black arrows) are seen. Scale bars 50 μm, 25 μm

Photo (14). Liver of group fed on croissant containing 15% pomegranate powder (G₅). rats showing apparently normal hepatic parenchyma and stroma with normal arrangement of portal area (red arrow) hepatic lobules, hepatic cords (blue arrows), central veins (yellow arrow), sinusoids and hypertrophied Von-Kuffer cells (green arrows). Scale bars 50 μm, 25 μm.

Conclusion

Eating croissant containing 15% persimmon or pomegranate powder is rich source of natural bioactive compounds. Also, have protective effects on high blood pressure, and lowering lipid profile and decreasing serum creatine kinase CK-MB and lactate dehydrogenase (LDH) and humanizing beneficial healthy liver and kidney functions and improving heart, lung and liver tissues. So, it could be suggested to consume croissant containing 15% persimmon or pomegranate.

References

- AACC (1996).** American Association of Chemists. Approved Method of A.A.C.C. Published by the American Association of Cereal Chemists. Inc., St. Paul., Minnesota, USA, pp.4, 13 and 61.
- Abderrezak, K. and Hayat, A. (2019).** Comparison of five solvents in the extraction of phenolic antioxidants from pomegranate (*Punicagranatum*L.) peel. The North African J. Food and Nutr. Res., 03:140-147.

- Al-Sayed, H.M.A.; Abdelalemand, M.A. and Elkatry, H.O. (2019).** Chemical, technological and biological evaluation of mulberry and persimmon leaves. Arab J. Nuclear Sci. and Applications, 52: 45-63.
- Al-Zoreky, N.S. (2009).** Antimicrobial activity of pomegranate (*Punicagranatum L.*) fruit peels. Int. J. Food Microbiol.,134: 244-48.
- Ancos, B. De.; Gonzalez, E. and Cano,M.P. (2000).** Effect of high-pressure treatment on the carotenoid composition and the radical scavenging activity of persimmon fruit purees, J. Agric. and Food Chem., 48: 3542–3548.
- AOAC (2001).** Official Methods of Analysis of the Association of Official Analytical Chemists 15Th E.d. Washington, D.C.,U.S.A.
- Asgary, S.; Keshvari, M.; Sahebkar, A. and Sarrafzadegan, N. (2017).** Pomegranate consumption and blood pressure: a review. Current pharmaceutical design, 23: 1042–1050.
- Asgary, S.;Sahebkar, A.;Afshani, M.R.; Keshvari, M.; Haghjooyjavanmard, S. and Rafieian-Kopaei, M. (2014).** Clinical evaluation of blood pressure lowering, endothelial function improving, hypolipidemic and anti-inflammatory effects of pomegranate juice in hypertensive subjects. Phototherapy Res. 28: 193–199.
- Aviram, M. and Dornfeld, L. (2001).** Pomegranate juice consumption inhibits serum angiotensin converting enzyme activity and reduces systolic blood pressure. Atherosclerosis 158: 195–198.
- Aviram, M.; Dornfeld, L.; Rosenblat, M.; Volkova, N.; Kaplan, M.; Coleman, R.; Hayek, T.; Presser, D. andFuhrman, B. (2000).** Pomegranate juice consumption reduces oxidative stress, atherogenic modifications to LDL, and platelet aggregation: studies in humans and in atherosclerotic apolipoprotein E-deficient mice. *The American J. Clinical Nutr.*,71: 1062–1076.
- Aviram, M.; Rosenblat,M.; Gaitini,D.; Nitecki, S.; Hoffman, A.; Dornfeld, L.; Volkova, N.;Presser, D.; Attias, J.; Liker, H. andHayek, T. (2004).** Pomegranate juice consumption for three years by patients with carotid artery stenosis ereduces common carotid intima –media thickness, blood pressure and LDL oxidation. J. Clinical Nutr., 23:423-33.
- Butta, M.S.;Sultanb, M.T.; Aziza, M.; Nazc, A.; Ahmeda, W.; Kumard, N. and Imrane, M. (2015).** Review article:

- Persimmon (*Diospyros Kaki*) Fruit: Hidden phytochemicals and health claims. *Experimental and Clinical Sci. J.*, 14:542-561.
- Cauvain, P.S. and Young, S.L.** (2000). Bakery food manufacture and quality water control and effects. Blackwell Science Ltd., Printed in Great Britain, p 62-64.
- Chen, X. N.; Fan, J.E.; Yue, X.; Wu, R. and Li, L.T.**(2008). Radical scavenging activity and phenolic compounds in persimmon (*Diospyros kaki L. Cv. Mopan*), *J. Food Sci.*, 73: 24-28.
- Chinnery, P.F.** (2011). Muscle Diseases. In: Goldman L, Schafer AI, Eds. Cecil Medicine. 24th ed. Philadelphia, Pa: Saunders Elsevier.
- Chistiakov, D.A.; Melnichenko, A.A.; Orekhov, A.N. and Bobryshev, Y.V.** (2017). Paraoxonase and atherosclerosis-related cardiovascular diseases. *Bioch.*, 132: 19–27.
- Derakhshan, Z.; Ferrante, M.; Tadi, M.; Ansari, F.; Heydari, A.; Hosseini, M.S.; Conti, G.O. and Sadarabad, E.K.** (2018). Antioxidant activity and total phenolic content of ethanolic extract of pomegranate peels, juice and seeds. *Journal of Food and Chemical Toxicology*, 114:108-11.
- Devi, R., and Sharma, D.K.** (2004). Hypolipidemic effect of different extracts of *Clerodendron colebrookianum* Walp in normal and high-fat diet fed rats. *J. Ethnopharmacol.*, 90: 63-68.
- Elfalleh, W.; Hannachi, H.; Tlili, N.; Yahia, Y.; Nasri, N. and Ferchichi, A.** (2012). Total phenolic contents and antioxidant activities of pomegranate peel, seed, leaf and flower. *J. Medicinal Plants Res.*, 6: 4724-4730.
- Elfalleh, W.; Tlili, N.; Nasri, N.; Yahia, Y.; Hannachi, H.; Chaira, N.; Ying, M. and Ferchichi, A.** (2011). Antioxidant capacities of phenolic compounds and tocopherols from tunisian pomegranate (*Punicagranatum*) Fruits. *J. Food Sci.*, 76:707-713.
- Fadavi, A.; Barzegar, M. and Azizi, H.M.** (2006). Determination of fatty acids and total lipid content in oilseed of 25 pomegranates varieties grown in Iran. *J. Food Composition and Analysis*, 19: 676-680.
- Fuhrman, B.; Volkova, N. and Aviram, M.** (2005). Pomegranate juice inhibits oxidized LDL uptake and cholesterol biosynthesis in macrophages. *The J. Nutr. Bioche.*, 16: 570–576.
- Genkinger, J.M.; Platz, E.A.; Hoffman, S.C.; Comstock, G.W. and Helzlsouer, K.J.**(2004). Fruit, vegetable, and antioxidant intake and all-cause, cancer, and cardiovascular disease mortality in a

- community-dwelling population in Washington County, Maryland. *American J. Epidemiol.* 160: 1223–33.
- Gil, M.I.; Tomas-Berberan, A.; Hess-Pierce, B.; Holcroft, D.M. and Kader, A.A. (2000).** Antioxidant activity of pomegranate juice and its relationship with phenolic composition and processing. *J. Agric. and Food Chem.*, 48: 4581–4589.
- Giménez-Bastida, J.A.; González-Sarrías, A.; Larrosa, M.; Tomas-Barberan, F.; Espin, J.C. and Garcia-Conesa, M.T. (2012).** Ellagitannin metabolites, urolithin A glucuronide and its aglycone urolithin A, ameliorate TNF- α -induced inflammation and associated molecular markers in human aortic endothelial cells. *Mol. Nutr. Food Res.* 56: 784–796.
- Giordani, E.; Doumett, S.; Nin, S. and Del Bubba, M. (2011).** Selected primary and secondary metabolites in fresh persimmon (*Diospyros kaki Thunb.*): A review of analytical methods and current knowledge of fruit composition and health benefits. *J. Food Res. Inter.*, 44: 1752–1767.
- Gorinstein, S.; Kulasek, G.W.; Bartnikowska, E.; Leontowicz, M.; Zemser, M.; Morawiec, M. and Trakhtenberg, S. (2000).** The effects of diets, supplemented with either whole persimmon or phenol-free persimmon, on rats fed cholesterol. *Food Chem.*, 70: 303–308.
- Gorinstein, S.; Zachwieja, Z.; Folta, M.; Barton, H.; Piotrowicz, J.; Zemser, M.; Weisz, M.; Trakhtenberg, S. and Martín-Belloso, O. (2001).** Comparative contents of dietary fiber, total phenolics, and minerals in persimmons and apples. *J. Agric. and Food Chem.*, 49: 952–957.
- Griendling, K.K. and FitzGerald, G.A. (2003).** Oxidative stress and cardiovascular injury: Part II: Animal and human studies. *J. Circulation*, 108: 2034–40.
- Gulcin, I.; Kufrevioglu, O.I.; Oktay, M. and Buyukokuroglu, M.E. (2004).** Antioxidant, antimicrobial, antiulcer and analgesic activities of nettle (*Urtica dioica L.*). *J. ethnopharmacol.*, 90: 205–215.
- Hanato, T.; Kagawa, H.; Yasuhara, T. and Okuda, T. (1988).** Two new flavonoids and other constituents in licorice root: Their relative astringency and radical scavenging effects. *Chemical & pharmaceutical bulletin*. 36: 2090–2097.
- Iqbal, S.; Haleem, S.; Akhtar, M.; Zia-ul-Haq, M. and Akbar, J. (2008).** Efficiency of pomegranate peel extracts in stabilization

- of sunflower oil under accelerated conditions. *Food Res. Inter.*, 41: 194-200.
- Jalal, H.; Pal, M.A.; Ahmad, S.R.; Rather, M.; Andrabi, M. and Hamdani, S. (2018).** Physico-chemical and functional properties of pomegranate peel and seed powder. *The Pharma Innovation Journal*, 7:1127-1131.
- John, A. O. and Nancy, J. B. (2001).** Antihypertensive agents and the drug therapy of Hypertention. In: Goodmann and Gilman's, the Pharmacological Basis of Therapeutics. 10th ed, McGraw-Hill, Medical Publishing Division, New York, pp.871 – 872.
- Johnson, R.; McNutt, P.; MacMahon, S. and Robson, R. (1997).** Use of the friedewald formula to estimate LDL-cholesterol in patients with chronic renal failure on dialysis. *J. Clinical Chem.*, 4:2183-2184.
- Jung, S.T.; Park, Y.S.; Zachwieja, Z.; Folta, M.; Barton, H.; Piotrowicz, J.; Katrich, E.; Trakhtenberg, S. and Gorinstein, S. (2005).** Some essential phytochemicals and the antioxidant potential in fresh and dried persimmon. *International J. Food Sci. and Nutr.*, 56:105-13.
- Jyoti, P.(2020).** Persimmon (*Diospyros kaki*): Apple of the Orient: A Review. *International Journal of Health Sciences and Research*. 10; 3: 129.
- Karaman, S.; Toker, O.S.; Yuksel, F.; Am, M.C; Kayacier, A. and Dogan, M. (2014).** Physicochemical, bioactive, and sensory properties of persimmon-based ice cream: Technique for order preference by similarity to ideal solution to determine optimum concentration, *J. Dairy Sci.*, 97: 97–110.
- Khalil, E.A.M. (2005).** Biochemical and histopathological changes in male albino rats treated with overdose of an aqueous extract of pomegranate (*Punicagranatum L.*) pericarps. *The Egyptian J. Hospital Medicine*, 16: 132 – 139.
- Lansky, E.P. and Newman, R.A. (2007).** *Punicagranatum* (pomegranate) and its potential for prevention and treatment of inflammation and cancer. *J. Ethnopharmacol.* 109:177-206.
- Lee, M.K.; Bok S.H. ; Jeong, T.S. ; Moon, S.S. ; Lee, S.E. ; et al. (2002)** Supplementation of naringenin and its synthetic derivative alters antioxidant enzyme activities of erythrocyte and liver in high cholesterol fed rats. *Bioorg. Med. Chem.* 10: 2239-2244.

- Lee, J.S.; Lee, M.K.; Ha, T.Y.; Bok, S.H.; Park, H.M.; Jeong, K.S.; Woo, M.N.; Yeo, J-Y; Do, G. M. and Choi, M.S. (2006).** Supplementation of whole persimmon leaf improves lipid profiles and suppresses body weight gain in rats fed high-fat diet. *J. Food and Chem. Toxicol.*, 44: 1875–83.
- Lei, F.; Zhang, X.N.; Wang, W.; Xing, D.M.; Xie, W.D.; Su, H. and Du, L.J. (2007).** Evidence of anti-obesity effects of the pomegranate leaf extract in high-fat diet induced obese mice. *International j. Obesity*, 31: 1023–1029.
- Maghamiour, N. and Safaie, N. (2014).** High Creatine Kinase (CK)-MB and Lactate Dehydrogenase in the Absence of Myocardial Injury or Infarction: A Case Report. *J. cardiovascular and Thoracic Research*, 6 (1): 67-70.
- Massoud, R.;Khosravi, K.;Varga, L. and Nakhsa, F. (2016).** Evaluation of Physicochemical, Microbiological and Sensory Properties of Croissants Fortified with *Arthrospiraplatensis* (*Spirulina*). *Czech J. of Food Sci.*, 34: 350–355.
- Mohan, M.; Waghulde, H. andKasture, S. (2010).** Effect of pomegranate juice on angiotensin II-induced hypertension in diabetic Wistar rats. *Phytotherapy research*, 24:(Suppl 2), S196–203.
- Oksuz, T.; Surek, E.; Tacer-Caba, Z. andNilufer-Erdil, D. (2015).** Phenolic contents and antioxidant activities of persimmon and red beet jams produced by sucrose impregnation. *J. Food Sci. and Technol.*, 3: 1-8.
- Ozgul-Yucel, S. (2005).** Determination of conjugated linolenic acid content of selected oil seeds grown in Turkey. *J. the American Oil Chemists Society*, 82: 893-897.
- Pachisia, J. (2020).** Persimmon (*Diospyros kaki*): Apple of the Orient: A Review. *Int. J. Health Sci. and Res.*, 10:129-133.
- Rowayshed, G.; Salama, A.; Abul-Fadl, M.;Akila-Hamza, S.andEmad, A.M.(2013).** Nutritional and chemical evaluation for pomegranate (*Punicagranatum*L.) fruit peel and seeds powders by products. *Middle East Journal of Applied Sciences*, 3:169-179.
- Sakanaka, S.; Tachibana, Y. and Okada, Y. (2005).** Preparation and antioxidant properties of extracts of Japanese persimmon leaf tea (Kakinoha-cha). *J. Food Chem.*, 89:569-575.
- Saravanan, G. andPakash, J. (2004).** Effect of garlic (*Allium sativum*) on lipid peroxidation in experimental myocardial infarction in rats. *J. of Ethnopharmacol.*, 94:155–158.

- Schubert, S.Y.; Lansky, E.P. and Neeman, I. (1999).** Antioxidant and eicosanoid enzyme inhibition properties of pomegranate seed oil and fermented juice flavonoids. *J. Ethnopharmacol.*, 66: 11-7.
- Shahbazizadeh, S.; Khosravi-Darani, K. and Sohrabvandi, S. (2014).** Fortification of Iranian traditional cookies with *Spirulina platensis*. *Annual Res. and Review in Biol.*, 7: 144–154.
- Shalaby, S.M. and Yasin, M.N. (2013).** Quality characteristics of croissant stuffed with imitation processed cheese containing microalgae *Chlorella vulgaris* biomass. *World J. Dairy and Food Sci.*, 8: 58-66.
- Shen, Howard (2008).** Illustrated Pharmacology Memory Cards. *PharMnemonics.Minireview*, 4.
- Skerget, M.; Kotnik, P.; Hadolin, M.; Rizner, H.; Simonic, A. and Knez, M. (2005).** Phenols, proanthocyanidins, flavones and flavonols in some plant materials and their antioxidant activities. *J. Food Chem.*, 89: 191–198.
- Slavica, G.; Božana, O. and Dragana, P. (2007).** Application of sensory evaluation in the croissant quality assurance. *J. Int. Congress Food Technol., Quality and Safety*, 11: 13-15.
- Slavica, G.; Božana, O.; Jasic, M. and Blagojevic, S. (2008).** Effects of food additives on croissant sensory quality improvement. *Conference Paper*, 2: 59-66.
- Statistics of the Ministry of Agriculture (2014).** Total citrus, other fruits and date palms, economic affairs sector, Arab Republic of Egypt, P. 116.
- Steckelings, U.M.; Rettig, R. and Unger, T. (2007).** Angiotensin in the kidney: A Key to understanding hypertension? *Cell Metabolism*, 5: 7-8.
- Steel, R.G.D. and Torrie, J.H. (1980).** Principles and procedures of statistics. A Biometrical Approach. 2nd Edition. McGraw-Hill, New York, USA, pp. 20-90.
- Sun, L.; Zhang, J.; Lu, X.; Zhang, L. and Zhang, Y. (2011).** Evaluation to the antioxidant activity of total flavonoids extract from persimmon (*Diospyros kaki L.*) leaves, *Food and Chem. Toxicol.* 49 :2689-2696.
- Suvarna Kim, S.; Christopher, L. and Bancroft, J.D. (2013).** Bancroft's Theory and Practice of Histological Techniques, 7th Edition. Churchill Livingstone. Elsevier, England.

- Tian, Y.;Zou, B.; Li, C.; Yang, J.;Xu, S. and Hagerman, A. E (2012).** High molecular weight persimmon tannin is a potent antioxidant both ex vivo and in vivo. *J. Food Res. Int.*, 45, 26–30.
- Tuba, O.; Ece, S.; Zeynep, T. andDilara, N. (2015).** Phenolic contents and antioxidant activities of persimmon and red beet jams produced by sucrose impregnation. *Food Sci. and Technol.* 3(1): 1-8.
- Wang, D.; Ozen, C.; Abu-Reidah, I.M.; Chigurupati, S.; Patra, J. K.;Horbanczuk, J.O.; wik, A.J.; Tzvetkov , N.T.; Uhrin, P., andAtanasov,A.G. (2018).** Vascular protective Effects of Pomegranate (*Punicagranatum L.*). *J. Frontiers in Pharmacol.*, 9: 544.
- Yaqub, S.; Farooq, U.; Shafi, A.; Akram, K.; Murtaza, M.A.; Kausar, T. and Siddique, F. (2016).** Chemistry and Functionality of Bioactive Compounds Present in Persimmon. Review Article. *J. Chem.*,Volume 2016.
- Young, D.S. (2001).** Effects of disease on clinical lab tests, 4th ed. *AACC. Clinical Chem.*,48: 682.