

## Role of Non-Contrast MRI in Diagnosis of Pulmonary Embolism

Iman Sherif Ahmad Mohamed<sup>a\*</sup> Laila Ahmad Abdurrahman<sup>a</sup> Ahmed Mohamed Osman<sup>a</sup>

<sup>a</sup> Radiology Department, Faculty of medicine, Ain Shams University, Cairo, Egypt

\*Corresponding author: Mobile: +20 1067813007 E-mail address FEB1991283007@GMAIL.COM.

### ABSTRACT

**Background:** Pulmonary embolism patients with contraindication to radiation exposure and contrast injection. **Objective:** comparative study between the non-contrast Magnetic Resonance Pulmonary Angiography (MR PA) and the Computed Tomography Angiography (CTA) in diagnosis of pulmonary embolism (PE). **Patients and methods:** twenty-one patients were included in our study. All patients were admitted and/or referred to Ain Shams University Hospital Departments, Kasr El Ainy Hospital and private centers confirmed to have pulmonary embolism (PE) by CTA. All patients underwent CTA and non-contrast MR-PA in the same day or within three consecutive days. The radiological examinations were interpreted by two different radiologists. The results were compared and statistically analyzed. **Results:** The mean age of the selected patients was about 49.43years old. 16 cases showed positive PE in both MR-PA and CTA. The 5 cases showed negative results in both. **Conclusion:** The non-contrast MR-PA has a reasonable sensitivity and specificity in the diagnosis of PE especially in major branches. So, it can be used as an alternative to the CTA especially when the CTA and the use of gadolinium are contraindicated.

**Keywords:** Magnetic Resonance Pulmonary Angiography (MRPA); Computed Tomography Angiography (CTA); pulmonary embolism (PE).

### INTRODUCTION

Pulmonary embolism (PE) is a serious condition responsible for significant morbidity and mortality. PE is currently the third leading cause of cardiovascular death worldwide, so it requires prompt diagnosis and treatment to prevent potentially deadly consequences<sup>(1)</sup>

Pulmonary embolism occurs when a blood clot—usually from the leg—travels to the lung and blocks the pulmonary artery or one of its branches<sup>(2)</sup>.

The diagnosis of acute PE is considered a clinical dilemma due to wide spectrum of multiple nonspecific signs and symptoms<sup>(3)</sup>. The D-dimer results are of bad positive laboratory test being positive in other situations rather than PE such as cancer and inflammation<sup>(4)</sup>

CT pulmonary angiography (CTA) is highly sensitive and specific for the diagnosis of PE and has become the imaging method of choice in patients suspected of having PE. The multislice CT offered high spatial and temporal resolution imaging in a short time scan. CTA has the ability to assess the pulmonary tree down to the fifth and to eighth order branches in less than 15 seconds due to high speed<sup>(5)</sup>.

Limitations of CT include exposure to ionizing radiation and iodinated contrast agent, which

carries a risk of allergic reactions and kidney damage in some patients<sup>(6)</sup>

Magnetic resonance-pulmonary angiography (MR-PA) is an attractive new method with the advantage of radiation avoidance and using of much less complicated gadolinium contrast agent which has less nephrogenic effect and less allergic risk<sup>(7)</sup>.

Conventional MRA requires precise bolus timing acquisition with respiration, which may be hampered by a symptomatic PE patient. Another MRA limitation is that it provides a lumen-only imaging; mural PE filling defects will lack conspicuity as these appear as dark signal against the dark adjacent lung<sup>(8)</sup>.

So, alternatively non contrast MRA improves diagnostic accuracy and simplify the acquisition techniques remains an area of clinically important development. The non-contrast MRA produces enhancing signal from the vessel wall, provides high contrast with no need for bolus timing and provides motion-insensitivity to respiration<sup>(9)</sup>

### AIM OF THE WORK

The aim of this work is to emphasize the role of non-contrast MR imaging in diagnosis of acute pulmonary embolism in comparison to CTA and

contrast enhanced MRA as gold standard techniques.

## PATIENTS AND METHODS

### *Study population*

The study included 20 inpatients admitted in different Ain Shams University Hospital Departments, Kasr El Ainy Hospital and private centers with symptoms suggested pulmonary embolism and confirmed by CTPA or contrast enhanced MRPA.

### *Inclusion criteria*

- Patients of any age with clinically evident and confirmed by CTPA or contrast enhanced MRPA to have PE.
- Both sexes were included.
- No age predilection but children were not included (Less than 18 years old).

### *Exclusion criteria*

- Patients known to have contraindication for MRI, e.g. an implanted magnetizable device, pacemakers or claustrophobia.
- Patients with bad general condition.

### **All patients will be subjected to:**

1. Full history taking and clinical examination.
2. CTPA or contrast enhanced MRPA.
3. Non-contrast MRI examination in same day or within 3 consequence days.

### **Patient preparation**

- No specific preparation was needed before MRI examination, except for obtaining an informed written consent from the patient according to the regulations of the ethical committee.

### **Technique of non-contrast MRPA examination**

- MRI study performed by using 1.5 T machine (achieva, philips medical system, Eindhoven, Netherlands) using 8 Channel dedicated phased array cardiac coil.
- Patient position: supine with arms is elevated.
- Examination time is 30-60 Minutes.
- Examination protocol :  
Non-contrast technique and depending on white blood (WB) and black blood (BB) sequences with ECG gating and respiratory gating.

### **Image interpretation**

- The images were transferred to the workstation and PACS system for interpretation by senior staff blindly without knowing the result of the

previously done CTPA or contrast enhanced MRPA.

- The thrombus was diagnosed when a hypointense lesion was seen inside the lumen of the pulmonary artery in the WB sequence causing partial or total occlusion of the lumen.
- The extension of the pulmonary embolism was recorded.

### *Ethical consideration*

The study was done after approval of Ain Shams University ethical committee.

### *Statistical analysis*

- The results of non-contrast MRPA were collected and compared the results of CTPA or contrast enhanced MRPA as regards the presence or absence of pulmonary embolism and the degree of thrombus extension within pulmonary tree. We used IBM SPSS statistics (V. 24.0, IBM Corp., USA, 2016) for data analysis Data were expressed as mean  $\pm$  SD for quantitative parametric measures in addition to both number and percentage for categorized data.

The following tests were done:

1. Chi-square test to study the association between each 2 variables as regards the categorized data. The probability of error at 0.05 was considered significant; while at 0.01 and 0.001 are highly significant.
2. Diagnostic validity test: it includes:
  - a) The diagnostic sensitivity: It is percentage of diseased cases truly diagnosed (TP) among total diseased cases (TP+FP).
  - b) The diagnostic specificity: It is the percentage of non-diseased truly excluded by test (TN) among total non-diseased cases (TN+FP).
  - c) The predictive value for a +ve test: It is the percentage of cases truly diagnosed among total positive cases.
  - d) The predicative value of -ve test: It is the percentage of cases truly negative among total negative cases.
  - e) The efficacy or diagnostic accuracy of the test: It is the percentage of cases truly diseased plus truly non-diseased among total cases.

## RESULTS

- The study was conducted over 21 patients, the mean age of the patient was 49 years ranged between 25 years old and 80 years old with  $\pm$  12.3

SD, There were 3 males in between selected patient representing (14.3%) while the rest 18 were females representing (85.7%).

- Regarding the risk factors to have PE. **Table 1** shows that immobilization was the highest risk factors reached among the selected population followed by patients having cancer anywhere in the body.
- The main presenting symptoms were mainly dyspnea followed by tachypnea & lower limb symptoms as pain and swelling. Tachycardia was the least presenting symptoms for patient presented by PE.
- 16 out of 21 case were diagnosed to have positive pulmonary thrombosis in both contrast enhanced CTPA and non-contrast MR PA with 6 of them show unequal distribution of the thrombus being less in non-contrast MRPA than contrast enhanced CTPA representing , 5 cases diagnosed to be free in both studies as shown in (**table 2**).
- **Table 2** shows that the PE more evident involving the lobar branches as seen in 7 patients and this is similar to the incidence of involvement of the segmental branches in our study population.
- The vessels in each cases were analyzed in both contrast enhanced CTPA and non -contrast MRPA namely main pulmonary trunk, right and left main divisions, lobar divisions as well as segmental

branches. No analysis was done to sub segmental branches.

- We noticed that the results of both non-contrast MRPA and CTPA were the same at the level of pulmonary trunk down to the level of lobar arteries
- The non-contrast MRPA detected thrombosis in 18 pulmonary arteries out of 24 arteries detected by contrast enhanced CTPA. The false negative results (6 vessels) were noted at the level of segmental branches. The per vessel sensitivity non-contrast MRPA reached to about 100% with specificity 100% at the level of the main trunk, right and left main pulmonary branches down to the lobar divisions ,In contrast the overall sensitivity and specificity of non-contrast MRA decreased in thrombus detection in segmental branches as shown in (**Table 3**).

**Table (1):** show the incidence of risk factors among the study population

Risk factors	Number	%
Cancer	6	28.6
Hormonal treatment	4	19.0
Immobilization	7	33.3
OCP	4	19
Pregnancy	0	0.0
Hypercoaguable state	4	19.0
Obesity	3	14.3

**Table (2):** Illustrate the non-contrast MR-PA per vessel result analysis using CTPA as reference modality

Distribution	CT +ve cases	%	MRI +ve cases	%
Main pulmonary trunk	2	9.5	2	9.5
Right main pulmonary artery	4	19	4	19
Left main pulmonary artery	4	19	4	19
Lobar branches	7	33.3	7	33.3
Right upper lobe segmental	1	4.8	0	0.0
Right middle lobe segmental	0	0.0	0	0.0
Right lower lobe segmental	2	9.5	1	4.8
Left upper lobe segmental	0	0.0	0	0.0
Left lingular segmental	1	4.8	0	0.0
Left lower segmental	3	14.3	0	0.0

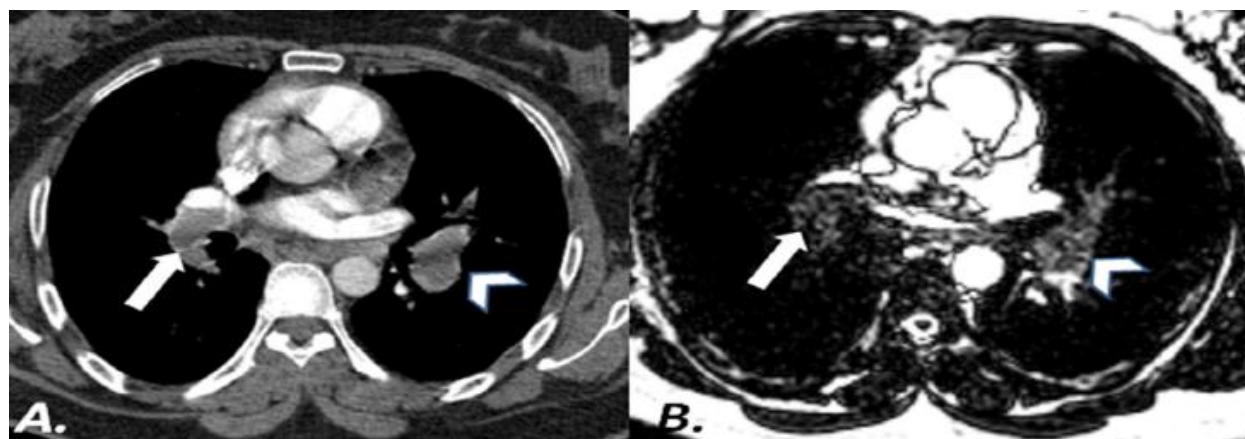
**Table (3):** illustrate the sensitivity and specificity of non-contrast MRPA in PE detection in comparison to CTPA as reference modality

Distribution	sensitivity %	Specificity %	Positive Predictive value %	Negative predictive value %	Efficacy %
Main trunk	100	100	100	100	100
Right main pulmonary artery	100	100	100	100	100
Left main pulmonary artery	100	100	100	100	100
Lobar branches	100	100	100	100	100
Right upper lobe segmental	Not tested	100	Not tested	95.2	100
right middle lobe segmental	Not tested	100	Not tested	100	100
Right lower lobe segmental	50	100	95	100	95.2
Left upper lobe segmental	Not tested	100	Not tested	100	100
Left lingular branches	Not tested	100	Not tested	95.5	100
Left lower lobe segmental	Not tested	100	Not tested	85.7	100

**DISCUSSION**

Our study was designed to evaluate non contrast MR PA for PE detection, with contrast enhanced CT PA as the reference standard. In this study, we tried to evaluate the non-contrast MR-PA technique on 21 patients. The patients were confirmed to have pulmonary embolism by contrast enhanced CT PA or contrast enhanced MRPA, Then non contrast MR-PA was done within the next 2 or 3 days.

MRI study performed by using 1.5 T machine (achieva, philips medical system, Eindhoven, Netherlands) using 8 Channel dedicated phased array cardiac coil and examination protocol was Non-contrast technique and depending on white blood (WB) and black blood (BB) sequences with ECG gating and respiratory gating.

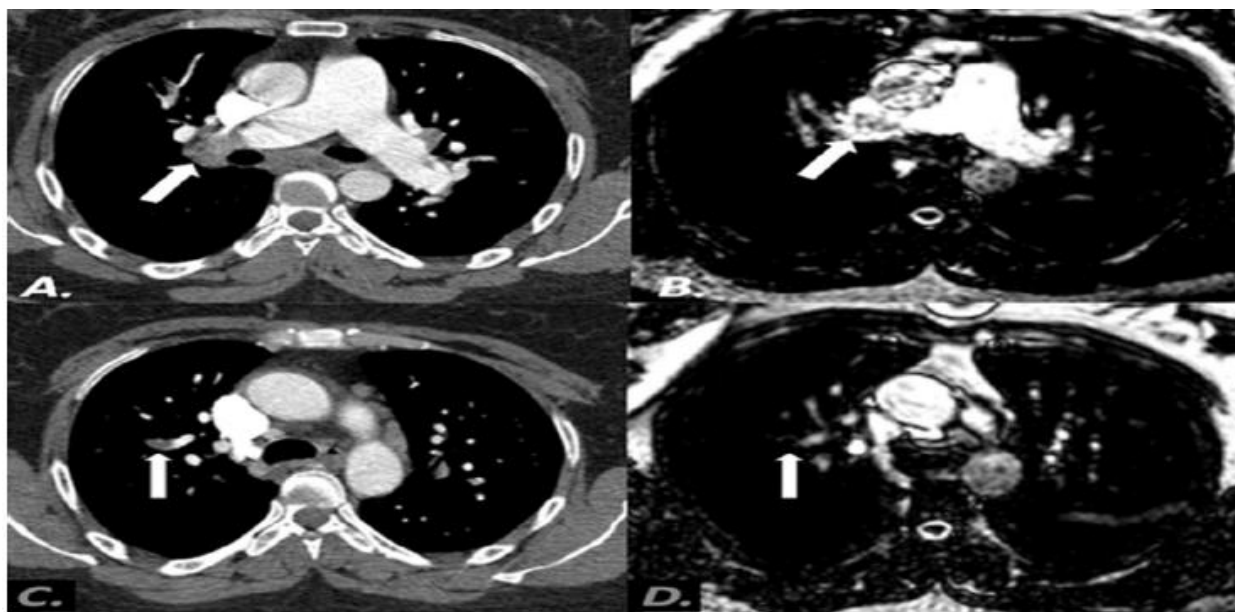


**Fig.1** a Female patient 50 years old presented with dyspnea and chest pain with high probability of PE according to Well’s score. (A)Axial CT image demonstrates pulmonary embolism involving the right (arrow) and left (arrow head) lower lobar divisions. (B) Axial MR-PA-WB taken 24 h later reveals the same result with the pulmonary embolism appearing as hypointense material.

This is similar to **Mudge et al.**<sup>(1)</sup> who used the same technique yet on only 11 patients. **Also Kluge et al.**<sup>(9)</sup> and **Kalb et al.**<sup>(8)</sup> tried to evaluate the non-contrast MRA in diagnosis of PE yet as a part of a larger MRI protocol including the use of gadolinium in other sequences of MRI with the CTA was also the reference tool. In our study the mean age was 49.43 (± 12.343) with more predominance in female patients (85.7 female and 14.3 males). Patient with positive history of immobilization were 7 (33.3 %), cancer patients were 6 (28.6 %) and patient on hormonal treatment were 4(19 %).

Regarding the main presentation 12 of our patients were presented with dyspnea (57.1%), 8 of them were presented with tachypnea (38.1%) and 7 were presented with lower limb symptoms like pain, swelling and confirmed deep venous thrombosis with duplex (33.3%).

The mean of the time interval between the contrast enhanced CTPA and non-contrast MRPA was 44 hours ( $\pm 9.357$ ).



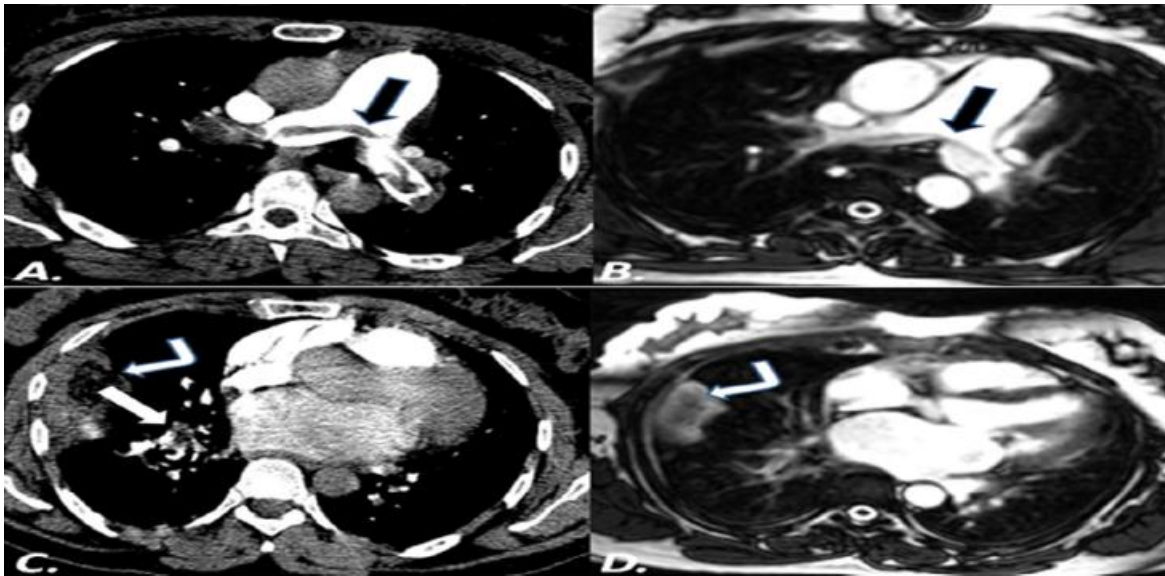
**Fig. 2** A female patient 47 years old presented with dyspnea and chest pain. (A) And (C) Axial CT image demonstrates pulmonary embolism totally occluding the right main pulmonary artery. Also, a totally Occluding one noted involving the segmental branch of the right upper lobe division (arrow). (B) and (D) Axial MR-PA-WB taken 48 h later reveals the right main pulmonary embolism appearing as a hypointense filling defect (arrow) yet partially occluding the lumen. The embolism involving the segmental branch of the right upper lobe division couldn't be demonstrated in MR-PA as in CTA.

Using radiologists' interpretation in our study and per vessel analysis of the contrast enhanced CTPA found that CTPA detected 24 multiple scattered pulmonary thrombi involving multiple scattered arterial branches at the main trunk, right, left main pulmonary trunks, lobar and segmental branches, yet the non-contrast MRPA detected only 18 scattered pulmonary thrombi resulting in false negative results.

Non contrast MRPA failed to identify PE in 6 vessels. These 6 non-detectable thrombi were detected inside the bilateral segmental branches of the lobar divisions.

So both sensitivity and specificity of non-contrast MRPA in detection of PE in the main pulmonary trunk, right, left main trunk and lobar

divisions were 100% which are higher than the results obtained from *Kalb et al.*<sup>(8)</sup> who found that the sensitivity of non-contrast MR PA in detection of PE in lobar branches only the ranging from (40-70%) varying according to which side and which lobar branch is involved being 40% only in the lobar branch of the lingula and 70% at the lower lobar branches, he postulated the low sensitivity at the lobar branch of the lingula to the vascular geometry in this area, in addition to cardiac and respiratory motion effects. Our sensitivity results are also higher than the results obtained from *Mudge et al.*<sup>(1)</sup> who found that the sensitivity of non-contrast MRPA was ranging from (30-100%) being 30% at the upper lobar branches and 100% at the lower lobar branches.



**Fig. 3** A female patient 50 years old presented with dyspnea and chest pain with high probability of PE. (A) and (C) Axial CT images demonstrate saddle pulmonary thrombus involving the major pulmonary trunk (black arrow) and pulmonary embolism involving the segmental branches of the right lower lobe division (white arrow) with subsequent peripheral pulmonary infarction (curved arrow). (B) and (D) Axial MR-PA-WB taken 48 h later reveals the presence of saddle thrombus yet much lesser in extent and size (black arrow) and failed to demonstrate the embolism involving the segmental branches of the right lobe division with still noted pulmonary infarction yet of much smaller in size (curved arrow).

In our study the non-contrast MRPA detected only 1 case of PE at the right lower segmental branches out of 7 cases of segmental branches emboli detected by contrast enhanced CTPA. So we found that the specificity of non-contrast MRPA in detection of PE is around 100% and the sensitivity was tested only at the right lower lobe segmental branches being 50%. As no positive cases of PE detected by MRPA at the other segmental branches. This may be explained due to image resolution at the segmental branches as well as the close of right lower lobe segmental branches to diaphragm making them more reliable to breathing motion artifacts.

The false negative results occurred in our study are owing to the low MR-PA resolution due to thick image acquisition, breathing motion artifacts due to long examination time and the delay time between non-contrast MR PA imaging and contrast enhanced CTA within this period the patient receive PE treatment.

## CONCLUSION

We conclude that the non-contrast MR-PA has a reasonable sensitivity and specificity in the diagnosis of PE especially in major branches. So, it can be used as an alternative to the CTA especially when the CTA and the use of gadolinium are contraindicated.

## REFERENCES

1. Mudge C S, Healey TT, Ataly M K and Pezzullo JA (2013): Feasibility of Detecting Pulmonary Embolism Using Noncontrast MRI. *ISRN, radiology*, **263**: 271- 278.
2. Hosch W, Schlieter M, Ley S, Heye T, Kauczor HU, and Libicher M (2014): Detection of acute pulmonary embolism: feasibility of diagnostic accuracy of MRI using a stepwise protocol. *Emerg Radiol.*, **21**: 151–158.
3. Goldhaber SZ (1998): Pulmonary embolism. *N Engl J Med.*, **339** (2):93–104.
4. Lee AY and Ginsberg JS (1998): Laboratory diagnosis of venous thromboembolism. *Arch Intern Med.*, **169**:2078–2086.
5. Christian F, Stefan OS and Maximilian FR (2008): MRI expands options in lung assessment. *Diagnos Imag.*, **193**:144-149.
6. Smith-Bindman R, Lipson J, Marcus R *et al.* (2010): Radiation dose associated with common computed tomography examinations and the associated lifetime attributable risk of cancer, **45**:321-328.
7. Huisman MV and Klok FA (2012): Magnetic resonance imaging for diagnosis of acute pulmonary embolism: not yet a suitable alternative to CT-PA. *J Thromb Haemost.*, **10**:741–244.
8. Kalb B, Sharma P, Tigges S *et al.* (2012): MR imaging of pulmonary embolism: diagnostic accuracy of contrast-enhanced 3D MR pulmonary angiography, contrast-enhanced low-flip angle 3D GRE, and non-enhanced free-induction FISP sequences. *Radiology*, **263**:320-356