

## MRI Evaluation of Lumbar Disc Degenerative Disease

Noha Mohamed Osman, Fady Mamdouh Fawzy, Hanady Mohammed Lateef

Radiodiagnosis Department, Faculty of Medicine, Ain Shams University, Cairo, Egypt

### INTRODUCTION

**Aim of the work:** lumbar disc degenerative disease is most leading cause of back pain, it is the most common cause of disability at age above 45 years and 2<sup>nd</sup> most common reason for primary care physician visit. Magnetic Resonance Imaging (MRI) is the standard imaging modality for detecting disc pathology due to its advantage of lack of radiation, multi planar imaging capability, excellent spinal soft-tissue contrast and precise localization of intervertebral discs' changes. this study aimed to evaluate the characterization, extent and changes associated with the degenerative lumbar disc disease by Magnetic Resonance Imaging. **Study Design:** cross-sectional and observational study.

**Study Sample:** forty consecutive and clinically examined patients with lower back pain suggestive of lumbar disc disease. **Material and Methods:** 40 patients with age group between 17 and 80 years with low back pain were diagnosed on 1.5 Tesla MRI machine. The following MRI findings were noted: lumbar lordosis preserved or not, ligamentum flavum hypertrophy, facet joint arthrosis or osteophytes formation and Endplate (modic) changes, decreased disc height as compared to the upper and lower vertebral levels and loss of signals, disc bulge at different levels, Disc protrusion and disc extrusion was observed.

**Result:** most of patient showed loss of lumbar lordosis, facet joint arthrosis, ligamentum flavum hypertrophy, Endplate (modic) changes, and osteophytes formation. Disc dehydration which is one of the earliest features of aging and disc degeneration was present in (42%) patients with the most dehydrated disc seen at L4/L5 and L5/S1. Patients with degenerative disc disease had the following disc contour abnormalities. Disc bulges (26.5%) and herniations (10.5%). Herniations were further reported as broad based herniations (9.5%), extrusions (19.0%) and the protrusions (71.4%). The most common site for bulges and herniations was L4/L5 (33.6%) and (57.1%) respectively. The most common complication of bulges and herniations was impingement of exiting nerve roots (40%) and compression of exiting nerve roots and cauda equina (47.6%) respectively.

**Conclusion:** lumbar disc degeneration is the most common cause of low back pain. It is the most common cause of disability at age above 45 years. Plain radiograph can be helpful, but MRI is the standard imaging modality for detecting disc pathology due to its advantage of lack of radiation, multi planar imaging capability, excellent spinal soft-tissue contrast and precise localization of intervertebral discs changes.

**Keywords:** Lumbar Disc, MRI, Degenerative Disease.

### INTRODUCTION

lumbar disc degenerative disease is most leading cause of back pain, it is the most common cause of disability at age above 45 years and 2<sup>nd</sup> most common reason for primary care physician visit<sup>(1)</sup>. Risk factors for causing lumbar disc degenerative disease include advancing age, socioeconomic status, torsional stress, smoking, obesity, heavy lifting, vibration, trauma, immobilization, psychosocial factors, gender, height, hereditary, genetic factors<sup>(2)</sup>. Lumbar disc degenerative disease describe a natural break down of an intervertebral disc of spine, changes occur in lumbar disc degenerative disease and lead to back pain can be osteoarthritis, herniated disc or spinal stenosis. The diagnostic process includes, medical history, physical examination, imaging studies including: X-ray, CT and MRI<sup>(3)</sup>. Radiographs are more often used to exclude other diagnoses rather than directly diagnose degenerative disc disease. Diagnoses that can be more directly excluded with appropriate X-rays include scoliosis,

spondylolisthesis, fractures and gross instability. The actual radiographic findings of lumbar disc disease encompass a range of findings used to infer disc disease. The radiographs are primarily used for assessing bony anatomy and alignment. They do not directly view the discs and soft tissues<sup>(4)</sup>. CT scan is of limited value in the correct diagnosis of degenerative disc disease. Often it can be normal in the face of this disease. A CT scan has little direct value beyond the lumbar radiographs in the direct assessment of degenerative disc disease<sup>(5)</sup>. MRI like CT scanning can be used to evaluate the spinal canal and space available for neural structures, it has additional benefit of allowing the direct assessment of neural structures as well as the disc structure, this direct evaluation not possible by CT scan, loss of water content, proteoglycans and collagens that occur in degenerated intervertebral disc can be visualized on MR images<sup>(6)</sup>. Radiologically, on MR images

a vertebral body end plate signal intensity changes also are used to diagnose degenerative disc disease and spondylolysis of lumbar spine (7).

**PATIENTS AND METHODS**

**Patients:** this was a cross-sectional and observational study. The duration of the study was 2 months from 1<sup>st</sup> April to 31<sup>st</sup> May 2017. A total of 40 patients of lumbar disc degeneration were diagnosed on 1.5 Tesla MRI machine. All the observations were done by three radiologists (Professor, Associate professor and resident). Patients between 17 to 80 y of the age with low back pain were included in this study after obtaining a verbal consent. Patients with the history of trauma, prior surgery, spinal infections, active malignancy, pregnancy, cervical spine involvement, age<17 y and > 80 y were excluded from the study. In this study 40 patients were enrolled and their demographic findings were noted. **MRI Study:** sagittal T1-weighted, sagittal T2-weighted and axial T2 - weighted sequences were obtained by standard technique in all the cases. The diagnostic information obtained from the sagittalT2-weighted sequence was first recorded. The final report was subsequently compiled by interpretation of all 3 sequences. Comparison was therefore made between the diagnostic information obtained by the full protocol and the proposed shortened protocol of sagittal T2-weighted images only. All scans were interpreted by one consultant radiologist. The presence of disc prolapse was assessed at each of 5 intervertebral levels, ie L1/2, L2/3, L3/4,L4/5, L5/S1. In addition, the following items were assessed as present or absent - loss of disc height, loss of disc hydration, annular disc tears, nerve root encroachment, and the cal sac indentation. Patients were imaged using a 1.5 tesla Philips Intera system. The sagittal T1-weighted sequence was performed using TR400ms, TE 11Ims, matrix 512 x384, slice thickness 4.4 mm, interslice gap 0.4 mm, field of view 325 mm, acquisition time 4 min 24 sec. The sagittal T2-weighted sequence was performed using TR 3500 ms, TE 120 ms, matrix 512 x 384,slice thickness 4.4 mm, interslice gap 0.4 mm, field of view 325 mm, acquisition time 3min 54 sec. The axial T2-weighted sequence was performed using TR 2500 ms, TE 120 ms, matrix 512 x 384, slice thickness 4.0 mm, interslice gap 0.4 mm, field of view 225 mm, acquisition time 4 min 52 sec.

The following MRI findings were noted: lumbar lordosis preserved or not, ligamentum flavum hypertrophy, facet joint arthrosis or osteophytes formation and Endplate (modic)

changes [Table-1], decreased disc height as compared to the upper and lower vertebral levels and loss of signals[Table-2],Disc bulge at different levels[Table-3],Disc herniations by it is three types at different levels [Table 4].

The study was approved by the Ethics Board of Ain Shams University.

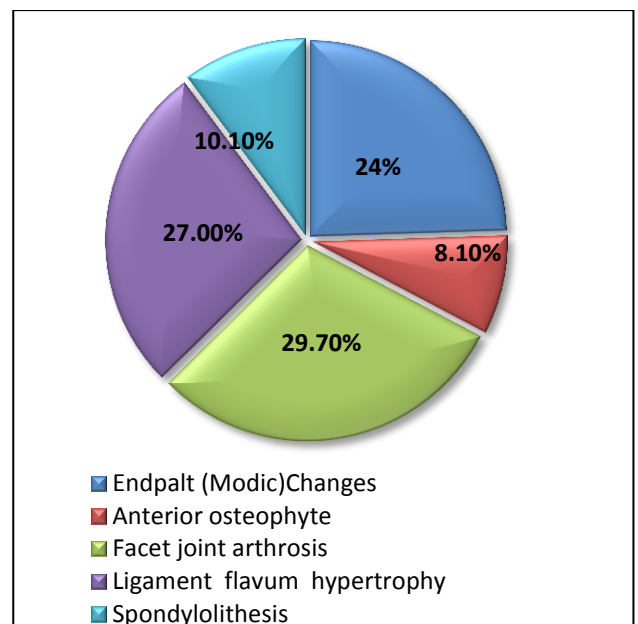
**RESULTS**

**The Most Common MRI Pattern in Patients with Low Back Pain**

The common lumbar spine degenerative findings in patients with low back pain were endplate (modic) changes 9 (24.3%), anterior osteophytes 3 (8.1%), facet joint arthrosis 11 (29.7%), ligamentum flavum hypertrophy 10 (27.0%) and spondylolisthesis 4 (10.8%) were shown in **Table 1** below. Lumbar disc degeneration (LDD) was common (92%) in LBP patients studied. Table 2 below illustrates that disc dehydration which is one of the earliest features of aging and disc degeneration was present in 84 (42%) patients with the most dehydrated disc seen at L4/L5 and L5/S1 21 (25.0%).

**Table 1:** lumbar spine degenerative findings

Variable	Freq. (%)
Lumbar Spine Degenerative Disease	37(92%)
Endpalt (Modic)Changes	9(24.3)
Anterior osteophyte	3(8.1)
Facet joint arthrosis	11(29.7)
Ligament flavum hypertrophy	10(27.0)
Spondylolithesis	4(10.8)



**Fig. 1:** a chart showing percentage of lumbar disc degenerative disease

**Table 2:** Disc hydration

Variable	Freq. (%)
Disc dehydration	84(42%)
<b>Sit of lesion</b>	
L1-L2	13(15.4)
L2-L3	13(15.4)
L3-L4	16(19.0)
L4-L5	21(25.0)
L5-S1	21(25.0)

**The common disc contour abnormalities in patients with low back pain:**

Patients with degenerative disc disease had the following disk contour abnormalities: disc bulges 53(26.5%) and herniations 21 (10.5%). Herniations were further reported as broad based herniations 2 (9.5%), extrusions 4 (19.0%) and the protrusions 15 (71.4%).

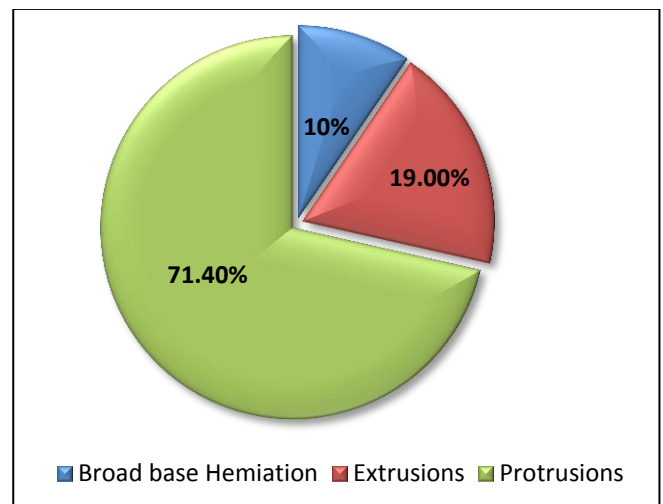
The most common site for bulges and herniations was L4/L5 18 (33.6%) and 12 (57.1%) respectively. The most common complication of bulges and herniations was impingement of exiting nerve roots 18 (40%) and compression of exiting nerve roots and cauda equina 10 (47.6%) respectively as shown in Table 3 and 4 overleaf.

**Table 3:** disc bulges

Variable	Freq(%)
Bulges	53 (26.5%)
<b>Site of Lesion</b>	
L1 -2	5(9.4)
L2-3	3(5.6)
L3-4	11(20.7)
L4-5	26(49.0)
L5-S1	18(33.9)
<b>Complications</b>	<b>45</b>
Impingement of exiting nerve root	18(40.0)
Impingement on nerves and cauda equine	1(2.2)
Mild thecal sac indentation	13(28.8)
Spinal canal stenosis	1(2.2)
Compression of exiting nerve root	12(26.6)

**Table 4:** disc herniation

Variable	Freq. (%)
Type of Herniation	N=21 (10.5%)
Broad Base Herniation	2(9.5)
Extrusions	4 (19.0)
Protrusions	15 (71.4)
<b>Site of Lesion</b>	
L1-2	1(4.7)
L2-3	1 (4.7)
L3-4	3 (14.2)
L4-5	12 (57.1)
L5-S1	4 (19.0)
<b>Complications</b>	<b>21</b>
Impingement of nerve root	1 (4.7)
Impingement on nerves and cauda equine	10 (47.6)
Mild thecal sac indentation	5 (23.8)
Spinal canal stenosis	1 (4.7)
Compression of exiting nerve root	4 (19.0)



**Fig. 2:** a chart showing percentage of each type of lumbar disc herniations.

**DISCUSSION**

The current study showed different MRI patterns of lumbar spine disease patients with LBP. A review of 40 MRIs of patients presenting with LBP in this study established lumbar degenerative disc disease (92.5%) as the most common followed by lumbar spondylosis 42%. A retrospective **Verma *et al***<sup>(8)</sup> study of 232 patients showed that the incidence of lumbar disc degeneration be more frequent at 79.3%.<sup>23</sup> According to the study of **Uduma *et al.***<sup>(9)</sup>

48 patients yielded 33.3% disc hernia, 37.5% spondylosis. This study was almost similar in

trying to address the prevalence of different disease patterns although the findings differed greatly possibly due to the small number of patients. **Mboka**<sup>(10)</sup> found that in 165 patients 83% of them had degenerative disc disease. This study also excluded patients with inflammatory conditions, infections and neoplasms. Most of the findings in all the studies mentioned focus only on degenerative disc disease. This study serves to reinforce the fact that MRI has a high sensitivity for detection of lumbar spine degenerative disease.

The most common MRI pattern in patients with low back pain. In the present study, the majority of patients with LBP had lumbar degenerative disc disease. **Yong et al.**<sup>(11)</sup> in their study concluded that the most frequent finding in 91.2% of patients with LBP was intervertebral disc degeneration. In Tanzania, a study carried out by **Mboka et al.** found 83% to have degenerative disc disease. **Samartzis** study<sup>(13)</sup> yielded 72.7% with degenerative disc disease. A study of **West et al.** in Jamaica was dominated by degenerative disc disease in 78.2% subjects. These findings may be comparable to the findings in the current study. A retrospective study was done by **Iurhe et al.**<sup>(12)</sup> yielded 37% disc degeneration. These results are much lower than the current study results (80%). These different global studies revealed a predominance of degenerative disc disease in both developed and developing countries. This is a fact reinforced in our study even though a study have found 35% of asymptomatic individuals to have degenerative disc disease<sup>(14)</sup>.

The common disc contour abnormalities in patients with low back pain.

Different disc contour abnormalities are resulted from lumbar disc degeneration. Many physicians refer to any or all disc abnormalities as herniated or prolapsed disk which may not put the abnormality seen on the imaging study in proper perspective and may be misleading. In the study of **Helm et al.**<sup>(15)</sup> disc morphology was assessed and graded using a published classification scheme of normal, bulge and herniation; broad based protrusion, focal protrusion and extrusion. Their findings reported 65.41% disc bulges and 23.24% herniations. Herniations were further reported as 62.79% broad based herniations, 6.98% extrusions and 30.23% protrusions. There was a substantial difference between the disc contour abnormalities reported and those reported in other studies. **Ongeti et al.** reported only prolapsed intervertebral discs<sup>(16)</sup>. Biluts 70.1%

disc prolapsed, further classifying them into 18.5% bulges<sup>(11)</sup>. This study had less bulges than our study. In Malaysia **Yong et al.** reported 40.4% bulges, 50% protrusions and 19.4% extrusions<sup>(11)</sup>. A study reported less bulges and more protrusions and extrusions than our study<sup>(8)</sup> a study reported 92% bulges, 74% protrusion and 28% extrusion<sup>(8)</sup>. Another particular study showed more bulges, protrusions and extrusions than our study<sup>(10)</sup>.

The later study reported 39% bulges, 63% herniations, 98% protrusion and 2% extrusion. This Tanzanian study reported less bulges and extrusions at the same time having a high number of protrusions and herniations.<sup>(12)</sup> reported 3.5% bulges, 59.7% multiple disc herniation, 44.7% protrusions and extrusions 24.7%.<sup>29</sup> This study reported less bulges, protrusions, extrusions and more herniations than our study. **Younis et al.** reported bulges 78% and herniations 25%<sup>(17)</sup>. This particular study reported more bulges than herniations, these findings are similar to our study. From these findings, bulges, herniations, protrusions and extrusions are common in patients with chronic LBP. Radiologists and spine surgeons need to use similar terminology so as to be able to determine clinically significant lesions.

The most common site of lumbar disc degeneration in patients with low back pain. Traditionally, disc degeneration is common in the areas with the heaviest mechanical stresses such as the lower lumbar region. A fact verified in this study, where the findings reported that the majority of the participants, who had bulges (49.0%), and herniation (57.1%) had lesions commonly appearing at L4/L5 on other hand, lesions at L5-S1 were seen in 33.6% and 19.0% patients with bulges and herniations respectively. These findings are comparable but with a higher incidence than those found in other African studies where L4/L5 lesions were the commonest at 42.3%, 54.5% respectively. These were then followed by L5/S1 lesions at 25.5% and 25% respectively<sup>(18)</sup>.

The common complications of lumbar disc degeneration

Individuals with lumbar disc degeneration (LDD) are predisposed to the development of common potential complications such as neural compression, chemical irritation of nerves, osseous abnormalities, segmental instability, spinal stenosis and pain<sup>(13)</sup>. In the study, the most common complication of bulges and herniations

were reported as an impingement of exiting nerve roots (40%) and compression of exiting nerve roots and cauda equine nerve roots (47.6%) respectively. Yong *et al.* reported 42.1% which was slightly lower, whereas **Mboka *et al.***<sup>(10)</sup> reported 77% nerve root compression which was comparable to the findings in this study.

## CONCLUSION

Lumbar disc degeneration is the most common cause of low back pain. Men are more frequently affected to the disc degeneration than women. Multiple levels of the disc involvement are seen per person. Annular disc tear, disc herniation, disc extrusion, narrowing of spinal canal, narrowing of lateral recess, compression of neural foramen, facetar arthropathy and ligamentum flavum thickening is common at the L4 –L5 disc level. L1- L2 disc involvement and spondylolisthesis are less common. The sequelae of disc degeneration are among leading causes of functional incapacity in both sexes and are a common source of chronic disability in working years. Disc degeneration involves structural disruption and cell-mediated changes in composition. Mechanical, traumatic, nutritional, and genetic factors all may play role in cascade of disc degeneration, albeit to variable degree in different individuals. The presence of degenerative change is by no means an indicator of symptoms, and there is very high prevalence in asymptomatic individuals. The etiology of pain as the symptom of degenerative disease is complex and appears to be combination of mechanical deformation and the presence of inflammatory mediators. The role of imaging is to provide accurate morphologic information and influence therapeutic decision making. Lower back pain secondary to degenerative disc disease is a condition that affects young to middle-aged persons with peak incidence at approximately 40 years. To evaluate the characterization, extent, and changes associated with degenerative lumbar disc disease by Magnetic Resonance Imaging cross sectional study. A total of 40 patients of lumbar disc degeneration with age group between 17 to 80 years diagnosed and studied on 1.5 Tesla Magnetic Resonance Imaging machine. MRI findings like lumbar lordosis, Schmorls nodes, decreased disc height, disc annular tear, disc herniation, disc protrusion and disc extrusion were observed. Narrowing of spinal canal, lateral recess and neural foramen with compression of nerve root observed. Ligamentum flavum thickening and facetar arthropathy was observed. Males were more commonly affected in

degenerative spinal disease and most of patients show loss of lordosis. Decreased disc height was common at L5-S1 level. More than one disc involvement was seen per person. L4-L5 disc was the most commonly involved. Annular disc tear, disc herniation, disc extrusion, narrowing of spinal canal, narrowing of lateral recess, compression of neural foramen, ligamentum flavum thickening and facetar arthropathy was common at L4-L5 disc level.

## REFERENCES

1. **Lehtola V, Luomajoki H, Leinonen V *et al.*( 2012):** Efficacy of movement control exercises versus general exercises on recurrent sub-acute non-specific low back pain in sub- group of patients with movement control dysfunction. Protocol of a randomized controlled trial. *BMC Musculoskeletal Disord.*,7(4):13-55.
2. **Saleem S, Aslam H, Rehmani M *et al.*(2013):** Lumbar disc degenerative disease: disc degeneration symptoms and magnetic resonance image findings. *Asian Spine J.*, 7(4):322-334.
3. **Bhalla A, Schoenfeld AJ, George J *et al.*(2016):** The influence of subgroup diagnosis on radiographic and clinical outcomes after lumbar fusion for degenerative disc disorders revisited: a systematic review of the literature. *Spine J.*, 17(3): 143-149.
4. **Livshits G, Ermakov S, Popham M *et al.*(2010):** Evidence that bone mineral density plays a role in degenerative disc disease: the UK twin spine study. *Annals of the Rheumatic Diseases*, 69 (12): 2102-2106.
5. **Hasz M (2012):** Diagnostic testing for degenerative disc disease: *Advances in Orthopedics*,13(4): 7-11.
6. **Maurer MH, Schreiter N, de Bucourt M *et al.*(2012):** Cost comparison of nerve root infiltration of the lumbar spine under MRI and CT guidance. *Eur. Radiol.*, 23(4): 1487-1494.
7. **Yu L, Qian W, Yin G, Ren Y and Hu Z(2012):** MRI assessment of lumbar intervertebral disc degeneration with lumbar degenerative disease using the Pfirrmann grading Systems. *PLOS.*,8(3): 215-233.
8. **Verma SR, Gupta PK, Munshi A *et al.*(2011):** A retrospective analysis of magnetic resonance imaging findings in 20-40 year old patients with low back pain: experience at a semi-urban tertiary health care center in Northern India. *The Intern. Journal of Spine Surgery*,6(4): 1937-1947.
9. **Uduma FU, Ongolo P, Assam G *et al.*(2011):** Evaluation of pattern of magnetic resonance images of lumbo-sacral spine in cameroon- a pioneer study. *Global Journals*, 11 (2): 33-41.
10. **Mboka J (2011):** Pattern of spine degenerative disease among patients referred for lumbar magnetic resonance imaging at Muhimbili National Hospital Dar el Salam Tanzania. *J. Muhimbili University of Health and Allied Sciences*,7(2):35-45.
11. **Yong PY, Alias NAA and Shuaib IL(2003):** Correlation of clinical presentation, radiography and MRI for low back pain- A preliminary survey. *J. H.K. Coll. Radiol.*,4 (6): 144-151.

## MRI Evaluation of Lumbar Disc Degenerative Disease

- 12. Irurhe NK, Adekola OO, Qudri AR *et al.*(2012):**  
The magnetic resonance imaging scans in adult Nigerians with low back pain. *World Journal of Medical Sciences*, 7(4): 204-209.
- 13. Samartzis D, Karpinnen J, Chan D *et al.*(2012):**  
The association of lumbar disc degeneration on magnetic resonance imaging with body mass index, in overweight and obese adults. *Arthritis Rheum.*, 64 (5): 1488-1496.
- 14. Urban JPG and Roberts S (2003):** Degeneration of the intervertebral disc. *Arthritis Res. Ther.*,5 (3): 125-135.
- 15. Helms CA, Major NM, and Anderson MW (2009):** Musculoskeletal MRI. *American Journal of Roentgenology*,8(5):124-130.
- 16. Ongeti KW, Ogeng'o J, Saidi H *et al.*(2012):**  
Prolapsed intervertebral disc in an African population: Kenyan experience. *East African Orthopedic Journal*,16(6):40-48
- 17. Younis F, Shahzad R and Rasool F (2011):**  
Correlation of magnetic resonance patterns of lumbar disc disease with clinical symptomatology of patients. *Annals of King Edward Medical University*, 17(1):122-130.
- 18. Biluts H and Munie T(2012):** Review of lumbar disc diseases at Tikur Anbessa Hospital. *Ethiop. Med. J.*, 50 (1): 57-65.