

Management of Charcot Arthropathy of ankle and foot

M.A.Elmorsy¹, E.M.Mohamady¹ and A.M.Abdelsalam²

¹Orthopedics surgery Dept., Faculty of Medicine, Benha Univ., Egypt

²M.B.BCH, Alazhar faculty of medicine, Egypt

E-Mail:ahmed2356@gmail.com

1.Introduction

Charcot Arthropathy is a relatively painless, progressive, and degenerative arthropathy of single or multiple joints, caused by underlying neurological deficits, with peripheral joints most commonly affected [1].

Charcot Arthropathy of the foot and ankle is a syndrome consisting of fractures and dislocations in patients with peripheral neuropathy [2]

In Chronic Charcot Arthropathy the temperature elevation and redness gradually subside, while permanent deformities may develop, typically, the latter include arch collapse with rocker bottom deformity and medial convexity.

As a result, pressures during standing and walking are redistributed so that areas of deformity develop high pressure and become prone to ulceration. Finally, ulcerated areas may become infected and infection may spread to the bone, leading to osteomyelitis [3]

Investigations of Charcot Arthropathy including laboratory studies, that can be used for diagnosis of the etiology, differential diagnosis, and radiological studies includes plain radiographic imaging which helps to identify fragmentation, fracture, destruction and joint dislocation [5].

Treatment of Charcot Arthropathy is mainly nonoperative. Treatment consists of 2 phases, an acute phase and a postacute phase.

Management of the acute phase includes immobilization and reduction of stress, and post-acute phase treated surgically [4].

2. Etiology and pathogenesis

[1]The etiology

Charcot Arthropathy is an extremely destructive joint disorder affecting a single or multiple joints that is almost uniformly initiated by even minor trauma to an insensate limb or region, the individuals acutely affected usually presenting by typical signs of inflammation, [edema, redness, hotness, etc] but generally without the protective sensation of pain.

Fractures, dislocations, and instability of multiple joints within the foot or ankle are commonly seen [5].

The process can potentially result in collapsing with severe deformity of the foot, that frequently results in gait abnormalities and ulcers formation [6].

Now the diabetes is known as the first and the most presented cause of Neuropathic Arthropathy [7].

In the case of the diabetic foot, the main predisposing factors are the presence of diabetes itself, combined with neuropathy and with preservation of the peripheral circulation [7].

[2] Pathogenesis

The mechanisms for the development of Charcot Arthropathy are not completely understood however, two theories that address the causes of Charcot Arthropathy have been described a neurovascular theory [French theory] and a neurotraumatic theory [German theory], both mechanisms likely contribute to development of Charcot Arthropathy [8].

The neurovascular theory is based on the increasing in blood flow to the limb which result from dilatation of the blood vessels because of sympathetic denervation, he loss of vasomotor control allows blood vessels to dilate, that leads to increasing the peripheral blood flow, the increased blood flow increases the arterio-venous shunting, which causes hyperemia, demineralization and bone resorption, excessive Osteoclastic activity without a concomitant increase in Osteoblastic function has also been documented in Charcot foot [9].

The neurotraumatic theory is based on the patients experiencing an overuse injury because of an absence of protective sensation, either acute trauma or repetitive minor traumas can initiate Charcot Arthropathy, absence of protective sensation limits the body's protective mechanisms such as shifting body weight, limiting activity, and muscle guarding [10].

It is generally accepted that trauma superimposed on a well perfused but severely neuropathic extremity can precipitate the development of an acute Charcot foot [11].

The precise role of trauma in the pathogenesis of Charcot Arthropathy is not clear, Charcot Arthropathy is recognized to progress very rapidly in humans after trauma [12]

A. Bone pathology

There is an association between diabetes mellitus and osteoporosis that could contribute to the development of Charcot Arthropathy [13].

Patients with Charcot Arthropathy were shown to have reduced bone density in the lower limbs in comparison to neuropathic control subjects [14].

Studies using bone markers to assess bone formation and resorption have indicated that there is an increase in osteoclastic activity in comparison with osteoblastic activity in acute and chronic Charcot Arthropathy, This is thought to lead to osteopenia, which can then predispose to fracture even with minimal trauma In addition, the loss of peripheral pain sensation means that protective mechanisms are lost and joint immobilisation, which is essential for proper healing of the bone injury, might not occur. This can result in non-union of fractures and pseudo-arthritis, often with the formation of osteophytes The end result is a gross

disorganisation of bone architecture in established Charcot Arthropathy [15].

B. Atypical neuropathy

It is not entirely clear why only a small proportion of patients with neuropathy develop CN. Trauma is likely to play an important part but some authorities have suggested that people with CN have a different variant of neuropathy from the usual distal chronic sensorimotor neuropathy. In one study, patients with CN were found to have preserved perception of warmth, but had complete loss of peripheral cold perception. This contrasted with patients with foot ulceration, who had severe impairment of both warm and cold sensory thresholds. Light touch perception was also preserved in CN but vibration perception at the big toe and cardiovascular autonomic function tests were abnormal in both groups.

In [1995], there was no difference in sensory impairment between the two groups but CN patients showed evidence of reduced bone density in their lower limbs with a relatively preserved bone density in the spine [14].

C. Increased plantar pressure

Plantar pressures were found to be higher in patients who developed acute CN compared with patients with distal sensorimotor neuropathy or neuropathic ulceration [16].

3. Pathology

The well-respected neurotraumatic and neurovascular theories have been depended on for a long time in order to clarify the pathogenesis of Charcot Arthropathy.

The contribution of each of the theories to pathogenesis of Charcot foot is broadly detailed and discussed as follows: [17].

A. Inflammation

The physiological balance between the pro and anti-inflammatory cytokines that restrains the inflammatory response to a necessary extent is compromised in Charcot patients. Baumhauer's findings support this phenomenon based on the fact that in a Charcot patient the modulation of immune system is disturbed in countenance of proinflammatory cytokines [18].

Thus, NF- κ B pathway is implicated in the excessive osteoclastic activity in diabetic Charcot Arthropathy [19].

IGF-1 is a mediator of vasodilatation, and bisphosphonate's reducing effect over IGF-1 could have a beneficial contribution to restrain proceeding inflammation [20].

B. Neuropeptides

The essential role of neuropeptides in the bone metabolism is thoroughly studied by Offley et al. [21].

They reported that capsaicin-induced depletion of neuropeptides such as Substance P [SP] and Calcitonin Gene-Related Peptide [CGRP] in unmyelinated sensory

neurons of adult rats resulted in an increased bone loss and fragility. The authors suggested that this effect could be reversed by daily injections of CGRP [21].

Nitric oxide [NO] is a free radical gas that functions as a secondary messenger molecule in many biological pathways. Several studies suggest that NO has a reciprocal effect on the modulation of bone metabolism [22].

Nitric oxide's inhibitory effect over the osteoclasts is demonstrated in animal studies, observing NO being able to induce apoptosis of preosteoclasts and decrease the resorptive action of the mature osteoclasts in mice [23].

Sympathetic innervation of the bone and bone marrow is demonstrated by monitoring of tyrosine hydroxylase activity, the rate-limiting enzyme of catecholamine synthesis [21].

C. Microvascular structure and bone turnover

When Charcot first described the neuropathic arthropathy, he implicated the increase in bone perfusion secondary to the sympathetic denervation as responsible for bone resorption [17].

Jeffcoate improves this hypothesis further by suggesting that Charcot Arthropathy requires the coexistence of a dense neuropathy with a relatively intact peripheral circulation [24].

D. Hyperglycemia

The expression of RANKL is proven to be closely associated with metabolic consequences of the diabetes. Increased blood sugar potentiates free radical formation, hyperlipidemia and advanced glycation end-products [AGEs], triggering the RANK/RANKL cytokine system [18].

Moreover, since collagen is a structural component of the bone, age-related modifications of collagen, may impair the mechanical properties of bone itself, predisposing it to fractures and dislocations [23].

(E) Genetics

A strong association with Charcot Arthropathy and the polymorphisms of those alleles were also demonstrated. Recently, Korzon-Burakowska et al. supported this association in their study conducted in the Polish population [25].

4. Investigations

The diagnosis of active Charcot foot is primarily depended on history and clinical findings, but it should be confirmed by investigation which helps to distinguish the condition from others that cause pain and swelling of the foot and ankle.

A. Laboratory investigations

Laboratory studies, it can be helpful in diagnosis of the etiology and for differential diagnosis.

(1) Glycosylated hemoglobin [HbA1C] indicates the level of hyperglycemic control in diabetes.

- (2) Elevation of HbA1C indicates poor hyperglycemic control.
- (3) Hyperglycemia can cause nonenzymatic collagen glycosylation, which can lead to laxity in ligaments and unstable joints.
- (4) Levels of alkaline phosphates, calcium, phosphorus, and parathyroid hormone [PTH], can help the physician to identify bone diseases, such as Paget disease, hypercalcemia may be indication for cancer or metastases.
- (5) Vit B-12/folate deficiency could suggest the etiology of peripheral neuropathy; this deficiency also could suggest chronic alcoholism.
- (6) Findings of liver function tests/coagulation studies may suggest chronic alcoholism. [32]

Rapid plasma reagin [RPR]/fluorescent treponemal antibody –absorption [FTA-ABS] tests aid in the diagnosis of syphilis, Elevated levels of creatine and of

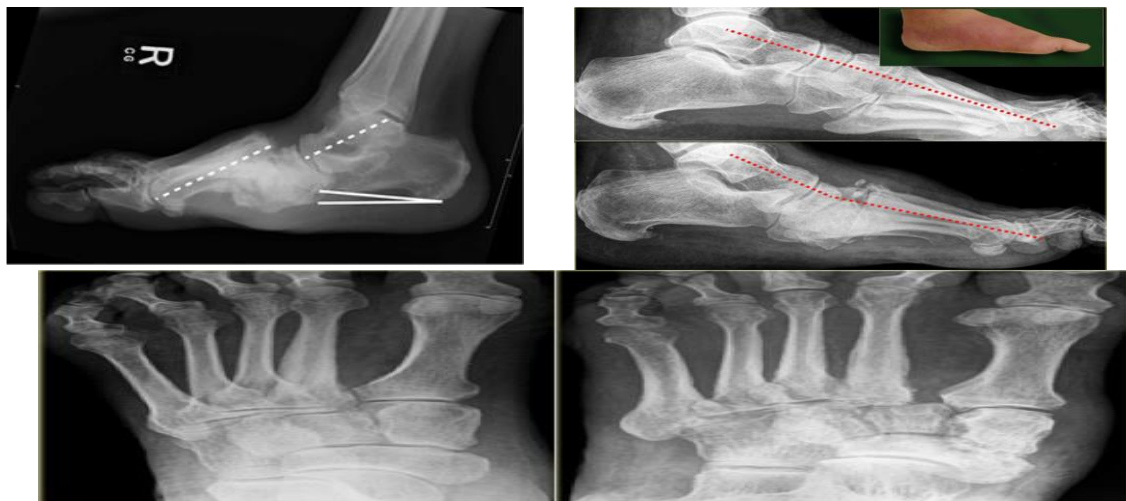
blood urea, nitrogen [BUN] could suggest renal disease, whereas an elevation in glucose level could suggest diabetes.

B. Radiological Investigations plain radiography

Experts agree with that radiographs are important as the first examination in virtually all settings, however a negative result obviously should not offer any confidence regarding lack of disease.

Here a radiograph of a patient with diabetic neuropathy and a red hot foot. In the acute stage, the radiographs are normal and may not exclude the diagnosis of acute Charcot neuro-osteoarthropathy.

Within 4 months there is progressive decrease of calcaneal inclination with equinus deformity at the ankle. There is destruction of the tarsometatarsal joint with the typical rocker-bottom deformity. Bony debris is seen on the dorsal aspect of the foot.



Ultrasonography

Ultrasonography may be helpful investigation in identification of local collection of pus when infection occurs and may guide aspiration for analysis; however, it provides no further information regarding the integrity of underlying bone, and fluid collections may occur with the production of sequestra in Charcot Arthropathy [32].

Computed topography[CT]

[CT] scanning can detect the presence of sequestra, cortical destruction, periosteal reaction and intraosseous gas which might not be detected on MR imaging [33].

Positron emission tomography [PET]

Can be used in the evaluation of Charcot Arthropathy patients with metal implants that would compromise the accuracy of MRI. Moreover, PET was also shown to distinguish between osteomyelitis and CN [32].

Bone scan

It is a very sensitive but nondiscriminatory test. A four phased bone scan [with a delayed image at 24 hours] is more specific to detect woven bone but does

not distinguish Charcot Arthropathy from severe degenerative changes, fractures and tumors [33].

111 In-labelled leucocytes scan

This can be differentiated by complementary marrow scanning using Tc-nanocolloid alongside a 111In-labelled leucocytes scan [32].

Lumbar puncture procedure

Can be used if the RPR test is positive. An FTA-ABS test is ordered if tertiary syphilis/tabs dorsalis is suggested. [34].

Bone probe

A blunt, sterile surgical probe is used. It is necessary to probe down to the bone to rule out osteomyelitis [32].

Joint aspiration

Inflammatory joint fluid containing CPPD crystals has been observed in some patient. Such fluid without the presence CPPD crystals should raise the possibility of sepsis as the synovial fluid is clear, straw colored, and viscous in charcot with normal WBC count and normal ESR. [32].

Synovial biopsy

Small fragments of bone and cartilage debris are embedded in the synovium because of joint destruction. Some state that this is pathognomonic, while others state that it is highly suggestive of Charcot Arthropathy [32].

MRI

MRI has a high sensitivity and specificity for osteomyelitis and has become the test of choice for evaluation of the complicated foot in diabetic patients [35].

Labeled white blood cell scanning [using ^{111}In or $^{99\text{m}}\text{Tc}$] provides improved specificity for infection in the setting of neuropathic bone changes but it can be difficult to differentiate soft tissue from bone [36].

Classification

Numerous classification systems based on clinical, radiographic, and anatomic pathology describe Charcot Arthropathy.

A. Saunders and mrdjencovich

The most commonly used and have the added benefit of prediction of the outcome and prognosis, it based on the location of the arthropathy, this system classifies Charcot arthropathy into four patterns:

Pattern 1, involves the forefoot,

Pattern 2, involves the tarsometatarsal joint,

Pattern 3, involves the cuneonavicular, talonavicular, and calcaneocuboid articulations,

Pattern 4, involves the talocrural, or ankle, joint,

Pattern 5 involves the posterior calcaneus [26].

B. Eichenholtz classification

Neuroarthropathic changes of the foot and ankle were first classified by Eichenholtz in 1966 [27].

C. Sanders and frykberg classification

Several authors have developed anatomically based classification systems by observing the patterns of involvement in the foot and ankle. Sanders and Frykberg classified Charcot Arthropathy anatomically into patterns of joint involvement. The authors divided the foot and ankle into five patterns of destruction [28].

D. The brodsky and rouse classification

Similarly, Brodsky and Rouse described four distinct anatomical areas of the foot and ankle that are most commonly affected by Charcot arthropathy [29].

Schon Classifies Midfoot Deformities

Schon et al [30] developed a system for categorizing acquired midtarsus deformities.

A Five-Stage classification

Sella and Barrette developed a five-stage classification scheme for medial column neuropathic joint disease based radiographs, clinical findings and bone scans. This system divides the medial column of the Charcot foot into five clinical stages [31].

Rogers and bevilacqua classification

Rogers and Bevilacqua at 2008, proposed a new classification scheme that considers the complications associated with the Charcot joint, which may be a prognostic tool for amputation. This is a two-axis system with the X-axis marking the anatomy affected including

1. Forefoot.
2. Midfoot.
3. Rearfoot/Ankle.

The Y-axis describes how complicated the Charcot joint is.

- A is acute Charcot with no deformity.
- B is Charcot foot with deformity.
- C is Charcot foot with deformity and ulceration.
- D includes osteomyelitis.

It makes clinical sense that as one moves across the X-axis or down the Y-axis the Charcot foot becomes "more complicated" and, thus, is at greater risk for amputation.

5. Treatment

Treatment of Charcot Arthropathy depends on many factors including clinical stage, location of involvement, degree of deformity and patient comorbidities. The mainstay of treatment is off-loading, while surgery is usually reserved for chronic cases with joint instability or severe deformity [37].

Modalities of treatment

A. Non-Operative Treatment including

- I. Total Contact Cast [TCC]
- II. Prefabricated Pneumatic Walking Brace [PPWB]
- III. Charcot Restraint Orthotic Walker [CROW]
- IV. Antiresorptive Drugs
- V. Electrical Bone Stimulators

B. Operative Treatment including

- I. Debridement of Ulcer.
- II. Osteotomy.
- III. Arthrodesis with Internal Fixation.
- IV. Arthrodesis with External Fixation.
- V. Amputation: with uncontrolled infection

A. Non operative therapies and medical management

The goals for every patients undergoing treatment for an acute or quiescent Charcot process should be to maintain or achieve structural stability of the foot and ankle, to prevent ulceration, and to preserve a plantigrade foot [38].

Total contact cast

Most cases of acute Charcot ankle especially stage 0 or stage 1 Eichenholtz Charcot arthropathy can be treated non-surgically with pressure-relieving methods such as total contact casting [TCC], which is believed to be the gold standard of treatment [39].

Prefabricated pneumatic walking brace

An alternative to TCC is a prefabricated pneumatic walking brace [PPWB]. Use of the PPWB is limited in patients who have severe foot deformity or who are noncompliant, benefits include easier wound surveillance, ease of application and the ability to use several types of dressings.

Charcot restraint orthotic walker

Antiresorptive drugs

Bisphosphonates are popular as antiresorptive drugs against osteoporosis, Paget's disease, and other diseases with increased bone turnover, and there have been reports on the possibility of pharmacologic therapy for Acute Charcot Arthropathy, but still doesn't get FDA approved [40].

Electrical bone stimulators

Other adjunct therapies have also been offered to help manage ACA. Electric bone growth [EBG] stimulators have been experimentally applied and clinically tested to promote healing of fractures in the acute phase [41].

B. Surgical management

Operative Treatment including

[1] Debridement of ulcer

Typically skeletal shortening through midfoot wedge excision creates sufficient redundant enough tissue to permit and can be used in either primary or delayed wound closure [42].

[2] Osteotomy

Exostectomy followed by protective bracing and antibiotic therapy can lead to a good result. In two studies, limb-salvage rates reached 90% with this procedure, although revision surgery was required in 25% of cases [43].

General rules and indications

However, [37] showed promising results with fusion during the fragmentation stage, without any major complications and a return to regular shoe wear in a mean of 27 weeks of treatment and follow up

A. Arthrodesis with internal fixation

Arthrodesis with external fixation

External fixation recently has gained popularity as a less invasive treatment of Charcot deformities. Good results have been reported with external fixation techniques in patients who were not suited for internal fixation and who otherwise may have required amputation, Limb salvage rates were >90%, and new or recurrent ulceration was rare [5].

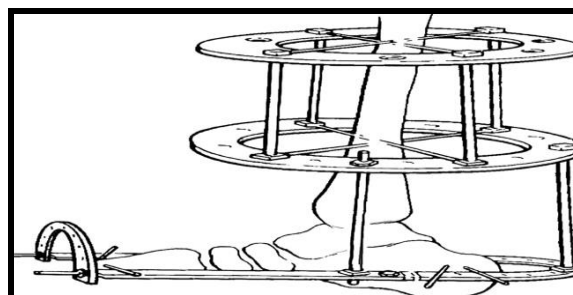
Taylor spatial frame

A recent development in external fixation [the Taylor spatial frame] uses a system of six struts to connect rings [44].

B. Hind foot and ankle

In many cases the acute Charcot event, if treated appropriately, can maintain reasonable alignment, and surgery or ulceration from pressure areas in the midfoot can be avoided. This experience has not been described in hindfoot and ankle literature [45].

Stability will aid the repair of soft tissues, much as in open trauma situations and the external fixators allow access for local care. The fixator also may allow the correction and maintenance of deformity during the initial stages [45].



Amputation

arthrodesis or recurrent ulceration or infection. In a retrospective review of multimodal management of patients with known Charcot deformities, Saltzman et al, noted a 2.7% annual rate of amputation [46].

5. Summary

Peripheral neuropathy can lead to multiple symptoms like numbness, pain, itching, burning sensation, and muscle weakness, it is usually affecting upper and lower limbs especially hands, feet, forearms and legs.

Peripheral nerves acting as an important alarm for tissues to face the dangers which is facing by them, it acting as a defence army for any harmful agents. Diabetes Mellitus is the most common cause of peripheral neuropathy. Jean Martin was the first one who described this disease, by year 1868. Until the development of antibiotics, the syphilis was the most common cause of peripheral neuropathy. The pathophysiology of Charcot Arthropathy can be explained by one of the two following theories,

Neurotraumatic theory, which explains the occurrence of Charcot arthropathy due to multiple and fine fractures which can be caused by fine and multiple dual trauma, due to absence of body defence alarming system.

Neurovascular theory, which explains occurrence of Charcot Arthropathy due to vasodilatation of blood vessels which leads to calcium absorption and weakness of the bones which become so soft and available to fractures.

Recently the overlapping between two theories is the most accepted cause to occurrence of Charcot Arthropathy. Usually the diagnosis of Charcot Arthropathy depends on clinical picture, as presence of peripheral neuropathy, past history of fine multiple traumas, poly morbidity of patient, and clinical examination of the patient.

Examination of patient can include general examination like vital signs, local examination can show acute inflammation signs as hotness, redness, edema, and limitation of movement. Diagnosis of Charcot arthropathy can be done by multiple investigations which include radiological and laboratory investigations.

Radiological investigations are the most reliable methods to diagnosis of Charcot Arthropathy. Plain radiograph the most used imaging, which can be used in diagnosis and staging of Charcot Arthropathy. CT scan, bone scan, magnetic resonance imaging can be useful in diagnosis, staging and differential diagnosis of Charcot Arthropathy from other suspected diseases.

The most used classification is Eschinholtz classification. Charcot Arthropathy can be treated by conservative or surgical treatment. Conservative treatment is used in early stages of disease [stage 0 and stage 1 and early stage 2]. Surgical treatment used in late stages of Charcot Arthropathy [stage 3 and 4].

Surgical treatment options may be one of the following:

1. forefoot deformity reconstruction and correction of calcaneal deviation angle
2. Saving of hind foot leg realignment
3. Reconstruction and arthrodesis of deformed joint

Reconstruction of the deformed joint can be done by arthrodesis with internal fixation, arthrodesis with external fixator or a combination by external and internal fixations.

References

- [1] B.Lamm, H.Gottlieb, D.Paley, A two stage percutaneous approach to Charcot diabetic foot reconstruction. *J Foot Ankle Surg*, Vol.25, PP.235-239, 2010.
- [2] S.J.Rajbhandari, R.C.Jenkins, C.Davies, Charcot neuroarthropathy in diabetes mellitus. *Diabetologia*, Vol.45, PP.1085-95, 2002
- [3] L.F.Sanders, Charcot neuroarthropathy of the foot. In: Bowker J, Pfeifer M, editors. *The diabetic foot*. 6th edition. St. Louis: Mosby, Vol.26, PP.439-66, 2001
- [4] P.Cooper, Application of external fixators for management of Charcot deformities of the foot and ankle. *Foot Ankle Clin*, Vol.7, PP. 207-54, 2002
- [5] W.Grant, S.Garcia-Lavin, A retrospective analysis of 50 consecutive Charcot diabetic salvage reconstruction. *J foot ankle surgery*, Vol.48, PP.30-81, 2009.
- [6] W. Jeffcoate, J. Lima, L. Nobrega, The Charcot foot. *Diabet Med*, Vol.44[17], PP.253-259, 2000.
- [7] A.Van der Ven, C.Chapman, J.Bowker, Charcot neuroarthropathy of the foot and ankle. *J Am Acad Orthop Surg*, Vol.45, PP.333-562, 2009.
- [8] A.Yousry, A.Abdalhady, Management of diabetic neuropathic ankle arthropathy by arthrodesis using an Ilizarov frame. *Acta orthopedic Belgica*, Vol.76, PP.821-825, 2010.
- [9] W.Jeffcoate, Abnormalities of vasomotor regulation in the pathogenesis of the acute Charcot foot of diabetes mellitus. *J Lower Extreme Wounds*, Vol.4, PP.122-197, 2005.
- [10] L.Bradley, Lamm and D.Paley, Charcot neuroarthropathy of the foot and ankle in limb lengthening and reconstruction surgery. *Limb Lengthening and Reconstruction Surgery*, Vol.7, PP.223-227, 2007.
- [11] R. Frykberg, Charcot Arthropathy in the Diabetic Foot. *The Diabetic Foot*, Vol.2, PP.272-345, 2005.
- [12] G.B.Jr.Holmes, N.Hill, Fractures and dislocations of the foot and ankle in diabetics associated with Charcot joint changes. *Foot Ankle Int*, Vol.15, PP.182-185, 1994.
- [13] M.Children, D.G.Armstrong, G.W. Edelson, Is Charcot arthropathy a late sequela of osteoporosis in patients with diabetes mellitus? *J Foot Ankle Surg*, Vol.37, PP.437-439, 1998.
- [14] M.J.Young, A.Marshall, J.E.Adams, P.L.Selby, A.J.Boulton, Osteopenia, neurological dysfunction, and the development of Charcot

- neuroarthropathy. *Diabetes Care*, Vol..18, PP.34–38,1995.
- [15] A.Gough, H.Abraha, F.Li, Measurement of markers of osteoclast and osteoblast activity in patients with acute and chronic diabetic Charcot neuroarthropathy. *Diabet Med*, Vol..14, PP.527–531,1997.
- [16] D.G.Armstrong,L.A.Lavery, Elevated peak plantar pressures in patients who have Charcot arthropathy. *J Bone Joint Surg*, Vol..15, PP.533-544,1998.
- [17] J.M.Charcot. Sur quelques arthropathies qui paraissent dependre d'une lésion du cerveau ou de la mouelle épinière. [On some arthropathies apparently related to a lesion of the brain or spinal cord] *Arch Physiol Norm Pathol*, Vol..15, PP.186-198,1998.
- [18] W.J.Jeffcoate, F.Game, P.R.Cavanagh, The role of proinflammatory cytokines in the cause of neuropathic osteoarthropathy [acute Charcot foot] in diabetes. *Lancet*, Vol..16, PP.366–611,2005.
- [19] A.Ndip, A.Williams, E.B.Jude, F.Serracino-Ingloft. The RANKL/RANK/OPG signaling pathway mediates medial arterial calcification in diabetic charcot neuroarthropathy. *Diabetes*, Vol..60,2187–96,2011.
- [20] D. Pitocco, V. Ruotolo, S. Caputo, L. Mancini , C.M.Collina, Six-month treatment with alendronate in acute Charcot neuroarthropathy: a randomized controlled trial. *Diabetes Care*, Vol..28, PP.1214–5,2005.
- [21] S.C. Offley, T.Z. Guo, T. Wei , J.D. Clark, H. Vogel, D.P. Lindsey. Capsaicin-sensitive sensory neurons contribute to the maintenance of trabecular bone integrity. *J Bone Miner*, Vol..20, PP.257–67,2005.
- [22] J.La.Fontaine, L.B. Harkless,V.L. Sylvia, D. Carnes, J. Heim-Hall, E. Jude,Levels of endothelial nitric oxide synthase and calcitonin gene-related peptide in the Charcot foot: a pilot study. *J Foot Ankle Surg*, Vol..47, PP.424–9,2008.
- [23] R. Blakytyn, M. Spraul, E.B. Jude, the diabetic bone: a cellular and molecular perspective. *Int J Low Extrem Wounds*, Vol..10, PP.16–32,2011.
- [24] W.J.Jeffcoate, Abnormalities of vasomotor regulation in the pathogenesis of the acute Charcot foot of diabetes mellitus. *Int J Low Extrem Wounds*, Vol..4, pp.133–7,2005.
- [25] A.Korzon–Burakowska,J. Jakóbkiewicz-Banecka,A. Fiedosiuk,N. Petrova, Osteoprotegerin gene polymorphism in diabetic Charcot neuroarthropathy. *Diabet Med*, Vol..29, PP.771–5,2012.
- [26] J.Embil, E.Trepman, Treatment of charcot foot and ankle with aprefabricated removable brace and custom insole.foot ankle surgery, Vol..35, PP.671–10,2012.
- [27] M.Rajeev Garapati,B. Steven Weinfeld, Complex reconstruction of the diabetic foot and ankle. *J am acad ortho sur*, Vol..9(187), pp. 81S–86S.2004.
- [28] M. Walter Panis, Charcot arthropathy: E-medicine, Vol.(187), pp. 81S–86S.2004
- [29] E. Trepman, M.S. Pinzur, Current topics review: Charcot neuroarthropathy of the foot and ankle. *Foot Ankle Int* , Vol.26[1], pp.46-63. 2005.
- [30] E.J. Sella, Staging of Charcot neuroarthropathy along the medial column of the foot in the diabetic patient. *J Foot Ankle Surg* , Vol.38, PP.34–40 .1999
- [31] A.B. Ram Singh, S. S. Atul Sachdev, diabetic neuropathic arthropathy. *Int. J. Diab. Dev. Countries*,Vol.20, pp.135-138.2000.
- [32] M. Shah , W Panis , charcot arthropathy article. e-medicine,Vol.22, pp.144-120.2007
- [33] S. Hopfner, C. Krolak , S. Kessler, R. Tiling, Preoperative imaging of Charcot neuroarthropathy. Does the additional application of 18F-FDG-PET make sense?. *Nuklearmedizin*, Vol.45, pp.15-20. 2005.
- [34] É.B. Rangel, J.R. Sá, S.A. Gomes, A.B. Carvalho, C.S. Melaragno ,Charcot neuroarthropathy after simultaneous pancreas–kidney transplant. *Transplantation*,Vol.94, PP.642–5. 2012.
- [35] Z. Keidar, The diabetic foot initial experience with 18F-FDG PET/CT. *J Nucl Med*,Vol.46, pp.444-449. 2005.
- [36] T. Mittlmeier, K. Klaue, P. Haar, Should one consider primary surgical reconstruction in Charcot arthropathy of the feet? *Clin Orthop Relat Res* , Vol.468, PP.1002–1011. 2010.
- [37] S.R. Simon, S.G. Tejwani, D.L. Wilson, Arthrodesis as an early alternative to nonoperative management of Charcot arthropathy of the diabetic foot. *J Bone Joint Surg Am* ,Vol.82, PP. 935–950. 2000.
- [38] R. Laurinaviciene, K. Kirketerp-Moeller, P.E. Holstein, Exostectomy for chronic midfoot plantar ulcer in Charcotdeformity. *J Wound Care*, Vol.17, pp. 53–59. 2008.
- [39] A.R. Catanzariti, R. Mendicino , B. Haverstock ,Ostectomy for diabetic neuroarthropathy involving the midfoot. *J Foot Ankle Surg*,Vol.39, PP. 291–300. 2000.
- [40] M.S. Pinzur, Current concepts review: Charcot arthropathy of the foot and ankle. *Foot Ankle Intvol* Vol.28, pp. 952-959. 2007.
- [41] J. William, M. Jeffcoate, Theories Concerning the Pathogenesis of the Acute Charcot Foot Suggest Future Therapy. *Current Diabetes Reports*,Vol.5, pp. 430– 435.2005.
- [42] J.W. Brodsky, Exostectomy for symptomatic bony prominences in diabetic Charcot feet *Clinical Orthopaedics and Related Research*, Vol.296, pp. 21-26. 1993.
- [43] Caputo GM, U.J., Cavanagh PR, Juliano P., the Charcot foot in diabetes: six key points. . *Am Fam Physician* 1998; 57: p. 27-05.
- [44] E.R.S.Zarutsky, J.M. Schuberth, The use of circular wire external fixation in the treatment of salvage ankle arthrodesis. *J Foot Ankle Surg*, Vol.44 (1) pp. 22–31. 2005.

[45] J. William ,M. Jeffcoate, Theories Concerning the Pathogenesis of the Acute Charcot Foot Suggest Future Therapy. Current Diabetes Reports, Vol.5, pp. 430–435.2005.

[46] C.L. Saltzman, B. Zimmerman, M. Estin, R. Cooper, How effective is intensive nonoperative initial treatment of patients with diabetes and Charcot arthropathy of the feet? Clin Orthop Relat Res, Vol.35 (1) , PP. 85-190,2005