

## Operative Treatment for First Carpometacarpal Arthritis ( Systematic Review )

S.M.Zahed, A.A.Ahmed, H.E.Farag and A.S.Kamel

Orthopedic Surgery Dept., Faculty of Medicine, Benha Univ., Benha, Egypt

E-Mail: Anton@gmail.com

### Abstract

The anatomy of the thumb carpometacarpal (CMC) joint, as well as the force transmitted through it, makes it extremely susceptible to osteoarthritis (OA). The thumb CMC joint has been reported as the most painful joint when compared to other hand joints affected by OA. to provide an updated, systematic review of surgical management and outcomes of the most commonly used surgical procedures to treat CMC joint OA presented in literature. we searched Medline via PubMed, SCOPUS, Web of Science, Cochrane Central Register of Controlled Trials (CENTRAL), and Google Scholar from their inception till January, 36 studies were included. the overall effect estimates showed that the rate of pain at rest after metacarpal osteotomy was 25.1% (95% CI 9.6 – 40.7%); while the rate of satisfaction after metacarpal osteotomy was 48.1% (95% CI 10.5 – 85.7%). The overall effect estimates showed that the rate of normal handgrip after metacarpal osteotomy was 87.1% (95% CI 79.2 – 95%). the overall effect estimates showed that the rate of pain at rest after Volar ligament reconstruction was 18.4% (95% CI 11.5 – 25.4%) and the rate of satisfaction was 81.6% (95% CI 74.6 – 88.5%). no surgical procedure appears to be definitely superior to another for the management of first carpometacarpal arthritis in terms of pain, physical function, patient global assessment, range of motion, or strength. Nevertheless, participants who had trapeziectomy had fewer complications than those who had the other commonly used procedures analyzed in the review.

**Keywords:** Operative, Carpometacarpal, Arthritis.

### 1. Introduction

The thumb is the most important digit of the hand and greatly magnifies the complexity of human prehension . Functionally, the most important joint of the thumb is the carpometacarpal (CMC) joint, located at the base of the digit [1].

Thumb base arthritis is a common affliction. It is particularly common in females, with 33% of post menopausal women affected. It usually occurs spontaneously, probably with a genetic predisposition. Only occasionally are other causal factors such as trauma or infection. Joint laxity may be a factor in those with a younger onset [2].

The carpometacarpal joint of the thumb is the second most common site of arthritis in the hand [3].

The thumb CMC joint obtains its stability primarily through ligamentous support. A diagnosis of thumb CMC arthritis is based on symptoms of localized pain, tenderness and instability on physical examination, and radiographic evaluation [4].

This joint is considered unstable when it exhibits gross abnormal alignment, which is often combined with excessive and aberrant mobility.

An unstable joint may, over time, become fixed and deformed, which is characterized by varying and often progressive dislocation of the joint surfaces, resulting in a displaced axis of rotation and abnormal actions of thumb muscles. The main consequence of the instability is most often pain and weakness, most notably during pinch and grasping actions [1].

In most persons, the CMC joint functions well throughout a lifetime of relatively large imposed stress. Force at the joint is partially absorbed and resisted by healthy, strong ligaments. In addition, intact and healthy articular cartilage can help to dissipate forces that cross the joint. Unfortunately, however, in the case of trauma or disease, ligaments may lose their ability to stabilize the

joint. Loss of stability at the basal joint of the thumb can lead to arthritic changes within the joint, as well as compensatory deformities in the more distal joints [1].

Fortunately, nonsurgical management can provide sustained relief, especially in early disease. Furthermore, when surgery is indicated, there are a variety of procedures that can reliably improve thumb function and engender high patient satisfaction, usually exceeding 90% [5].

Surgical intervention is typically used when conservative therapy is unable to retard the progression of instability. Surgery is especially considered when the instability is associated with uncontrollable pain and a loss of function. The goals of surgery are essentially similar to those of conservative intervention for the CMC joint. Selection of the specific surgical procedure is based on physical assessment and the radiographic findings of the CMC joint [6].

The review presents a brief explanation of relatively common surgical procedures for arthritis of the first CMC joint.

Ligament reconstruction Stabilization of the painful, hypermobile trapezio-metacarpal by reproducing the palmar beak ligament with a portion of the flexor carpi radialis tendon can effectively reduce symptoms [7]; progression to arthritis is perhaps slowed [8]. The technique can be very effective in reducing the pain of early stage arthritis as well. Attention has been drawn to the potential importance of stabilizing the dorsal ligamentous structures as well as the palmar beak ligament. Potential disadvantages are stiffness and quite a prolonged recovery [9].

A CMC hemiarthroplasty is generally indicated for persons with marked arthritis and associated instability that is limited primarily to the base of the thumb [10]. Hemiarthroplasty can provide a stable,

painless, mobile thumb in cases of isolated osteoarthritis of trapeziometacarpal joint in patients with good bone stock [11].

An arthrodesis of the CMC joint of the thumb is most typically performed on a person with posttraumatic arthritis or joint destruction that is limited to the base of the thumb. Trapeziometacarpal arthrodesis provides stability and strength. Despite clear advantages the method has been criticized for different reasons: predisposition to increased arthrosis at adjacent joints, significant limitation in range of motion, limited ability to flatten the hand, necessity for prolonged postoperative immobilization, compensatory hyperextension of the metacarpophalangeal joint (MCP) and a high rate of nonunion [12].

The purpose of this work is to conduct a systematic review study from former available studies to compare between surgical treatment procedures for first carpometacarpal arthritis regarding: postoperative long term pain, stability, range of motion, hand grip power, patient satisfaction and complications.

## 2. Methods

We performed this systematic review and meta-analysis in accordance to the recommendations of the Preferred Reporting Items for Systematic Reviews and Meta-Analyses (PRISMA) statement and Meta-analysis Of Observational Studies in Epidemiology (MOOSE) statement. PRISMA and MOOSE are reporting checklists for Authors, Editors, and Reviewers of Meta-analyses of interventional and observational studies. According to International committee of medical journal association (ICJME), reviewers must report their findings according to each of the items listed in those checklists [13].

### The present review included studies that fulfilled the following criteria:

- 1) Studies that included adults patients (aged  $\geq 18$  years old) with osteoarthritis of the thumb carpometacarpal.
- 2) Studies that assessed the safety and effectiveness of one of the following operative treatment for osteoarthritis of the thumb carpometacarpal:
  - a. Volar ligament reconstruction,
  - b. Metacarpal osteotomy,
  - c. CMC arthrodesis,
  - d. Trapeziectomy,
  - e. Trapeziectomy with TI,
  - f. Trapeziectomy with LR,
  - g. Trapeziectomy with LRTI,
  - h. Resection Arthroplasty,
  - i. Joint replacement.

- 3) Studies that reported any of the following outcomes:
  - a. Postoperative long-term pain.
  - b. Stability.
  - c. Range of motion.
  - d. Hand grip power.
  - e. Patient satisfaction.
  - f. Complications.
- 4) Studies that were prospective or retrospective or nonrandomized or randomized controlled trials.

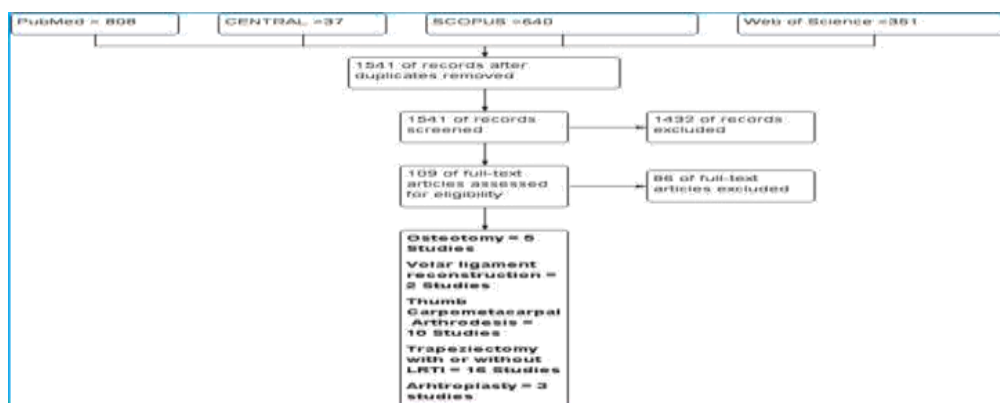
### We excluded

1. Review articles.
2. Non-English studies.
3. In-vitro studies.
4. Theses, dissertations and conference abstracts.
5. Trials with unreliable date for extraction.

An electronic search was conducted from the inception till January 2020 in the following bibliographic databases: Medline via PubMed, SCOPUS, Cochrane Central Register of Controlled Trials (CENTRAL), and Web of Science to identify relevant articles. We used different combinations of the following queries: ((Thumb) OR (Carpometacarpal,)) AND (Osteoarthritis) AND (Surgical).

## 3. Results

In the present study, we searched Medline via PubMed, SCOPUS, Web of Science, Cochrane Central Register of Controlled Trials (CENTRAL), and Google Scholar from their inception till January. The search retrieved 692 unique records. We then retained 109 potentially eligible records for full-texts screening. Finally, 36 studies (4 Randomized Controlled Trials (RCT), 13 Prospective Studies and 19 Retrospective Studies) were included; Fig (1).

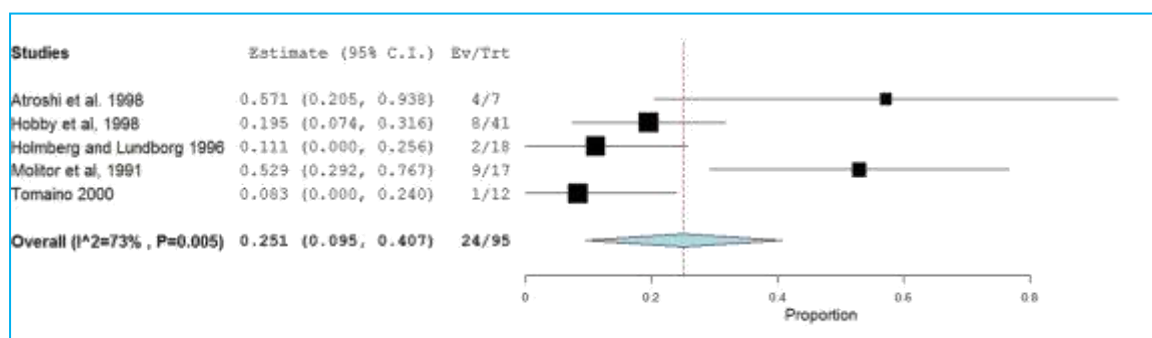


**Fig (1) Metacarpal Osteotomy:** Overall, five studies reported the rates of pain at rest for Metacarpal Osteotomy Table (1).

**Table (1)** Summary of Characteristics of the Included Studies Using Metacarpal Osteotomy..

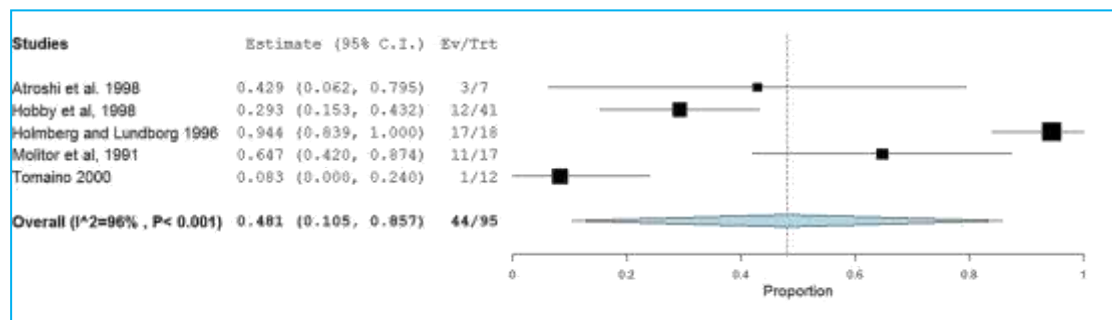
Authors	Year	Country	Study Design	Population	Procedure	Level of Evidence
Atroshi et al [14]	1998	Sweden.	Retrospective	Patients with Primary trapeziometacarpal arthrosis	Osteotomy Trapeziectomy with LR	V
Hobby et al.[15]	1998	England	Prospective Study	Patients with Painful trapeziometacarpal osteoarthritis	Osteotomy	III
Holmberg and Lundborg[16]	1996	Sweden.	Prospective Study	Patients with osteoarthritis of the trapeziometacarpal joint	Radial, 30 degrees wedge osteotomy	III
Molitor et al.[17]	1991	England	Pro and Retrospective study	Patients with osteoarthritis of the trapeziometacarpal joint	Basal osteotomy	IV
Tomaino [9]	2000	Russia	Prospective Study	Patients with osteoarthritis of the trapeziometacarpal joint	30 degrees extension osteotomy	III

The overall effect estimates showed that the rate of pain at rest after metacarpal Osteotomy was 25.1% (95% CI 9.6 – 40.7%). The pooled studies showed significant heterogeneity ( $p = 0.0001$ ;  $I^2 = 73%$ ; Fig (2).



**Fig (2)** Forest Plot of rates of pain at rest for Metacarpal Osteotomy

The overall effect estimates showed that the rate of satisfaction after metacarpal Osteotomy was 48.1% (95% CI 10.5 – 85.7%). The pooled studies showed significant heterogeneity ( $p = 0.0001$ ;  $I^2 = 96%$  Fig (3)).



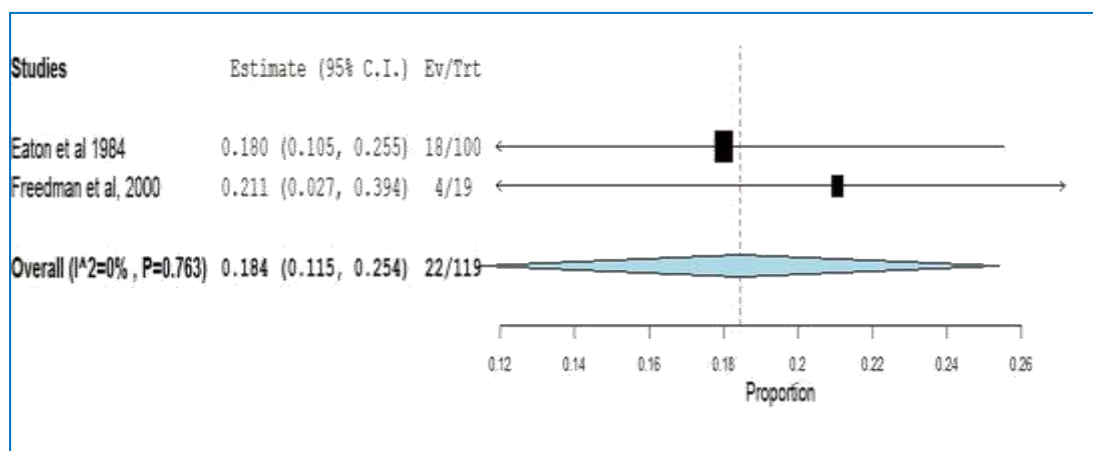
**Fig (3)** Forest Plot of rates of satisfaction for Metacarpal Osteotomy.

**I. Volar Ligament Reconstruction;** the studies included in Table (2).

**Table (2)** Summary Characteristics of the Included Studies Using Volar Ligament Reconstruction.

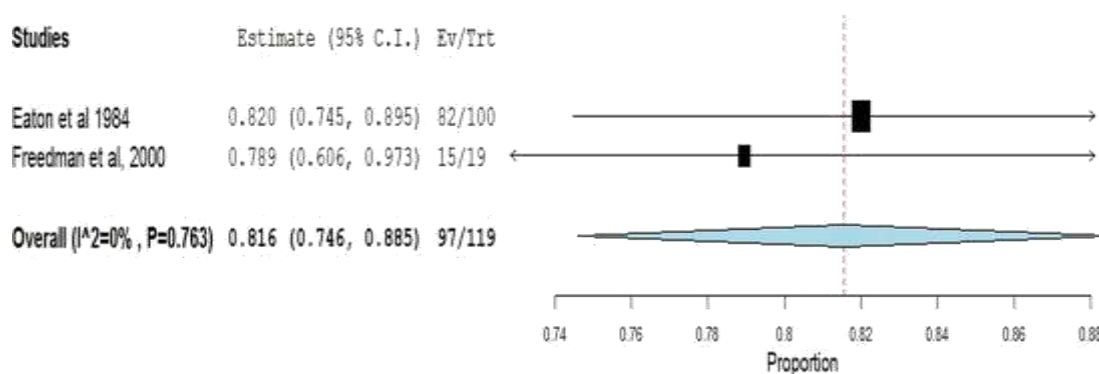
Authors	Year	Country	Study Design	Population	Procedure	No.	Level of Evidence
Eaton et al,[18]	1984	USA.	Retrospective Study	Patients with primary trapeziometacarpal arthrosis	Ligament reconstruction	100	IV
Freedman et al,[8]	2000	USA	Retrospective Study	Patients with painful trapeziometacarpal osteoarthritis	Ligament reconstruction	19	IV

The overall effect estimates showed that the rate of pain at rest after Volar ligament reconstruction was 18.4% (95% CI 11.5 – 25.4%). The pooled studies showed no significant heterogeneity ( $p = 0.76$ ;  $I^2 = 0\%$ ; Fig (4).



**Fig (4)** Forest Plot of rates of pain at rest for Volar ligament reconstruction.

The overall effect estimates showed that the rate of satisfaction after Volar ligament reconstruction was 81.6% (95% CI 74.6 – 88.5%). The pooled studies showed no significant heterogeneity ( $p = 0.76$ ;  $I^2 = 0\%$  Fig (5)).



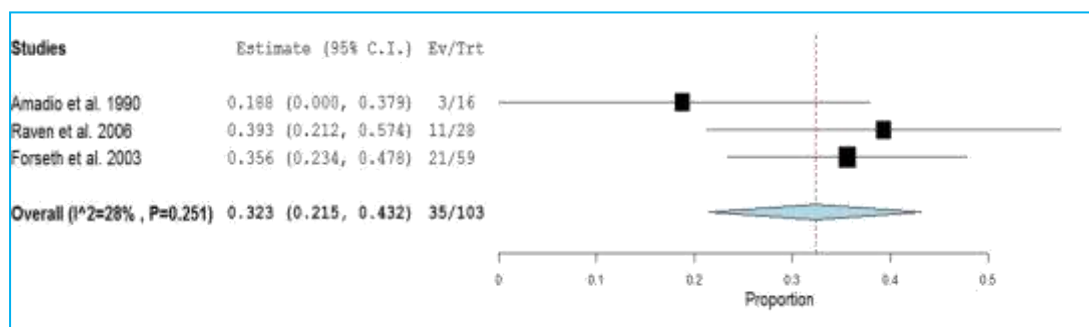
**Fig (5)** Forest Plot of rates of satisfaction for Volar ligament reconstruction.

**II. Thumb Carpometacarpal Arthrodesis;** included studies in Table (3).

**Table(3)** Summary Characteristics of the Included Studies Using Thumb Carpometacarpal Arthrodesis.

Authors	Year	Country	Study Design	Population	No.	Procedure	Level of Evidence
Hart et al.[19]	2006	Germany	Prospective Study	Patients with primary trapeziometcarpal arthrosis	20	CMC arthrodesis	III
					20	Trapeziectomy with LRTI	
Schröder et al.[20]	2002	Germany	Retrospective Study	Retrospective Study	18	CMC arthrodesis	V
					18	Trapeziectomy with TI	
Mureau et al.[21]	2001	Netherlands	Retrospective Study	Retrospective Study	32	CMC arthrodesis	V
					24	Trapeziectomy with TI	
Hartigan et al.[22]	2001	USA	Retrospective Study	Retrospective Study	58	CMC arthrodesis	V
					49	Trapeziectomy with LRTI	
Conolly et al.[23]	1993	Australia.	Retrospective Study	Retrospective Study	16	CMC arthrodesis	V
					15	Trapeziectomy with LRTI	
Amadio et al.[24]	1990	USA	Retrospective Study	Retrospective Study	16	Silicone arthroplasty	V
					24	CMC arthrodesis	
Kvarnes et al.[25]	1985	Norway	Retrospective Study	Retrospective Study	24	Different types of joint replacements	V
					7	Trapeziectomy with TI	
Raven et al.[26]	2006	Netherlands	Retrospective Study	Retrospective Study	53	CMC arthrodesis	V
					12	Trapeziectomy	
Taylor et al.[27]	2005	England	Retrospective Study	Retrospective Study	3	Silicone arthroplasty	V
					17	Trapeziectomy with TI	
Forseth et al.[28]	2003	USA	Retrospective Study	Retrospective Study	18	Resection	V
					28	arthroplasty	
Taylor et al.[27]	2005	England	Retrospective Study	Retrospective Study	36	CMC arthrodesis	V
					22	CMC arthrodesis	
Forseth et al.[28]	2003	USA	Retrospective Study	Retrospective Study	55	Silastic trapezial replacement	V
					59	Trapeziectomy or trapeziectomy with LR	
					19	CMC arthrodesis (K-wire)	
						CMC arthrodesis (plate and screw)	

The overall effect estimates showed that the rate of pain at rest after Thumb Carpometacarpal Arthrodesis was 32.3% (95% CI 21.5 – 43.2%). The pooled studies showed no significant heterogeneity ( $p=0.25$ ;  $I^2=28\%$ ; Fig (6)).



**Fig (6)** Forest Plot of rates of pain at rest for Thumb Carpometacarpal Arthrodesis.

The overall effect estimates showed that the rate of satisfaction after Thumb Carpometacarpal Arthrodesis was 55.7% (95% CI 36.7– 74.6%). The pooled studies showed significant heterogeneity ( $p = 0.001$ ;  $I^2 = 88\%$ ; Fig (7)).

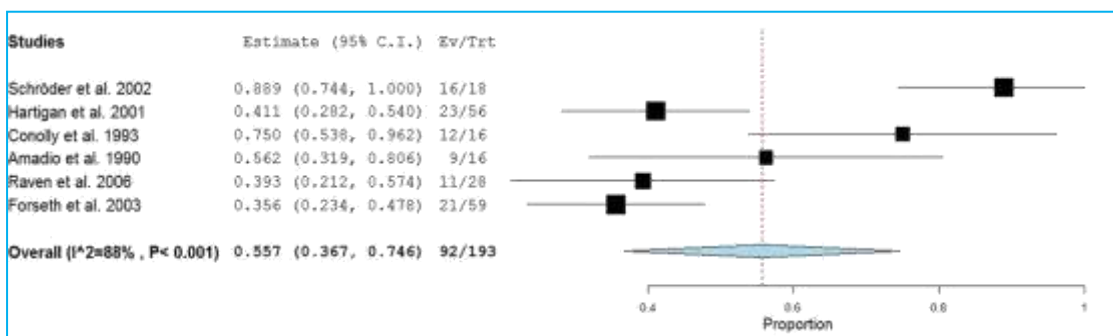


Fig (7) Forest Plot of rates of satisfaction for Thumb Carpometacarpal Arthrodesis.

The overall effect estimates showed that the normal range of motion after Thumb Carpometacarpal Arthrodesis was 64.1% (95% CI 13.8 – 100%). The pooled studies showed significant heterogeneity ( $p = 0.001$ ;  $I^2 = 92\%$ ; Fig (8)).

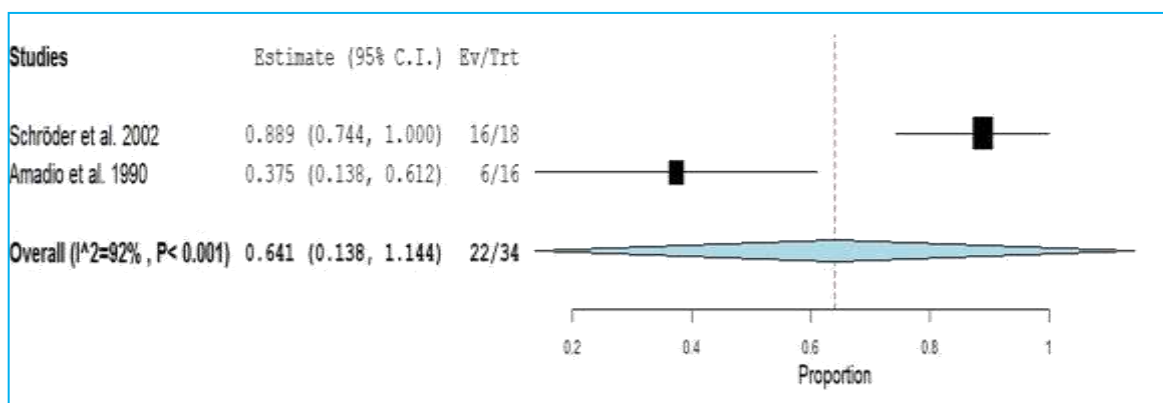


Fig (8) Forest Plot of rates of normal range of motion for Thumb Carpometacarpal Arthrodesis.

The overall effect estimates showed that the rate of normal handgrip after Thumb Carpometacarpal Arthrodesis was 75.3% (95% CI 44.7– 100%). The pooled studies showed significant heterogeneity ( $p = 0.017$ ;  $I^2 = 82\%$ ; Fig (9)).

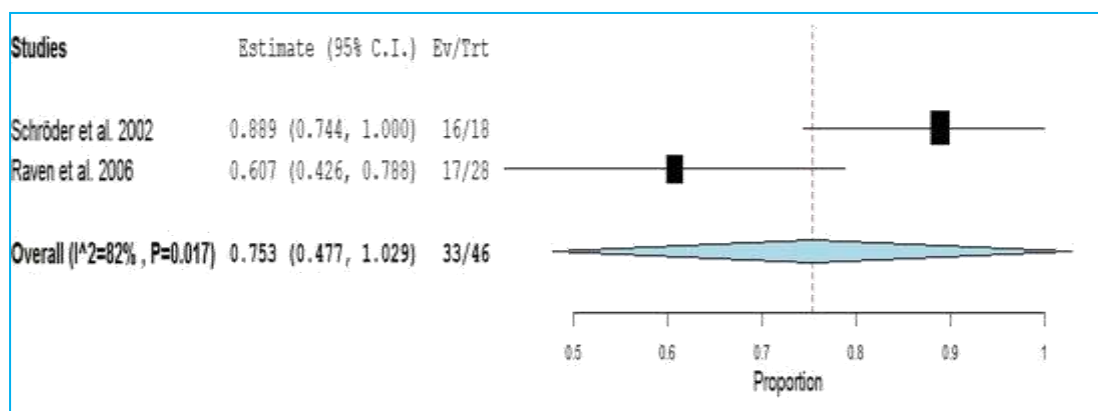


Fig (9) Forest Plot of rates of normal handgrip for Thumb Carpometacarpal Arthrodesis.

#### 4. Discussion

In the present study, the overall effect estimates showed that the rate of pain at rest after metacarpal osteotomy was 25.1% (95% CI 9.6 – 40.7%); while the rate of satisfaction after metacarpal osteotomy was 48.1% (95% CI 10.5 – 85.7%). The overall effect estimates showed that the rate of normal handgrip after metacarpal osteotomy was 87.1% (95% CI 79.2 – 95%).

In agreement with our findings, [29] evaluated the long-term outcomes of first metacarpal extension osteotomy for early CMC arthritis. The authors retrospectively reviewed 13 patients who underwent first metacarpal extension osteotomy between 1996 and 2005. Ten of the 13 patients (77 %) were either satisfied or very satisfied with their results. Of the eight patients who agreed to repeat radiographs, five had no progression of degenerative changes compared to pre-op radiographs [29].

Likewise [30] evaluated the survival and long-term outcomes of thumb metacarpal extension osteotomy for early CMC arthritis. Patients who underwent a thumb extension osteotomy between years 2000 and 2011 were identified. Thirty-two procedures in 7 males and 21 females were performed (mean age, 44.8 y). Overall, thumb metacarpal osteotomy provided some degree of pain relief and improvement of function [30].

In the present systematic review and meta-analysis, the overall effect estimates showed that the rate of pain at rest after Volar ligament reconstruction was 18.4% (95% CI 11.5 – 25.4%) and the rate of satisfaction was 81.6% (95% CI 74.6 – 88.5%).

In line with our findings, [8] limited their indications for volar ligament reconstruction to stage I and stage II disease. At an average follow-up of 5.2 years, all patients with stage I disease had good or excellent results, with complete pain relief. Patients with stage II disease had 82% good to excellent results, with 70% pain relief. Follow-up radiographs showed no further degeneration at the CMC joint. Pinch strength averaged 108% of the contralateral Side and grip strength averaged 105% of the contralateral side. All but 1 patient were able to oppose the thumb to the base of the little finger [8].

At 15-year follow-up, all patients with stage I thumb CMC arthritis who were treated with volar oblique ligament reconstruction had high satisfaction rates; 65% of patients showed no further progression of radiographic CMC arthritis [4].

In the past decades, arthrodesis of the thumb CMC joint has been another popular technique to treat OA at the base of the thumb. In the present study, we found that rate of pain at rest after Thumb Carpometacarpal Arthrodesis was 32.3% (95% CI 21.5 – 43.2%), the rate of satisfaction was 55.7% (95% CI 36.7– 74.6%), the rate of normal range of motion after Thumb Carpometacarpal Arthrodesis was 64.1% (95% CI 13.8–100%), and the rate of normal handgrip was 75.3% (95% CI 44.7– 100%).

In concordance with our findings, a retrospective study by [28]. in 2003 (level V) compared arthrodesis

using plate and screw fixation with a previously published K-wire fixation group [28]. showed that the satisfaction rate was 70% and almost 65% of the patients had normal function[28].

#### 5. Conclusion

No surgical procedure appears to be definitely superior to another for the management of first carpometacarpal arthritis in terms of pain, physical function, patient global assessment, range of motion, or strength. Nevertheless, participants who had trapeziectomy had fewer complications than those who had the other commonly used procedures analyzed in the review. However, given the lack of level I–III studies on some of the reviewed procedures (volar ligament reconstruction and metacarpal osteotomy for the early stages of osteoarthritis and carpometacarpal arthrodesis and joint replacement for the advanced stages of osteoarthritis) and based on good results of carpometacarpal arthrodesis and total joint prostheses in studies with less methodological quality, we postulate that there could be differences between the various surgical procedures, certainly in the long term. Therefore, RCTs of carpometacarpal arthrodesis and total joint prostheses compared to trapeziectomy with long follow-up are warranted. Furthermore, because differences between the various techniques are small, researchers should focus on developing more sensitive outcome measures that are indicative of the specific changes in hand function after carpometacarpal osteoarthritis.

#### References

- [1] D. A. Neumann and T. Bielefeld, "The carpometacarpal joint of the thumb: stability, deformity, and therapeutic intervention.," *J. Orthop. Sports Phys. Ther.*, Vol. 33, PP. 386–99, Jul., doi: 10.2519/jospt.2003.33.7.386. 2003
- [2] D. Warwick, P. Beredjiklian, L. De Smet, A. Smit, and G. Vermeulen, "IFSSH Scientific Committee on Degenerative Arthritis – CMC Joint, Vol. 14, PP. 1–12, 2014.
- [3] M. S. Shuler, S. Luria, and T. E. Trumble, "Basal joint arthritis of the thumb.," *J. Am. Acad. Orthop. Surg.*, Vol. 16, PP. 418–23, Jul. 2008.
- [4] A. E. Van Heest and P. Kallemeier, "Thumb carpal metacarpal arthritis.," *J. Am. Acad. Orthop. Surg.*, Vol. 16, PP. 140–51, Mar. 2008.
- [5] A. S. Croog and M. E. Rettig, "Newest advances in the operative treatment of basal joint arthritis.," *Bull. NYU Hosp. Jt. Dis.*, Vol. 65, PP. 78–86, 2007.
- [6] V. D. Pellegrini, "Pathomechanics of the thumb trapeziometacarpal joint.," *Hand Clin.*, Vol. 17, PP. 175–84, vii–viii, May 2001.
- [7] C. M. Robinson and R. J. Dobson, "Anterior instability of the shoulder after trauma," *J. Bone Jt. Surg.*, Vol. 86, PP. 469–479, May, doi: 10.1302/0301-620X.86B4. 2004
- [8] D. M. Freedman, R. G. Eaton, and S. Z. Glickel,



- “Long-term results of volar ligament reconstruction for symptomatic basal joint laxity,” *J. Hand Surg. Am.*, Vol. 25, PP. 297–304, Mar., doi: 10.1053/jhsu.2000.jhsu25a0297. 2000
- [9] M. M. Tomaino, “Treatment of Eaton stage I trapeziometacarpal disease with thumb metacarpal extension osteotomy,” *J. Hand Surg. Am.*, Vol. 25, PP. 1100–1106, 2000
- [10] T. E. Trumble, G. Rafijah, M. Gilbert, C. H. Allan, E. North, and W. V McCallister, “Thumb trapeziometacarpal joint arthritis: partial trapeziectomy with ligament reconstruction and interposition costochondral allograft,” *J. Hand Surg. Am.*, Vol. 25, PP. 61–76, Jan., 2000
- [11] P. M. PHALTANKAR and P. A. MAGNUSSEN, “Hemiarthroplasty for Trapeziometacarpal Arthritis – A Useful Alternative?,” *J. Hand Surg. Am.*, Vol. 28, PP. 80–85, 2003
- [12] J. V. D. B. L. De Smet \*, F.Vaes, “Trapeziometacarpal Arthrodesis or Trapeziectomy,” *J. Bone Jt. Surg.*, Vol. 96, no. 9, PP. 726–733, 2014, doi: 10.1016/S0021-9355(14)74164-5.
- [13] D. Moher et al., “Preferred reporting items for systematic reviews and meta-analyses: The PRISMA statement,” *PLoS Med.*, Vol. 6, PP.10-1371. 2009
- [14] I. Atroshi, G. Axelsson, and E. L. Nilsson, “Osteotomy versus tendon arthroplasty in trapeziometacarpal arthrosis. 17 Patients followed for 1 year,” *Acta Orthop. Scand.*, Vol. 69, PP. 287–290, 1998, 2003
- [15] J. L. Hobby, H. A. Lyall, and B. F. Meggitt, “First metacarpal osteotomy for trapeziometacarpal osteoarthritis,” *J. Bone Jt. Surg. - Ser. B*, Vol. 80, PP. 508–512, 1998, doi: 10.1302/0301-620X. 80B3 2000.
- [16] J. Holmberg and G. Lundborg, “Osteotomy of the first metacarpal for osteoarthrosis of the basal joints of the thumb,” *Scand. J. Plast. Reconstr. Surg. Hand Surg.*, Vol. 30, PP. 67–70, , doi: 10.3109/02844319609072407. 1996
- [17] P. J. A. Molitor, R. J. H. Emery, and B. F. Meggitt, “First metacarpal osteotomy for carpo–metacarpal osteoarthritis,” *J. Hand Surg. (British Eur. Vol.)*, Vol. 16, PP. 424–427, , doi: 10.1016/0266-7681(91)90018-J. 1991
- [18] R. G. E. M. D, L. B. L. M. D, J. W. L. M. D, and J. J. K. M. D, “Ligament reconstruction for the painful thumb carpometacarpal joint: A long-term assessment,” *J. Hand Surg. Am.*, Vol. 9, PP. 692–699, , doi: 10.1016/S0363-5023(84)80015-5. 1984
- [19] R. Hart, M. Janeček, V. Šiška, B. Kučera, and V. Štípčák, “Interposition suspension arthroplasty according to Epping versus arthrodesis for trapeziometacarpal osteoarthritis,” *Eur. Surg. - Acta Chir. Austriaca*, Vol. 386, PP. 433–438, , doi: 10.1007/s10353-006-0285-1. 2006
- [20] J. Schröder, G. M. M. J. Kerkhoffs, H. J. Voerman, and R. K. Marti, “Surgical treatment of basal joint disease of the thumb: Comparison between resection-interposition arthroplasty and trapeziometacarpal arthrodesis,” *Arch. Orthop. Trauma Surg.*, Vol. 122, PP. 35–38, , doi: 10.1007/s004020100313. 2002
- [21] M. A. M. Mureau, R. P. C. Rademaker, J. A. N. Verhaar, and S. E. R. Hovius, “Tendon interposition arthroplasty versus arthrodesis for the treatment of trapeziometacarpal arthritis: A retrospective comparative follow-up study,” *J. Hand Surg. Am.*, Vol. 26, PP. 869–876, , doi: 10.1053/jhsu.2001.26659. 2001
- [22] B. J. Hartigan, P. J. Stern, and T. R. Kiefhaber, “Thumb Carpometacarpal Osteoarthritis: Arthrodesis Compared with Ligament Reconstruction and Tendon Interposition,” *JBJS*, Vol. 83, PP. 24–56, 2001.
- [23] W. B. Conolly and M. Lanzetta, “Surgical Management of Arthritis of the Carpo-Metacarpal Joint of the Thumb,” *Aust. N. Z. J. Surg.*, Vol. 63, PP. 596–603, , doi: 10.1111/j.1445-2197.1993.tb00465.x. 1993
- [24] P. C. Amadio and S. P. De Silva, “Comparison of the results of trapeziometacarpal arthrodesis and arthroplasty in men with osteoarthritis of the trapeziometacarpal joint,” *Ann. Chir. la Main*, Vol. 9, PP. 358–363, , doi: 10.1016/S0753-9053(05)80509-5. 1990
- [25] L. Kvarnes and O. Reikers, “Osteoarthritis of the carpometacarpal joint of the thumb. An analysis of operative procedures,” *J. Hand Surg. Am.*, Vol. 10, PP. 117–120, , doi: 10.1016/S0266-7681(85) 80037-1. 1985
- [26] E. E. J. Raven, G. M. M. J. Kerkhoffs, S. Rutten, A. J. W. Marsman, R. K. Marti, and G. H. R. Albers, “Long term results of surgical intervention for osteoarthritis of the trapeziometacarpal joint: Comparison of resection arthroplasty, trapeziectomy with tendon interposition and trapezio-metacarpal arthrodesis,” *Int. Orthop.*, Vol. 31, PP. 547–554, , doi: 10.1007/s00264-006-0217-5. 2007
- [27] J. C. D. and A. V. B. E. J. TAYLOR, K. DESARI, “A comparison of fusion, trapeziectomy, and silastic replacement for the treatment of osteoarthritis of the trapeziometacarpal joint,” *J. hand Surg. (Edinburgh, Lothian)*, Vol. 30, PP. 45–49, 2005.
- [28] M. J. Forseth and P. J. Stern, “Complications of trapeziometacarpal arthrodesis using plate and screw fixation,” *J. Hand Surg. Am.*, Vol. 28, PP. 342–345, , doi: 10.1053/jhsu.2003.50042. 2003
- [29] F. H. Chou, J. J. Irrgang, and R. J. Goitz, “Long-term follow-up of first metacarpal extension osteotomy for early CMC arthritis,” *Hand*, Vol. 9, PP. 478–483, 2014.
- [30] A. Bachoura, E. J. Yakish, and J. D. Lubahn, “Survival and long-term outcomes of thumb metacarpal extension osteotomy for symptomatic carpometacarpal laxity and early basal joint arthritis,” *J. Hand Surg. Am.*, Vol. 43, PP. 7–72 , 2018.