

Fixation of Unstable Neck Femur Fractures in Adults, Review Article

Ahmed H. Yousry^a, Shady S. El-Beshry^a, Gergis Nabil Benyameen^{b,#}

^aDepartment of Orthopedics, ^bFaculty Of Medicine, Ain Shams university, Egypt

Corresponding author Tel.:022458239 ; Mob.:01201330211; Email : dr.gergisnabil@yahoo.com

ABSTRACT

Background : Femoral neck fracture is a common problem especially in young adults. There are different methods of fixation of unstable neck femur fractures in adults, some of which are accompanied by complications. **Aim of study:** A systematic review on the different methods of fixation of unstable femoral neck fractures in adults with clarifying the incidence of nonunion, avascular necrosis, displacement and other complications in each type of fixation. **Methods** : A systematic review of literatures was conducted on five studies (306 patients) published in literature in the last 10 years using different methods of fixation with inclusion criteria including : English literature, human studies on adults aged 18-60 years with unstable neck femur fractures Pauwel grade 3. Exclusion criteria including :in vitro studies, pathological and non united fractures in people aged below 18 or above 60 years with stable neck femur fractures Pauwel grade 1,2

Results: showed that Achieved union in management by osteosynthesis and primary valgus intertrochantric osteotomy using broad DCP showed better results than by other methods of fixation (cannulated screws , DCS, cephalomedullary nail) and by achieving union percentage of 92,7% as in (MP Singh 2008), the same percentage achieved by fixation by DHS as in (Frank Liporace 2008), followed by 92% rate of union achieved by fixed angle device (DCS or cephalomedullary nail) in (Frank Liporace 2008)

Comparing complications in different fixation methods showed that complications are inevitable yet manageable, but higher complications rate associated with fixation of neck femur fractures using DHS by achieving 26,4% rate of nonunion and 26,4% rate of AVN in (carlos Roberto schwartsmann 2017) while rate of non union was 7,3% in valgus intertrochantric osteotomy by broad DCP and rate of AVN was 11% as in (MP Singh 2008). **Summary and conclusion** Management of unstable neck femur fractures in adults is done by means of direct fixation with cannulated screws, DHS, fixed angle device (DCS or cephalomedullary nail) or osteosynthesis and valgus intertrochantric osteotomy to avoid some adverse effects of the direct fixation methods, so, recent studies showed that valgus intertrochantric osteotomy achieve better results than traditional methods with less complications.

Keywords:Unstable femoral neck fractures , pauwel's III, young adults ,primary valgus osteotomy.

INTRODUCTION

Femoral neck fracture is a common problem especially in young adults to the extent that more than 250000 hip fractures occur in united states each year (50 % involve the femoral neck). The number is projected to double by the year 2050⁽¹⁾.

Risk factors include female sex , white race , increasing age , poor health , tobacco and alcohol use , previous fracture , fall history , and low estrogen level ⁽¹⁾.

Vertical shear (pauwel type 3) femoral neck fractures result in young adult from high energy trauma extending to medial calcar and lesser trochanter and apparently evident in AP view of plain x ray⁽²⁾.

A common clinical picture of femoral neck fracture patients in displaced types is non ambulatory patient on presentation with shortening and external rotation in the lower limb. Patient with non displaced or stress fracture typically lacks the

deformity pattern and may be able to weight bear but the main complain becomes groin pain. ⁽³⁾

An accurate history is important in patients with fracture neck femur especially in older individuals giving history of loss of consciousness, prior syncopal episodes, medical history, chest pain, prior hip pain (pathological fracture) and pre injury ambulatory status is very important in detection the method of treatment. ⁽⁴⁾

Radiographic evaluation of femoral neck fracture depends on :

- **X ray imaging** :
- AP view of the pelvis.
- AP view and cross lateral view of affected proximal femur.
- A physician assisted internal rotation view of the injured hip is helpful in diagnosis. Frog lateral view of the hip is contraindicated.
- **CT imaging** :
- is of value in trauma patient

- is of choice in non displaced fractures when MRI imaging is contraindicated.

Pauwel classification of femoral neck fracture

This is based on the angle of fracture from horizontal (fig 1)

Type 1: < 30°

Type 2 : 31-70°

Type 3 : > 70° (vertical fracture pattern)

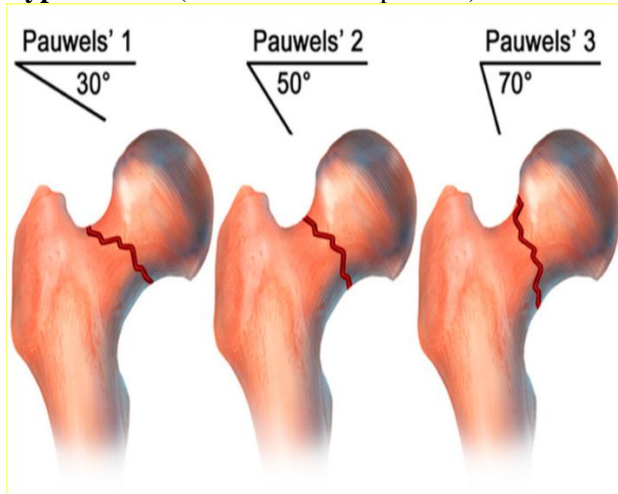


Fig. 1: Schematic representation of the Pauwels classification

There is also garden classification of femoral neck fracture (figure 2)⁽³⁾

Type 1 : incomplete / valgus impacted.

Type 2 : complete and non displaced on AP and lateral views.

Type 3 : complete with partial displacement

Trabecular pattern of femoral head does not line up with that of acetabulum

Type 4 : completely displaced

Trabecular pattern of the head assumes a parallel orientation with that of the acetabulum.

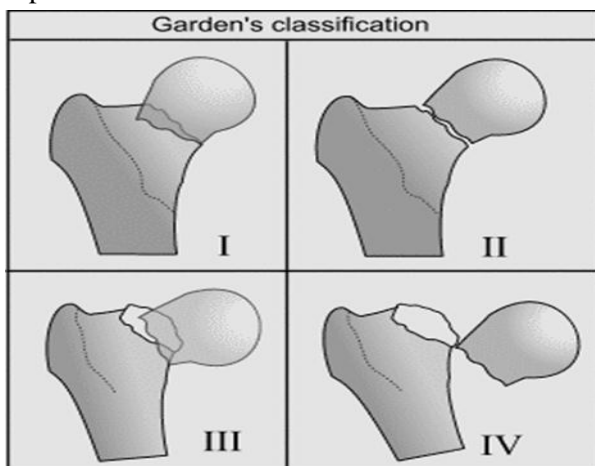


Fig 2: shows garden classification of femoral neck fracture

Aim of treatment

- 1- To minimize patient discomfort.
- 2- To restore hip function.
- 3- To allow rapid mobilization by early anatomic reduction and internal fixation.

MATERIALS AND METHODS

This is a systematic review article on fixation of unstable femoral neck fractures in adults. The search was conducted through Medline, Pubmed and Cochrane library results for the following titles;

1. Fixation of unstable femoral neck fractures in adults.
2. Medial buttress plating for femoral neck fractures.
3. Fixation of vertical shear fractures in femoral neck in adults.

Studies included were interventional studies, comparing results of fixation of unstable neck femur fractures in adults that using different methods published from 2006 to 2017 in English literature
 Inclusion criteria: 1- English language literature. 2. Human studies. 3. Article types : Clinical trial , Comparative study , Systematic reviews , Meta analysis and case series study. 4- Adults aged from 18-60 years. 5- Unstable femoral neck fracture Pauwel grade III.

Exclusion criteria: 1. In vitro studies. 2- Fractures in people aged below 18 years or above 60 years. 3- Stable femoral neck fracture Pauwel grade I, II. 4- Pathological fractures. 5- non united fractures.

Types of included participants: Adult patients with unstable fracture of femoral neck, medically free, with no previous hip fractures , fixations and no knee or spine problems.

The electronic comprehensive literature search after application of inclusion criteria identified 5 studies with total of 306 cases that were managed either by DHS, cannulated screws, and fixed angle device or by valgus intertrochantric osteotomy.

All of the studies were published between 2006-2017, the mean follow up period for these patients in these studies ranged from 24 months-54 months, the longest mean follow up was in (carlos Roberto schwartsmann2014) was 64,6 months. The mean age for the cases was 53 years
 Description of studies comparing different methods of fixation of unstable neck femur fractures in adults.

1-(carlos Roberto schwartsmann2017): A study containing 53 patients , showing the results of fixation of unstable femoral neck fractures in young adults using DHS

2-(**Carlos Roberto schwartsmann 2014**) :A study containing 96 patients , showing the results of fixation of unstable femoral neck fractures in young adults using DHS

3-(**S Kumar 2009**): A study containing 40 patients showing the results of fixation of femoral neck fractures with multiple cannulated screws.

4- (**MP Singh 2008**): A study containing 55 patients showing results of osteosynthesis and valgus intertochantric osteotomy using broad DCP as A method of management of femoral neck fracture in adults.

5- **Frank Liporace et al (2008)**: A study containing 62 patients comparing the results of fixation of femoral neck fractures by cannulated screws in 37 patients (32 patients by cannulated screws in triangular configuration and five with crossed-screw configuration) and by fixed angle device in 25 patients (14 patients by DHS ,9 patients by cephalomedullary nail and two by DCS)..

NB: The study having the largest no. of patients was (carlos Roberto schwartsmann2014) which had 96 patients and the study having smallest no. of patients was (s Kumar2009) which had 40 patients .

The study was approved by the Ethics Board of Ain Shams University.

Different methods of fixation

Cannulated screws

Cannulated screw fixation is widely accepted technique for transcervical femoral neck fracture which could be done in parallel inverted triangle configuration or recently by addition of transverecalscrew to add stability to the fracture and to resist axial ,bending ,and tortional forces affecting the hip⁽⁶⁾.

Sliding hip screw

Has a successful record for typical hip fractures. It is a fixed angle device so that it may provide increased resistance to varus collapse .but,it lacks rotational control so, it must be mixed with antirotational screw to avoid rotation⁽⁷⁾.

Dynamic condylar screw

Has a limited use for fixation of femoral neck fracture and alone cannot resist rotation, the same as DHS⁽⁷⁾.

Cephalomedullary nailing

Fixation of the fracture of femoral neck by cephalo medullary nail is done when it is combined with femoral shaft fracture. It can resist rotation but it has the problem of catastrophic migration and violation of abductors (Z-effect) and this limits its use⁽⁷⁾.

1. Medial buttress plate augmentation:

In addition to cannulated screws , Mir and Collinge(8) added medial buttress plate through open approach inferomedially along the fracture apex to add stability to the vertical shear fracture fixation and to perform antiglide function. This is done through smith-paterson or Watson jones approach using third tubular or minifragment plate (fig 3). this overcomes shear forces and convert them into compressive forces and resist varus collapse of femoral neck⁽⁸⁾.

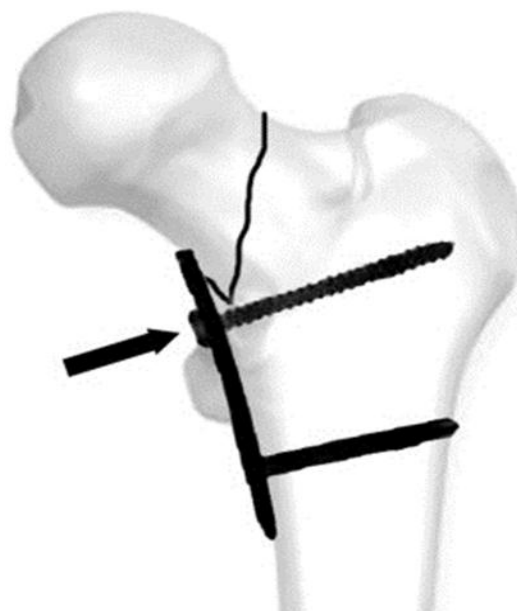


Fig 3 : AP view of vertical femoral neck fracture augmented by medial buttress plate

2. Novel Fixed Angle Femoral Neck Fixation Implants:

This is fixed angle device that consists of short 5-6 holes plate that incorporate three or four cancellous screws proximally in the femoral neck and two distal cortical screw (fig 4) collecting the dynamic compression advantage of DHS and antirotational advantage of cannulated screws⁽⁹⁾.

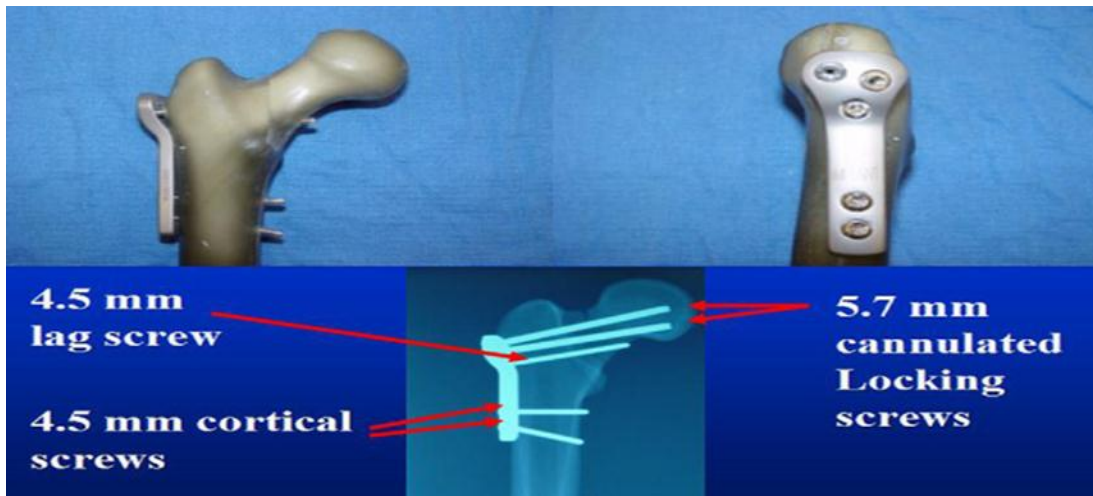


Fig 4: The A–P and lateral views of the proximal femur with the femoral neck locking plate in place are shown to demonstrate construct detail; two 5.7 mm locking head cancellous screws, one transverse 4.5 mm cortical lag screw into the calcar, and two 4.5 mm bicortical screws through the distal two holes of the plate.

3. Cement Augmentation:

This is performed by augmentation of the cannulated screw fixation of femoral neck fracture using polymethyl methacrylate or calcium phosphate cement. A metal catheter is introduced through the lumen of a special screw and about 1 ml of composite is injected under continuous fluoroscopic guidance and the injection is stopped when leakage toward the fracture or joint space, this is usually used in osteoporotic patients⁽¹⁰⁾.

4. Primary valgus osteotomy:

Primary valgus intertrochantric osteotomy Could be done after open reduction of the fracture through

modified Watson-jones approach to add stability if there is high inclination of the fracture.

Method : This is done by passing a blunt retractor at the lesser trochanter and application of closed wedge osteotomy to valgize the the femur by about 20-40° to decrease pauwel angle to become less than 50°. The osteotomy is fixed with four holed dynamic compression plate of proximal femur. after removal of the closed wedge two cancellous 6,5 screws passed through femoral neck, then abduction of the distal femur to close the osteotomy and the femoral shaft is fixed to DCP with cortical 4,5 screws (fig 5). the patient cannot weight bear for 6 weeks then on crutches or a walker and after 10 weeks the patient can completely weight bear⁽¹¹⁾.

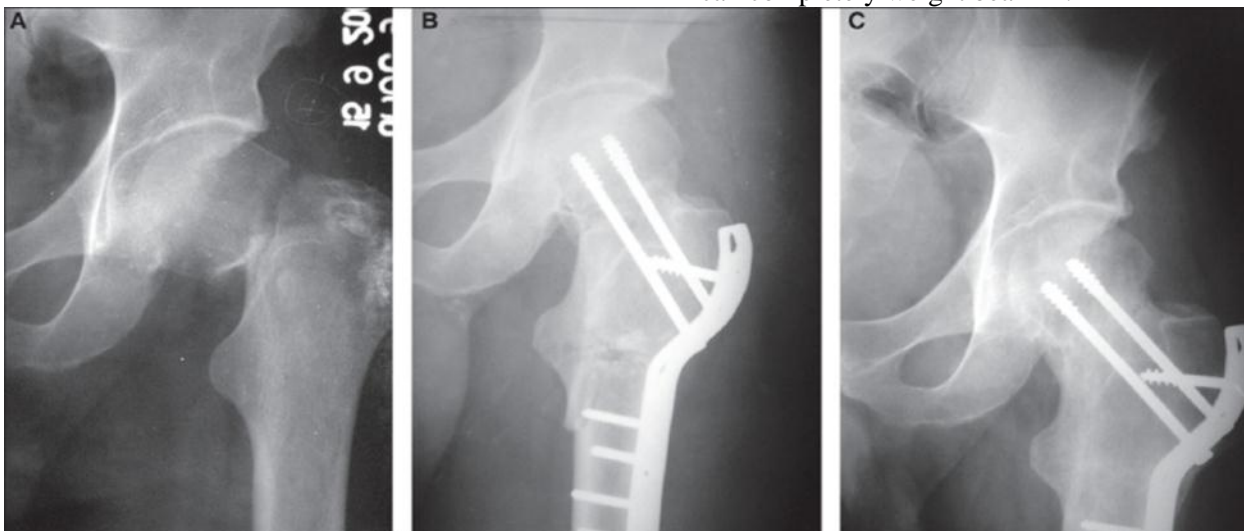


Fig 5: AP view of pre and postfemoral neck fracture augmented by valgus osteotomy

The valgus osteotomy plays a two-fold role: It overcomes the shear forces and converts them to compression forces by placing the fracture site perpendicular to the resultant force, and buttresses the head of femur from below and improves the stability provided by the internal fixation device⁽¹²⁾.

The low incidence of avascular necrosis (8%) may be due to following factors: Osteosynthesis with valgus intertrochanteric osteotomy gives adequate, stable fixation, and The osteotomy may have a biological role in revascularisation of an ischaemic femoral head⁽¹²⁾.

Complications of femoral neck fractures

Nonunion⁽⁴⁾:

- 1) Complicates about 5% of non displaced fracture and about 25% of displaced fracture (shear type vertical fractures).
- 2) usually apparent after 6 months as groin pain ,pain on extention, pain with weight bearing.
- 3) Treatment usually in elderly is arthroplasty but in young ,patient may benefit from proximal femoral valgus osteotomy and cancellous bone graft⁽¹²⁾.

AVN⁽⁵⁾:

- 1) Complicates about 10 % of non displaced fracture and about 30 % of displaced (shear type vertical fracture).
- 2) Usually present as groin, thigh or proximal pain.
- 3) Treatment is guided by symptoms:
 - a) Early without x ray changes: treatment by protected weight bearing and core decompression.
 - b) Late with x ray changes :treatment in elderly by arthroplasty and in young individuals by valgus intertrochntric osteotomy ,arthrodesis or arthroplasty.

Fixation failure⁽¹³⁾:

- 1) Usually in osteoporotic bone and in technical problems (malreduction and poor implant insertion.
- 2) Treatment :by repeat ORIF or prosthetic replacement.

DISCUSSION

1-Achieved union

It is important to compare the results of each method in fixation of femoral neck fracture and to achieve targeted union, the percentage of union was higher in (MP Singh 2008) by achieving union in 92,7% of the cases which were managed by primary valgus osteotomy and fixation with broad dynamic compression plate and mean follow up period was 54 months. The same percentage of union is

achieved in (Frank Liporace 2008) by fixation of unstable neck femur fracture with DHS with mean follow up period 24 months And was lowest in (carlos Roberto schwartsmann 2017) by using DHS in fixation of unstable neck femur fractures by achieving union rate of 73 % and the mean period of follow up was 30 months ,the superiority of application of valgus intertrochantric osteotomy and fixing it by broad DCP over other methods of fixation is noticed as the mean of united rate was 92,7% in (MP Singh 2008) .

2-Complications

This review showed a number of patients with complications with the least rate of AVN was in (S Kumar 2009) with a rate of AVN 5,5% with the use of multiple cannulated screws in fixation of unstable neck femur fractures ,and least rate of non union was in (MP Singh 2008) with a rate of non union 7,3 % with fixation of unstable neck femur fracture using fixed angle device (DCS ,cephalomedullary nail) and the highest rate of AVN was in (carlos Roberto schwartsmann 2017) with rate of AVN 26,4% by using DHS in the fixation and the highest rate of non union was in the same study by the same percentage (26,4%)

In cases treated by primary valgus intertrochntric osteotomy and fixation with broad DCP (MP Singh 2008), there are other complications e.g. shortening in six patients (10,9%) , coxavara in two patients (3.6%), infection in two patients (3,6%) (one of them treated by debridement ,the other developed stiff hip so, the implant had been removed and girdlestonearthroplasty had been done), and delayed osteotomy site healing occurred in one patient (1,8%) and the healing had been completed within 6 months.

Of all patients in the five studies (306 patients), there were 55 patients developed non union (17,9%) , 44 patients developed AVN (14,3%) , six patients developed shortening (1,9%), two patients developed coxavara (0,65%) , three patients developed infection (0,98%) and one patient developed delayed osteotomy site healing (0,3%) in cases treated by valgus intertrochntric osteotomy, that's why the non union is considered the most common complication of fracture neck femur in adults while the least common complication is delayed healing at valgus intertrochntric osteotomy site.

We collected numbers of complicated cases in all mentioned studies as shown in ,and the types

of complications in each study and what was the management method used in the study to treat the complications was mentioned, this showed that in (carlos Roberto schwartsmann 2017) which includes 53 patients , of them 13 patients developed non union (26.4%) and 13 patients developed AVN (26.4%) , in (carlos Roberto schwartsmann 2014) which includes 96 patients , of them 19 patients developed non union (20%) and 16 patients developed AVN (16%) , in (S Kumar 2009) which includes 40 patients , 9 patients developed non union (22.5%) and two patients developed AVN (5.5%) , in (MP Singh 2008) which includes 55 patients , of them 4 patients developed non union (7.3%) , 6 patients developed AVN (11%) , 6 patients developed shortening (11%) , two patients developed coxavara (3,6%) , two patients developed infection (3,6%) and one patient developed delayed osteotomy site healing (1,8%) , in (Frank Liporace 2008) which includes 62 patients , of them 11 patients developed non union (17,7%) , 7 patients developed AVN (11%).

in the study of (carlos Roberto schwartsmann 2017) 26 of 53 cases were complicated ,these 26 complicated cases 13 of them had Avascular necrosis (one of them treated by drilling then observation and the other twelve patient by observation till arthroplasty time, the other 13 patients had non union (one case treated by valgus intertrochntic osteotomy and the other twelve patients treated by THA).

In the study of (carlos Roberto schwartsmann 2014) about 35 of 96 patients experienced complications : 16 patients developed non union ,all are treated by valgus intertrochntic osteotomy and 19 patients developed AVN and all are observed till arthroplasty

In the study of (S Kumar 2009) eleven of 40 patients experienced complications ,nine of them developed non union and treated by valgus intertrochntic osteotomy and two of them developed AVN and treated by observation till arthroplasty time.

In the study performed by (MP Singh 2008) 21 of 55 patients experienced complications: four of them developed non union and treated by THA, six of them developed AVN and treated by observation till time of arthroplasty, six patients developed shortening, two of patients developed coxavara ,one of patients developed delayed union at osteotomy site which took six months to unite and infection occurs in two patients (one of them treated

by debridement ,the other developed stiff hip and treated by girdlestonearthroplasty).

In the study performed by (Frank Liporace 2008) 17 of 62 patients experienced complications :ten patients developed non union (four patients with parallel cannulatedscrews,three patients with crossed- figure screws ,one with DCS ,one with cephalomedullary nail and one septic non union with DHS) and seven developed AVN(five with cannulated screws ,one with DCS and one with cephalomedullary nail)

Three of the nine aseptic non union treated with THA,two are managed by hemiarthroplasty, three initially treated with screw fixation are refixed with fixed angle device (one with DHS, one with DCS and one with cephalomedullary nail) and all are united, one patient initially fixed with DCS is refixed with double angle blade plate and united within 2 months and the one septic non union initially fixed with DHS is treated with resection arthroplasty. Five of the patients developed AVN under went THA finally.

CONCLUSION

Management of unstable neck femur fractures in adults is done by means of direct fixation with cannulated screws, DHS, fixed angle device (DCS or cephalomedullary nail) or osteosynthesis and valgus intertrochntic osteotomy to avoid some adverse effects of the direct fixation methods, so, recent studies showed that valgus intertrochntic osteotomy achieve better results than traditional methods with less complications.

REFERENCES

- 1-Cory A Collinge, Hassan Mir, and Robert Reddix (2014). Fracture Morphology of High Shear Angle “Vertical” Femoral Neck Fractures in Young Adult Patients .J Orthop Trauma, 28 (5):11-22.
- 2-Ly TV, Swiontkowski MF(2008). Instructional Course Lecture: treatment of femoral neck fractures in young adults. J Bone Joint Surg Am. ,900: 2254–2266.
- 3-Haidukewych GJ, Rothwell WS, Jacofsky DJ *et al.* (2004). Operative treatment of femoral neck fractures in patients between the ages of fifteen and fifty years. J Bone Joint Surg Am. ,86:1711–1716.
- 4-Lowe JA, Crist BD, Bhandari M *et al.* (2010). Optimal treatment of femoral neck fractures according to patient’s physiologic age: an evidence-based review. OrthopClin North Am. ,41:157–166.
- 5-Kevin L, Michael B and Cory A(2014). Preoperative Decision Making in the Treatment of High-Angle

- “Vertical” Femoral Neck Fractures in Young Adult Patients. *J OrthopTrauma*, 28: 9.
- 6- Seyit A, HacıBayram T, İsmail A, Mehmet M, Tolga O, Güvenir O (2014).** Influence of number and orientation of screws on stability in the internal fixation of unstable femoral neck fractures. *ActaOrthopTraumatolTurc* .,48(6):673-678.
- 7-Liporace F, Gaines R, Collinge C, Haidukewych GJ (2008).** Results of internal fixation of Pauwels type-3 vertical femoral neck fractures. *J Bone Joint Surg Am* .,90(8):1654-1659.
- 8- Mir H, Collinge C (2015).** Application of a medial buttress plate may prevent many treatment failures seen after fixation of vertical femoral neck fractures in young adults. *Med Hypotheses*,84(5):429-433.
- 9-Nowotarski PJ, Ervin B, Weatherby B, Pettit J, Goulet R, Norris B (2012).** Biomechanical analysis of a novel femoral neck locking plate for treatment of vertical shear Pauwel’s type C femoral neck fractures. *Injury*, 43(6):802-806.
- 10- Frihagen F, Madsen J, Madsen F *et al.* (2007).** screw augmentation in displaced femoral neck fractures ,clinical and histological results using a new composite .*Injury,int.j.care injured* ,38:797-805
- 11- Singh m, Aditya N ,Anil A, Ish K D and Jagjit S (2008).** Unstable recent intracapsular femoral neck fractures in young adults :Osteosynthesis and primary valgus osteotomy using broad dynamic compression plate. *Indian J Orthop* .,42(1):43-48.
- 12- Magua N, Roop S, Rahul M *et al.* (2005).** Osteosynthesis and primary valgus intertrochanteric osteotomy in displaced intracapsular fracture neck of femur with osteoporosis in adults. *Injury, Int. J. Care Injured*, 36: 110—122.
- 13-Gardner ST, Waever MJ, Jerabek SA *et al.* (2012).** Displaced Femoral Neck Fractures in Patients ,60 Years of Age. Conference Presentation: Orthopaedic Trauma Association Annual Meeting; ; Minneapolis, Minnesota. <https://www.ncbi.nlm.nih.gov/pubmed/25972697>
- 14-Carlos R, Henrique M, Leandro D, Ary da Silva U (2017).** Treatment of displaced femoral neck fractures in young patients with DHS and its association to osteonecrosis. *Sociedade Brasileira DE OrtopediaeTraumatologia* ,33:12-15.
- 15-Carlos R, Lucas S, Leandro D *et al.* (2014).** Dynamic Hip Screw for the Treatment of Femoral neck Fractures :A Prospective Study with 96 patients. *ISRN Orthopedics*,45:33-36.
- 16- Kumar S, Bagchi D (2009).** Fractures of the Neck of The Femur – Treated with Multiple Cannulated Screws in Younger Patients –A study of 40 Cases. *The Internet Journal of Orthopedic Surgery*, 18 :1-15.