

Proximal Femoral Nail Vs Prosthetic Replacement for Treatment of Unstable Trochanteric Fractures in Elderly, A Systematic Review

M.R.Hasan, A.S.Rizk, O.M.Esawy and M.A.Abou Omar

Orthopedic Surgery Dept., Faculty of Medicine, Benha Univ., Benha, Egypt

E-Mail: Mohamed222@gmail.com

Abstract

This review was conducted to compare between arthroplasty and proximal femoral nail in fixation of unstable intertrochanteric fractures of elderly patients. Randomized controlled trials and quasi-random studies comparing the results of arthroplasty and proximal femoral nail fixation of unstable intertrochanteric fractures in the elderly published studies from 2010 to 2017. 18 articles were found matching our inclusion criteria. 7 of them were comparative. 11 studies were non-comparative. PFN was with relatively lower post-operative mortality and better functional outcomes PFN establishes itself as a better modality than hemiarthroplasty in unstable intertrochanteric fractures in the elderly. Hemiarthroplasty should ideally be reserved for the patients who have lower life expectancies and require immediate weight bearing and mobilization.

Introduction

As the life expectancy of elderly population has been steadily rising, there is a significant increase in the incidence of hip fractures, it also expected to further rise in the coming decade [1].

The intertrochanteric fractures are extracapsular fractures of proximal femur between the greater and the lesser trochanter of femur, and these fractures are more common in males than females and commonly seen in elderly due to low energy falls in osteoporotic patients or in young due to high energy trauma [1].

These fractures are of two types; stable and unstable according to the presence or absence of posteromedial cortex of femur "calcar femorale" and the treatment strategy is either conservative or operative [2.]

In earlier days these fractures were managed conservatively either by non-rotating boot, Thomas splint, skin traction with weights or upper tibial Steinman pin traction for 6-8 weeks, but nowadays this strategy of treatment is for non ambulatory patients and the patients unfit for surgery with high risk for perioperative mortality.

There are many complications related to prolonged immobilization like deep vein thrombosis, hypostatic pneumonia, pressure sores, dehydration and increased morbidity and mortality, also fracture healing is generally accompanied by varus deformity and shortening of the hip because of the inability of traction to counteract effectively the deforming muscular forces [3].

Intertrochanteric fractures are almost always treated by early internal fixation [treatment of choice] not because they fail to unite with conservative treatment [they unite quite readily] but to obtain best possible position and to get the patient up and walking as soon as possible and thereby reducing the complications associated with prolonged recumbency.

Intertrochanteric fractures could be treated operatively either by dynamic hip screw, dynamic condylar screw, proximal femoral locked plate, proximal femoral nail, prosthetic replacement or by external fixator in high risk patients [4].

Many surgeons used to use the dynamic hip screw and the dynamic condylar screw in treatment of intertrochanteric fractures as they allow dynamic intrafracture compression and are of low cost, but these techniques increase blood loss during surgery and are not advisable in unstable fracture patterns because it may result in collapse, limb shortening and varus deformity [5.]

Many surgeons prefer the use of proximal femoral nail in the treatment of unstable intertrochanteric fractures as it is percutaneous approach with minimal blood loss but due to the rising incidence of trochanteric fractures and its common association with osteoporosis [6].

A need for a viable alternative to internal fixation of trochanteric fractures with intramedullary nails has thus arisen and prosthetic replacement has been noted to give acceptable results in many studies. Primary prosthetic replacement for comminuted, unstable intertrochanteric fractures has yielded up to 94% good functional results in limited series [7, 8].

The short term advantages seemed to give a significant advantage to the elderly in terms of outcome, but long term complications need to be studied and taken into account due to the increase in life expectancy over world [9,10].

The aim of this work is to perform a systematic review comparing the results of patients with unstable trochanteric fractures of femur managed by internal fixation using proximal femoral nail and those treated with prosthetic replacement regarding radiological and functional outcome, complications, compliance and patients satisfaction in light of evidence based medicine.

2. Material and method

Randomized controlled trials and quasi-random studies comparing the results of arthroplasty and proximal femoral nail fixation of unstable intertrochanteric fractures in the elderly published studies from 2010 to 2017. Also non-comparative studies were included according to our inclusion criteria.

All the articles relevant to the subject were be selected according to the following inclusion and exclusion criteria .

Inclusion criteria

- Clinical human studies
- Studies on the treatment of unstable intertrochanteric fractures of femur either by the proximal femoral nail or the prosthetic replacement
- Studies reporting post-operative radiographic data at least with two years follow up
- English language studies Over the years 2010-2017

Exclusion criteria

- Cadaveric studies
 - Non-human studies
 - Book chapters
 - Conference posters
 - Studies with no post-operative clinical or radiographic parameters
- Elderly patients with unstable intertrochanteric fractures.

Surgical treatment of the fractures with arthroplasty or proximal femoral nail.

References of each included study were screened to find similar studies matching inclusion criteria.

Two reviewers independently searched the following databases and J.,s: The Cochrane Library, PubMed, science direct, clinical key, bone and joint J., [Br], J., of bone and joint surgery [Am] and other orthopaedic J.,s with the key words: trochant*, intertrochant*, extracapsular, femoral nail, proximal femoral nail, trochanteric fractures, hemiarthroplasty, intertrochanteric, pertrochanteric .

We used the medical subject headings [the MeSH database]. We included only English articles.

3. Results

After searching data basis, total search results reached 4786 articles.

Final included studies were 18 studies

18 articles were found matching our inclusion criteria. 7 of them were comparative. 11 studies were non-comparative. 5 studies investigated PFN and 6 studies investigated BPH for fixation of unstable intertrochanteric fractures.

This systematic review included 1534 patients, 697 for BPH and 837 for PFN. Male patients were 566 [36.9%] and female patients were 833 [54.3%].

Follow up period ranged between 24 and 58.8 months. Mean age of patients was from 60 years and 85 years maximally.

The results of methodological quality of each study are as follows

In this systematic review, every study was assessed according to risk of bias Random sequence generation

[selection bias], Allocation concealment [selection bias], Blinding of participants and personnel [performance bias], Blinding of outcome assessment [detection bias], Incomplete outcome data [attrition bias], and Selective reporting [reporting bias].

We have summarized reported bias in every study in the final pages of this study.

Randomization and allocation concealment fulfillment method was reported, blinding of outcome assessors and loss of follow up.

Inclusion and exclusion criteria statement, matching of both groups in demographic data, experience of surgeons and conflict of interest.

Detailed results of the included studies regarding different types of bias. Operative details include length of surgery in minutes, operative blood loss in milliliters and number of patients received blood transfusion. Length of surgery in minutes:

This was reported in 5 comparative studies. Mean operative length was measured in minutes. Length of surgery in minutes was significantly lower in PFN group [p <0.001].

Range of operative mean time was 47-63.3 min in PFN group. In arthroplasty group it was between 53-71 min. So, operative time was lower significantly in PFN than arthroplasty in both comparative and noncomparative studies.

Among the included studies, range of blood loss was between 136.5 ml and 567 ml maximally in arthroplasty group. In PFN group range was 30.6-142.3 ml which is lower than arthroplasty group [p <0.001].

The mean difference in quantity of peri-operative blood loss between arthroplasty and proximal femoral nail was [MD 172.59, 95% CI 170.62 to 174.56; participants = 489; studies = 3].

Tang et al., the only study that mentioned quantity of blood transfusion as the following. Arthroplasty group had a higher volume of blood transfusion.

Total reported cases was 8 [2.81%] in arthroplasty group compared with 11 cases [2.86%] in PFN group. Statistically, No difference between both interventions in pressure sores rate.

Park et al., and Tang et al., reported Chest complications in their patients. [OR 0.39, 95% CI 0.09 to 1.76; participants = 356; studies = 2. No difference between both interventions.

Rate of thromboembolic complications was higher in arthroplasty group and total reported cases was 12 [3.47%] in arthroplasty group compared with 11 cases [1.79%] in PFN group.

Total reported cases with superficial wound infection was 18 [3.23%] in arthroplasty group compared with 21 cases [3.51%] in PFN group. Rate of superficial wound infection was near equal in both groups of intervention.

Ahmed et al., Bassiony et al. {Bassiony, 2013 #1}, Celiktas et al. {Celiktas, 2015 #2} and Choy et al., {Choy, 2010 #3} mentioned that no cases complicated by deep wound infection.

Total reported cases with complications was 80/585

[13.68%] in arthroplasty group compared with 135/737 cases in PFN group. Rate of complications was higher in PFN group.

This was reported in 6 comparative studies [OR 0.79, 95% CI 0.47 to 1.33; participants = 699; studies = 6; I2 = 24%]. No difference was found after meta-analysis.

Hospital stay ranged between 5.3-40 days in arthroplasty group compared with 6.8-37.8 days in PFN group.

This was reported in 5 comparative studies. [MD -0.66, 95% CI -0.89 to -0.43; participants = 566; studies = 5]. Sensitivity analysis was done. Sahoo et al. was excluded. Meta-analysis revealed higher duration of hospital stay in arthroplasty.

Total reported cases with urinary tract infection was 4/248 [1.61%] in arthroplasty group compared with 10/561 cases [1.78%] in PFN group. Rate of complications was not different in both groups.

Park et al., the only study that mentioned number of patients with UTI and neurological complications as the following. Tang et al.2015 mentioned no cases of UTI.

Total reported cases with cardiovascular complications was 7/248 [1.61%] in arthroplasty group compared with 14/561 cases [1.78%] in PFN group. Rate of complications was not different in both groups.

Harris Hip Scores at 3 months range of means between 61-80.5 in arthroplasty group. In PFN group range was 45.24-68.89. PFN group had a lower HHS at 3 months.

Harris Hip Score at 3 months was reported in 3 comparative studies. [MD 11.17, 95% CI 5.18 to 17.16; participants = 177; studies = 3]

Ahmed et al., 2012 [BPH] reported Harris hip score

at 3, 6, 12 and at the end of the study as 61, 67, 75 and 78.19 respectively.

Harris Hip Score at 12 months

Harris Hip Scores at 12 months range of means between 68.44-83.25 in arthroplasty group. In PFN group range was 72.4-75.9. PFN group had a lower HHS at 12 months but with no statistical significance [p.=0.78].

Harris Hip Score at 12 months was reported in 3 comparative studies.

[MD 0.84, 95% CI -5.14 to 6.83; participants = 177; studies = 3]

Harris Hip Scores at the end of the study range of means between 68.6-85 in arthroplasty group. In PFN group range was 72.4-83.01. Arthroplasty group had a higher HHS at the end of the study [p. <0.001].

Harris Hip Score at the end of the study was reported in 5 comparative studies [MD -4.23, 95% CI -7.14 to -1.32; participants = 613; studies = 5].

Total reported cases with mortality was 71/454 [15.64%] in arthroplasty group compared with 89/522 cases [17.05%] in PFN group.

Rate of mortality was higher in PFN group.

Total reported cases with reoperation was 15/391 [3.84%] in arthroplasty group compared with 28/563 cases [4.97%] in PFN group.

Reoperation rate was higher in PFN group.

Reoperation rate was reported in 6 comparative studies [OR 0.59, 95% CI 0.28 to 1.22; participants = 699; studies = 6]. With no significant difference between both interventions.

Celiktas et al., 2015[BPH] reported VAS score as 5.15 ± 1.39, 1.48 ± 1.54 and 1.46 ± .54 for pre-operative, 1 and 2 years respectively.

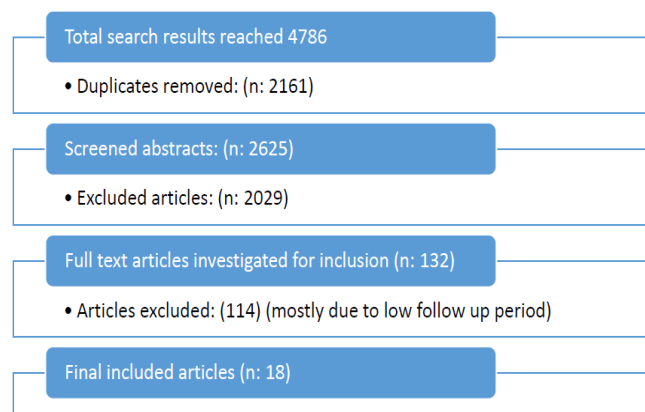


Fig (1) Flow chart of the study

Table (1) Characteristics of included studies.

Authors	Year	Type of procedure	No of patients	Male	female	Follow up	Mean-Age in years
Choy et al., [11]	2010	BPH	40	8	32	24 months	79
Sancheti et al., [12]	2010	BPH	37	10	27	24.5 months	77
Ahmed et al., [13]	2012	BPH	41	19	22	24 months	65

Table (1) Continue

Bassiony et al., [14]	2012	BPH	30	10	20	24 months	66
Karthik et al., [15]	2012	BPH	28	9	19	4.2 y	79
Landeroinis et al., [16]	2012	PFN	102	27	75	24 months	85
Wang et al., [17]	2012	THR	40	14	26	48.8 months	73
		BPH	72	27	45	39.9 monthes	77
Kashigar et al., [18]	2014	PFN	77	15	62	4.9 y	78
Celiktas et al., [19]	2015	BPH	54	15	39	31 months	81
Desteli et al., [20]	2015	BPH	44	27	15	24 months	60
		PFN	42	26	16		
Görmeli et al., [21]	2015	BPH	65	NA	NA	30 months	77
		PFN	68	NA	NA		
Ozkayin et al., [22]	2015	BPH	33	10	23	31.72	82
		PFN	21	9	13	months	
Park et al., [23]	2015	BPH	22	4	18	24 months	78
		PFN	31	12	19		
Sahoo PK et al., [24]	2015	BPH	35	16	19	24 months	73
		PFN	35	17	18		
Tang et al., [25]	2015	BPH	156	86	70	39.9 months	82
		PFN	147	73	71		
Yamak et al., [26]	2015	PFN	152	67	85	24 months	76
Singh et al., [27]	2017	PFN	23	9	14	24 months	82
Zhang et al., [28]	2017	PFN	139	53	86	38.8 months	79

PFN: Proximal Femoral Nail, THR: Total Hip Replacement, BPH: Bipolar Hemi bias were shown in Fig (2 ,3).

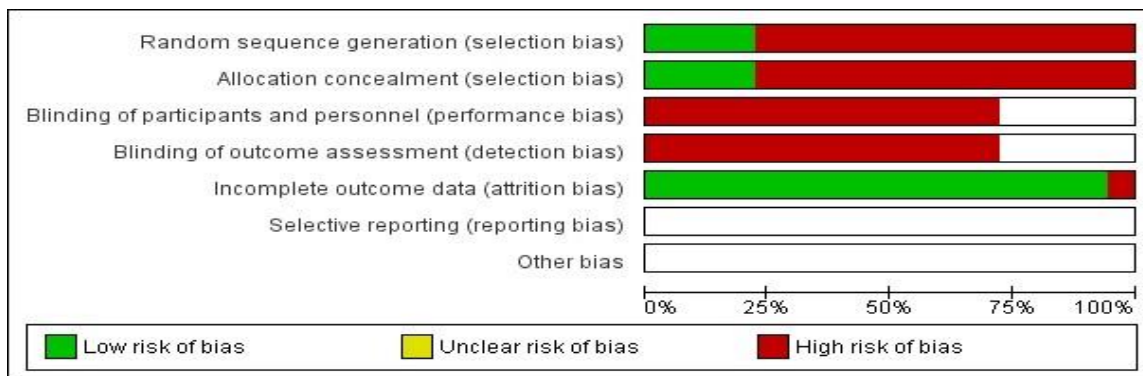


Fig (2) Risk of bias graph: review authors' judgments about each risk of bias item presented as percentages across all included studies.




Fig (3) Risk of bias summary: review authors' judgments about each risk of bias item for each included study.

4. Discussion

This review was conducted to compare between arthroplasty and proximal femoral nail in fixation of unstable intertrochanteric fractures of elderly patients.

It included randomized controlled trials and quasi-random studies comparing the results of arthroplasty and proximal femoral nail fixation of unstable intertrochanteric fractures in the elderly published studies from 2010 to 2017. Also non-comparative studies were included according to our inclusion criteria.

18 articles were found matching our inclusion criteria. 7 of them were comparative. 11 studies were non-comparative. 5 studies investigated

PFN and 6 studies investigated BPH for fixation of unstable intertrochanteric fractures. This systematic review included 1534 patients, 697 for BPH and 837 for PFN. Male patients were 566 [36.9%] and female patients were 833 [54.3%]. Table 4. And Figure 55. Follow up period ranged between 24 and 58.8 months. Mean age of patients was from 60 years and 85 years maximally.

Duration of surgery

This was reported in 5 comparative studies. Mean operative length was measured in minutes. Length of surgery in minutes was significantly lower in PFN group [$p < 0.001$].

The Mean duration of surgery for Arthroplasty was more than PFN group in all studies except in Park et al., 2015 who did not find any difference in the surgical times between the OR-IF BHA groups [23]. They explained that by attributable to the longer amounts of time required to prepare patients with fractures on a surgical table and to perform reduction, even though the actual amount of time taken between incision and suture was short.

Peri-operative blood loss

Among the included studies, range of blood loss was between 136.5 ml and 567 ml maximally in arthroplasty group. In PFN group range was 30.6-142.3 ml which is lower than arthroplasty group [$p < 0.001$]. this was reported in all studies included in our meta analysis.

Using cement is even more difficult in unstable intertrochanteric fracture accompanied by comminution of the posteromedial buttress, exceeding a simple lesser trochanteric fragment or those with subtrochanteric extension; since this can result in larger amount of blood loss and longer operation times.

Blood transfusion

Tang et al., 2012 the only study that mentioned quantity of blood transfusion as the following. Arthroplasty group had a higher volume of blood transfusion [25].

This finding agreed with the mean of blood loss in both groups as Arthroplasty is associated with more blood loss.

Also Tang et al., 2012 reported that the the PFNA had superiorities in anaesthesia, short operation time, blood loss, and so less amount of blood transfusion [25].

Thromboembolic complications

Total reported cases was 12 [3.47%] in arthroplasty group compared with 11 cases [1.79%] in PFN group. Rate of thromboembolic complications was higher in arthroplasty group but with no statically significance.

Bassiony et al., 2013 who used BPH technique reported that the technique adopted allowed safe and early weight bearing on the injured hip and had a relatively low rate of complications. As most of the patients were out of bed on an average of 3 days postoperatively, there were neither chest complications nor thromboembolic complications [14].

Wound infection

Total reported cases with superficial wound infection was 18 [3.23%] in arthroplasty group compared with 21 cases [3.51%] in PFN group. Rate of superficial wound infection was near equal in both groups of intervention. According to deep infection this was reported in 7 comparative studies [OR 0.89, 95% CI 0.21 to 3.84; participants = 699; studies = 7; I² = 21%]. No difference was found after meta-analysis. No significant difference was found by meta-analysis.

There's no difference between the two groups about superficial wound infection. In all studied groups, superficial wound infection represented a small problem and successfully treated by topical and systematic antibiotics for 2 weeks.

Hospital stay

Hospital stay ranged between 5.3-40 days in arthroplasty group compared with 6.8-37.8 days in PFN group. Meta-analysis revealed higher duration of hospital stay in arthroplasty.

Karthik et al., 2012 reported that patients who regain their independence have significantly lower mortality rates [15]. In this elderly cohort of patients with various comorbidities, it is difficult to maintain compliance with partial weight bearing. This obviously prolongs the duration of hospital stay in these patients and potentially predisposes them to further falls. In addition, they need regular outpatient follow-up to assess fracture healing, osteonecrosis and implant position.

Harris score

Harris Hip Scores at the end of the study range of means between 68.6-85 in arthroplasty group. In PFN group range was 72.4-83.01. Arthroplasty group had a higher HHS at the end of the study [$p < 0.001$].

This finding explains why many surgeons prefer arthroplasty for the treatment of unstable trochanteric fractures in the elderly according to Choy et al., 2012 who used arthroplasty and reported mean 80.6 ± 9.3 Harris hip score at the end of two years follow-up

period [11].

Mortality rate

Total reported cases with mortality was 71/454 [15.64%] in arthroplasty group compared with 89/522 cases [17.05%] in PFN group. Rate of mortality was higher in PFN group.

Early mobilization is of particular importance for these patients as it might decrease the risk of mortality according to Celiktas et al.,2015 although older patients are unable to walk soundly enough and are only capable of partial weight-bearing in the postoperative period following internal fixation methods.

Sancheti et al.,2010 reported that delay in surgery is an important predictor for mortality in patients with proximal femur fracture and also of the postoperative morbidity Therefore, many researchers have shown interest in arthroplasty in trochanteric fractures [12].

As the new intramedullary fixation allowed for immediate postoperative full weight bearing rehabilitation, negative results gradually prevailed and the use of hemiarthroplasty for intertrochanteric fractures was rather controversial, even for those patients with advanced age and serious osteoporosis.Sahoo et al.,2015 found hemiarthroplasty was not an advantageous alternative to internal fixation due to its shorter survival and higher mortality; the only advantage of hemiarthroplasty was earlier weight bearing [25].

5. Conclusion

Our study found that PFNA has a significant superiority over hemiarthroplasty in the treatment of intertrochanteric fractures in elderly patients in the operative statistics, but no significant differences in the functional outcome at short follow-up were observed. No significant differences were found statistically regarding complications, but mortality was higher in PFNA group.

Limitations to this review

Lack of Randomized controlled trials, high risk of bias in the included studies and incomplete outcome data in some studies. Detailed bias was illustrated in Fig (2) and Fig (3).

References

- [1] I.Weller, "The effect of hospital type and surgical delay on mortality after surgery for hip fracture." *Bone & Joint J.*, Vol.87.3,PP.361-366,2005.
- [2] Lindskog, M.Dieter, "Unstable intertrochanteric hip fractures in the elderly." *JAAOS-J.*, of the American Academy of Orthopaedic Surgeons 12.3 [2004], 179-190.
- [3] Jain, Rina, Antoni Basinski, "Nonoperative treatment of hip fractures." *International orthopaedics*.Vol. 27.1 ,PP.11-17.2003.
- [4] Kesmezacar, Hayrettin, "Treatment of intertrochanteric femur fractures in elderly patients: internal fixation or hemiarthroplasty." *Acta orthopaedica et traumatologica turcica*.Vol.39 (4) ,PP.287-294,2005.
- [5] M. J.Parker, G. A. Pryor. "Gamma versus DHS nailing for extracapsular femoral fractures." *International orthopaedics*.Vol. 20(3), PP.163-168,1996.
- [6] Yadav, Sidharth, V.Anil Golhar, "Management of unstable intertrochanteric fracture by proximal femoral nail." *J.*, of Evolution of Medical and Dental Sciences.Vol. 3(15) ,PP. 4084-4103,2014.
- [7] Jolly, Angad, "Comparison of complications and functional results of unstable intertrochanteric fractures of femur treated with proximal femur nails and cemented hemiarthroplasty." *J.*, *Clinical Orthopaedics and Trauma* ,2017.
- [8] P.Bonnevialle, "Trochanteric locking nail versus arthroplasty in unstable treintertrochanteric fracture in patients aged over 75 years." *Orthopaedics & Traumatology: Surgery & Research*.Vol. 97(6) ,PP.S95-S100,2011.
- [9] A.Thakur, M. Lal. "Cemented Hemiarthroplasty in Elderly Osteoporotic Unstable Trochanteric Fractures using Fracture Window." *Malaysian orthopaedic J.*, 10.1 ,2016.
- [10] Y. T. Liang, "Clinical research of hemiprosthesis arthroplasty for the treatment of unstable intertrochanteric fractures in elderly patients." *Zhonghua yi xue za zhi.*,Vol. 85(46) ,PP.3260-3262,2005.
- [11] W.S.Choy, Cementless bipolar hemiarthroplasty for unstable intertrochanteric fractures in elderly patients. *Clinics in orthopedic surgery*.Vol. 2[4],PP. 221-226,2010.
- [12] K.Sancheti, Primary hemiarthroplasty for unstable osteoporotic intertrochanteric fractures in the elderly: A retrospective case series. *Indian J.*, *orthopaedics*.Vol.44(4),PP. 428,2010.
- [13] Ahmed, Elmorsy, Saied Mahmoud, Zaied Mahmoud, "Primary bipolar arthroplasty in unstable intertrochanteric fractures in elderly." *Open J.*, *Orthopedics* , 2012.
- [14] A.A.Bassiony, M.K. Asal, Cemented calcar replacement hemiarthroplasty for unstable intertrochanteric fracture femur in elderly.Vol. 48[2],PP.190. patients. *The Egyptian Orthopaedic J.*,, 2013.
- [15] K.Karthik, Unstable trochanteric fractures in elderly osteoporotic patients: role of primary hemiarthroplasty. *Orthopaedic surgery*,Vol.4(2), PP. 89-93. 2012
- [16] E.S.Landvoisin, Proximal femoral nail antirotation [PFN-ATM] fixation of extracapsular proximal femoral fractures in the elderly: retrospective study in 102 patients. *Orthopaedics & Traumatology: Surgery & Research*.Vol. 98(3), PP. 288-295, 2012.
- [17] L.Wang K Fan, X.Dang, Comparison between bipolar hemiarthroplasty and total hip arthroplasty

- for unstable intertrochanteric fractures in elderly osteoporotic patients. *PLoS One*.Vol. 7[6] ,2012.
- [18] A.Kashigar, Predictors of failure for cephalomedullary nailing of proximal femoral fractures. *The bone & joint J.*, Vol. 96(8).PP, 1029-1034,2014.
- [19] M.Celiktas, E. Togrul, O. Kose, Calcar preservation arthroplasty for unstable intertrochanteric femoral fractures in elderly. *Clinics in orthopedic surgery*.Vol. 7(4),PP. 436-442,2015.
- [20] Desteli, E.Engin, " Quality of life following treatment of trochanteric fractures with proximal femoral nail versus cementless bipolar hemiarthroplasty in elderly ". *Clinical and Investigative Medicine*,PP. E63-E72,2015.
- [21] Gormeli, Gokay, "Comparison of femur intertrochanteric fracture fixation with hemiarthroplasty and proximal femoral nail systems." *Turkish J., of Trauma and Emergency Surgery* ,Vol.21.6 ,PP. 503-508,2015.
- [22] N. Özkayın, G.Okçu, K.Aktuğlu, Intertrochanteric femur fractures in the elderly treated with either proximal femur nailing or hemiarthroplasty: A prospective randomised clinical study. *Injury*, Vol. 46, ,PP.S3–S8,2015.
- [23] Park, Bong-Ju, Hong-Man Cho, Woong-Bae Min. "A comparison of internal fixation and bipolar hemiarthroplasty for the treatment of reverse oblique intertrochanteric femoral fractures in elderly patients." *Hip & pelvis*.Vol. 27(3) ,PP.152-163,2015.
- [24] Sahoo, K.Prafulla, "Cemented bipolar hemiarthroplasty versus proximal femoral nails: a prospective comparative outcome analysis in unstable elderly intertrochanteric fractures,2015.
- [25] Tang, Peifu, "Proximal femoral nail antirotation versus hemiarthroplasty: a study for the treatment of intertrochanteric fractures." *Injury* .Vol.43(6) ,PP. 876-881,2012.
- [26] K. Yamak, Ş. Koyuncu, T .Altay, C. Kayalı, F. Ozan, Mechanical failures after fixation with proximal femoral nail and risk factors. *Clin Interv Aging*. Dec ,Vol.17(10), PP.1959-65, 2015.
- [27] M.Singh, A.R. Magrath, P.S. Maini, "Changes in the trabecular Pattern of the upper end of the femur as an index of osteoporosis ". *J. Bone Joint Surg*.Vol. 52A, PP. 457-467, 1970.
- [28] P.X .Zhang, J.B.Ju, B.G. Jiang, Hip Replacement as Alternative to Intramedullary Nail in Elderly Patients with Unstable Intertrochanteric Fracture: A Systematic Review and MetaAnalysis. *Orthop Surg*.Vol. 11(5), PP. 745-754,2019.