

## Peri-Operative Pain Management for Cleft Lip Repair in Children, Bilateral Infraorbital Nerve Block Versus Combined Intravenous Fentanyl with Peri-Incisional Infiltration. A Randomized Comparative Study

M Elsonbaty, Mohamed Maher, Ahmed Reda, Khaled Sarhan

Anesthesia Department, Faculty of Medicine, Cairo University

\*Corresponding author: M Elsonbaty, Mobile: (+20) 01111110126, Email: jijsonbaty@yahoo.com

### ABSTRACT

**Background:** The good control of postoperative pain has an important impact on the patient as regards his general condition, wound healing and hospital stay. Regional nerve blocks and systemic analgesics especially opioids offered this control but with superiority of the regional block due to avoidance of the side effects of opioids. The assessment of pain in pediatrics is difficult, as they usually do not have the ability to describe their pain. Pediatric patients undergoing cleft lip repair can benefit from nerve blocks related to the lip. Different types of analgesia were described, such as bilateral infraorbital nerve block (IONB), pharmacological analgesics and surgical site infiltration.

**Objective:** To compare the effect of bilateral infraorbital nerve block with conventional methods (IV fentanyl and peri-incisional infiltration) as a proper perioperative pain management in children undergoing cleft lip (CL) repair operation. **Patients and Method:** Seventy-six children, scheduled for cleft lip repair, were enrolled in this study in Cairo University Pediatric Hospital (Abu El Reesh). The patients were randomly assigned into two groups: Group infraorbital nerve block IONB (n=38): received bilateral infraorbital nerve block. Group conventional (n= 38): received IV fentanyl with surgical site infiltration. Patients in both groups received general anesthesia and our interventions were performed after induction of anesthesia and before skin incision. **Results:** This study demonstrated that the use of bilateral IONB in children undergoing cleft lip repair was accompanied by superior levels of intraoperative and postoperative analgesia as compared to the use of IV fentanyl with surgical site infiltration in the same population. This difference was evidenced by significantly less need for postoperative rescue analgesia as well as lower pain scores up to 24 hours postoperative in the IONB group. **Conclusion:** This study results indicate that bilateral ION block is simple, safe and technically easy to perform with good postoperative analgesia.

**Keywords:** Regional block, Perioperative analgesia, Infraorbital block, Cleft lip.

### INTRODUCTION

Cleft lip (CP) is very common congenital anomaly that require surgical correction <sup>(1)</sup>. After correction, these children experience severe post-operative pain. Complications of the surgery can be airway obstruction and respiratory complications. Administration of analgesia during and after surgery increases the risk of airway obstruction and affects impairment of ventilatory control. Cleft lip is mainly painful for the first 24-48 hours after surgery. Morphine is one of the common medications used for pain relief after surgery, thus, a 24-hour stay in the recovery room or ICU is often necessary. There is a growing awareness of the need for the complete well-being of the child after CL repair in the postoperative period and not just a pain-free state and reduced postoperative hospital stay <sup>(2,3)</sup>.

Anesthesia and other negative complications that opioids produce do not help achieve this goal. Local anesthesia combined with nerve block appears to be the solution in such circumstances. Local and general anesthesia techniques are considered to be complementary. This is indicated in pediatrics when local anesthesia is performed under general anesthesia.

The combination of the two techniques has dramatically decreased the risks of both procedure <sup>(4)</sup>. **Hodges et al.** <sup>(5)</sup> while reviewing anesthesia for cleft surgeries found that opioids are better to be avoided, and intraoperative and postoperative analgesia can be achieved by local both infiltration with local anesthetics or by giving nerve block. There is a lack of consensus and evidence concerning both techniques of intraoperative and postoperative analgesia strategies for cleft lip in repair children. Cochrane systematic review about infraorbital nerve block for postoperative analgesia (2016) concluded that: "The evidence of infraorbital nerve block either with lignocaine or bupivacaine may reduce postoperative pain more than placebo, is very low in comparing to intravenous analgesia in children undergoing cleft lip repair". Studies with larger samples and standardized observation time used to measure outcomes were needed <sup>(6)</sup>.

The hypothesis is the regional or local nerve block has good nerve block in addition no effect on systemic condition nor respiratory depression. The aim of this work was to compare the effect of bilateral infraorbital nerve block with conventional methods (IV fentanyl and peri-incisional infiltration) as a proper



This article is an open access article distributed under the terms and conditions of the Creative Commons Attribution (CC BY-SA) license (<http://creativecommons.org/licenses/by/4.0/>)

perioperative pain management in children undergoing CL repair operation.

**Ethical approval:** The study was conducted after Cairo University Research Committee approval and clinical trial number NCT04614259.

## PATIENTS AND METHODS

A single blind prospective randomized comparative trial. The study was conducted in Children Hospital of Cairo University (Abu El-Reesh Hospital) on 76 children aged from 6 months to 3 years presented for cleft lip (CL) primary corrective surgery at Children Hospital of Cairo University. Patient were divided into two equal groups; group C (n=38) conventional group and group S (n=38) infraorbital nerve block group.

**Inclusion criteria:** pediatric patients with ASA physical status I-II., age 6 months to 3 years, scheduled to undergo correction for cleft lip repair, and both genders were eligible for study.

**Exclusion criteria:** Parents refusal, bleeding disorders as platelets count < 100.000 ,or INR >1.5, no previous wound or skin lesion at the site of need insertion, comorbidities as congenital heart disease, lung pathology or CNS disorders, children posted for combined procedures like CL correction with palatoplasty, and known hypersensitivity to local anesthetics or opioids.

Pediatrics who enrolled in the study were randomly assigned into two groups. The randomization method was done by computer-generated numbers and concealed by serially numbered, opaque and sealed envelopes. The details of the series were unknown to the investigators and the group assignment was kept in asset of sealed envelopes each bearing only the case number on the outside. Before the surgery, the appropriate numbered envelopes were opened by the nurse, the card inside determined the patient' group. All children were assessed clinically, and investigations were done to exclude any of exclusion criteria mentioned above. Laboratory works needed were complete blood count (CBC), prothrombin time and concentration and partial thromboplastin time.

One hour before, the children were pre-medicated with IM midazolam 0.1 mg/kg. After insertion of IV cannula the child was given atropine 0.01 mg/kg, dexamethasone 0.15 mg/kg and ondansetron 0.15 mg/kg, then full intraoperative monitoring in form of Non-invasive blood pressure, electrocardiography, oxygen saturation and rectal temperature were continuously monitored intraoperatively. Baseline blood pressure, heart rate and O<sub>2</sub> saturation were measured just before the induction of anesthesia as the baseline parameters.

Using inhalational induction with sevoflurane, atracurium and fentanyl, mechanical ventilation was started using pressure-controlled ventilation and end-tidal carbon dioxide was adjusted between 30 and 35 mmHg, anesthesia was maintained with isoflurane and atracurium. All pediatric patients were injected diclofenac sodium 0.5 mg/kg IM. After endotracheal intubation, both blood pressure and heart rate were measured 5 minutes and every 15 minutes until full recovery from the general anesthesia then every 15 min in the PACU for 30 minutes. In group S, locating the infraorbital foramina at the floor of orbit at the level of the pupil, the finger is placed externally (extra oral) at the level of the infraorbital foramen and the upper lip was folded back to prevent the needle to proceed cephalic to avoid insertion in the globe of the eye. To ease the insertion through the buccal mucosa, A 27-gauge needle was bent about 70 degree and introduced over the maxillary process, towards the infraorbital foramen.

The local anesthetic was injected (injection of 3 ml 0.25% bupivacaine in 1:200.000 adrenaline, 1.5 ml on each side) after careful aspiration<sup>(7)</sup>.

As there is loose adventitious tissue that can lead to swelling and ecchymosis, pressure was needed to be applied for one minute to the area of injection. In group C, after intubation the child was given 1 mcg/kg IV fentanyl and the local anesthetic (1.5 ml on each side 0.25% bupivacaine in 1:200.000 adrenaline) were injected as peri-incisional infiltration.

In both groups of patients, if the analgesia obtained was inadequate in the form of increase in the heart rate or mean arterial blood pressure more than 20% of baseline values in response to surgical stimulus or thereafter through the whole operation warrants the administration of an additional dose of IV fentanyl (0.5 mcg/kg) with maximum dose 2 mcg/kg. Anesthesia was discontinued at the conclusion of the surgery and all were extubated using standard extubation criteria. Wake-up time after the discontinuation of anesthesia was recorded. The pediatric patients were transferred to the post-anesthesia care unit (PACU). The quality of analgesia was assessed immediately postoperative and then at 4, 8, 12, 16, 20 and 24 hours postoperatively using CHEOPS pain score<sup>(8)</sup>. All patients received postoperative paracetamol (IV) 15 mg/kg every 8 hours.

Morphine IV was given as rescue doses (0.01 mg/kg) in all patients if CHEOPS pain score was more than 6. Then the assessment was repeated after 20 minutes. If the score was still more than 6 another dose was given and so on with maximum dose of 0.05 mg/kg/4 hours) and they were kept under close observation till discharging from the hospital<sup>(9,10)</sup>.

**Study outcomes:**

**I. Primary outcome:** Total rescue doses of morphine IV over 24 hours postoperatively used in each group.

**II. Secondary outcomes:**

1. Hemodynamic parameters (heart rate, systolic, diastolic and mean arterial blood pressures) were recorded preoperatively and every 15 minutes till the end of the surgery.
2. Total doses of intraoperative fentanyl required.
3. The awakening time.
4. Time to feed (the time taken for the child to tolerate milk feeding after trial of water first without swallowing difficulty).
5. Incidence of peri-operative adverse events.
6. Pain assessment immediately postoperative and then 4, 8, 12, 16, 20 and 24 hours postoperatively using CHEOPS pain score (Children Hospital Eastern Ontario Pain Scale) is based on 6 criteria: Crying, facial expression, child verbal expression, torso (body position), touching or grabbing at wound and leg position.

Criterion 1 is given a score of 1-3. The criterion 2 and 3 are given a score of 0-2. The criterion 4, 5 and 6 are given a score of 1-2. This score is making the worst score is 13 while the least score is 4, a total score equal or less than 6 indicates adequate analgesia.

**Sample size:**

Power analysis was performed using G power program on the overall dose of intravenous morphine after 48 hours. For independent samples using student test because it was the main outcome variable in the present study. A previous study has reported that the mean±SD of morphine requirement 48 hours post-operative in nerve block group 139.6 (95.3) microgram/kg versus 279.7 (204.69) for conventional group <sup>(11)</sup>, for a power of 0.96 and an alpha error of 0.05. A minimum sample size of 35 patients was calculated for each group. A sample size was increased to 38 in each group to compensate for drop out.

**Statistical analysis**

Continuous variables that are normally distributed were reported as mean with standard deviation, while those that were not normally distributed were reported as a median with interquartile range (IQR). Categorical data were presented as a number (percentage). Categorical data were analyzed using Chi square (X<sup>2</sup>) test or Fisher's exact test as appropriate. Continuous data were analyzed using unpaired t-test. The Statistical Package of Social Science software program (SPSS), version 20 (Chicago,

IL, USA) was used for all statistical comparisons. P value of ≤ 0.05 is considered statistically significant.

**RESULTS**

Seventy-six patients were recruited to undergo operative treatment for cleft lip. Patients were divided into two groups. Group S received infraorbital nerve block (IONB) and group C received IV fentanyl and surgical site infiltration with bupivacaine. Patients in both groups were comparable about demographic data where there was no significant difference (Table 1).

**Table (1):** Demographic data are presented as mean ± standard deviation.

	Group C	Group S	P value
<b>Age/Months</b>	15.79 ± 4.9	16.34 ± 5.4	0.64
<b>Male gender (%)</b>	60.5	65.8	0.812
<b>Weight /kg</b>	11.68 ± 1.63	11.58 ± 1.85	0.79

Group C: conventional group, Group S: IONB group.

The intra-operative heart rate readings showed no significant difference compared to baseline except one reading (after 30 minutes). While the systolic, diastolic and mean arterial blood pressures preoperatively and intraoperatively showed that, they were comparable in both groups.

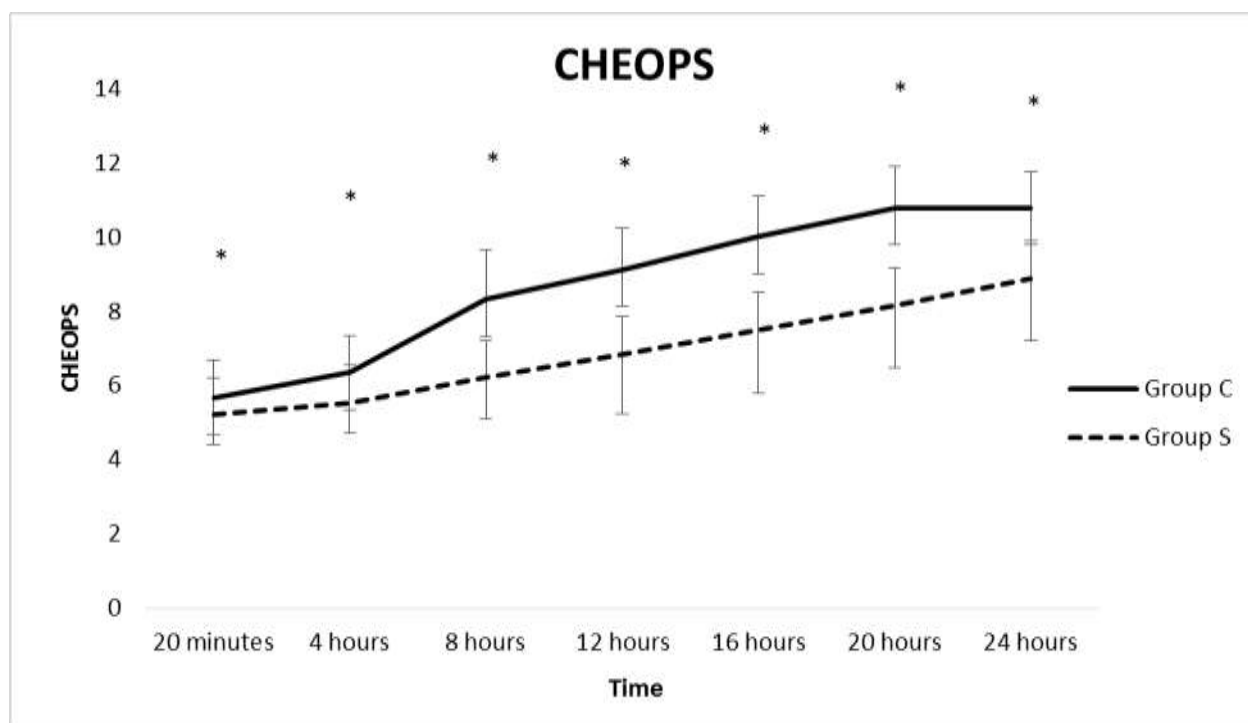
In group C, 84.22% of children required additional IV fentanyl, while in group S, only 7.9% required additional doses of fentanyl (P value < 0.001\*).

Morphine consumption in group C was significantly higher than in group S, while time to morphine rescue doses was much longer than group S (Table 2).

**Table (2):** The rescue analgesia consumption and time to requirement in both groups. Data is represented as mean and SD, \*denotes significance.

	Group C	Group S	P value
<b>Morphine consumption (mg/kg)</b>	0.55 ± 0.01	0.03 ± 0.02	<0.001*
<b>Time to morphine requirement (hours)</b>	5.86 ± 3.8	13.1 ± 8.3	<0.001*

CHEOPS scale was significantly lower in group S than in group C after 20 minutes, 4, 8, 12, 16 and 24 hours postoperatively (Figure 1).



**Figure (1):** The CHEOPS score for the two groups during the first 24 hours post-operatively. Group C: conventional group, Group S: IONB group, \*: identifies significant difference between both groups.

The awakening time and post-operative first time of feeding (hours) did not differ significantly in both groups.

There were no recorded complications in both groups either intra- or post-operatively in the form of intravascular injection, local anesthetic toxicity, temporary or permanent nerve damage, infection or allergy to any of the preparations used, post-operative desaturation, laryngospasm and post-operative nausea or vomiting.

## DISCUSSION

Cleft lip repair is associated with severe pain that is difficult to assess and treat in the postoperative period. It is desirable that active analgesia be used in these patients not only to improve patient comfort but also to encourage oral administration to maintain the child's hydration state. It may also reduce crying, which is a factor that has been assumed to increase the risk of postoperative bleeding. Various treatment methods have been used to reduce or relieve pain after cleft lip repair. These include opioids, paracetamol, anti-inflammatory drugs (NSAIDs), and various nerve blocks. However, sedative medications may not provide adequate analgesia and have side effects such as respiratory depression and bleeding<sup>(12)</sup>.

Various techniques for perioperative analgesia have been described for cleft lip surgery. Two studies compared infraorbital nerve block with anesthetic infiltration of the cleft<sup>(13-14)</sup>. Three studies compared infraorbital nerve block and intravenous analgesia<sup>(15-17)</sup> and three studies compared infraorbital nerve block to

placebo<sup>(18-20)</sup>. Despite all these studies, there is a lack of consensus and evidence concerning the best technique for intraoperative and postoperative analgesia strategies for cleft lip in repair children due to nonuniform design, small sample size and high risk of bias of the above studies. More studies with larger samples and standardized observation time and the instruments used to measure outcomes were needed<sup>(21)</sup>.

Our study reported that time to first request of rescue morphine analgesic was significantly longer in the block group compared to the conventional group and the total consumption of postoperative morphine was significantly lower in the block group compared to the conventional group. This is in agreement with **Prabhu et al.**<sup>(14)</sup> who enrolled 30 children aged 4-20 months scheduled for cleft lip repair into a group with a bilateral infraorbital nerve block with 0.125% bupivacaine with 1: 200 000 adrenaline, 2 ml on each side, and another group peri-incisional infiltration with the same volume and dose of local anesthetic. All patients in the infiltration group required rescue analgesics within the first 24 hours, whereas only 13% of patients in the block group required rescue analgesics. However, the time to first request of rescue analgesic was not reported in this study.

Comparing CHEOPS for the two groups 20 minutes and then at 4, 8, 12, 16, 20 and 24 hours post-operatively, significantly lower scores were recorded in group S. **Gaonkar et al.**<sup>(13)</sup> studied the efficacy of

preoperative bilateral infra-orbital block with 0.25% bupivacaine-adrenaline versus peri-incisional infiltration with 0.25% bupivacaine-adrenaline (1:200000) in 50 pediatric patients undergoing cleft lip repair. The post-operative pain relief scoring was comparable in both groups. However, the duration of analgesia was longer in the block group than the infiltration group. While, **Prabhu et al.** <sup>(14)</sup> found that pain relief score was higher in the infiltration groups for up to 8 hours postoperatively.

**Rajamani et al.** <sup>(16)</sup>, enrolled 82 children aged 3 months to 10 years undergoing cleft lip repair randomized to one of two groups: bilateral infraorbital nerve block or IV fentanyl and bilateral infraorbital injection of 1 ml saline as control. They used the children and infants. Postoperative pain scale (CHIPPS). 82.9% in block group had adequate analgesia compared to 36.6% in fentanyl group. In this study they suffered from an important limitation, which is the choice of fentanyl, a relatively short acting opioid could have adversely influenced the analgesia duration in fentanyl group.

Our results do not agree with **Simion et al.** <sup>(17)</sup> who enrolled 46 infants scheduled for primary cleft lip repair into one of two groups (fentanyl intravenous injection versus the infraorbital nerve block). The neonatal infant pain score (NIPS) did not differ between the two groups. However, they only assessed the postoperative pain score for only one hour.

We reported no significant difference in the intraoperative heart rate values and blood pressure values between the two groups. This result is in line with **Gaonkar et al.** <sup>(13)</sup>, **Ahuja et al.** <sup>(18)</sup> and **Takmaz et al.** <sup>(20)</sup>. However, **Prabhu et al.** <sup>(14)</sup> concluded that the group of infraorbital nerve block had significantly lower heart rates and diastolic blood pressures than the infiltration group throughout the intraoperative period. However, the systolic blood pressure in both groups raised significantly from the baseline after induction of anesthesia but no statistical difference in the intraoperative systolic blood pressure was noted between both groups, the same as our study showed.

No significant difference in the feeding time, volumes or quality of feeding was detected in our study. On the contrary, **Simion et al.** <sup>(17)</sup> reported that the block group might have some difficulty in feeding in the immediate postoperative period in the PACU. However, this conclusion was based on subjective assessment only. In **Rajamani et al.** <sup>(16)</sup> study, the time to feeding was significantly shorter by approximately 10 min in the block group than the fentanyl group, although the clinical significance of this duration is debatable.

A recent 2016 Cochrane systematic review evaluated the effects of infraorbital nerve blocking for

postoperative pain after cleft lip repair in children <sup>(5)</sup>. None of the eight included trials reported any significant difference in the incidence of intraoperative or postoperative complications between study groups, and there were no documented adverse events associated with infraorbital nerve block such as localized hematoma, infection or nerve injury. This aligns with our study that did not report any complications in the IONB group either during or after surgery.

Our study had some limitations as the subjectivity of assessing pain specially in pediatric population. Future studies should also stratify children by age group.

## CONCLUSION

At the start of cleft lip correction surgery, injection of 0.25% bupivacaine for bilateral infraorbital nerve block aiming for peri-operative pain relief, is a simple, safe and effective analgesic method with high success rates, providing good analgesia alone for at least 12 hours. This technique has minimal complication rates, greater parental satisfaction, and also decreases rescue analgesic consumption without increase in side effects.

## REFERENCES

1. **Tremlett M (2004):** Anaesthesia for cleft lip and palate surgery. *Curr Anaesth Crit Care*, 15: 309–16.
2. **Doyle E, Hudson I (1992):** Anesthesia for primary repair of cleft lip and cleft palate: a review of 244 procedures. *Paediatr Anaesth.*, 2: 139–145.
3. **Takemura H, Yasumoto K, Toi T et al. (2002):** Correlation of cleft type with incidence of perioperative respiratory complications in infants with cleft lip and palate. *Paediatr Anaesth.*, 12: 585–588.
4. **Mitchell B, Sharma R (2009):** Embryology, an illustrated colour text. 2nd edition. Churchill Livingstone, Elsevier, Pp. 182.
5. **Feriani G, Hatanaka E, Torloni M et al. (2016):** Infraorbital nerve block for postoperative pain following cleft lip repair in children. *Cochrane Database of Systematic Reviews*, 4:16-226.
6. **Bosenberg A, Kimble F (1995):** Infraorbital nerve block in neonates for cleft lip repair: anatomical study and clinical application. *Br J Anaesth.*, 74: 506–508.
7. **Frank L, Greenberg C, Stevens B (2000):** Pain assessment in infants and children. *Pediatr Clin North Am.*, 47: 487-512

8. **Suresh S, Barcelona S, Young N *et al.* (2002):** Postoperative pain relief in children undergoing tympanomastoid surgery: is a regional block better than opioids? *Anesth Analg.*, 94: 859– 862.
9. **Engelhardt T, Steel E, Johnston G *et al.* (2003):** Tramadol for pain relief in children undergoing tonsillectomy: a comparison with morphine. *Paediatr Anaesth.*, 13: 249–252.
10. **Fenlon S, Somerville N (2007):** Comparisons of codeine phosphate and morphine sulphate in infants undergoing cleft palate repair. *Cleft Palate Craniofac J.*, 44: 528–531
11. **Chiono j, Raux O, Bringuier S *et al.* (2014):** Bilateral Suprazygomatic Maxillary Nerve Block for Cleft Palate Repair in Children. *Anesthesiology*, 120: 1362-9.
12. **Choi S, Lee W, Lee S (2008):** Parent – controlled analgesia in children undergoing cleft palate repair. *J Korean Med Sci.*, 23: 122–125.
13. **Gaonkar V, Daftary S (2004):** Comparison of preoperative infraorbital block with peri-incisional infiltration for postoperative pain relief in cleft lip surgeries. *Indian Journal of Plastic Surgery*, 37 (2): 105–9.
14. **Prabhu K, Wig J, Grewal S (1999):** Bilateral infraorbital nerve block is superior to peri-incisional infiltration for analgesia after repair of cleft lip. *Scandinavian Journal of Plastic and Reconstructive Surgery and Hand Surgery*, 33 (1): 83–7.
15. **Delgado J, Martínez-Tellería A, Cano M *et al.* (2005):** Postoperative analgesia for the management of cheiloplasty in the breastfed baby. Comparative study: bilateral intraoral blockade of the infraorbital nerve with bupivacaine 0.25% plus adrenaline versus intravenous analgesia with tramadol (Analgesia postoperatoria en la queiloplastia dellactante. Estudio comparativo: bloqueo infraorbitario intraoral bilateral con bupivacaína 0,25% con adrenalina vs. analgesia intravenosa con tramadol). *Revista de la Sociedad Española del Dolor.*, 12 (4): 204–10.
16. **Rajamani A, Kamat V, Rajavel V *et al.* (2007):** A comparison of bilateral infraorbital nerve block with intravenous fentanyl for analgesia following cleft lip repair in children. *Paediatric Anaesthesia*, 17 (2): 133–9.
17. **Simion C, Corcoran J, Iyer A *et al.* (2008):** Postoperative pain control for primary cleft lip repair in infants: is there an advantage in performing peripheral nerve blocks? *Paediatric Anaesthesia*, 18 (11): 1060–5.
18. **Ahuja S, Datta A, Krishna A *et al.* (1994):** Infra-orbital nerve block for relief of postoperative pain following cleft lip surgery in infants. *Anaesthesia*, 49 (5): 441–4.
19. **Nicodemus H, Ferrer M, Cristobal V *et al.* (1991):** Bilateral infraorbital block with 0.5% bupivacaine as post-operative analgesia following cheiloplasty in children. *Scandinavian Journal of Plastic and Reconstructive Surgery and Hand Surgery*, 25 (3): 253–7.
20. **Takmaz S, Uusal H, Uysal A *et al.* (2009):** Bilateral extraoral, infraorbital nerve block for postoperative pain relief after cleft lip repair in pediatric patients: a randomized, double-blind controlled study. *Annals of Plastic Surgery*, 63 (1): 59–62.