
EFFECT OF GARCINIA CAMBOGIA AND ST. JOHN'S WORT (HYPERICUM PERFORATUM) EXTRACTS ON OBESITY IN MALE RATS

By
Reham A. Arafat

Nutrition and Food Sciences Department
Faculty of Home Economics
Helwan University

Research Journal Specific Education
Faculty of Specific Education
Mansoura University

ISSUE NO. 44, OCTOBER. 2016

مجلة بحوث التربية النوعية - جامعة المنصورة
العدد الرابع والأربعون - أكتوبر ٢٠١٦

EFFECT OF GARCINIA CAMBOGIA AND ST. JOHN'S WORT (HYPERICUM PERFORATUM) EXTRACTS ON OBESITY IN MALE RATS

*Reham A. Arafat**

Abstract

This study was conducted to assess the effect of *Garcinia Cambogia* and *H. Perforatum* extracts on Obesity in male rats. The experiment was performed in 35 mature male rats distributed into 5 equal groups. Group (1) was kept as a normal control (fed on a basal diet), while rats of the other four groups were fed on a high-fat- diet for 6 weeks to induce obesity. Rats of the group (2) were left as a control positive (obese) and those of groups (3), (4) and (5) were orally given *Garcinia Cambogia* and *H. Perforatum* and their mixture in a dose of 400 mg/kg B.wts., respectively, for 4 weeks. At the end of the experiment, all rats were sacrificed and blood samples were collected for estimating serum liver enzymes such as aspartate aminotransferase (AST) , alanine aminotransferase (ALT) , Alkaline phosphatase (ALP), total cholesterol (TC), triglycerides (TG) and lipoprotein fractions as well as blood urea nitrogen (BUN), uric acid and creatinine concentrations. Estimation of serum levels of thyroxin, insulin and leptin as well as histopathology of liver and kidneys were also carried out. The results showed that the two herbs extract and their mixture were significantly decreased serum levels of AST, ALT, ALP, TC, TG, LDL-c ,BUN and uric acid concentrations as well as decreased leptin level , on the other hand, it increased levels of thyroxin, insulin as well as alleviated the histopathological changes which seen in the liver and kidneys of obese rats. In conclusion, intake of *Garcinia Cambogia* and *H. Perforatum* may be useful in the treatment of obesity and for patients who suffer from hyperlipidemia .

Keywords: *Garcinia Cambogia*, St. John's Wort, Liver enzymes, kidney function, Lipid profile, Hormones, Histopathology.

* Nutrition and Food Sciences Department, Faculty of Home Economics, Helwan University

Introduction

Obesity is now the most prevalent nutritional disease and a growing public health problem worldwide. The disease has acquired epidemic proportions projected to reach 2.3 billion of overweight adults and 700 million obese adults, respectively, by 2015 (**Malik et al., 2013**). Obesity is often associated with dyslipidemia, cardiovascular risks, hypertension and type 2 diabetes mellitus and has recognized as one of the most serious public health problems (**Barness et al., 2007**).

Excessive intake of fatty acids leads to an accumulation of triglyceride in many tissues, particularly in the fat tissue, in which lipolysis is increased. The increased levels of fatty acids in the circulatory system to facilitate the uptake of fatty acids in peripheral tissue through the induction of fatty acid binding and transport proteins (e.g., FABP and CD36) (**Atshaves et al., 2010**). The exaggerated availability and deposition of free fatty acids induce lipotoxicity and insulin resistance in peripheral tissues (**Samuel et al., 2010**). Furthermore, a high concentration of free fatty acids contributes to triglyceride accumulation in the liver. Prolonged and repeated accumulation of triglyceride in the liver increases the possibility of inflammation, hepatocellular necrosis, and fibrosis (**Farrell and Larter, 2006**). In addition, obesity aggravates the course of many primary renal diseases such as glomerulonephritis and also impairs renal function (**Guebre-Egziabher et al., 2013**).

Numerous drugs have been approved for the treatment of obesity; however, most of them have been withdrawn from the market because of their serious adverse effects, leaving only Orlistat, a lipase inhibitor (**Powell et al., 2011**). Therefore, many studies have been conducted to find and develop the new anti-obesity drugs, or dietary supplements through the use of medicinal plants that could minimize the side effects (**Yun, 2010** and **Lim et al., 2012**).

Garcinia gummi-gutta (L.) Roxb. or the Malabar tamarind, commonly known by its previous scientific name *Garcinia Cambogia* (Gaertn.) Desr. (Clusiaceae), is native to Southeastern Asia. The fruit rind is

commonly used as a food preservative, flavoring agent or food-bulking agent (Roy *et al.*, 2003), and as a traditional remedy to treat constipation, piles, rheumatism, edema, irregular menstruation and intestinal parasites in many Asian countries (Tharachand and Avadhani, 2013). Earlier phytochemical reports on the plant led to the isolation of various organic acids, benzophenones (Kumar *et al.*, 2009) and xanthenes (Inuma *et al.*, 1998) as major constituents and numerous scientific studies have indicated biological activity such as anti-obesity (Kim *et al.*, 2008), hypolipidaemic (Altiner *et al.*, 2012) and anticancer activity (Mazzio and Soliman, 2009) amongst numerous others.

Hypericum Perforatum, also called as St. John's wort (SJW) is distributed in Europe, Asia, North Africa and North America. *Hypericum Perforatum* has been known for a long time for its putative medicinal properties including wound-healing (Ozturk *et al.*, 2007), anti-inflammatory (Sosa *et al.*, 2007), diuretic, antibiotic and antiviral (Medina *et al.*, 2006), antidepressant (Chatterjee *et al.*, 1998) and nootropic activity (Kumar *et al.*, 2000). Principle constituents reported from SJW include the naphodianthrones hypericin and pseudohypericin, a broad range of flavonoids, including quercetin, quercitrin, Amentoflavone and Hyperin, the phloroglucinols hyperforin and adhyperforin, essential oils and xanthenes (Nahrstedt and Butterweck, 1997). Flavonoids like quercetin have proved antidiabetic potent (Coskun *et al.*, 2005).

The present study was carried out to investigate the effect of *Garcinia Cambogia* and *H. Perforatum* extracts on Obesity in male rats.

Materials and Methods

Materials

Plant:

Dried leaves of *Garcinia Cambogia* and *H. Perforatum* were purchased from Haraz market for Herbs and Medicinal Plants, Cairo, Egypt.

Rats:

Thirty-five male albino rats (Sprague-Dawley strain) weighting 160 ± 5 g were obtained from the Laboratory Animal Colony, Helwan, Egypt. The rats were kept under controlled hygienic conditions in plastic cages and fed on the basal diet for one week before starting the experiment.

Biochemical Kits:

Biochemical kits were obtained from Gama Trade Company, Dokki, Egypt.

Methods:

Preparation of the basal diet:

The basal diet was prepared according to the recommended dietary allowances for rats (American Institute of Nutrition, AIN) adjusted by **Reeves *et al.*, (1993)**. Basal diet consisted of 14 % casein, 10 % sucrose, 5 % corn oil, 0.25% choline chloride, 1% vitamin mixture (**Campbell, 1963**), 3.5 % salt mixture (**Hegsted *et al.*, 1941**), 5% fiber and the remainder were corn starch up to 100 %.

Preparation of plants extract:

Leaves of *Garcinia Cambogia* and *H. Perforatum* were finely grounded into a fine powder using a mechanical grinder. Each dried plant (10 g) was extracted twice with 100 ml of 50% methanol in distilled water. The pooled extracts were filtered and concentrated at 40 ° C using a rotary evaporator under low pressure. The residue was freeze-dried in a lyophilizer and stored at -20°C until used (**Kanchana and Nuannoi , 2012**).

Induction of obesity:

Experimental obesity was induced by feeding rats for 6 weeks on the high fat diet, which supplies 45% calories from fat (lard). A 4- to 6-week HFD feeding is sufficient to induce obesity, according to the method of (**Bhatt *et al.*, 2006**). This model in rats resembles closely the reality of obesity in human.

Experiment and grouping of rats:

Thirty- five mature male Sprague-Dawley rats were housed in a well-ventilated animal room under controlled hygienic conditions of 24°C temperature, 50% relative humidity, and 12 h light/12 h dark cycles. After acclimatization, rats were randomized into 5 groups of 7 rats each. Group (1) was fed on basal diet and kept as a normal control, while the other four groups were fed on a high-fat diet containing 45% fat from hog fat (lard) for 6 weeks to induce obesity. Group (2) was left as a positive control (obese) and rats of groups(3), (4) and (5) were orally administered the extract of *Garcinia Cambogia* and *H. Perforatum* and their mixtures in a dose of 400 mg/kg B.wts., respectively ,once daily for 4 weeks. At the end of the experiment, B.wts of rats was recorded, and rats were then euthanized by prolonged exposure to ether anesthetic. The abdomen was opened, and body fats, including mesenteric, visceral, epididymal and retroperitoneal fats were carefully dissected out and total fat mass was weighed. The adiposity index (Ad. I) was calculated by dividing total body fat mass by B.wts. and multiplied by 100 (Ad. I = fat weight [F.wt]/B.wt × 100) as described by **Pichon *et al.*, (2006)**. Blood samples were collected for serum biochemical analyses. Liver and kidneys of the sacrificed rats were preserved in 10% formalin solution till processed for histopathological examination.

Biochemical analyses:

Serum liver enzymes aspartate and alanine aminotransferase (AST and ALT) were chemically determined according to (**Bergmeyer *et al.*, 1978**) and alkaline phosphatase (ALP) was estimated according to (**Roy ,1970**). Serum total cholesterol was calorimetrically determined according to (**Richmond , 1973**) and triglycerides were estimated according to (**Friedewald *et al.*, 1972**). Atherogenic index (**Kumari *et al.*, 1995**) and high-density lipoprotein cholesterol (HDL) (**Richmond ,1973**) was chemically determined using specific diagnostic kits and measured using a spectrophotometer. Low-density lipoprotein (LDL) cholesterol was calculated according to **Friedewald *et al.*, (1972)**. Blood urea nitrogen was determined using biomeriuex kits according to the method of (**Patton and**

Crouch, 1977). Serum uric acid was determined using the enzymatic colorimetric method as described by (**Fossati *et al.*, 1980**). Serum creatinine concentrations were colorimetrically determined by Jaffe reaction , (**Husdan and Rapoport ,1968**). Concentrations of thyroxin (T4) and insulin were estimated by specific antibody radioimmunoassay kits according to the methods described by (**Patrono and Peskar, 1987**) and (**Yallow and Bauman, 1983**), respectively. Leptin was measured using enzyme-linked immunosorbent assay (ELISA) according to (**Xiong *et al.*, 2010**).

Histopathological examination:-

Liver and kidneys of the sacrificed rats were taken and immersed in 10% formalin solution. The fixed specimens were then trimmed, washed and dehydrated in ascending grades of alcohol. Specimens were then cleared in xylol, embedded in paraffin, sectioned at 4-6 microns thickness and stained with Haematoxylin and Eosin stain for histopathological examination as described by **Carleton, (1979)**.

Statistical analysis:

Statistical analysis was carried out using Statistical Package for the Social Sciences (SPSS) for Windows, version 20 (SPSS Inc., Chicago, IL, USA). Collected data were presented as a mean± standard deviation (SD). Analysis of Variance (ANOVA) test was used for determining the significances among different groups according to **Armitage *et al.*, (2002)**. All differences were considered significant if $P < 0.05$.

Results

Feeding of rats on HFD for 6 weeks significantly ($P < 0.05$) increased B.wt., body fat mass weight (F.wt) and Ad. I when compared to negative control rats fed on the basal diet. Oral administration of *Garcinia Cambogia* ,*H. Perforatum* and mixture of both herbs in a dose of 400 mg/kg B.wt., given to obese rats for 4 weeks induced significant decreases in B.wt, F.wt, and Ad.I when compared to the positive control group as shown in Table 1.

Table (1): The effects of alcoholic extracts of *Garcinia Cambogia* ,*H. Perforatum* and mixture of both herbs on body weight (B.wt), fats weight (F.wt) and adiposity index (Ad.I) in obese rats.

Groups	B. wt (g)	F. wt (g)	Ad. I (%)
G.1 Negative control (Normal rats)	200.0±4.4c	5.58±0.12c	2.79±0.10d
G.2 Positive control (Obese rats)	295.21±4.5a	14.55±0.22a	4.93±0.15a
G.3 <i>Garcinia Cambogia</i> (400 mg/kg b.wt.)	240.32±1.2b	7.34±0.13b	3.05±0.14b
G.4 <i>H. Perforatum</i> (400 mg/kg b.wt.)	245.22±2.5b	7.60±0.10b	3.19±0.12b
G.5 <i>Garcinia Cambogia</i> (200 mg/kg b.wt.) + <i>H. Perforatum</i> (200 mg/kg b.wt.)	235.45±1.5bc	6.81±0.10c	2.89±0.18c

Data are presented as means ± standard deviation, (n = 7 for each group) Values with different superscripts within the column are significantly different at P< 0.05. Values with similar or partially similar superscripts are non-significant.

Rats fed on HFD for 6 weeks had significant (P < 0.05) increases in serum levels of liver enzymes AST, ALT, and ALP when compared with negative control rats. Alcoholic extracts of *Garcinia Cambogia* ,*H. Perforatum* and mixture of both herbs in a dose of 400 mg/kg B.wt., when orally given to obese rats significantly (P < 0.05) lowered the highest serum levels of AST, ALT and ALP enzymes when compared to the positive control group, as illustrated in Table 2.

Table (2): The effects of alcoholic extracts of *Garcinia Cambogia* ,*H. Perforatum* and mixture of both herbs on serum levels of aspartate aminotransferase (AST), alanine aminotransferase (ALT) and alkaline phosphatase (ALP) in obese rats.

Groups	AST (U/L)	ALT (U/L)	ALP (U/L)
G.1 Negative control (Normal rats)	63.62 ± 1.8 c	37.15 ± 1.6 c	86.59 ± 1.9 c
G.2 Positive control (Obese rats)	92.45 ± 2.1 a	60.57 ± 2.4 a	118.41 ± 1.2 a
G.3 <i>Garcinia Cambogia</i> (400 mg/kg b.wt.)	70.83 ± 2.1 b	45.78 ± 2.8 b	96.32 ± 2.8 b
G.4 <i>H. Perforatum</i> (400 mg/kg b.wt.)	71.65 ± 2.3 b	46.32 ± 2.6 b	99.71 ± 2.5 b
G.5 <i>Garcinia Cambogia</i> (200 mg/kg b.wt.)+ <i>H. Perforatum</i> (200 mg/kg b.wt.)	63.98 ± 2.4 c	39.12 ± 2.2 c	88.53 ± 2.2 c

Data are presented as means ± standard deviation, (n = 7 for each group) Values with different superscripts within the column are significantly different at P< 0.05. Values with similar or partially similar superscripts are non-significant.

As demonstrated in Table 3, feeding of rats on HFD for 6 weeks produced significant (P < 0.05) increases in serum levels of TC and TG when compared to rats fed on the basal diet. *Garcinia Cambogia*, *H. Perforatum* and mixture of both herbs in a dose of 400 mg/kg B.wt., when given orally to obese rats significantly lowered the high levels of serum TC and TG, when compared to the positive control group.

Table (3): The effects of alcoholic extracts of *Garcinia Cambogia*, *H. Perforatum* and mixture of both herbs on serum levels of total cholesterol (TC) and triglycerides (TG) in obese rats.

Groups	TC (mg/dL)	TG (mg/dL)
G.1 Negative control (Normal rats)	101.98 ± 1.56 b	55.43 ± 1.5 b
G.2 Positive control (Obese rats)	119.95 ± 3.95 a	70.32 ± 1.9 a
G.3 <i>Garcinia Cambogia</i> (400 mg/kg b.wt.)	104.26 ± 4.43 b	59.85 ± 1.4 b
G.4 <i>H. Perforatum</i> (400 mg/kg b.wt.)	104.92 ± 5.45 b	60.31 ± 1.1 b
G.5 <i>Garcinia Cambogia</i> (200 mg/kg b.wt.)+ <i>H. Perforatum</i> (200 mg/kg b.wt.)	100.62 ± 4.34 b	57.50 ± 1.2 b

Data are presented as means ± standard deviation, (n = 7 for each group) Values with different superscripts within the column are significantly different at P< 0.05. Values with similar or partially similar superscripts are non-significant.

Feeding of rats on HFD for 6 weeks significantly (P < 0.05) decreased serum HDL and increased both LDL, VLDL, and At. I, when compared to negative control rats. Oral administration of *Garcinia Cambogia*, *H. Perforatum* and mixture of both herbs in a dose of 400 mg/kg B.wt., to obese rats induced a significant (P < 0.05) increase in serum HDL and decreased LDL, VLDL, and At. I, when compared with the positive control groups as depicted in Table 4.

Table (4): The effects of alcoholic extracts of *Garcinia Cambogia*, *H. Perforatum* and mixture of both herbs on serum levels of lipoprotein fractions (HDL-c, LDL-c, and VLDL-c) and At. I in obese rats.

At. I LDL-c/HDL-c	VLDL-c (mg/dL)	LDL-c (mg/dL)	HDL-c (mg/dL)	Groups
0.689	11.09± 1.9 b	37.07 ± 1.6 c	53.82 ± 1.8 a	G.1 Negative control (Normal rats)
1.316	14.06 ± 3.7 a	60.16 ± 1.4 a	45.73 ± 2.1 b	G.2 Positive control (Obese rats)
0.776	11.97± 1.5 b	40.34 ± 1.8 b	51.95 ± 1.3 b	G.3 <i>Garcinia Cambogia</i> (400 mg/kg b.wt.)
0.817	12.06 ± 2.8 b	41.76 ± 1.2 b	51.10 ± 2.1 b	G.4 <i>H. Perforatum</i> (400 mg/kg b.wt.)
0.685	11.50 ± 1.2 b	36.22 ± 1.6 c	52.90 ± 2.4 b	G.5 <i>Garcinia Cambogia</i> (200 mg/kg b.wt.)+ <i>H. Perforatum</i> (200 mg/kg b.wt.)

Data are presented as means ± standard deviation, (n = 7 for each group) Values with different superscripts within the column are significantly different at P < 0.05. Values with similar or partially similar superscripts are non-significant.

Feeding rats on a high-fat -diet (HFD) for 6 weeks caused significant (P < 0.05) increases in urea nitrogen, uric acid, and creatinine compared to the negative control group. Oral administration of an alcoholic extract of *Garcinia Cambogia*, *H. Perforatum* and mixture of both herbs in a dose of 400 mg/kg B.wt., to obese rats for 4 weeks significantly (P < 0.05) decreased the elevated serum levels of urea nitrogen uric acid and creatinine when compared with the positive control group, (Table 5).

Table (5): The effects of alcoholic extracts of *Garcinia Cambogia*, *H. Perforatum* and mixture of both herbs on serum levels of blood urea nitrogen (BUN), uric acid (UA) and creatinine (Cr) concentrations in obese rats.

Cr (mg/dL)	UA (mg/dL)	BUN (mg/dL)	Groups
1.25 ± 0.02b	1.22 ± 0.05 c	15.9 ± 0. 41 c	G.1 Negative control (Normal rats)
1.39 ± 0.02 a	2.28 ± 0.02 a	24.2 ± 0. 63 a	G.2 Positive control (Obese rats)
1.28 ± 0.01 b	1.38 ± 0.05 b	19.8 ± 0. 31 b	G.3 <i>Garcinia Cambogia</i> (400 mg/kg b.wt.)
1.29 ± 0.03 b	1.40 ± 0.05 b	20.5 ± 0. 25 b	G.4 <i>H. Perforatum</i> (400 mg/kg b.wt.)
1.27 ± 0.03 b	1.28 ± 0.07 c	17.3 ± 0. 11 c	G.5 <i>Garcinia Cambogia</i> (200 mg/kg b.wt.)+ <i>H. Perforatum</i> (200 mg/kg b.wt.)

Data are presented as means ± standard deviation, (n = 7 for each group) Values with different superscripts within the column are significantly different at P < 0.05. Values with similar or partially similar superscripts are non-significant.

Data in Table 6 showed that rats fed on HFD for 6 weeks had a significant (P < 0.05) increase in leptin hormone and decreases in both T4 and insulin serum levels when compared to the negative control group. Alcoholic extract of *Garcinia Cambogia*, *H. Perforatum* and mixture of both herbs when orally given in a dose of 400 mg/kg B.wt., to obese rats for 4 weeks significantly (P < 0.05) decreased leptin hormone and increased T4 and insulin serum levels when compared with the positive control group.

Table (6): The effects of alcoholic extracts of *Garcinia Cambogia*, *H. Perforatum* and mixture of both herbs on serum levels of free thyroxine (T4), insulin and leptin hormones in obese rats.

Leptin (ng/ml)	Insulin (µU/ml)	Free T4 (µg/dL)	Groups
30.0 ± 1.2 b	69.49 ± 0.86 a	4.50 ± 0.09 a	G.1 Negative control (Normal rats)
42.7 ± 1.4 a	44.58 ± 1.11 b	2.15 ± 0.03 c	G.2 Positive control (Obese rats)
33.6 ± 0.9 b	66.35 ± 2.16 a	3.65 ± 1.79 b	G.3 <i>Garcinia Cambogia</i> (400 mg/kg b.wt.)
33.9 ± 1.3 b	66.16 ± 1.78 a	3.77 ± 1.32 b	G.4 <i>H. Perforatum</i> (400 mg/kg b.wt.)
31.4 ± 1.9 b	68.15 ± 1.79 a	4.25 ± 1.54 a	G.5 <i>Garcinia Cambogia</i> (200 mg/kg b.wt.)+ <i>H. Perforatum</i> (200 mg/kg b.wt.)

Data are presented as means \pm standard deviation, (n = 7 for each group) Values with different superscripts within the column are significantly different at $P < 0.05$. Values with similar or partially similar superscripts are non-significant.

Histopathological study:

Examination of the liver of normal rats fed on basal diet showed the normal histological structure of hepatic lobules (Photo.1). Liver of obese rats fed on a high-fat diet revealed marked congestion of hepatic central vein (Photo.2) associated with hyperplasia of the bile duct and leucocytic infiltration (Photo. 3). Oral administrations of *Garcinia Cambogia* extract at 400 mg/kg B.wt., for 4 weeks to obese rats showed mild congestion of central vein and hepatic sinusoids (Photo.4). In obese rats orally given 400 mg/kg B.wt., of *H. Perforatum* extract, the examination of liver sections showed only mild congestion of central vein (Photo.5). Oral administrations of the mixture of both herbs showed the normal histological appearance of the hepatocytes and a low number of inflammatory cells (Photo.6).

The kidney of normal rats fed on basal diet showed the normal histological architecture of renal parenchyma (Photo.7). Examination of kidneys of obese rats showed marked congestion of glomerular tufts and renal blood vessels (Photo. 8). Kidneys of obese rats given *Garcinia Cambogia* extract at 400 mg/kg B.wt., for 4 weeks showed slight congestion of glomerular tufts and renal blood vessel (Photo.9). Oral administrations of *H. Perforatum* extract at 400 mg/kg B.wt., for 4 weeks to obese rats showed mild tubular epithelial degeneration and no necrosis was observed in epithelial cells of the proximal tubules and no tubular cast(Photo.10). Kidneys of obese rats given the mixture of both herbs (400mg/kg B.wt.) showed the normal histological structure of renal parenchyma (Photo.11).

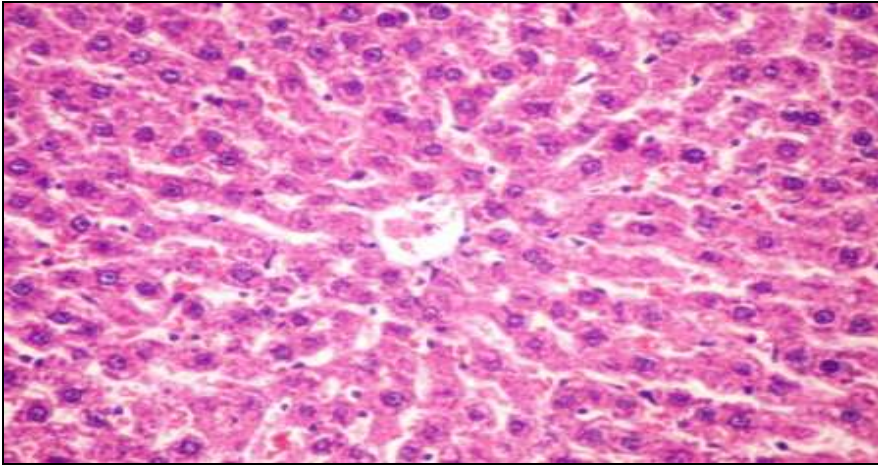


Photo. (1): Liver of a control rat showing normal histological structure of hepatic Lobules. (H & E X400)

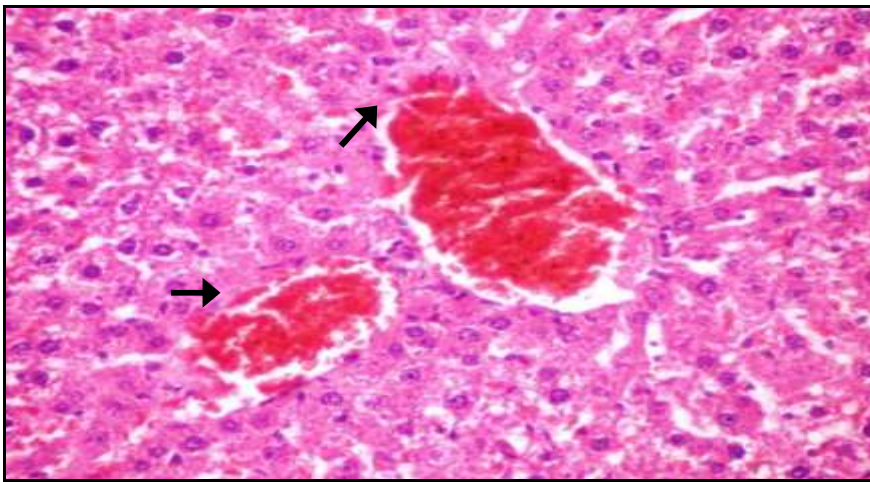


Photo. (2): Liver of an obese (non-treated) rat showing marked congestion of hepatic central veins (Arrows). (H & E X400)

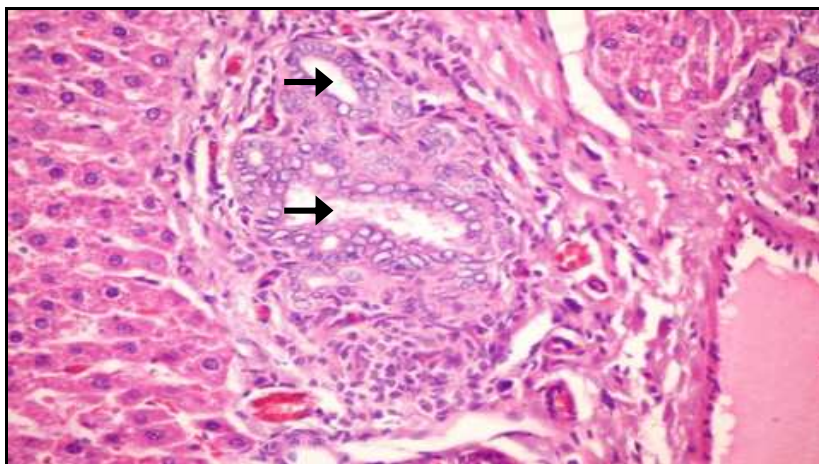


Photo. (3): Liver of an obese (non-treated) rat showing hyperplasia of the bile duct (Arrows) and infiltration with leucocytes (Arrow). (H & E X400)

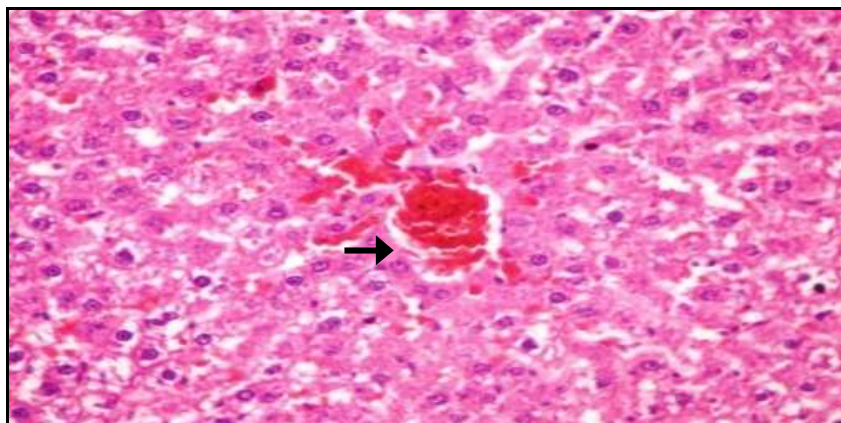


Photo. (4): Liver of an obese given Garcinia Cambogia extract at 400 mg/kg B.wt., for 4 weeks to obese rats showed mild congestion of central vein and hepatic sinusoids (H & E X400)

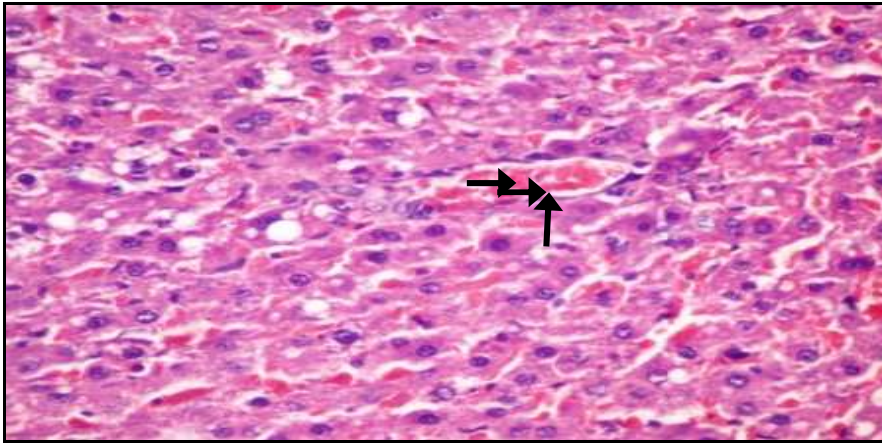


Photo. (5): Liver of an obese rat orally given *H. Perforatum* extract in a dose of 400 mg/kg B.wt., for 4 weeks the examination of liver sections showed only mild congestion of central vein (Arrow) (H & E X400).

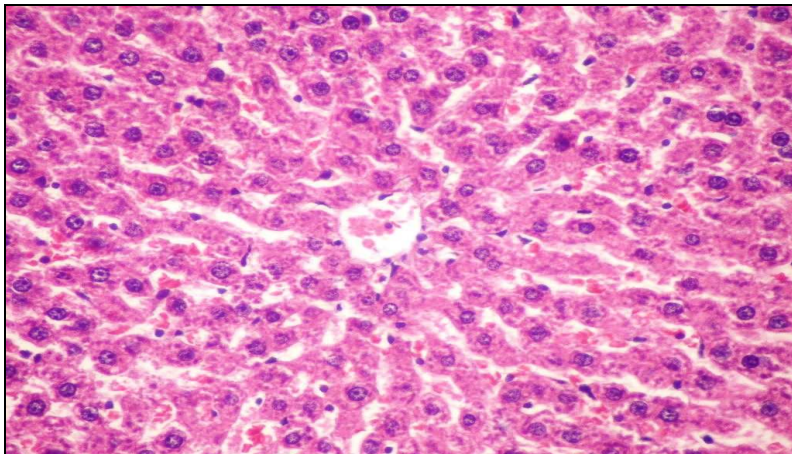


Photo. (6): Liver of an obese rat orally given Mixture of both herbs showed the normal histological appearance of the hepatocytes and a low number of inflammatory cells.(H & E X400).

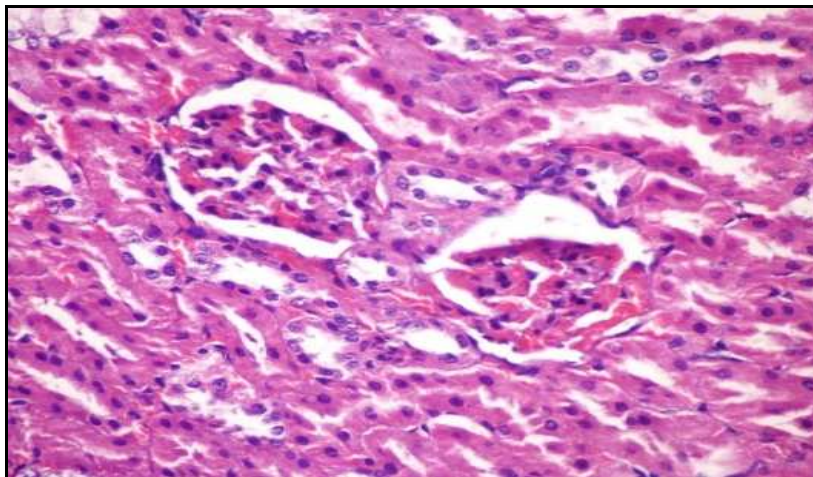


Photo. (7): Kidney of a control rat showing normal histological structure of renal Parenchyma (H & E X400).

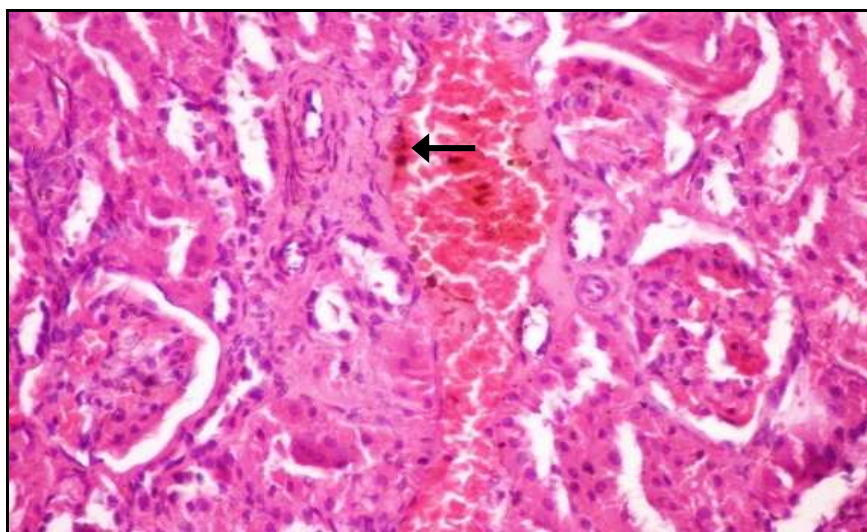


Photo. (8): Kidney of an obese rat showing marked congestion of glomerular tufts and renal blood vessels (Arrows) (H & E X400).

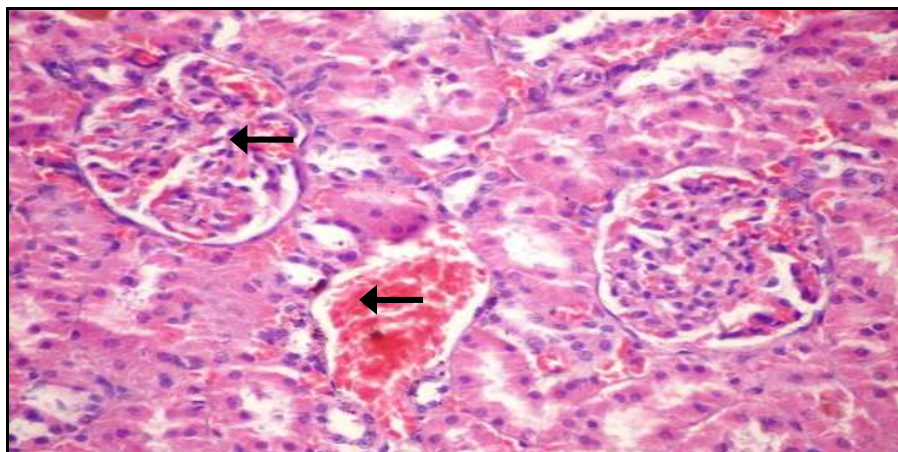


Photo. (9): Kidney of an obese rat given *Garcinia Cambogia* extract at 400 mg/kg B.wt., for 4 weeks showing slight congestion of glomerular tufts and renal blood vessel(Arrows) (H & E X400).

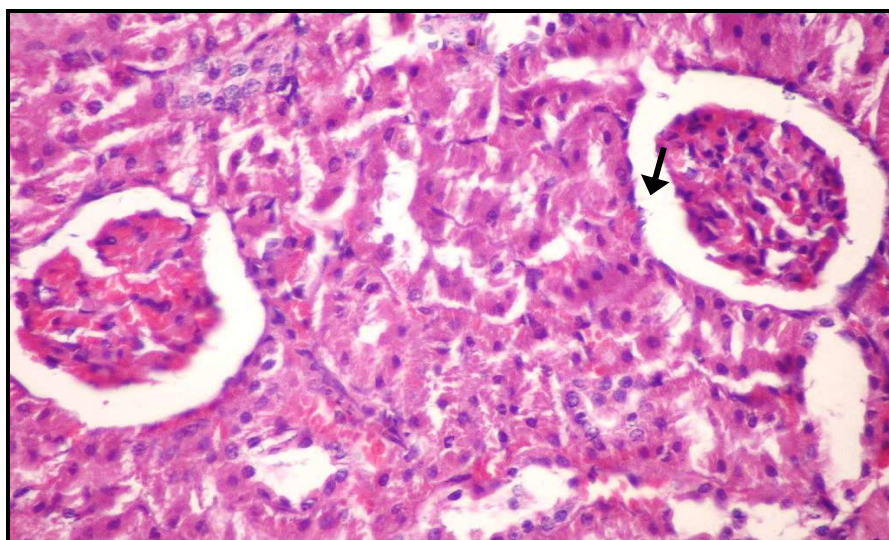


Photo. (10): Kidney of an obese rat given *Garcinia Cambogia* extract at 400 mg/kg B.wt., for 4 weeks showing mild tubular epithelial degeneration and no necrosis was observed in epithelial cells of the proximal tubules and no tubular cast Arrows) (H & E X400).

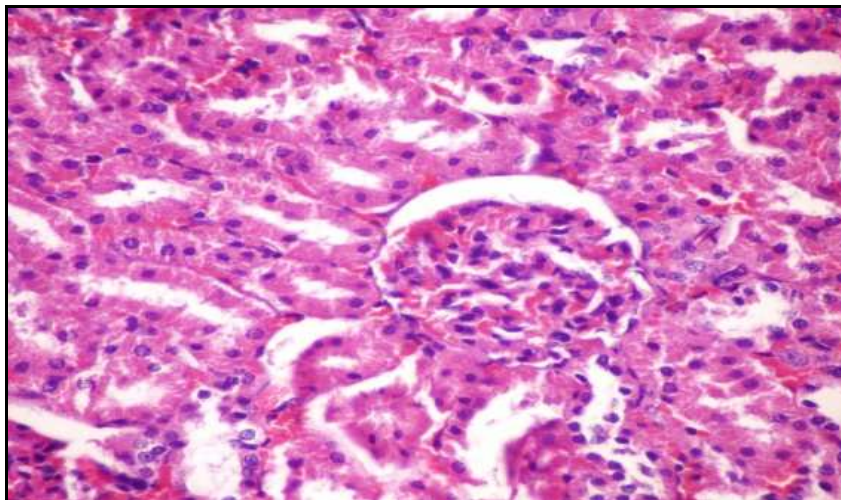


Photo. (11): Kidney of an obese given Mixture of both herbs at 400 mg/kg b.wt. for 4 weeks showing the normal histological structure of renal parenchyma (H & E X400) .

Discussion

The present study aimed to assess some pharmacological effects of *Garcinia Cambogia* and St. John's Wort (*Hypericum perforatum*) leaf extracts obese male rats. Obesity has become a major public health problem worldwide. The concerns associated with obesity are related to numerous symptoms of metabolic syndrome, including hypertension, dyslipidemia, insulin resistance, and glucose intolerance. A variety of approaches could be used to prevent and control obesity in human. Since perfect cure or prevention for obesity are yet to be found and most of the anti-obesity medications could have side effects, there has been growing interests in investigating the discovery of new naturally occurring materials (Monteiro *et al.*, 2008). In this study, obesity was induced by feeding rats on HFD for 6 weeks. This obese rat model closely resembles the reality of obesity in humans (Bhatt *et al.*, 2006). However, the experimental obesity could be also induced in rats and mice by other methods such as feeding on high fructose diet (Qin *et al.*, 2004), damage in the anterior hypothalamus and genetically induced obesity.

Results of the present study showed that HFD feeding effectively induced obesity

In rats, because it facilitates the development of a positive energy balance leading to an increase in visceral fat deposition and this led to abdominal obesity as evidenced by a significance increment of body weight, fats weight (F.wt) and adiposity index in the control positive group compared to the control negative group. Our results were in the same line with **Ji et al., (2005)**, **Xu et al., (2008)** and **Melega et al., (2013)**. **Gopinathan and Naveenraj, (2014)** reported that rats fed HFD were consumed considerably more amount of fat than the control rats throughout the experiment. So their calorie intake was increased and they showed an increase in perirenal visceral adipose tissue mass, suggesting that the excess energy led to the buildup of adiposity. This is also the source for increasing the body weight.

Our results showed a significant decrease in body weight, fats weight (F.wt) and adiposity index accumulation from oral administration of either *GarciniaCambogia*, *Hypericumperforatum* and the mixture of both herbs compared to the control positive group. These results agreed with the findings of **Gopinathan and Naveenraj, (2014)** who concluded that *Garcinia*, reduces food consumption probably by diverting fatty acids and carbohydrates that would have become fat in the liver into hepatic glycogen. This metabolic alteration may send a signal to the brain that results in rising serotonin level concomitant with a reduced appetite. Moreover, using *Garcinia* causes dispersion of fat which facilitates the action of lipase on adipose tissue (**Roy et al., 2007**), suppresses body fat accumulation (**Saito et al., 2005**), inhibit cytoplasmic lipid accumulation and regulates adipogenesis, so eliminates body fat. **Mi-Kyoung et al., (2014)** reported that Several isoflavone constituents are unique phytoestrogens, which like estradiol, affect the serotonergic system, inhibiting serotonin re-uptake and thereby increasing the levels of serotonin in synaptic clefts. This enhances satiety and resembles the action of sibutramine, but naturally. The mixture of both herbs showed a powerful effect than each herb alone but no available literature could be obtained concerning the effect of both herbs on body weight, fats weight (F.wt) and adiposity index accumulation.

The results showed that rats fed a high-fat- diet had significant ($p < 0.05$) increase in the level of serum liver enzymes (AST, ALT, and ALP), as compared to the normal control rats. The profound increase in the levels of biomarker enzymes (AST, ALT, and ALP) indicates an impaired liver function. In obese condition, the liver is bombarded by the free fatty acids that pour out of the adipose tissues into the portal blood. This can directly cause inflammation within the liver cells, which then release further pro-inflammatory cytokines, leading to liver injury and affecting the integrity of liver cells (Fielding and Frayn, 2000). Adeniran *et al.*, (2013) reported that the mechanism for increasing the liver enzymes include cell membrane disruption at high concentration, mitochondrial dysfunction, toxin formation, and activation and inhibition of key steps in the regulation of metabolism .Oral administration of *GarciniaCambogia*, *Hypericumperforatum* and the mixture of both herbs extract to obese rats for 4 weeks caused significant reductions of the elevated liver enzymes compared to the positive control group .A similar result was observed in the anti-obesity activity of *GarciniaCambogia* reported by Gopinathan and Naveenraj, (2014) and Mohammad *et al.*, (2016) who concluded that the mechanism of hepatoprotection of *Hypericumperforatum* was assumed to be through inhibition of cytochrome P450 enzymes activity in liver microsomes. The hepatoprotective activity was also supported by histopathological studies of liver tissue.

Rats fed on HFD to induce obesity caused a significant elevation in the levels of lipid constituents in the serum such as total cholesterol, serum triglycerides, LDL cholesterol, and VLDL cholesterol and decreased the HDL cholesterol level compared to rats fed on the basal diet . The elevated levels of serum lipid constituents increase the risk of atherosclerosis and coronary heart disease. Co-treatment of *GarciniaCambogia* and *H.perforatum* leaf extracts showed a significant decrease in the levels of atherogenic agents like serum cholesterol, triglycerides, LDL and VLDL cholesterols along with significant increase in the protective agent, serum HDL cholesterol level. This trend was reflected in the LDL/HDL ratio. LDL/HDL ratio was markedly higher in obese rats than healthy control rats.

After the treatment with herb extracts the ratio was brought back to normalcy in the ratio.

HDL cholesterol is responsible for the mobilization of cholesterol from peripheral cells to the liver. Based on the results from the present study it can be considered that *GarciniaCambogia* and *H.perforatum* leaf extracts are having the cardioprotective efficacy. Total cholesterol and triglycerides are defined as the main risk factor for dyslipidemia (**Paccaud et al.,2000**) and the levels of both total cholesterol and triglycerides were significantly increased in HFD fed obese animals. After the treatment with plant extracts, the obese animals showed a significant decrease in the levels of lipid profiles. This result indicates the antihyperlipidemic potential of *GarciniaCambogia* and *H.perforatum* leaf extracts. Further, lipoproteins such as HDL, LDL and VLDL showed a profound increment in their production in obese rats, which were brought back to normal levels by the treatment of *GarciniaCambogia* and *H.perforatum* leaf extracts.

Co-treatment with *Garcinia Cambogia* extract maintained the activity of lipoprotein lipase of near normalcy thereby preventing a rise of VLDL and LDL levels in the plasma (**MahendranandShyamala., 2001**). *Garcinia Cambogia* which contain the principle organic acid (-)-erythro-L - s hydroxy citric acid is an effective anti-lipogenic agent (**Sawada and Harumichi,1997**).**Kamal et al., (2011)** reported that *Garcinia Cambogia* has an inhibiting effect of hydroxy citric acid on ATP citrate lyase, an enzyme which catalyzes the extramitochondrial cleavage of citrate to oxaloacetate and acetyl COA. The produced acetyl COA is used in fatty acid synthesis, TC, and TG synthesis. The current data suggested that *Garcinia* has hypolipidemic action causing significant hypocholesterolemic and hypotriglyceridemic effect. Similar results were reported by **Gopinathan and Naveenraj, (2014)**.**Habibi et al.,(2008)** studied the therapeutic effects of total ethanolic *Hypericumperforatum*(EHP) on the lipid profiles of hyperlipidemic rats and concluded that EHP significantly reduced TCH, TG, and LDL . Also in the study conducted by **Zou et al.,(2005)** and **Asgary et al.,(2012)**, who reported that EHP reduced TCH in hyperlipidemic rats and able to increase HDL-CH levels . In addition, it has

been previously shown that the flavonoid components of *H. perforatum* can increase HDL-CH levels by augmenting the synthesis of apolipoprotein A-I and was able to reduce TG levels. They speculated that this therapeutic effect occurred through the augmentation of vascular wall resistance, which prevents cholesterol penetration into the atherogenic lipoprotein composition (**Khushbactova et al., 1989**).

In the present study, the level of serum urea, creatinine, and uric acid were elevated in the HFD induced obese rats compared with healthy rats, Regarding levels of urea, creatinine and uric acid of positive control group. **Matsuda, (1999)** ; **Aguila and Mandarin-De-Lacerda (2003)** stated that HFD had adverse effects on the kidney. In addition, **Chagnac et al., (2000)** reported that renal structural and functional adaptations occur in consequence of obesity in experimental animals and humans such as increased glomerular filtration rate, increased renal blood flow, and renal hypertrophy. **Roberts et al., (2006)** and **Hamidian et al., (2009)** reported that consumption of HFD which result in metabolic syndrome marked by obesity, hyperlipidemia and associated with oxidative stress and nitric oxide inactivation by reactive oxygen species (ROS) and diminish NO bioavailability] which leading to renal dysfunction, characterizing by high level of creatinine and blood urea nitrogen.

Treatment with *Garcinia Cambogia* and *H. perforatum* leaf extracts on kidney function significantly decreased urea, creatinine, and uric acid levels. Thus the herb extract proved their anti- hyperuricemia effect. *Garcinia* treatment enhances renal function as a result of hydroxycitric acid (HCA-SX) derived from *Garcinia Cambogia* (HCA-SX, Super Citric Max) which attenuated the increased oxidative stress biomarker through reducing lipid peroxidation (MDA) and declining lipid profiles and level of oxidized LDL which generally improved kidney function (**Asghar et al., 2007**). Concerning the effect of *H. perforatum* leaf extraction kidney function, **Hammer et al., (2007)**, concluded that the bioactive constituents of *H. perforatum* extracts are complex and include many different classes of chemicals. Some classes of constituents present within *H. perforatum* are potent antioxidants which were effective in lowering the blood urea and uric

acid, thereby maintaining the nitrogen balance. (Benedí *et al.*, (2004), Lu *et al.*, (2004) and Medina *et al.*, (2006). The nephroprotective activity was also supported by histopathological studies of kidney tissue.

High-fat fed animals showed a significant increase in T4 when compared to normal diet fed animals. This result was agreed with Kuroshima *et al.*, (1971) who study the effects of a HFD for 4 to 5 weeks on thyroid activity and found that HFD caused a marked hypertrophy of brown and white adipose tissue, while there was a significant decrease in the T4 in all treated groups compared to the positive control group available literature could be obtained concerning the effect of *Garcinia Cambogia*, *Hypericum perforatum* and the mixture of both herbs extract on the level of T4 but its effect on increasing thyroid hormones could be indirect result of their effect on lipids metabolism..

Concerning insulin hormone, it was noticed that the rats fed on a high-fat diet (positive control) had significantly lower level of insulin than that of normal rats fed on basal diet. This finding agrees with that reported by (Huang *et al.*, 2004) who concluded that high-fat diet can result in impaired pancreatic function of insulin secretion in rats. Oral administration of *Garcinia Cambogia* extract to obese rats (fed a high –fat diet) significantly increased serum insulin level, This result was similar to that reported by (Kim *et al.*, 2008) who concluded that *Garcinia Cambogia* significantly improved the hyperglycemia, in HFD, by declining insulin resistance ,in this concern *Garcinia Cambogia* could be used for management of diabetes ,by increasing metabolic pathway via rising glucose oxidation through improving insulin action; also *Garcinia Cambogia* promotes glycogenesis and lipid oxidation (Kamal *et al.*, 2011). Rats treated by administration of *H. perforatum* extract showed a significant increase in the level of serum insulin. The possible mechanism by which *H. perforatum* brings about its hypoglycemic action in diabetic rats may be by potentiating the insulin effect of plasma by increasing either the pancreatic secretion of insulin from the existing beta cells or by its release from the bound form (Arokiyaraj *et al.* ,2011). *H. perforatum* is reported to contain several phytochemical constituents such as rutin, flavonoids including

quercetin, isoquercitrin(**Can et al., 2011**). For example, rutin has been reported to enhance insulin release and decrease blood glucose level in diabetic animals(**Kamalakkannan and Prince ,2006**).

With regard to leptin hormone, leptin is produced primarily by adipocytes, and its serum levels reflect the amount of energy stored in the adipose tissue and are proportional to the overall adipose mass in both mice and humans (**Blancas-Flores et al.,2010**).The present study showed that obese rats had an increased level of leptin hormone as compared to the normal control rats. This finding agrees with that reported by (**Huang et al., 2004**) who found that high –fat diet increased serum leptin level in the rats. Oral administration of *Garcinia Cambogia* and *H.perforatum* leaf extracts to obese rats significantly decreased serum leptin level. This result agrees with that of **Hayamizuet al.,(2003)**who reported that *Garcinia Cambogia* decreased serum leptin level and depressed appetite in obese rats. The authors suggested that *G. Cambogia* extract efficiently improved glucose metabolism and displayed leptin-like activity .Similar results were reported by **Jin-ying et al.,(2015)**who stated that obese rats treated with *H. perforatum* had low serum leptin level .This may be due to its anti-obesity acting mechanism which reported for *H. perforatum* is the quantity of serotonin present within synaptosomes and inhibiting the synaptosomal uptake of serotonin (**Husain et al., 2011**).This increased level of serotonin reduces the food intake and suppresses the appetite (**Hernández-Saavedra et al., 2013**).

CONCLUSION

Based on these broad observations, we suggest that high-fat-diet-induced obesity resulted in deleterious effects in kidney and liver tissues. *Garcinia Cambogia* and *H.perforatum* leaf extracts administration counteracted the injuries, and ameliorated and/or normalized most of the biochemical parameters. Collectively obesity is associated with metabolic complications, including insulin resistance, dyslipidemia, and cardiovascular disease. When comparing therapies for obesity, both herbs extract have influenced the improvements in amelioration of body weight,

levels of lipid profiles, and markers of liver, kidney and cardiac function, as well as insulin resistance. So the plant extracts have a hypolipidemic, renoprotective, hepatoprotective, antioxidant and antiobesity effect.

References

- **Adeniran, S. A., Dolapo ,P. O., Oluwole ,A. B., Temitope, A. , Ahmed ,K. J.andAdepeju ,A. A. (2013):**Liver Enzymes and Lipid Profile Among Type 2 Diabetic Patients in Osogbo, Nigeria *Greener Journal of Medical Sciences* Vol. 3 (5), pp. 174-178.
- **Aguila , M.B., and Mandarim-De-Lacerda, C.A.(2003):** Effects of chronic high-fat diets on renal function and cortical structure in rats *Exp Toxic Pathol* , 55: 187–195.
- **Altiner ,A., Ates , A., Gursel, F.E.and Bilal T.(2012):**Effect of the antiobesity agent *Garcinia Cambogia* extract on serum lipoprotein (a), apolipoproteins a1 and b, and total cholesterol levels in female rats fed atherogenic diet. *J Anim Plant Sci*;22:872–7.
- **Armitage, P. G., Berry, and Matthews, J.M.S. (2002):**Statistical Methods in Medical Research. 4th Ed. Blackwell Science Ltd.
- **Arokiyaraj, S ., Balamurugan, R .and Augustian, P. (2011):** Antihyperglycemic effect of *Hypericumperforatum* ethyl acetate extract on streptozotocin-induced diabetic rats.*Asian Pac J Trop Biomed.*; 1(5): 386–390.
- **Asgary ,S., Solhpour, A., Parkhideh, S., Madani, H., Mahzouni, P. and Kabiri ,N. (2012):**Effect of hydroalcoholic extract of *Hypericumperforatum* on selected traditional and novel biochemical factors of cardiovascular diseases and atherosclerotic lesions in hypercholesterolemic rabbits: A comparison between the extract and lovastatin. *J Pharm Bioallied Sci.*;4(3):212–8.
- **Asghar, M., Monjok, E., Kouamou, G., Bagchi, D., Lokhandwala, M.F. (2007):** Super citric max (HCA-SX) attenuate the increase in oxidative stress, inflammation, insulin resistance, body weight in developing obese Zucker rats. *Mol cell Biochem.* ;304(1-2):93–99.
- **Atshaves, B.P., Martin, G.G., Hostetler, H.A., McIntosh, A.L., Kier, A.B.and Schroeder, F. (2010):**Liver fatty acid-binding protein and obesity. *J. Nutr. Biochem.*21, 1015–1032.

- **Barness, L.A., Opitz, J.M. and Gilbert-Barness, E. (2007):** Obesity: genetic, molecular, and environmental aspects. *Am. J. Med. Genet.* 143A, 3016–3034.
- **Benedi, J., Arroyo, R., Romero, C., Martin-Aragon, S. and Villar A. M. (2004):** Antioxidant properties and protective effects of a standardized extract of *Hypericum perforatum* on hydrogen peroxide-induced oxidative damage in PC12 cells. *Life Sci.* 75 1263–1276.
- **Bergmeyer, H.U., Scheibe, P. and Wahlefeld, A.W. (1978):** Optimization of methods for aspartate aminotransferase and alanine aminotransferase. *Clin. Chem* 24:58-73.
- **Bhatt, B.A., Dube, J.J., Dedousis, N., Reider, J.A. and O'Doherty, R.M. (2006):** Diet-induced obesity and acute hyperlipidemia reduce I kappa B alpha levels in rat skeletal muscle in a fiber-type dependent manner *American Journal of Physiology*, 290: 233-240.
- **Blancas-Flores, G., Almanza-Pérez, J., López-Roa, R., Alarcón-Aguilar, F., García-Macedo, R. and Cruz, M. (2010) :** Obesity as an inflammatory process. *Bol Med Hosp Inf Mex* 67:88–97.
- **Campbell, J.A (1963):** "Methodology of protein Evaluation." RAG Nutr. Document R. 10, led. 37. June Meeting New York.
- **Can, O.D., Oztürk, Y., Oztürk, N., Sagratini, G., Ricciutelli, M., Vittori, S. (2011):** Effects of treatment with St. John's Wort on blood glucose levels and pain perceptions of streptozotocin-diabetic rats. *Fitoterapia*; 82(4):576–584.
- **Carleton, H. (1979):** In "Histological Techniques", 4th Edition, London, Oxford University press, New York, USA.
- **Chagnac, A., Weinstein, T., Korzets, A., Ramadan, E., Hirsch, J. and Gafter, U. (2000):** Glomerular hemodynamics in severe obesity. *Am J Physiol Renal Physiol* ., 278: 817–822.
- **Chatterjee, S.S., Bhattacharya, S.K., Wonnemann, M., Singer, A. and Muller, W.E. (1998):** Hyperforin as a possible antidepressant component of *Hypericum* extracts. *Life Sci*; 63(6):499- 510.
- **Coskun, O., Kanter, M., Korkmaz, A. and Oter S (2005):** Quercetin, a flavonoid antioxidant, prevents and protects streptozotocin-induced oxidative stress and β -cell damage in rat pancreas. *Pharmacol Res*; 51:117-23.

- **Farrell, G.C. and Larter, C.Z. (2006):** Nonalcoholic fatty liver disease: From steatosis to cirrhosis. *Hepatology*, 43, S99–S112.
- **Fielding, B.A. and Frayn, K.N. (2000):** Lipid metabolism. *Current Opinion Lipidology*; 11(6): 657-659.
- **Fossati, P., Prencipe, L. and Berti, G. (1980):** Use of 3, 5 dichloro-2-hydroxyl benzene sulfonic acid /4-amylphenazone chromogenic system in the direct enzymatic assay of uric acid in serum and urine. *Clin. Chem.*; 26: 227-231.
- **Friedewald, W.T., Levy, R.I. and Fredrickson, D.S. (1972):** Estimation of the concentration of low-density lipoprotein cholesterol in plasma, without the use of the preparative ultracentrifuge. *Clin. Chem.* 18:499-502.
- **Gopinathan, S. and Naveenraj, D. (2014):** Antiobesity Potential of *Clerodendrum Phlomidis* Linn and *Garcinia Cambogia* Linn –A Comparative Animal Model Study. *World Journal of Pharmaceutical Research* Vol 3, Issue 9.
- **Guebre-Egziabher, F., Alix, P.M., Koppe, L., Pelletier, C.C., Kalbacher, E., Fouque, D. and Soulage, C.O. (2013):** Ectopic lipid accumulation: A potential cause of metabolic disturbances and a contributor to the alteration of kidney function. *Biochimie*, 95, 1971–1979.
- **Habibi, A. B., Nemati, M., Delazar, A., Mesgari, M., Vatankhah, A.M. and Ordukhani, S. (2008):** Comparison of the therapeutic effects of a total extract of *Hypericum perforatum* and calcific and magnesic sulfate mineral water on the lipid profile of Hyperlipidemic rats. *J Fac Pharm, Tabriz U Med Sci.*; 4:23–9.
- **Hamidian, J. A., Jalali, G.A., Roozbeh, J. (2009):** Impact of obesity on the development of chronic renal allograft dysfunction. *Saudi J kidney Dis transpl.*; 20(3):375–377.
- **Hammer, K.D.P., Hillwig, M.L., Solco, A.K.S., Dixon, P.M., Delate, K., Murphy, P.A., Wurtele, E.S. and Birt, D.F. (2007):** Inhibition of PGE₂ production by anti-inflammatory *Hypericum perforatum* extracts and constituents in RAW264.7 mouse macrophage cells. *J AgrFood Chem.*; 55:7323–7331.
- **Hayamizu, K., Hirakawa, H., Oikawa, D., Nakanishi, T., Takagi, T., Tachibana, T., Furuse, M. (2003):** Effect of *Garcinia Cambogia* extract on serum leptin and insulin in mice. *Fitoterapia.*; 74(3):267-73.

- **Hegsted, D.; Mills, R. and Perkins, E. (1941):** "Salt mixture ". J. Biol. Chem., 138:459.
- **Hernández-Saavedra ,D., Hernández-Montiel, H.L., Gamboa-Gómez, C.I., Salgado, L.M., Reynoso-Camacho R. (2013):**The effect of Mexican herbal infusions on diet-induced insulin resistance. *Nutrafoods.*;12:55–63.
- **Huang, B.W., Chiang, M.T., Yao, H.T. and Chiang, W. (2004):** The effect of high-fat and high-fructose diets on glucose tolerance and plasma lipid and leptin levels in rats. *Diab.Obesity.Metabol.*, 6(2): 120-126.
- **Husain, G.M., Chatterjee ,S.S., Singh ,P.N., Kumar, V. (2011):**Hypolipidemic and antiobesity-like activity of standardized extract of *Hypericum perforatum* L. in rats. *ISRN Pharmacology.* ; 1–7.
- **Husdan, H., and Rapoport, A. (1968):**Estimation of creatinine by Jaffe reaction method.*Clin. Chem.*; 14: 222-228.
- **Iinuma, M., Ito, T., Miyake, R., Tosa, H., Tanaka ,T.andChelladurai ,V. (1998):** A xanthone from *Garcinia Cambogia*. *Phytochemistry*;47:1169–70.
- **Ji ,H., K., Dae Hyun, H., Deck Chun, Y., Jang, H. K., Hye Jung, L., and Insop,S.(2005):** Effect of Crude Saponin of Korean Red Ginseng on High-Fat Diet- Induced Obesity in the Rat.*JPharmacolSci* 97, 124 – 131.
- **Jin-Ying ,T., Rong-ya, T., Xiao-lin, Z., Qian, L., Yi-bo, H., Ya-Kun, S., Teng-Fei ,J.i. and Fei Ye.(2015):**Effect of *Hypericum perforatum* L. Extract on Insulin Resistance and Lipid Metabolic Disorder in High-Fat-Diet-Induced Obese Mice*Phytother Res. Jan*; 29(1): 86–92.
- **Kamal, A. A., Hamdy ,H. K., Mohamed, A. A. E.(2011):**Protective effect of *Garcinia* against renal oxidative stress and biomarkers induced by high fat and sucrose diet .*Lipids in Health and Disease*, 10(6)
- **Kamalakkannan, N., and Prince, P.S. (2006):**Antihyperglycaemic and antioxidant effect of rutin, a polyphenolic flavonoid, in streptozotocin-induced diabetic Wistar rats. *Basic ClinPharmacolToxicol.*;98(1):97–103.
- **Kanchana, P., and Nuannoi ,C.(2012):** Comparison of the Antioxidant and Cytotoxic activities of *Phyllanthusvirgatus* and *Phyllanthusamarus* Extracts. *Med. Princ..Pract* 21:24–29.

- **Khushbactova, Z.A., Syrov, V.N. and Kuliyeu, Z. (1989):** Study of hypolipidemic properties of polymer proanthocyanidins derived from the plants used in folk medicine. *Khim-Farm Zh.*;23(9):1111–5.
- **Kim, K.Y., Lee, H.N., Kim, Y.J. and Park, T. (2008):** *Garcinia Cambogia* extract ameliorates visceral adiposity in C57BL/6 J mice fed on a high-fat diet. *Biosci Biotechnol Biochem*;72:1772–80.
- **Kim, K.Y., Lee, H.N., Kim, Y.J. and Park, T. (2008):** *Garcinia cambogia* extract ameliorates visceral adiposity in C57BL/6 j mice fed on high-fat diet. *Biosci Biotechnol Biochem*, 72(7):1772-1780.
- **Kumar, S., Sharma, S. and Chattopadhyay, S.K. (2009):** High-performance liquid chromatography and LC-ESI-MS method for identification and quantification of two isomeric polyisoprenylated benzophenones oxanthochymol and camboginol in different extracts of *Garcinia* species. *Biomed Chromatogr*;23:888–907.
- **Kumar, V., Singh, P.N., Muruganandam, A.V. and Bhattacharya, S.K. (2000):** Effect of Indian *Hypericum perforatum* Linn. on animal models of cognitive dysfunction. *J Ethnopharmacol*; 72:119-128.
- **Kumari, K., Mathew, B.C. and Augusti, K.T. (1995):** Antidiabetic and hypolipidemic effects of S- methyl cysteine sulfoxide isolated from *Allium cepa* Linn. *Indian J Biochem Biophys.*;32:49–54.
- **Kuroshim, A., Doi, K. and Itoh, S. (1971):** Effects of a high-fat diet on thyroid activity, with special reference to thyroidal responses to cold. *International Journal of Biometeorology*, 15(1): 55-64.
- **Lim, D.W., Song, M., Park, J., Park, S.W., Kim, N.H., Gaire, B.P., Choi, H.Y. and Kim, H. (2012):** Anti-obesity effect of HT048, a herbal combination, in high fat diet-induced obese rats. *Molecules*, 17, 14765–14777.
- **Lu, Y. H., Du, C. B., Liu, J. W., Hong, W., Wei, D. Z. (2004):** Neuroprotective effects of *Hypericum perforatum* on trauma induced by hydrogen peroxide in PC12 cells. *Am. J. Chin. Med.* 32 397–405.
- **Mahendran and Shyamala, D. C. S. (2001):** Effect of *Garcinia Cambogia* Extract on Lipids and Lipoprotein Composition in Dexamethasone Administered Rats. *Indian J Physiol Pharmacol*; 45 (3) : 345-350 P.

- **Malik ,V.S., Willett, W.C. and Hu ,F.B.(2013):**Global obesity: trends, risk factors, and policy implications. *Nat Rev Endocrinol.* 9:13–27.
- **Matsuda, S., Arai ,T., Iwata, K., Oka ,M. and Nagase, M.(1999):** A high fat diet aggravates tubulointerstitial but not glomerular lesions in obese Zucker rats. *kidney international*, 56(71s) 150s-152s.
- **Mazzio ,E.A.andSoliman, K.F.A. (2009):** In vitro screening for the tumoricidal properties of international medicinal herbs. *Phytother Res;*23:385–98.
- **Medina, M.A., Martinez-Poveda, B., Amores-Sanchez, M.I.and Quesada, A.R.(2006):**Hyperforin: More than an antidepressant bioactive compound? *Life Sci;* 79:105-111.
- **Melega, S. Canistro, D. De Nicola, G. R. Lazzeri, L. Sapone A. and Paolini M.(2013):** Protective effect of Tuscan black cabbage sprout extract against serum lipid increase and perturbations of liver antioxidant and detoxifying enzymes in rats fed a high-fat diet *British Journal of Nutrition*, 110, 988–997.
- **Mi-Kyoung ,Y., Jin, R., Kyu-Shik, J., Mi-Ae ,B., Myung-Seok, K., and Hyeon,A. K .(2014):**Effect of St. John's Wort (*Hypericumperforatum*) on obesity, lipid metabolism and uterine epithelial proliferation in ovariectomized rats.*Nutr Res Pract.*; 8(3): 292–296.
- **Mohammad, H. G. M., Mehrdad, R., and Maryam, M.(2016):**Effect of *Hypericumperforatum* Aqueous Extracts on Serum Lipids, Aminotransferases, and Lipid Peroxidation in HyperlipidemicRats,*ResCardiovasc Med.* May; 5(2): e31326.
- **Monteiro, R., Assunção, M., Andrade, J.P., Neves, D., Calhau, C. and Azevedo, I. (2008):** Chronic green tea consumption decreases body mass, induces aromatase expression, and changes proliferation and apoptosis in adult male rat adipose tissue. *J. Nutr.*, 138: 2156-2163.
- **Nahrstedt, A.and Butterweck, V. (1997):** Biologically active and other chemical constituents of the herb of *Hypericumperforatum* L. *Pharmacopsychiatry;* 30:129-134.
- **Ozturk ,N., Korkmaz, S.andOzturk, Y.(2007):** the Wound-healing activity of St. John's Wort (*Hypericumperforatum* L.) on chicken embryonic fibroblasts. *J Ethnopharmacol;* 111(1):33-39.

- **Paccaud, F., Fasmeyer, S.V., Wietlisbach, V., and Bovet, P.(2000):** Dyslipidemia and abdominal obesity: an assessment in three general populations and abnormal blood lipids are risk factors for CVD. *J ClinEpid.*; 53: 393–400.
- **Patrono, C. and Peskar, B.A.(1987):** Radioimmunoassay in Basic and Clinical Pharmacology, Springer-Verlag, Heidelberg.
- **Patton, C. J. and Crouch S.R. (1977):** an Enzymatic colorimetric method for determination of urea in serum. *Anal. Chem.*, 49: 464-465.
- **Pichon, L., Huneau, J.F., Fromentin, G. and Tomé D.(2006):** A high-protein, high-fat, carbohydrate-free diet reduces energy intake, hepatic lipogenesis, and adiposity in rats. *J Nutr*; 136:1256-60.
- **Powell, A.G., Apovian, C.M. and Aronne, L.J. (2011):** New drug targets for the treatment of obesity. *Clin.Pharmacol.Ther.* 90, 40–51.
- **Qin, B., Nagasaki, M., Ren, M., Bajotto, G., Oshida, Y. and Sato, Y. (2004):** Cinnamon extract prevents the insulin resistance induced by a high-fructose diet. *HormMetab Res*; 36:119-25.
- **Reeves, P.G.; Nielson, F.H., and Fahmy, G.C. (1993):** Reports of the American Institute of Nutrition, ad-hoc wiling committee on the reformulation of the AIN93. Rodent Diet. *J. Nutri.*, 123, 1939-1951.
- **Richmond, N. (1973):** Colorimetric determination of total cholesterol and high-density lipoprotein cholesterol (HDL). *Clin.Chem.* 19:1350-6.
- **Roberts, C.K., Barnard, R.J. and Vaziri, N.D.(2006):** Oxidative stress and dysregulation of NADPH oxidase and antioxidant enzyme in diet-induced metabolic syndrome. *Metabolism*.; 55(7):928–934.
- **Roy, S.E. (1970):** Colorimetric determination of serum alkaline phosphatase. *Clin.Chem* 16:431-2.
- **Roy, S., Rink, C., Khanna, S., Phillips, C., Bagchi, D. and Bagchi M.(2003):** Bodyweight and abdominal fat gene expression profile in response to a novel hydroxy citric acid-based dietary supplement. *Gene Expr* ,11:251–62.
- **Roy, S., Shah, H., Rink, C., Khanna, S., Bagchi, D., Bagchi, M. and Sen, C.K.(2007):** Transcriptome of primary adipocytes from an obese woman in response to novel hydroxy citric acid- based dietary supplement. *DNA cell Biol*, 26(9):627-639.

- **Saito, M., Nagata, J., Takeuchi, M. (2005):** High dose of garcinia is effective in suppressing fat accumulation in developing male Zucker obese rats but highly toxic to testes. *Food Chem Toxicol*, 43(3):411-419.
- **Samuel, V.T., Petersen, K.F. and Shulman, G.I. (2010):** Lipid-induced insulin resistance: Unraveling the mechanism. *Lancet*, 375, 2267-2277.
- **Sawada and Harumichi (1997):** Effect of liquid Garcinia extract and soluble Garcinia powder on body weight change. *Nihon Yukagakkashi*; 46: 1467-1474.
- **Sosa, S., Pace, R. and Bornancin, A. (2007):** Topical anti-inflammatory activity of extracts and compounds from *Hypericum perforatum* L. *J Pharm Pharmacol*; 59(5):703-709.
- **Tharachand, S., I. and Avadhani, M. (2013):** Medicinal properties of Malabar tamarind [*Garcinia cambogia* (Gaertn.) Desr.]. *Int J Pharm Sci Rev Res* ;19:101-7.
- **Xiong, Y., Shen, L., Liu, K.J., Tso, P., Xiong, Y. and Wang, G. (2010):** Antiobesity and antihyperglycemic effects of ginsenoside Rb1 in rats. *Diabetes* ;59:2505-12.
- **Xu, R.Y., Wan, Y.P., Tang, Q.Y., Wu, J. and Cai, W. (2008):** The effects of high fat on central appetite genes in Wistar rats: A microarray analysis. *Clin Chim Acta.*, 397: 96-100.
- **Yallow, R. and Bauman, W.A. (1983):** Plasma insulin in health and disease. In *Diabetes Mellitus: Theory and Practice*. Vol. 15. New York: Excerpta Medica. p. 119-20.
- **Yun, J.W. (2010):** Possible anti-obesity therapeutics from nature—a review. *Phytochemistry*, 71, 1625-1641.
- **Zou, Y., Lu, Y. and Wei, D. (2005):** Hypocholesterolemic effects of a flavonoid-rich extract of *Hypericum perforatum* L. in rats fed a cholesterol-rich diet. *J Agric Food Chem.*;53(7):2462-6.

تأثير مستخلصات الجارسينيا ونبته سانت جون على السمنة في ذكور الفئران

ريهام ابوالحاسن عرفات*

الملخص العربي

استهدف هذا البحث دراسة تأثير مستخلصات كل من الجارسينيا ونبته سانت جون وخليطهما على السمنة في ذكور الفئران. وتم إجراء التجربة على عدد ٣٥ فأرووزعت إلى ٥ مجموعات كل منها سبعة فئران، تركت احداها مجموعة ضابطة سائلة، وتم تغذية فئران الاربع مجموعات الاخرى على عليقة عالية في محتواها من الدهن لمدة ستة اسابيع لاحداث بدانة بها. وتركت احدى المجموعات مجموعة ضابطة موجبة وتم إعطاء الفئران البدينة خلاصة الجارسينيا ونبته سانت جون وخليطهما بجرعة ٤٠٠ ملجم /كجم من وزن الجسم علي التوالي عن طريق الفم لمدة اربعة أسابيع. وفي نهاية فترة التجربة تم ذبح الفئران وأخذت عينات من الدم لقياس مستوى إنزيمات الكبد، الكوليسترول، الدهون الثلاثية والليبوبروتينات، ووظائف الكلى منها تركيزات اليوريا، حمض البولييك والكرياتين في السيرم. وكذلك تم قياس تركيز هرمونات الثيروكسين، الانسولين واللبتين وإجراء الفحص الهستوباثولوجي للكبد والكليتين.

وأظهرت نتائج الدراسة أن اعطاء مستخلصات الجارسينيا ونبته سانت جون وخليطهما للفئران المصابة بالبدانة أدى إلى نقص معنوي في مستوى إنزيمات الكبد، الكوليسترول الكلى، الدهون الثلاثية والكوليسترول منخفض الكثافة مقارنة بالمجموعة الضابطة الموجبة. وأدى إلى نقص تركيزات اليوريا وحمض البولييك في السيرم. كذلك أدى إلى زيادة تركيز هرمون الثيروكسين والانسولين ونقص تركيز هرمون اللبتين. وأظهر الفحص الهستوباثولوجي اختفاء التغييرات الهستوباثولوجية بالكبد والكليتين في الفئران البدينة. وتوصى هذه الدراسة بأن تناول الجارسينيا ونبته سانت جون وخليطهما قد يكون مفيدا للمرضى الذين يعانون من البدانة وارتفاع دهون الدم.

الكلمات المفتاحية: جارسينيا، نبته سان جون، انزيمات الكبد، وظائف الكلى، صورة دهون الدم، الهرمونات، الهستوباثولوجي.

* قسم التغذية وعلوم الأطعمة - كلية الاقتصاد المنزلي - جامعة حلوان