

The Prognostic Role of B-Catenin Subcellular Localization in Hepatocellular Carcinoma of Egyptian Patients

Rania Abdallah Abdallah¹, Dalia Refaat Al-Sharaky¹, Doha Maher Taie²,
Marwa Said EL Masry², Rehab Monir Samaka¹

¹Pathology Department, Faculty of Medicine, Menoufia University, Shebin El Kom, Menoufia Governorate,

²Pathology Department, National Liver Institute, Menoufia University, Shebin El Kom, Menoufia Governorate, Egypt

Corresponding author: Rehab Monir Samaka, **Mobile:** (+20) 01002806239, **E-Mail** rehabsamaka@yahoo.com

ABSTRACT

Background: Hepatocellular carcinoma (HCC) is one of the most common cancers in Egypt with fatal outcome. The molecular pathogenesis of this type of cancer is so complex involving interaction of several signaling pathways. Among those is Wingless (WNT)/ β -catenin signaling pathway, which is frequently activated in HCC.

Objectives: To investigate the relationship of different localization patterns of β -catenin in relation to different histopathologic parameters in Egyptian HCC cases.

Patients and methods: One hundred and twenty-one (121) HCC specimens were subjected for β -catenin evaluation by immunohistochemistry.

Results: The studied HCC cases showed β -catenin membranous expression in 47/121 (38.8%) of cases, while nucleocytoplasmic localization was observed in 31/121 (25.6%). Most of HCC cases that showed single tumor mass presentation exhibited negative nucleocytoplasmic expression pattern (79.2%, $P=0.02$). Membranous pool of β -catenin was associated with adverse prognostic factors like increased positivity among high-grade cases ($P=0.04$), higher H score value in cases having lymphovascular invasion, positive lymph node and higher (advanced) TMN stages ($P = 0.01, 0.00, 0.00$ & 0.03 respectively).

Conclusion: HCC cases showed heterogeneous β -catenin expression pattern. Membranous β -catenin localization was associated with aggressive prognostic parameters of HCC.

Keywords: β -catenin, Subcellular localization, HCC, Immunohistochemistry.

INTRODUCTION

Hepatocellular carcinoma (HCC) represents a popular and challenging health problem in Egypt, being a leading cause of cancer-related morbidity and mortality⁽¹⁾. It is ranked as the fourth common cancer in Egypt and the sixth most common cancer worldwide⁽²⁾.

Several etiologic factors played an important role in the pathogenesis of HCC, among them, chronic hepatitis B virus (HBV) and hepatitis C virus (HCV) infections, which by far were considered as the most common risk factors for HCC⁽³⁾. In the same line, alteration of numerous signaling transduction pathways have been documented in HCC⁽⁴⁾. The Wingless (WNT)/ β -catenin signaling pathway regulates multiple cellular processes and is a commonly dysregulated pathway in several types of cancers including HCC⁽⁵⁾.

β -catenin is a central component of the WNT signaling pathway. Aberrant activation of WNT pathway causing accumulation of β -catenin in the cytoplasm and then translocate into the nucleus with subsequent activation of different transcription genes thus contributing to carcinogenesis⁽⁶⁾.

In addition to its WNT signaling activity, β -catenin at cell membrane functions as a component of

adherence junction complex connecting cadherins with actin cytoskeleton. The activity of this molecule is well organized via several binding proteins affecting its stability, subcellular localization and transcriptional activity⁽⁷⁾.

In this study, we used immunohistochemistry to investigate the relationship of different localization patterns of β -catenin in relation to different histopathologic parameters in Egyptian HCC cases.

PATIENTS AND METHODS

This is a retrospective study; included 121 liver tissues (surgical specimens) obtained from Egyptian patients presented by HCC and retrieved from the archival material of Pathology Department, National Liver Institute, Menoufia University during the period between April 2010 and August 2017. All specimens were collected as a part of the standard clinical management of the patients.

Ethical approval:

The study was approved by Institutional Review Board (IRB) of the National Liver Institute (NLI) and Faculty of Medicine, Menoufia University.



Clinical data

The following data for HCC cases were collected from patients' medical records and included age, gender, virology status, previous treatment in HCV positive cases, total bilirubin, serum alanine transaminase (ALT), aspartate transaminase (AST) and α -fetoprotein level (AFP) and computed tomography data (site, size and tumor focality).

Data about recurrence and patient status were available for only 50 cases.

Histopathologic Evaluation:

Hematoxylin and eosin (H & E) stained slides from HCC cases were reevaluated to confirm the diagnosis and to assess histological type⁽⁸⁾, grade (Grade 1, 2 and 3 and for statistical purpose grade 1 and 2 were lumped as low and grade 3 as high)^(8,9). Staging (classified into I, II, III & VI then lumped into two groups for statistical purpose)⁽¹⁰⁾.

Presence of perineural invasion, lymphovascular invasion (LVI), and the status of the surgical margin (free or involved) together with the presence of involved lymph nodes.

Tissue Microarray (TMA) constructing Technique:

All formalin-fixed, paraffin-embedded tissues were carefully assessed by H & E staining to identify viable, representative areas of each sample, which is circled with a pen (Quick-Ray Tissue Microarray System). Then TMA was done on the most representative parts of the stained slides. Tissue cores with a diameter of 1.5 μ m from the predefined region of each specimen paraffin block were punched and arrayed in triplicate on a recipient paraffin block, into a ready-made hole, guided by a defined x-y position. A control normal tissue is placed in strategic regions throughout the blocks or asymmetrically at one end of the block. A TMA map is created, indicating the position and origin of each core in the tissue microarray. Four μ m sections of these tissue array blocks were cut and placed on positive charged slides for immunohistochemical analysis.

Immunohistochemistry technique:

Five μ m thick serial sections were cut from each paraffin block and mounted on positively charged glass slides to be ready for immunohistochemical staining using streptavidin-biotin amplified system. The primary antibody was a monoclonal mouse anti β -catenin

antibody (ready to use, Clone: R702; Dako). Ultra V block was applied to block nonspecific background staining. Antigen retrieval was performed using Tris-EDTA (pH 9). The detection kit was ultravision detection system antipolyvalent HRP/DAB (ready to use, cat. #TP-015-HD; Lab Vision Corporation, Fremont, California). Finally, the reaction can be visualized by appropriate substrate/chromogen (Diaminobenzidine, DAB) reagent with Mayer's hematoxylin as a counterstain. The staining procedure included positive tissue control (fibromatosis) and negative tissue controls by omitting the primary antibodies.

Interpretation of immunostaining results:

β -catenin positivity was seen in the membrane, nucleus & cytoplasm, and was categorized predominantly nuclear with or without significant cytoplasmic (nucleocytoplasmic) and pure membranous staining patterns⁽¹¹⁾.

- H score system was applied according to **Han et al.**⁽¹²⁾, where both the intensity and percentage of positivity were considered using the following formula: H score = (3 \times % of strong intensity) + (2 \times % of moderate intensity) + (1 \times % of mild intensity)
- N.B. The intensity of expression was ranked as: 0, no staining; +1, mild intensity; +2, moderate intensity; and +3, strong intensity.

Statistical analysis

Data were collected, tabulated, and statistically analyzed using a personal computer with 'statistical package for the social sciences, version 22' program (SPSS Inc., Chicago, USA). Fisher's exact and χ^2 tests were used to compare between qualitative variables while Mann-Whitney (U) and Kruskal Wallis tests were used when quantitative variables were used in comparison. Spearman's correlation coefficient was used to measure the association between two quantitative variables. P values \leq 0.05 were considered statistically significant.

RESULTS

The clinical and pathologic data of the included HCC cases in addition to immunostaining results of β -catenin was listed in table (1).

Table (1): The clinical, histopathological data and β - catenin immunostaining results of the studied HCC cases

	Parameters	HCC patients No=121 No (%)
Age (Years)	<50	16 (13.2)
	≥50	105 (86.8)
Gender	Male	96 (79.3)
	Female	25 (20.7)
Virology status	HBV	1 (0.8)
	HCV	110(90.9)
	Combined	7 (5.8)
	Non B-nonC	3 (2.5)
Total bilirubin mg/dl (No=119)	Mean ± SD	1.04 ± 0.37
	Median	0.84
AST (U/L) (No=117)	Mean ± SD	148.15 ± 30.1
	Median	123
ALT(U/L) (No=115)	Mean ± SD	119.4 ± 16.28
	Median	78
AFP (U/L) (No=110)	Mean ± SD	302.5 ± 94.5
	Median	89
Tumor site	Right lobe	57 (47.1)
	Left lobe	62 (51.2)
	Bilobar	2 (1.7)
Tumor size/cm	≤5cm	84 (69.4)
	>5cm	37 (30.6)
Tumor focality	Single	96 (79.3)
	Multiple	25 (20.7)
Histological pattern	Solid	23 (19)
	Trabecular	13 (10.7)
	Mixed	84 (69.5)
	Fibrolamellar	1 (0.8)
Tumor grade	Low	96 (79.3)
	High	25 (20.7)
Perineural invasion	Present	0 (0)
	Absent	121 (100)
Lymphovascular invasion	Present	57 (47.1)
	Absent	64 (52.9)
Surgical margin	Free	101 (83.5)
	Involved	20 (16.5)
Lymph node involvement	Present	15 (12.4)
	Absent	106 (87.6)
TNM Staging	I	38 (31.4)
	II	34 (28.1)
	III	34 (28.1)
	IV	15 (12.4)
TNM stage grouping	Early	72 (59.5)
	Advanced	49 (40.5)
β- catenin membranous expression	Positive	47 (38.8)
	Negative	74 (61.2)
	Mean ± SD	91.81 ± 61.35
	Median	80
β- catenin nucleocytoplasmic expression	Positive	31 (25.6)
	Negative	90 (74.4)
	Mean ± SD	40.48 ± 34.48
	Median	30

No: Number, SD: standard deviation, AST: aspartate transaminase ALT: alanine transaminase, ALP: alkaline phosphatase, AFP: α -fetoprotein.

Association of β -catenin positivity with the studied clinicopathologic features of HCC cases:

*Regarding membranous localization:

- Most of HCC cases (60%) with stage IV presentation showed membranous β -catenin positivity, a relationship that appeared significant (P = 0.04) as shown in table (2) and figures (1 A & B).

*Regarding nucleocytoplasmic localization:

- A statistically significant relationship was found between nucleo-cytoplasmic β -catenin expression pattern and tumor focality as the majority of cases presented with single tumor focus exhibited β -catenin negative expression (79.2%, P=0.02) (Table 2 and figures 2 A & B).

Table (2): Association of β -catenin positivity with the studied clinico-pathologic parameters of HCC cases

	Parameters	β -catenin (Membranous) expression			β -catenin (Nucleocytoplasmic) expression		
		Positive No=47 No (%)	Negative No=74 No (%)	P value	Positive No=31 No (%)	Negative No=90 No (%)	P value
Age (Years)	≥50	42 (40)	63 (60)	0.6 ^{NS}	27 (25.7)	78 (74.3)	0.95 ^{NS}
Gender	Male	36 (37.5)	60 (62.5)	0.65 ^{NS}	28 (29.2)	68 (70.8)	0.08 ^{NS}
	Female	11 (44)	14 (56)		3 (12)	22 (88)	
Virology status (No=117)	HCV	45 (40.9)	65 (59.1)	0.24 ^{NS}	27 (24.5)	83 (75.5)	0.81 ^{NS}
	Combined	1 (14.3)	6 (85.7)		2 (28.6)	5 (71.4)	
Treatment	No treatment	12 (48)	13 (52)	0.47 ^{NS}	6 (24)	19 (76)	0.77 ^{NS}
	Interferon	19 (39.6)	29 (60.4)		14 (29.2)	34 (70.8)	
	Sovaldi	16 (33.3)	32 (66.7)		11 (22.9)	37 (77.1)	
Status (No=50)	Alive	12 (40)	18 (60)	0.77 ^{NS}	8 (26.7)	22 (73.3)	0.33 ^{NS}
	Dead	7 (35)	13 (65)		3 (15)	17 (85)	
Recurrence (No=50)	Yes	5 (35.7)	9 (64.3)	1 ^{NS}	3 (21.4)	11 (78.6)	0.95 ^{NS}
	No	14 (38.9)	22 (61.1)		8 (22.2)	28 (77.8)	
Total bilirubin mg/dl (N=119)	Median(Range)	0.87 (0.2-3.1)	0.8 (0.12-4)	0.77 ^{NS}	0.92 (0.34-4)	0.8 (0.19-3.1)	0.13 ^{NS}
AST (U/L) (N=117)	Median(Range)	98 (27-311)	129 (14-1070)	0.77 ^{NS}	183 (22-1070)	122.5 (14-421)	0.18 ^{NS}
ALT(U/L) (N=115)	Median(Range)	82 (22-543)	78 (10-644)	0.54	84 (10-644)	77.5 (11-543)	0.73 ^{NS}
AFP (U/L) (N=110)	Median(Range)	84 (4-1412)	90 (0.2-3497)	0.66 ^{NS}	93 (10-971)	115 (0.2-3497)	0.96 ^{NS}
Tumor site (N=119)	Right lobe	22 (38.6)	35 (61.4)	0.85 ^V	16 (28.1)	41 (71.9)	0.63 ^{NS}
	Left lobe	25 (40.3)	37 (59.7)		15 (24.2)	47 (75.8)	
Tumor size/cm	Median(Range)	3.2 (0.5-10)	4 (1.5-17)	0.06 ^{NS}	4 (1.5-14)	4 (0.5-17)	0.96 ^{NS}
Tumor size	≤5cm	37 (44)	47 (56)	0.1 ^{NS}	22 (26.2)	62 (73.8)	0.83 ^{NS}
	>5cm	10 (27)	27 (73)		9 (24.3)	28 (75.7)	
Tumor focality	Single	39 (40.6)	57 (59.4)	0.5 ^{NS}	20 (20.8)	76 (79.2)	0.02*
	Multiple	8 (32)	17 (68)		11 (44)	14 (56)	
Histological type	Solid	10 (43.5)	13 (56.5)	0.46 ^{NS}	6 (26.1)	17 (73.9)	0.19 ^{NS}
	Trabecular	3 (23.1)	10 (76.9)		6 (46.2)	7 (53.8)	
	Mixed	33 (39.3)	51 (60.7)		19 (22.6)	65 (77.4)	
Tumor grade	Low	37 (38.5)	59 (61.5)	1 ^{NS}	23 (24)	73 (76)	0.41 ^{NS}
	High	10 (40)	15 (60)		32 (31)	68 (90)	
Lymphovascular invasion	Present	20 (35.1)	37 (64.9)	0.46 ^{NS}	18 (31.6)	39 (68.4)	0.16 ^{NS}
	Absent	27 (42.2)	37 (57.8)		13 (20.3)	51 (79.7)	
Surgical margin	Free	43 (42.6)	58 (57.4)	0.08 ^{NS}	27 (26.7)	74 (73.3)	0.53 ^{NS}
	Involved	4 (20)	16 (80)		4 (20)	16 (80)	
Lymph node involvement	Yes	9 (60)	6 (40)	0.09 ^{NS}	5 (33.3)	10 (66.7)	0.47 ^{NS}
	No	38 (35.8)	68 (64.2)		26 (24.5)	80 (75.5)	
Staging	I	17 (44.7)	21 (55.3)	0.04*	8 (21.1)	30 (78.9)	0.82 ^{NS}
	II	14 (41.2)	20 (58.8)		9 (26.5)	25 (73.5)	
	III	7 (20.6)	27 (79.4)		9 (26.5)	10 (66.7)	
	IV	9 (60)	6 (40)		5 (33.3)		

No: Number, AST: aspartate transaminase ALT: alanine transaminase, ALP: alkaline phosphatase, AFP: α -fetoprotein, NS: non-significant.

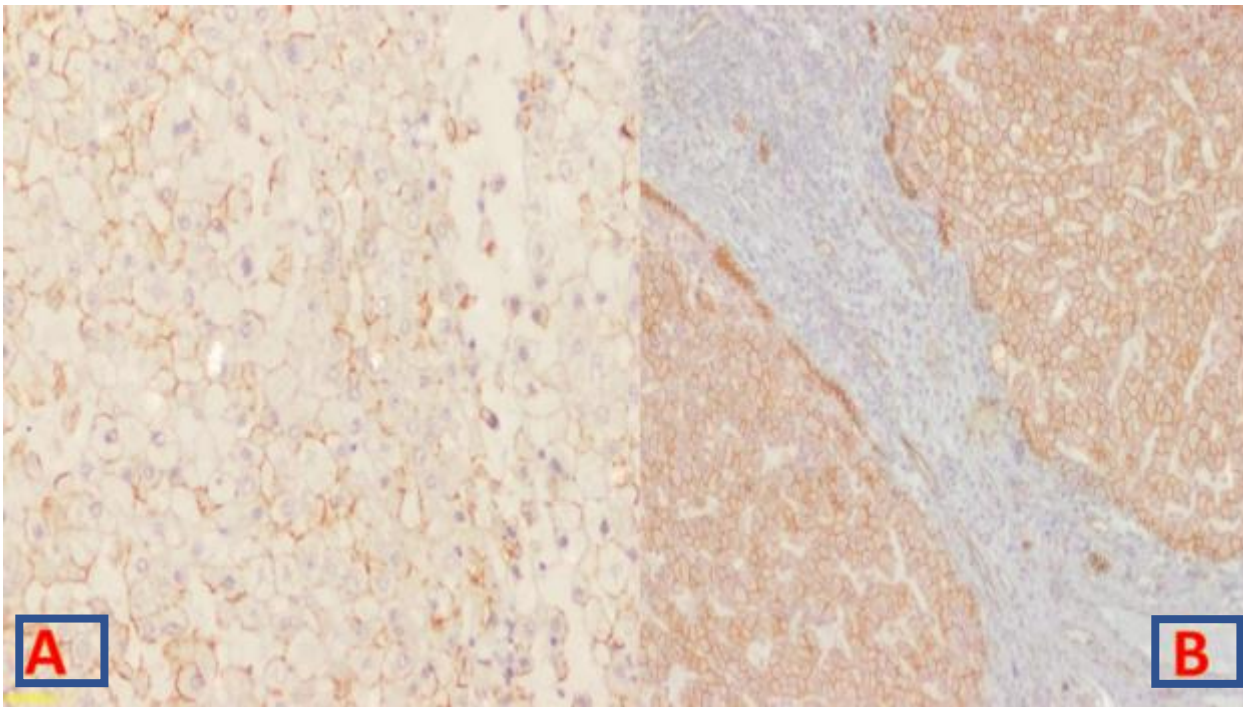


Figure (1): β -catenin membranous expression in HCC; mild/patchy (A), strong /diffuse (B) staining in tumor cells {immunohistochemical staining, $\times 100$ for (A & B)}.

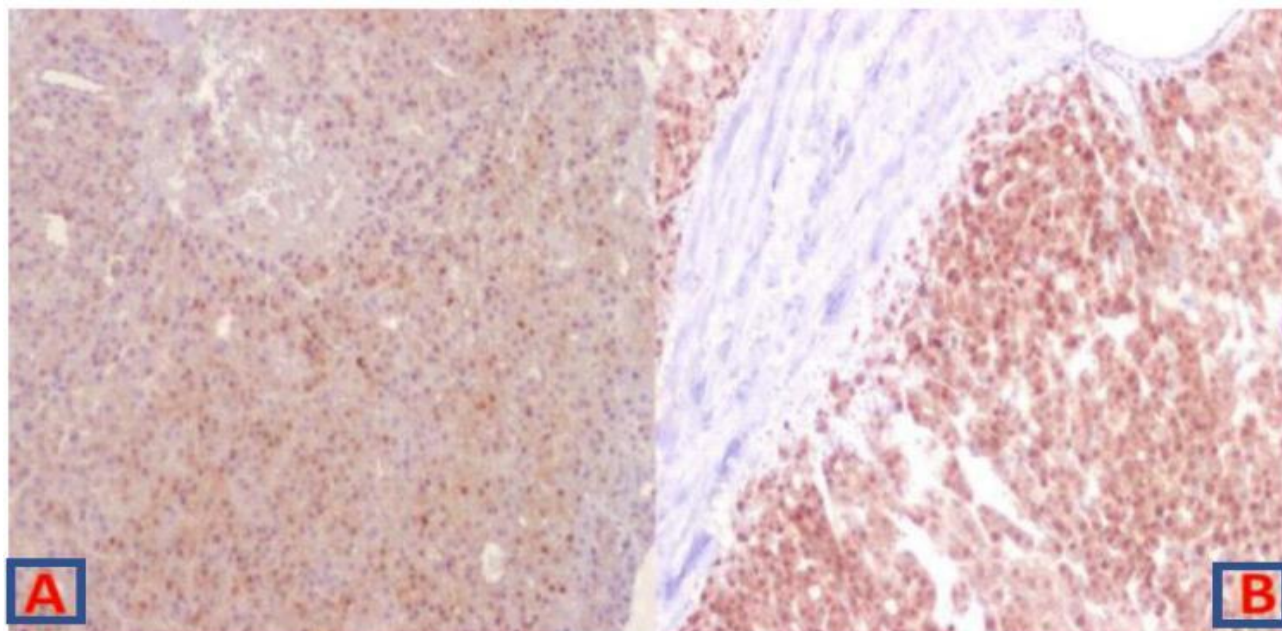


Figure (2): Nucleocytoplasmic localization of β -catenin in HCC; mild/patchy (A), strong /diffuse (B) expression in tumor cells {immunohistochemical staining, $\times 100$ for (A & B)}.

Association of β -catenin H score with the studied clinico-pathologic features of HCC cases:

*Regarding membranous localization:

- HCC cases associated with lymphovascular invasion or positive lymph nodes showed higher H score values of membranous β -catenin ($P = 0.01$ and 0.00 respectively) (Table 3).
- A progressive elevation of H score values of membranous β -catenin localization were noted with increasing HCC TNM stage ($P = 0.00$). In the same line HCC cases presented with advanced stage showed higher H score values of membranous expression ($P = 0.03$) (Table 3).

*Regarding nucleocytoplasmic localization:

- None of the studied parameters showed significant association with nucleocytoplasmic expression pattern (Table 3).

Table (3): Association of H score values of different subcellular localization of β -catenin positive cases with the studied parameters in HCC cases

Parameters	β -catenin (Membranous) H score	P value	β -catenin (Nucleocytoplasmic) H score	P value
Age (Years)				
<50	80 (40-210)	0.9 ^{NS}	30 (10-40)	0.83 ^{NS}
\geq 50	80 (5-270)		30 (10-195)	
Gender				
Male	80 (5-270)	0.17 ^{NS}	30 (10-195)	0.14 ^{NS}
Female	60 (10-210)		35 (10-80)	
Virology status (No = 73)				
HCV	80 (5-270)	0.2 ^{NS}	30 (10-195)	0.85 ^{NS}
Combined	180 (180-180)		30 (10-40)	
Treatment				
No treatment	80 (20-180)	0.9 ^{NS}	35 (10-60)	0.64 ^{NS}
Interferon	80 (5-225)		42.5 (10-195)	
Sovaldi	80 (20-270)		30 (10-80)	
Status (No = 29)				
Alive	100 (20-270)	0.07 ^{NS}	30 (10-80)	0.38 ^{NS}
Dead	80 (10-80)		30 (10-60)	
Recurrence (No = 29)				
Yes	70 (10-120)	0.16 ^{NS}	15 (10-30)	0.87 ^{NS}
No	80 (20-270)		35 (10-80)	
Total bilirubin (N = 74)	r = 0.14	0.34 ^{NS}	r = 0.07	0.72 ^{NS}
AST (N = 73)	r = -.09	0.55 ^{NS}	r = 0.14	0.47 ^{NS}
ALT (N = 71)	r = 0.004	0.98 ^{NS}	r = 0.29	0.12 ^{NS}
AFP (N = 69)	r = -0.116	0.46 ^{NS}	r = 0.18	0.37 ^{NS}
Tumor site (N = 76)				
Right lobe	80 (5-270)	0.7 ^{NS}	40 (15-195)	0.25 ^{NS}
Left lobe	80 (20-225)		30 (10-80)	
Tumor size/cm	r = -0.005	0.97 ^{NS}	r = 0.18	0.33 ^{NS}
Tumor size \leq5 cm	80 (5-270)	1 ^{NS}	30 (10-195)	0.78 ^{NS}
Tumor size >5 cm	80 (20-170)		40 (10-60)	
Tumor focality				
Single	80 (10-270)	0.9 ^{NS}	35 (10-80)	0.58 ^{NS}
Multiple	80 (5-225)		30 (20-195)	
Histological type				
Solid	82.5 (5-150)	1 ^{NS}	30 (20-70)	0.86 ^{NS}
Trabecular	80 (20-225)		35 (10-195)	
Mixed	80 (10-270)		30 (10-80)	
Tumor grade : Low	80 (5-270)	0.7 ^{NS}	40 (10-195)	0.44 ^{NS}
Tumor grade : High	82.5 (20-150)		25 (10-70)	
Lymphovascular invasion				
Present	87.5 (5-210)	0.01*	35 (10-70)	0.62 ^{NS}
Absent	60 (10-270)		30 (10-195)	
Surgical margin				
Free	80 (10-270)	0.8 ^{NS}	30 (10-80)	0.63 ^{NS}
Involved	95 (5-120)		35 (20-195)	
Lymph node involvement				
Present	170 (80-270)	0.00*	45 (10-70)	0.31 ^{NS}
Absent	80 (5-225)		30 (10-195)	
Staging				
I	60 (10-120)	0.00*	25 (10-80)	0.72 ^{NS}
II	87.5 (5-225)		30 (20-195)	
III	70 (20- 130)		40 (10-60)	
IV	170 (80-270)		45 (10-70)	
Lumped staging				
Early	80 (5-225)	0.03*	30 (10-195)	0.59 ^{NS}
Advanced	105 (20-270)		40 (10-70)	

No: Number, AST: aspartate transaminase ALT: alanine transaminase, ALP: alkaline phosphatase, AFP: α -fetoprotein, r : Spearman correlation, NS: non-significant.

DISCUSSION

β -catenin is a dual function protein, in addition to its role as a proto-oncogene, it acts also as a critical player in cell-cell adhesion process⁽¹³⁾. β -catenin mutation is an early event in HCC affecting 20-40% of cases⁽¹⁴⁾. Cell membrane localization of β -catenin was observed in normal liver tissue in addition to HCC cases in the absence of significant WNT target gene activation⁽¹⁵⁾. On the other hand, nuclear and/or cytoplasmic location of β -catenin is closely related to WNT activation⁽¹⁶⁾.

In the current study, β -catenin showed membranous expression in 38.8% of cases, while nucleocytoplasmic localization was observed in 25.6%. The percentage of β -catenin membranous localization among HCC cases in several studies showed great variation; it is 27.1%⁽¹⁷⁾, 41.7%⁽¹⁸⁾, 53%⁽¹⁹⁾ and 61%⁽²⁰⁾ of tumor cells. Similar variation was observed also in nuclear with or without cytoplasmic localization; it is 18.5%⁽²¹⁾, 43%⁽²²⁾ and 72.94%⁽¹⁷⁾ of tumor cells.

Intratumor heterogeneity is a common feature of HCC which involves morphologic, immunohistochemical, and mutational status reflecting the complex molecular pathogenesis of this tumor⁽²³⁾. Although CTNNB1 mutations appeared widely distributed within each tumor in β -catenin-induced HCC⁽²⁴⁾, nuclear and cytoplasmic localization of β -catenin seemed to be heterogeneous in both animal models⁽²⁵⁾ and patients⁽²⁶⁾. This heterogeneity in β -catenin immunostaining is mainly due to heterogeneous β -catenin activity and not due to limitations in detection of β -catenin protein. Furthermore, the significance of this heterogeneity remain obscure⁽²⁷⁾.

Regarding the relationship of β -catenin nucleocytoplasmic localization with studied histopathologic parameters of HCC cases, no significant relationship was found with exception of tumor focality in which most HCC cases with single tumor mass were β -catenin negative (79.2%, $P=0.02$). Thus, nucleocytoplasmic localization β -catenin seemed to carry a bad prognostic effect. Surprisingly, membranous expression pattern of β -catenin was linked also with poorer parameters like (increased positivity among high grade cases ($P=0.04$), higher H score value in cases having lymphovascular invasion, positive lymph node and higher (advanced) stages ($P=0.01$, 0.00 , 0.00 & 0.03 respectively). The prognostic role of β -catenin localization in HCC remained unclear with conflicting reports regarding its relation to histopathologic parameters^(13, 14). Nuclear β -catenin carried a good prognosis in some studies⁽²⁸⁾ and bad prognosis in others like us⁽¹⁶⁾. Similar controversial results were also observed regarding the membranous location of β -catenin. Many authors reported membranous expression be associated with better prognosis^(18, 19), others linked

this pattern with unfavorable prognostic factors, which is in accordance with our results⁽²⁹⁾. These contradictory results could be explained by intrinsic tumor heterogeneity, the use of different sources and dilution of the primary antibodies together with different characteristics of the included cases in each study⁽³⁰⁾. Adding more, the prognosis of β -catenin nuclear expression depends on whether β -catenin is present in either mutant type or wild type, which appear functionally distinct. Of note, mutation of axin or adenomatous polyposis coli (APC) can cause nuclear localization of β -catenin in the absence β -catenin gene mutations^(29, 31).

When WNT signaling is off, β -catenin is expressed mainly at the membranous pool where it interacts with several members of cadherin family. At this position, β -catenin can enhance HCC tumor cell survival via activation of growth factor receptors such as epidermal growth factor receptor (EGFR)⁽³²⁾. Furthermore, despite the observation that β -catenin overexpression probably occurs after the initial stages of HCC carcinogenesis, it may be a relatively late event in tumor progression⁽²⁹⁾. All the aforementioned factors could contribute to the bad prognostic effect of membranous β -catenin expression pattern faced in this study.

CONCLUSION

Immunohistochemical expression of β -catenin in the studied HCC cases appeared heterogeneous where β -catenin showed both nucleocytoplasmic and membranous localization. β -catenin membranous expression pattern seemed to have a bad prognostic significance in HCC.

REFERENCES

1. **Rashed W, Kandeil M, Mahmoud M *et al.* (2020):** Hepatocellular Carcinoma (HCC) in Egypt: A comprehensive overview. *J Egypt Natl Canc Inst.*, 32: 5.
2. **Forner A, Reig M, Bruix J (2018):** Hepatocellular carcinoma. *Lancet*, 391: 1301-1314.
3. **Shlomai A, De Jong Y, Rice C (2014):** Virus associated malignancies: the role of viral hepatitis in hepatocellular carcinoma. *Semin Cancer Biol.*, 26: 78-88.
4. **Dhanasekaran R, Bandoh S, Roberts L (2016):** Molecular pathogenesis of hepatocellular carcinoma and impact of therapeutic advances. *F1000Res.*, 5: 879-8784.
5. **Vilchez V, Turcios L, Marti F *et al.* (2016):** Targeting Wnt/ β -catenin pathway in hepatocellular carcinoma treatment. *World J Gastroenterol.*, 22: 823-32.
6. **Gekas C, D'altri T, Aligué R *et al.* (2016):** β -Catenin is required for T-cell leukemia initiation and MYC transcription downstream of Notch1. *Leukemia*, 30: 2002-2010.
7. **Monga S (2015):** β -Catenin Signaling and Roles in Liver Homeostasis, Injury, and Tumorigenesis. *Gastroenterology*, 148: 1294-310.

8. **Torbenson M, Ng I, Park Y *et al.* (2019):** Hepatocellular carcinoma. In: WHO Classification of Tumours Editorial Board, editor. Digestive system tumours. WHO classification of tumours series. 5th ed. Lyon: International Agency for Research on Cancer, 19: 229-39.
9. **Martins-Filho S, Paiva C, Azevedo R *et al.* (2017):** Histological Grading of Hepatocellular Carcinoma-A Systematic Review of Literature. *Front. Med. (Lausanne)*, 4: 193-6.
10. **Amin M, Greene F, Edge S *et al.* (2017):** The Eighth Edition AJCC Cancer Staging Manual: Continuing to build a bridge from a population-based to a more "personalized" approach to cancer staging. *CA Cancer J Clin.*, 67: 93-99.
11. **Lee J, Yang J, Newell P *et al.* (2014):** β -Catenin signaling in hepatocellular cancer: Implications in inflammation, fibrosis, and proliferation. *Cancer Lett.*, 343: 90-7.
12. **Han S, Bai E, Jin G *et al.* (2014):** Expression and clinical significance of YAP, TAZ, and AREG in hepatocellular carcinoma. *J Immunol Res.*, 2014: 261365.
13. **Macdonald B, Tamai K, He X (2009):** Wnt/ β -catenin signaling: components, mechanisms, and diseases. *Dev Cell*, 17: 9-26.
14. **Wang Z, Sheng Y, Gao X *et al.* (2015):** β -catenin mutation is correlated with a favorable prognosis in patients with hepatocellular carcinoma. *Mol Clin Oncol.*, 3: 936-940.
15. **Ren Y, Huang T, Yu H *et al.* (2016):** Expression of β -catenin protein in hepatocellular carcinoma and its relationship with alpha-fetoprotein. *J Huazhong Univ Sci Technolog Med Sci.*, 36: 846-851.
16. **Chen J, Liu J, Jin R *et al.* (2014):** Cytoplasmic and/or nuclear expression of β -catenin correlate with poor prognosis and unfavorable clinicopathological factors in hepatocellular carcinoma: a meta-analysis. *PLoS One*, 9: 111885.
17. **Li P, Cao Y, Li Y *et al.* (2014):** Expression of Wnt-5a and β -catenin in primary hepatocellular carcinoma. *Int J Clin Exp Pathol.*, 7: 3190-5.
18. **Suzuki T, Yano H, Nakashima Y *et al.* (2002):** β -catenin expression in hepatocellular carcinoma: a possible participation of β -catenin in the dedifferentiation process. *J Gastroenterol Hepatol.*, 17: 994-1000.
19. **Tien L, Ito M, Nakao M *et al.* (2005):** Expression of β -catenin in hepatocellular carcinoma. *World J Gastroenterol.*, 11: 2398-401.
20. **Inagawa S, Itabashi M, Adachi S *et al.* (2002):** Expression and prognostic roles of β -catenin in hepatocellular carcinoma: correlation with tumor progression and postoperative survival. *Clin Cancer Res.*, 8: 450-6.
21. **Suarez M, Uribe D, Jaramillo C *et al.* (2015):** Wnt/ β -catenin signaling pathway in hepatocellular carcinomas cases from Colombia. *Ann Hepatol.*, 14: 64-74.
22. **Nhieu J, Renard C, Wei Y *et al.* (1999):** Nuclear accumulation of mutated β -catenin in hepatocellular carcinoma is associated with increased cell proliferation. *Am J Pathol.*, 155: 703-10.
23. **Zhai W, Lim T, Zhang T *et al.* (2017):** The spatial organization of intra-tumour heterogeneity and evolutionary trajectories of metastases in hepatocellular carcinoma. *Nat Commun.*, 8: 4565.
24. **Torrecilla S, Sia D, Harrington A *et al.* (2017):** Trunk mutational events present minimal intra- and inter-tumoral heterogeneity in hepatocellular carcinoma. *J Hepatol.*, 67: 1222-1231.
25. **Qiao Y, Xu M, Tao J *et al.* (2018):** Oncogenic potential of N-terminal deletion and S45Y mutant β -catenin in promoting hepatocellular carcinoma development in mice. *BMC Cancer*, 18: 1093-10102.
26. **Friemel J, Rechsteiner M, Frick L *et al.* (2015):** Intratumor heterogeneity in hepatocellular carcinoma. *Clin Cancer Res.*, 21: 1951-61.
27. **Kalasekar S, Kotiyal S, Conley C *et al.* (2019):** Heterogeneous β -catenin activation is sufficient to cause hepatocellular carcinoma in zebrafish. *Biol Open*, 8 (10): bio047829. <https://pubmed.ncbi.nlm.nih.gov/31575545/>
28. **Hsu H, Jeng Y, Mao T *et al.* (2000):** β -catenin mutations are associated with a subset of low-stage hepatocellular carcinoma negative for hepatitis B virus and with favorable prognosis. *Am J Pathol.*, 157: 763-70.
29. **Wong C, Fan S, Ng I (2001):** β -Catenin mutation and overexpression in hepatocellular carcinoma: clinicopathologic and prognostic significance. *Cancer*, 92: 136-45.
30. **Zhang S, Wang Z, Shan J *et al.* (2016):** Nuclear expression and/or reduced membranous expression of β -catenin correlate with poor prognosis in colorectal carcinoma: A meta-analysis. *Medicine (Baltimore)*, 95: 5546.
31. **Satoh S, Daigo Y, Furukawa Y *et al.* (2000):** AXIN1 mutations in hepatocellular carcinomas, and growth suppression in cancer cells by virus-mediated transfer of AXIN1. *Nat Genet.*, 24: 245-50.
32. **Kim E, Lisby A, Ma C *et al.* (2019):** Promotion of growth factor signaling as a critical function of β -catenin during HCC progression. *Nat Commun.*, 10: 1909-12.