



Normal Variations in Sphenoid and Their Significance Regarding Endoscopic Sinus Surgeries: Multislice Computed Tomographic Study

Akram Shahat Abdo¹, Marwa Makboul Ahmed², Ahmed H. Monib¹

1. Department of Otorhinolaryngology, Assiut University, Assiut, Egypt

2. Department of Radiology, Assiut University, Assiut, Egypt

Abstract:

Background: Sphenoid sinus (SS) is one of the most variables of all sinuses and its relation to vital vascular and nervous elements as optic nerve (ON), cavernous sinus, pituitary gland, and internal carotid arteries. This makes its transsphenoidal approach a challenge for functional endoscopic sinus surgeries (FESS). We aimed to delineate SS radiologically using multislice computed tomography (MSCT), to show normal variations in pneumatization pattern, septation, intercarotid distance, bony covering of carotid artery and ON, to provide successful and safe FESS -transsphenoidal surgeries and to decrease morbidity and mortality during its surgeries.

Methods and materials: A prospective observational study on 210 patients from May 2017 to July 2019 was conducted and included all cases requiring MCTS, with free sphenoid sinus. We excluded patients who have pathology in SS, or previous SS surgery.

Results: Onodi cells presented in 67 of cases case (31.9%) from whom 30 cases (14.3%) were bilateral, and 143 cases were absent (68.1%). Pneumatization of SS, sellar (adult) type is the most common type of pneumatization that presented in 160 cases (76.2%), presellar (juvenile) type in 48 cases (22.9%), then conchal (fetal) type only in 2 cases (0.95%). The relation between pneumatization of anterior clinoid process (ACP) and dehiscence of ON showed that among 168 cases who had absent ACP pneumatization, 159 of them showed no ON dehiscence (94.6%). Pneumatization of greater wing of sphenoid was in 28 cases (41.8%). Type I ON presented in 321 cases (76.4%), type II was in 54 (12.8%), type III was in 21 (5%), and type IV was in 24 cases (5.7%). Inter sphenoid septum was found in 119 cases (56.7%), multiple septa were found in 87 (41.4%), and no septum in 4 cases (1.9%). Dehiscence in carotid artery occurred in 17% of cases.

Conclusion: We concluded SS variations, septation pattern, type of pneumatization, and onodi cells. All that will help preoperative regarding transsphenoidal surgeries, as that decrease morbidity and mortality by avoiding injury of important structures.

Keywords: Sphenoid sinus; Pneumatization; Onodi; Internal carotid; optic nerve.

Introduction

Sphenoid sinus (SS) is a sinus that grows up after birth. It is notorious by the pneumatization progression that launches from the sixth age till the ninth/twelve years. This sinus is described as the most variable human cavity.¹⁻² The concern about SS is its

location in the body of the sphenoid bone, closed with a thin plate of bone tissue that separates it from the surrounding structures: the optic nerve (ON), optic chiasm, cavernous sinus, pituitary gland, and internal carotid arteries (ICA).³ Therefore, the infection of SS is exposing those structures

causing serious complications. This proximity of the SS to vital vascular and nervous elements hails any surgical interference as a challenge for surgeons.²

Since 1907, the transsphenoidal surgery to combat the intrasellar lesions was superior to other approaches as the transcranial approach. Furthermore, the pneumatization of the sphenoidal sinus opens a gate to the skull parts which varies according to both direction and degree of the sphenoid sinus.⁴ With the recent advancement in the endoscopic sinus surgeries (including both the transsphenoidal approach and the intracranial approach), the need to explore the meticulous anatomy of the sphenoid sinus and its variations.⁵

To avoid any complication (iatrogenic lesions) and have a full picture for the pathological status of the SS; the radiological examination of the sinus and its variations have a necessity for a safe and functional endoscopic sinus surgery.⁶ Additionally, the SS and its pneumatization pattern represents a high value in the surgical access to the pituitary gland and other skull members (septation pattern, intercarotid distance (in millimetres), bony covering of carotid artery, and bony covering of ON); hence, the full illustration of their anatomical variation is critical for decreasing morbidity and mortality.⁷

In this study, our work is focused to use the multislice computed tomography (MSCT) to depict the sphenoid sinus, radiologically. In addition, we investigated the pneumatization pattern, septation, intercarotid distance, bony covering of carotid artery and ON to support the medical community with a better illustration for the SS. This investigation is going to help in reducing the risk of the endoscopic/transsphenoidal surgeries

and cut down the morbidity/mortality rates of the skull surgeries.

Patients and Methods:

This observational cross-sectional study was conducted at the department of otorhinolaryngology at Assiut university hospital between May 2017 and July 2019, after the acceptance of the ethical committee of the university with IRB approval code (17100092). The protocol of study was uploaded in clinical trial.gov with registration code (NCT03222934).⁸

All patients underwent this study needed a multislice computed tomography study and accepted to be a part of this study. All patients showed infected SS or previous surgical intervention for SS were excluded from this study. Also, all patients with tumors or inflammatory diseases that may alter the anatomical landmarks of the SS were excluded. The privacy of all participants in this study was protected through a double-blind methodology. The study participants were not identified by name in any reports or publications resulted from data collected in this study. CT on the nose and paranasal sinuses were done for all cases studied. Axial images of CT were obtained with a slice thickness of less than 1 mm. Coronal and sagittal images were obtained by reformatting the axial images, using a software program (Radiant DICOM Viewer 64-bit). The outcomes were evaluated by a radiologist and a rhinologist. All cases requiring a multislice computed tomography study, with free sphenoid sinus, had a high-resolution CT image of the sinuses and skull base. Images were analyzed and measurements were performed using the software program. Axial and sagittal images were obtained

and analyzed from 210 patients undergoing imaging for various pathologies including mastoid and petrous tumors and inflammatory diseases.

Statistical analysis:

All of our cases were analyzed for their age, sex, ondoi air cells, pneumatization pattern, pneumatization of anterior clinoid process (ACP), pneumatization of the greater wing of the sphenoid, type of ON, dehiscence of optic nerve canal (ONC), septation, bony covering of carotid artery and bony covering of ON.

The data were tested for normality and for homogeneity variances prior to further statistical analysis using the Anderson-Darling test. Categorical variables were described by number and per cent (N, %), while continuous variables described by the mean and standard deviation (Mean, SD). Chi-square test and Fisher exact test used to compare categorical variables. A two-tailed $p < 0.05$ was considered statistically significant. All analyses were performed with the IBM SPSS 20.0 software.

Results:

Demographic distribution:

This study included 210 cases; among them, 148 were males (70.5%), while 62 were females (29.5%). The ages ranged from 20-88 years, while the mean age was 40.27 ± 16.78 years.

From the 210 MSCT images; the various dimensions of sphenoid sinus were measured. Concerning the demographic distribution, there was no statistical significance (**Table 1**).

CT scan findings:

Ondoi cells: The MSCT images showed that Onodi cells were presented in 67 cases (31.9%). From those cases,

30 cases (14.3%) were bilateral and 25 cases (11.9%) were on the right side. However, 12 (5.7 %) cases were on the left side while those cells were not present in 143 cases (68.1%) (Table 1).

Type of pneumatization: Table 1 showed that according to pneumatization of the sphenoid sinus; the sellar (adult) type is the most common type of pneumatization recording 160 cases (76.2%); where 114 cases were males while 46 were females [male/female ratio, (71.3%)/(28.8%)] (Figure 1A). The second place was preserved for the pre-sellar (juvenile) type which is recorded in 48 cases (22.9%); 33 of them were males while 15 females [male/female ratio, (68.8%)/(31.3%)] (Figure 1B). Then the conchal (fetal) type was present in only two cases (0.95%; one male). Overall, there is no statistically significant difference between males and females regarding the type of pneumatization (Figure 1C).

Pneumatization of anterior clinoid process: In our study, we found that pneumatization of the anterior clinoid process (ACP) was existent in 42 cases (20%), where the bilateral was present in 16 cases (7.6%). The ACP was unilateral in 26 cases (12.3%), where 15 cases were on the right side (11/4 M/F), while 11 were on the left side (5.2%) (9/2 M/F). The rest of cases showed no pneumatization (114/54 M/F). Our results showed no statistically significant difference between males and females regarding pneumatization of ACP (Table 1).

Types		Values
Males (p-value)		148 (0.72)
Age (range)		20-88
Ondoi Cells (N, %)		67 (31.9%)
	Bilateral	30 (14.3%)
	Right	25 (11.9%)
	Left	12 (5.7%)
Type of pneumatization:		
	Sellar	160 (76.2%)
	Pre-sellar	48 (22.9%)
	Conchal	2 (0.95%)
Pneumatization of anterior clinoid process (N, %)		42 (20)
	Bilateral	16 (7.6%)
	Right	15 (7.1%)
	Left	11 (5.2%)
	Not pneumatized	168 (80%)
Pneumatization of greater wing of sphenoid (N, %)		61 (29%)
	Bilateral	25 (11.9%)
	Right	19 (9%)
	Left	17 (8%)
	Not pneumatized	149 (71%)
Type of optic nerve (N, %)		420
	Type I	321 (76.4%)
	Type II	54 (12.8%)
	Type III	21 (5%)
	Type IV	24 (5.7%)
Optic nerve canal dehiscence (N, %)		30
	Bilateral	9 (2.14%)
	Right	8 (1.9%)
	Left	13 (3.1%)
	Not dehiscent	381(90.7)
Number of bony septa within SS (N, %)		
	One	119 (56.7%)
	Multiple	87 (41.4%)
	No	4 (1.9%)
Bony coverage of right carotid artery (N, %)		
	Dehiscent	17(8.09%)
	Not dehiscent	193(91.9%)
Bony coverage of left carotid artery (N, %)		
	Dehiscent	19(9.1%)
	Not dehiscent	191(90.9%)

Table 1. Characteristics data and Demographic distribution of included patients

Relation between pneumatization of ACP and dehiscence of ONC: This relation was studied as shown in Table 2. Our study proved that among 168 cases who showed the absence of ACP pneumatization; 159 of them showed no ONC dehiscence (94.6%) while only nine cases proved dehiscent on ONC where two cases of them were bilateral (1.2%), 4 at right side (2.4%) and three on the left side (1.8%). Moreover, the bilateral ACP pneumatization occurred in 16 cases where 10 of them showed no ONC dehiscence (62.5%). Only three cases proved bilateral ONC dehiscence (18.8%) where all of them showed left ONC dehiscence (18.8%). Furthermore, the right ACP pneumatization took place in 15 cases, where eight of them showed no ONC dehiscence (53.3%), three cases showed bilateral ONC dehiscence (20%) and four cases showed right ONC dehiscence (26.7%). Coming to the left ACP pneumatization which was seen in 11 cases; three of them showed no ONC dehiscence (27.3%), one case showed bilateral ONC dehiscence (9.1%), and seven cases showed left ONC dehiscence (63.6%).

Pneumatization of the greater wing of the sphenoid: Pneumatization of the greater wing of the sphenoid in our study was seen in 61 cases (29 %). The pneumatization was unilateral in 36 cases (19 cases on the right side and 17 cases on the left side) and bilateral in 25 cases (11.9 %) (Table 1).

Table 2: Comparison between pneumatization of the ACP and Dehiscence of ONC

Dehiscence of ONC	Pneumatization of ACP								P. value
	No (n=168)		Bilateral (n=16)		Right (n=15)		Left (n=11)		
	No.	%	No.	%	No	%	N	%	
No.	159	94.6	10	62.5	8	53.3	3	27.3	0.000**
Bilateral	2	1.2	3	18.8	3	20.0	1	9.1	
Right	4	2.4	0	0.0	4	26.7	0	0.0	
Left	3	1.8	3	18.8	0	0.0	7	63.6	

Chi-square test, * Statistically significant difference ($p < 0.05$), **Highly statistically significant difference ($p < 0.01$). Note: optic nerve canal (ONC); anterior clinoid process (ACP).

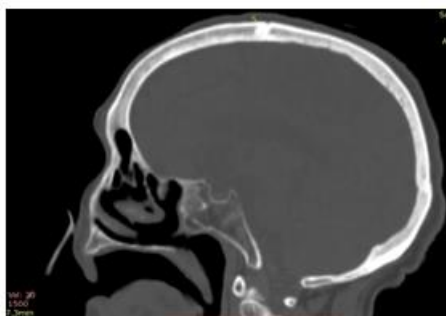


Figure (1A): sagittal MSCT revealed the conchal type of sphenoid sinus pneumatization.

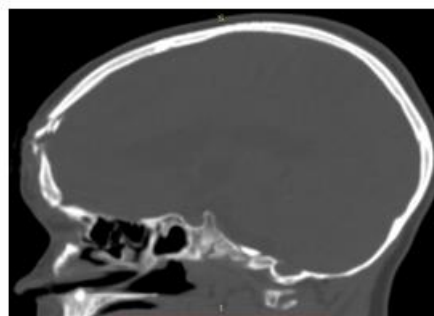


Figure (1B) : Sagittal MSCT show presellar type of sphenoid sinus pneumatization.

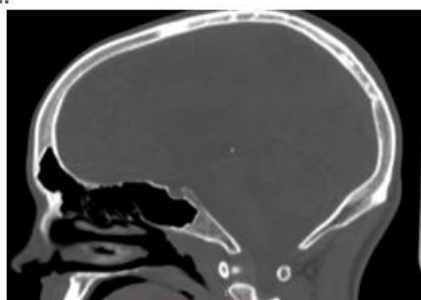


Figure (1C): Sagittal MSCT show sellar type of sphenoid sinus pneumatization.

Figure 1. Sagittal MSCT show different types of sphenoid sinus pneumatization

Table 3. Comparison between onodi cells and pneumatization of the anterior clinoid

Pneumatization of anterior clinoid process	Onodi cells				X ²	P. value
	No (n=143)		Yes (n=67)			
	No.	%	No.	%		
No	12	88.1	42	62.	18.433	0.000**
	6			7		
Yes	17	11.9	25	37.		
				3		
Pneumatization of the greater wing of sphenoid process, pneumatization of greater wing of sphenoid						
	No.	%	No.	%		
No	11	76.9	39	58.2	7.753	0.005**
	0					
Yes	33	23.1	28	41.8		

Table 4: Comparison between dehiscence of ONC and type of ON

Type of ON	Dehiscence of ONC								P. value
	Not dehiscent (n=381)		Bilateral (n=18)		Right (n=8)		Left (n=13)		
	No.	%	No.	%	No.	%	No.	%	
Type I	321	84.2	0	0.0	0	00.0	0	00.0	0.000**
Type II	40	10.5	6	33.3	3	37.5	5	38.4	
Type III	10	2.6	2	11.1	3	37.5	6	46.1	
Type IV	10	2.6	10	55.6	2	25	2	15.3	

Chi-square test, * Statistically significant difference ($p < 0.05$), **Highly statistically significant difference ($p < 0.01$)

Table 5. Bony coverage of right and left carotid artery

	Range	Mean \pm SD
Bony coverage of right carotid artery (mm)	0.4-1.9	1.07 \pm 0.36
Bony coverage of left carotid artery (mm)	0.4-2.5	1.13 \pm 0.42

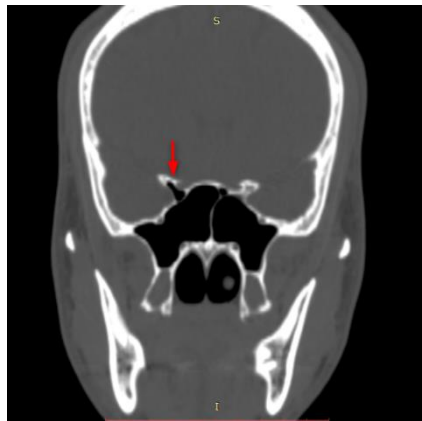
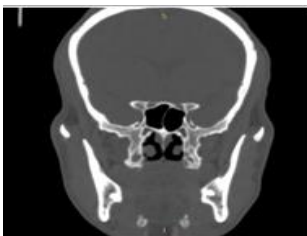

Figure 2. Male patient 35 years old, coronal MSCT revealed right anterior clinoid process pneumatization (arrow), with bilateral pterygoid process pneumatization



Figure(3A): Coronal CT showing type I optic nerve (arrows) the nerve is seen to course immediately adjacent to the sphenoid sinus, without contact with the posterior ethmoid air cell

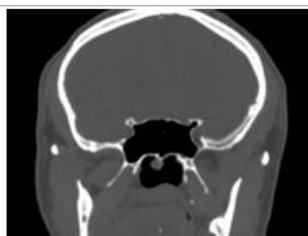

Figure (3B): Coronal CT showing type II optic nerve (arrows)causing an indentation of the sinus wall, but without contact with the posterior ethmoid air cell

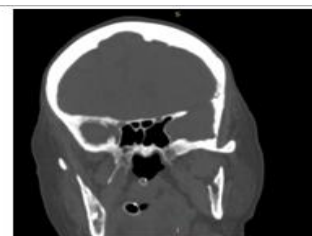

Figure (3C)Coronal CT shows type III optic nerve at left side (arrow) where more than 50% of the nerve is surrounded by air

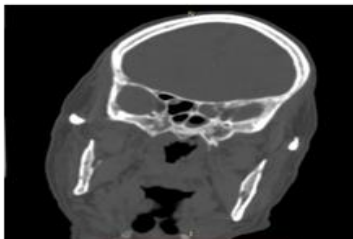


Figure (3D): Coronal CT showing type IV optic nerve on the right (arrow)-The nerve course lies immediately adjacent to the sphenoid and posterior ethmoid sinus.

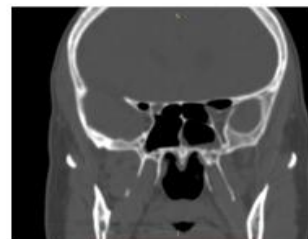


Figure (3E): Coronal CT showing type IV optic nerve bilaterally (arrow)-The nerve course lies immediately adjacent to the sphenoid and posterior ethmoid sinus. Blue circle: Onodi cell;

Figure 3. Coronal CT showing different types of optic nerve and its dehiscence

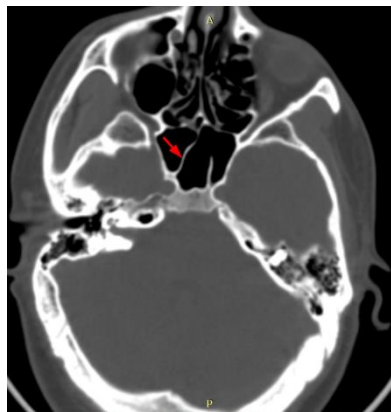


Figure 4. Axial MSCT shows the main and accessory sphenoid septum with main sphenoid septum deviated to the right(arrow); it is seen to insert over the bone covering the right internal carotid artery canal.

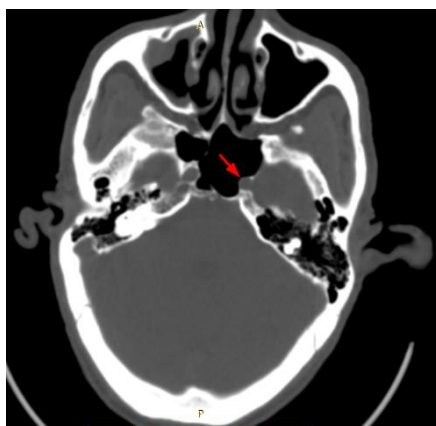


Figure 5. Axial MSCT show dehiscent left internal carotid artery bony wall (arrow)

Relation between onodi cells and pneumatization of ACP and pneumatization of greater wing of sphenoid: This relation was investigated in Table 3. For instance, of the 67 onodi cells including cases; we found 25 cases showed ACP pneumatization and 28 cases share pneumatization of the greater wing of the. Overall the Onodi cells, the ACP and the pneumatization of the greater wing of sphenoid were absent in 143, 126, and 33, respectively.

Type of ON and its dehiscence: The ONs in our cases varied to include type I, II, III and IV with percent of 76.4%, 12.8%, 5% and 5.7%, respectively (Figure 2) (Table 1).

Relation between dehiscence of ONC and type of ON: The ON dehiscence was bilaterally in 9 cases, 5 of them were type 4 ON (55.6%), and 3 of them were type 2 ON (33.3%), and one case was type 3 ON (11.1%). ON dehiscence on the right side was in 8 cases, 3 cases were type 2 ON (37.5%), and 3 of them were type 3 ON (37.5%) and 2 cases with type 4 ON (25%). ON dehiscence on the left side was in 13 cases, 5 of them were type 2 ON (38.4%), and 6 of them were type 3 ON (46.1%) and 2 of them with type 4 ON (15.3%) (Table 4).

Inter sphenoid septa: In our study; the single inter sphenoid septum was

found in 119 of cases (56.7%), while the multiple septa were found in 87 cases (41.4%) (Supplementary Figure 3).

Bony coverage of right and left carotid artery: The range of bony coverage of right and left carotid artery was (0.4–1.9) and (0.4–2.5), respectively. While mean of right and left carotid artery was (1.07 ± 0.36) and (1.13 ± 0.42) , respectively (Table 5).

Discussion:

With the considerable expansion in the endoscopic sinus surgeries; there is a rising need to investigate all the aspects of the anatomical variation in the sphenoidal sinus through radiology.⁹ Of 215 included case in our study; we figured that the sellar type of sphenoid sinus pneumatization prevailed, while the conchal type was the least common. This is backed by previous reports^{6,10-12} where they proved the majority of the adult type of pneumatization in the sphenoidal sinus and the scarce of the fetal type.

Coming for the pneumatization of ACP; we hailed it in 42 cases (20%) with being bilateral in 16 cases (7.6%), and unilateral in 26 cases (12.3%). Also, those results did not go far away from the published studies.¹³⁻¹⁴ On the other side, the pneumatization of the greater

wing of the sphenoid was noticed in 29 % of our cases where the cases were bilateral/unilateral with 11.9/29. The greater wing pneumatization varied in the literature to be 5.1% in a study ¹⁵, while it is reported to be 21% in another one. ¹⁶ We may stem that back to the sample tested in both studies.

In addition, our study figured that 56.7% of our cases were with single inter sphenoid septum, while 41.4% were with multiple septa. The variation in the incidence of sphenoidal septation pattern caused a variation in the literature-including data. A report ¹⁷ found that the multiple intersinus septae happened in 80 % of the cases. On the opposite, **Miranda et al.** ¹⁸ revealed that at least one of the septa is inserted on the carotid canal in 87% of cases. However, the multiple septa recorded only 31 % of cases in **Alshaikh et al** ¹⁹.

For the onodi cells, these cells were present in 67 cases (32%); of whom 30 cases (14.3%) were bilateral, 25 cases (11.9%) on the right side, while the left side occurred in 12 cases (5.7 %). These results were close with other studies' results where the onodi cells were existent in 22.5%. ²⁰ Another study reported the rate to be 15.5% of Onodi cells. ²¹

The optic nerve studies were classified into type I (without indentation on the wall of sphenoid sinus), type II (with indentation but with no contact with the posterior ethmoidal cell), type III (with contact with the posterior ethmoidal cell) and type IV (the nerve is adjacent to the Onodi cell). ²² Our study could reveal that type one was presented 321 times, type II was presented 54 times, type III was presented 21 times and type IV was presented 24 times. In addition, the optic nerve dehiscence was bilaterally present in 9 cases, 5 of them with type 4 ONC (55.6%), 3 of them with type 2 ONC

(33.3%) and one case in type 3 ONC (11.1%). **Dalenome et al** ²² had comparable results.

In our study we found that right carotid artery was dehiscent in 17 cases (8%) and left carotid artery was dehiscent in 19 cases (9%), so dehiscence in the carotid artery (right or left) was (17 %). This result is incompatible with a study recording the dehiscence of the artery, which may be related to the by the new criteria for defining protrusion and dehiscence. ¹³

Conclusion:

This work is presenting the variations of sphenoidal sinus, radiologically. We managed to show the vital neurovascular relations; as ICA and ONC. In addition, we explained the relations between those variations, septation patterns and type of pneumatization. We showed the presence/absence of onodi cells and we compared our results with previous studies showing how vital to assess such information.

Ethical approval

All procedures performed in our study that involved human participants were in accordance with the ethical standards of the institutional and/or national research committee and with the 1964 Helsinki declaration and its later amendments or comparable ethical standards version 2002.

Ethical approval was taken from Institutional Review Board from XXX with IRB code (17100092). All patients signed informed written consent prior study started without receiving any received any stipend, and they were informed about study requirements.

Author contributions

AHM was responsible for the idea. Data collection was done by MMA. Data analysis, and its interpretation, as well as Tables and figures were done by GMT GMT and ASA. All authors contributed to the manuscript writing and approval of the final version.

Conflicts of interest: None of the authors have any conflicts of interest to declare.

Acknowledgments: None.

References:

1. Simonetti G, Meloni F, Teatini G, Salvolini U, Rovasio S, Masala W, et al. Computed tomography of the ethmoid labyrinth and adjacent structures. 1987;96(3):239-50.
2. Wang J, Bidari S, Inoue K, Yang H, Rhoton Jr AJN. Extensions of the sphenoid sinus: a new classification. 2010;66(4):797-816.
3. Odat H, Almardeeni D, Tanash M, Al-Qudah M. Anatomical variation of the sphenoid sinus in paediatric patients and its association with age and chronic rhinosinusitis. *J Laryngol Otol.* 2019;1-5.
4. Štoković N, Trkulja V, Dumić-Čule I, Čuković-Bagić I, Lauc T, Vukičević S, et al. Sphenoid sinus types, dimensions and relationship with surrounding structures. 2016;203:69-76.
5. Halawi AM, Simon PE, Lidder AK, Chandra RK. The relationship of the natural sphenoid ostium to the skull base. *The Laryngoscope.* 2015;125(1):75-9.
6. Štoković N, Trkulja V, Dumić-Čule I, Čuković-Bagić I, Lauc T, Vukičević S, et al. Sphenoid sinus types, dimensions and relationship with surrounding structures. *Annals of Anatomy - Anatomischer Anzeiger.* 2016;203:69-76.
7. Wang S-S, Xue L, Jing J-J, Wang R-M. Virtual reality surgical anatomy of the sphenoid sinus and adjacent structures by the transnasal approach. *Journal of Cranio-Maxillofacial Surgery.* 2012;40(6):494-9.
8. Cortellini D, Canale A. Bonding lithium disilicate ceramic to feather-edge tooth preparations: a minimally invasive treatment concept. *Journal of Adhesive Dentistry.* 2012;14(1):7.
9. Reddy UDMA, Dev B. Pictorial essay: Anatomical variations of paranasal sinuses on multidetector computed tomography-How does it help FESS surgeons? *The Indian journal of radiology & imaging.* 2012;22(4):317.
10. Hamid O, El Fiky L, Hassan O, Kotb A, El Fiky S. Anatomic variations of the sphenoid sinus and their impact on trans-sphenoid pituitary surgery. *Skull base.* 2008;18(01):009-15.
11. Lupascu M, Comsa GI, Zainea V. Anatomical variations of the sphenoid sinus-a study of 200 cases. *ARS Medica Tomitana.* 2014;20(2):57-62.
12. Seddighi A, Seddighi A, Mellati O, Ghorbani J, Raad N, Soleimani MM. Sphenoid Sinus: Anatomic Variations and Their Importance in Trans-sphenoid Surgery. *International Clinical Neuroscience Journal.* 2014;1(1):31-4.
13. Budu V, Mogoanta CA, Fanuta B, Bulescu I. The anatomical relations of the sphenoid sinus and their implications in sphenoid endoscopic surgery. *Rom J Morphol Embryol.* 2013;54(1):13-6.
14. Rahmati A, Ghafari R, AnjomShoa M. Normal variations of sphenoid sinus and the adjacent structures detected in cone beam computed tomography. *Journal of Dentistry.* 2016;17(1):32.
15. Elkammash TH, Enaba MM, Awadalla AM. Variability in sphenoid sinus pneumatization and its impact upon reduction of complications following sellar region surgeries. *The*

- Egyptian Journal of Radiology and Nuclear Medicine. 2014;45(3):705-14.
16. Yeğin Y, Çelik M, Altıntaş A, Şimşek BM, Olgun B, Kayhan FT. Vidian canal types and dehiscence of the bony roof of the canal: an anatomical study. Turkish archives of otorhinolaryngology. 2017;55(1):22.
 17. Sareen D, Agarwal A, Kaul J, Sethi A. Study of sphenoid sinus anatomy in relation to endoscopic surgery. Int J Morphol. 2005;23(3):261-6.
 18. Fernandez-Miranda JC, Prevedello DM, Madhok R, Morera V, Barges-Coll J, Reineman K, et al. Sphenoid septations and their relationship with internal carotid arteries: anatomical and radiological study. The Laryngoscope. 2009;119(10):1893-6.
 19. Alshaikh N, Aldhuraish A. Anatomic variations of the nose and paranasal sinuses in Saudi population: computed tomography scan analysis. The Egyptian Journal of Otolaryngology. 2018;34(4):234.
 20. Yazici D. The effect of frontal sinus pneumatization on anatomic variants of paranasal sinuses. European Archives of Oto-Rhino-Laryngology. 2019;276(4):1049-56.
 21. Mokhasanavisu VJP, Singh R, Balakrishnan R, Kadavigere R. Ethnic Variation of Sinonasal Anatomy on CT Scan and Volumetric Analysis. Indian Journal of Otolaryngology and Head & Neck Surgery. 2019.
 22. DeLano MC, Fun F, Zinreich SJ. Relationship of the optic nerve to the posterior paranasal sinuses: a CT anatomic study. American journal of neuroradiology. 1996;17:669-75.