



# Microbes and Infectious Diseases

Journal homepage: <https://mid.journals.ekb.eg/>

## Continuous Medical Education Forum (CME from EB)

## Continuous medical education activities; Case No. 4

**Mai Maamoun\***

*Medical Microbiology and Immunology Department, Faculty of Medicine, Zagazig University.*

### ARTICLE INFO

#### Case history:

Received 10 December 2020

Received in revised form 12 January 2020

Accepted 14 January 2020

#### Keywords:

Urinary tract infection

Beta-hemolytic

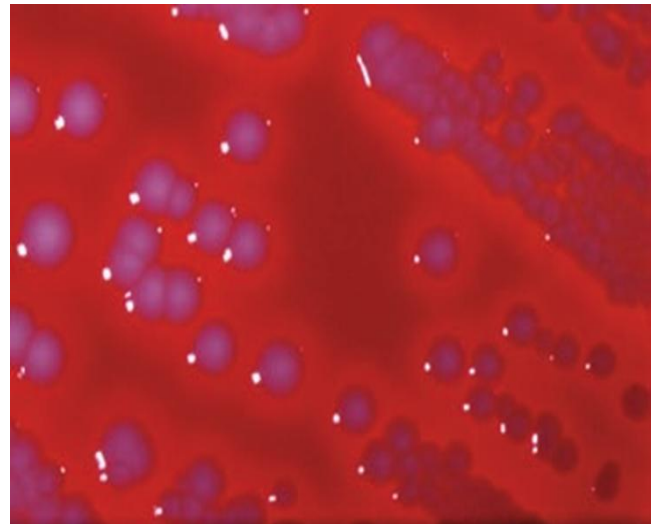
Antimicrobial resistance

A 19-years-old female patient was admitted to the outpatient clinic. She gave a history of urinary tract infection (UTI) 4 months preceding admission for which she was treated with oral ampicillin without complications. Five days prior to this admission, she began to complain nausea without vomiting. One day later, she developed left flank pain, fever, and chills, and increased micturition frequency. She was admitted to a general hospital. She noted foul-smelling urine on the day before admission. She was presented with a temperature of 38.8°C (To be continued..).

A 19-years-old female patient was admitted to the outpatient clinic. She gave a history of urinary tract infection (UTI) 4 months preceding admission for which she was treated with oral ampicillin without complications. Five days prior to this admission, she began to complain nausea without vomiting. One day later, she developed left flank pain, fever, and chills, and increased micturition frequency.

She was admitted to a general hospital. She noted foul-smelling urine on the day before admission. She was presented with a temperature of 38.8°C. Physical examination showed left costovertebral angle tenderness. Urinalysis of a clean catch urine sample was notable for >50 white blood cells per high-power field, 8-10 red blood cells per high-power field, and 3+ bacteriuria. Urine culture was subsequently positive for >10<sup>5</sup> CFU of an organism per ml (seen growing on culture in **figure (1)** [sheep blood agar] and **figure (2)** [MacConkey agar]). Note that the organism is beta-hemolytic.

**Figure 1.** Sheep blood agar showing mucoid, beta-hemolytic colonies.



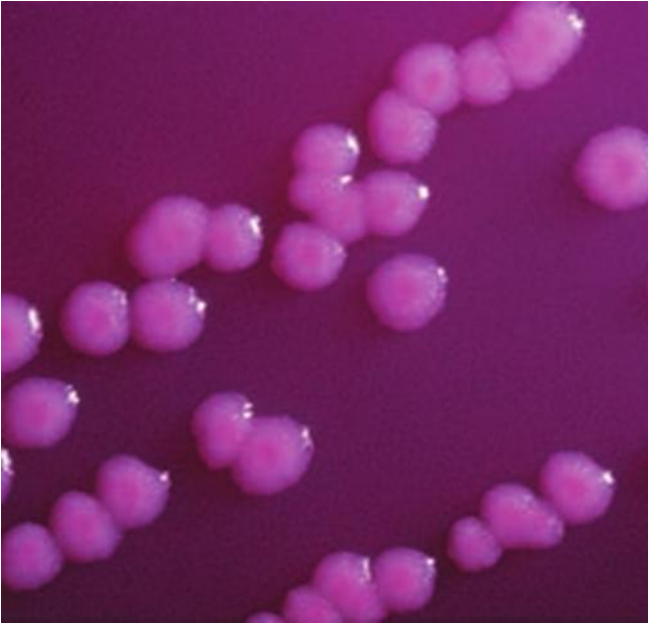DOI: 10.21608/mid.2021.139661

\* Corresponding author: Mai Maamoun

E-mail address: mai030@hotmail.com

© 2020 The author (s). Published by Zagazig University. This is an open access article under the CC BY 4 license (<https://creativecommons.org/licenses/by/4.0/>),

**Figure 2.** MacConkey agar showing mucoid, lactose fermenting colonies.



- 1-Interpret the urinalysis report?
- 2-Why were the numbers of organisms in her urine quantitated on culture? How would you interpret the culture results in this case?
- 3-What is the name of this organism?
- 4-This bacterium was resistant to ampicillin. What in this patient's history might explain this observation? Multidrug-resistant strains of this organism are beginning to be seen as an important cause of UTI. Describe the mechanism of resistance that these organisms most likely will have.
- 5-Why UTIs are more frequent in women than men?
- 6-Did this woman have cystitis or pyelonephritis? Why is it important to differentiate between the two?
- 7-Briefly explain the evolution of the organism causing this infection in terms of its ability to infect the urinary tract. What virulence factors have been shown to play a pathogenic role in this infection?

**To cite this article:** Maamoun M. Continuous medical education activities, Case No. 4. Microbes Infect Dis 2021; 2(1): 1-2.