

Possible Protective Role of Aphanizomenon Flos-Aquae (AFA) Food Supplement against Cerebellum Neuronal Injury Induced by Gamma Radiation (Histological, Histochemical and Immunohistochemical Study)

Mohamed Nasr^{1*} MD., Wagih M. Abdelhay¹ MD., Ahmed Kamal Elbana² MD.

*** Corresponding Author:**

Mohamed Nasr

mohammedmsn2013@gmail.com

Received for publication November 25, 2020; Accepted January 15, 2021; Published online January 15, 2021.

Copyright 2020 The Authors published by Al-Azhar University, Faculty of Medicine, Cairo, Egypt. All rights reserved. This an open-access article distributed under the legal terms, where it is permissible to download and share the work provided it is properly cited. The work cannot be changed in any way or used commercially.

doi: 10.21608/aimj.2021.51081.1359

¹Department of Histology, Faculty of Medicine, Al-Azhar University, Cairo, Egypt.

²Department of Anatomy & Embryology, Faculty of Medicine, Al-Azhar University, Cairo, Egypt.

ABSTRACT

Background: Exposure to radiation alters the equilibrium of the protection mechanism by producing of free radicals, resulting in an imbalance in prooxidant, antioxidant status inside the cells. Oxidative stress has been shown to affect our nervous system. Natural dietary supplements have been shown to have antioxidant properties which can protect our bodies against free radicals. For example, Aphanizomenon flos-aquae (AFA) is a specific dietary supplement that has clinically proven health-promoting effects especially on the nervous system. AFA grows and is harvested from nature.

Aim of the work: Our goal of this research is to study the radio-protective impact of AFA as a natural antioxidant on the cerebellar neuronal cells of adult albino rats against the gamma radiation damaging effects.

Material and methods: The present research was performed on 24 adult male local strain albino rats weighed 120±3 g and equally divided into Group 1(C, control), Group 2 (A, AFA extract treated): rats were ingested daily AFA extract (94.5 mg/kg body weight) for one month. Group 3 (I, Irradiated): rats were irradiated 6 Gy delivered as a fractionated doses of gamma radiation (2 Gy each 3 days). Group 4 (I+A, Irradiated+AFA extract treatment) rats were exposed to a combination of irradiation (in the same way like group 3) plus oral intake of AFA extract for one month. For histologic, histochemical, immunohistochemical and morphometric analysis, cerebellum paraffin sections were prepared. Data has been analyzed statistically.

Results: Sections studied demonstrated significant cellular damage in group 3 relative to the control groups. Group 4 demonstrated obvious reduction in pathological changes occurring in comparison with group 2.

Conclusion: These findings indicate that AFA has a radio-protective function as it decreases pathological cellular injuries in the cerebellar neuronal cells caused by chronic radiation exposure doses.

Keywords: Cerebellum; AFA; Radiation; Immunohistochemical; GFAP.

Disclosure: The authors have no financial interest to declare in relation to the content of this article. The Article Processing Charge was paid for by the authors.

Authorship: All authors have a substantial contribution to the article.

INTRODUCTION

Exposure to radiation alters balance of the defense system through generation of free radicals resulting in an imbalance in prooxidant, antioxidant status inside the cells.^{1,2} The biological adverse radiation effects are largely due to oxidative stress. This stress causes damage to DNA and eventual cell death.^{3,4} Ionizing radiation affects the atoms or cell molecules, and then biological disruption to cell functions later follows.⁵ Free radicals are molecules that lack one electron that they are usually pair with it to be stabilized again, free radicals randomly grab electrons from other healthy molecules. The reaction leads to the development of and replication of new free radicals in a radical cascade.^{1,2}

Scientific researches showed that the bioavailability and defensive efficacy of antioxidants taken from natural sources (mainly food) is greater than that of synthetic one.⁶ Aphanizomenon flos-aquae (AFA) is a blue-green algal filamentous species collected from Upper Klamath Lake in Klamath Falls, Oregon, each summer. AFA was marketed for some 20 years as a food supplement as the nutritional benefits of AFA have been appreciated by a lot of people.^{7,8}

Aphanizomenon flos-aquae (AFA) directly metabolize air molecular nitrogen and several low molecular weight peptide groups are synthesized. These low molecular weight peptides are known to be precursors of neurotransmitters that are used by different regions of the brain and body to induce the

secretion of certain substances and affect metabolic functions.^{7,8}

The cerebellar neuronal cells has ability to generate and use neurotransmitters depends on food consumption and subsequently the concentration of amino acids in the bloodstream.^{9,10} Also, AFA was considered a good source of essential fatty acids such as Omega-3 and Omega-6 which support immune system and create myelin sheaths around the neural fibers in the brain.¹¹

Consumption of AFA had been found to improve many medical conditions such as Alzheimer's disease, improving the immune response, increasing fertility, reducing tumors size and occurrence, improving digestion, increasing stamina, increasing mental acuity, reducing cholesterol and protecting against radiation.^{12,13}

Glial Fibrillary Acidic Protein (GFAP) is a type III intermediate filament marker of astroglial injury, which is part of the cytoskeleton, but is not present outside the CNS of mature astrocytes and other glial cells.¹⁴

MATERIAL AND METHODS

Animals

Twenty four adult male albino rats with a weight of {120- 140g} have been used in this study. Until the experiment started they were kept under observation for a week to acclimatize. All the animals were fed on a regular diet (dry food) containing protein, fibers, fats, carbohydrates, and vitamins, mixture of minerals, and water.

Gamma-Irradiation Facility

Irradiation conducted in Nasr City, Cairo, Egypt, at the National Centre for Radiation Research and technology (NCRRT). The source of the radiation was Gamma Cell-40 (Cesium137), which allowed for a homogeneous irradiation distribution. The dose rate during the experimental phases was 0.61 Gy / minute. Rats were exposed to 6 Gy as a fractionated dosage of whole body (2 Gy per 3 days).¹⁵

AFA-Klamath Administration

AFA-Klamath capsules (350 mg) (German Egyptian Pharmaceutical Company) were dissolved in distilled water. For one month the drug was administered orally via gastric tube at a dosage of 94.5 mg / kg body weight / day. The dose for the rats was measured on the basis of the human dose, according to the Paget formula.¹⁶

Study Groups

Animals have been divided into four groups. Group 1, (C: control): one month without any treatment. Group 2 (A: AFA extract treatment): the rats were used as positive control. 94.5mg/kg body weight AFA extract was administrated daily for one month. Group 3 (I: Irradiated): The rats were irradiated via exposing them to 6 Gy delivered as a fractionated doses of gamma radiation for one month (2 Gy each 3 days). Group 4 (I+A: Irradiated+AFA extract

treatment): the rats had a mixture of irradiation (same as group 3) plus a month's oral intake of AFA extract.

Histological and Histochemical Studies

After one month the control rats and the treated groups were sacrificed and small pieces of cerebellum were taken for the histological and histochemical studies. Specimens were prepared via fixation in 10% neutral buffered formalin solution and Carnoy's fluid. Paraffin sections of 5µm thickness were prepared and stained with Harris haematoxylin and eosin (H&E). The polysaccharides were detected by PAS (Periodic Acid-Schiff) method. Toluidine blue stain was used to detect Nissel granules.⁶

Immunohistochemical Study

Caspase-9 immunostaining was done to detect programmed cell death or apoptotic changes in the various study groups.¹⁷

GFAP immunostaining was conducted to detect glial fibrillary acidic protein, a protein found in glial cells.¹⁸

Morphometric Analysis

The image analyzer (Image J 1.46r) was used to obtain morphometric data as follows:

The carbohydrate content of the cerebellar cortex neuronal cells using PAS-stained sections at 400x magnification.

- The mean apoptotic changes of the cerebellar cortex neuronal cells using Caspase-9 immunostained sections at 400x magnification.
- The mean content of fibrillary acidic protein in glial and neural cells using GFAP immunohistochemical stained sections at 400x magnification.
- Previous measurements were calculated from each animal in each group in five non-overlapping fields / section in five serial sections / rat.

Statistical Analysis

All statistical analyses were performed via Paleontological Statistics Version 3.0 (PAST 3.0) statistical software.¹⁹ The data obtained was represented as mean standard deviation (SD) and analyzed using variance analysis (ANOVA). The level of statistical significance was described as $p < 0.05$.

RESULTS

Histological and Histochemical Results

In Group I, (C, control); The light microscopic examination of the control group's H&E stained cerebellum sections showed that there were three layers of the cerebellar cortex: the molecular layer, the Purkinje cell layer, and the granular layer (Fig. 1). Nerve fibers and dispersed cells make up the molecular layer. The middle layer of the Purkinje cell was composed of broad pyriform cells with clear vesicular nucleus clustered in a row along the granular layer's upper margin. The cerebellar cortex's innermost layer, directly contiguous to the

cerebellar medulla (white matter), was the granular layer. This layer consists of small, rounded, tightly packed cells with nuclei that are deeply stained (Fig.2). In the cerebellar medulla (white matter), littered neurons were found with their nerve fibers and endothelium-lined capillaries (Fig.2).

Periodic Acid Chief (PAS) stained cerebellar medulla and cortex showed efficient PAS response on normal neurons (Fig. 3, 4, 25 and Table 1). Toluidine showed a strong blue stain in the perikarya of normal Purkinje cells in the cerebellar cortex of Nissel granules (Fig. 5, 6). For group 1&2, immunohistochemical studies of brain sections showed a mild expression of Caspase-9 immunostaining for neuronal cell bodies and glial cells (Figs. 7, 8 Fig. 26, and Table 1) also, for group 1&2, GFAP immunostaining (glial fibrillary acidic protein– the characteristic intermediate filament protein of astroglia) for neuroglial and neuronal cells processes which rich in intermediate filament containing fibrillary acidic protein expressed brown in color (Fig. 21, 22).

Group II (A, AFA extract treatment): Displayed the same light microscopic appearance as the control group I

Group III (I, Irradiated): Examination of H&E stained cerebellar cortex sections of irradiated rats revealed distorted Purkinje cells of different shapes. Either degenerated or with karyolytic nuclei, some Purkinje cells appeared (Figs. 9, 10). With the shrinkage of their cytoplasm and nucleus pyknosis, degenerated Purkinje cells emerged.

The PAS reactions of the cerebellar medulla portion of this group suggested mild PAS reactions in degenerated neurons and moderate reactions in some normal neurons. (Fig. 11, 25, and Table 1). Toluidine blue stained sections of cerebellar cortex parts displayed a weak reaction to Nissel granules in the perikarya of some Purkinje cells and in degenerated cells (Fig. 12, 13).

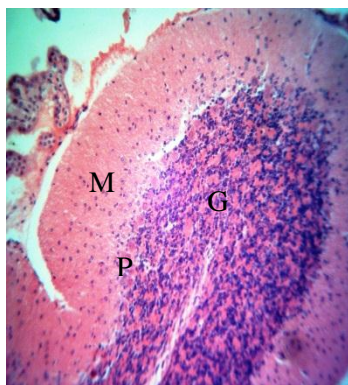

Fig.1: A photomicrograph of the molecular layer (M), Purkinje cell layer (P) and granular layer (G) of the controlled adult rat cerebellar cortex (H&E, X200)

Immunohistochemical investigations performed post irradiation of rats, showed a significantly increased Caspase-9 expression in degenerating neuronal cell bodies, degenerating neurons in comparison to the control groups (Figs. 14, 15, 16, 26 and Table 1).

Also, for cerebellum sections of rats showed a significant decrease in GFAP immunostaining expression in comparison to the control groups (Fig. 23, 27 and Table 1).

Group IV protective group (I+A, Irradiated +AFA extract treatment):

A light microscopic examination of group IV H&E stained cerebellum, the Purkinje cell layer with near normal cells, was shown (Fig.17). Most cerebellar medulla neurons have maintained their normal appearance, but some neurons still tend to be degenerated with a slightly congested capillary (Fig.17).

In almost normal neurons, the cerebellar medulla stained with (PAS) displayed a strong PAS reaction (Fig.18, 25 and Table 1). The Toluidine blue stain displayed a strong blue stain of Nissel granules in the perikarya of almost normal Purkinje cells in the cerebellar cortex, although poor reaction was observed in some degenerated Purkinje cells (Fig. 19).

Immunohistochemical sections showed marked significant decrease in Caspase-9 immunostaining expression in degenerating neuronal cell bodies, degenerating neurons and degenerating glial cells in comparison to the irradiated group (Figs. 20 , 26 and Table 1).

Also, for cerebellum sections of rats in protective group showed significant increased GFAP immunostaining expression in comparison to the irradiated group (Fig. 24, 27 and Table 1).

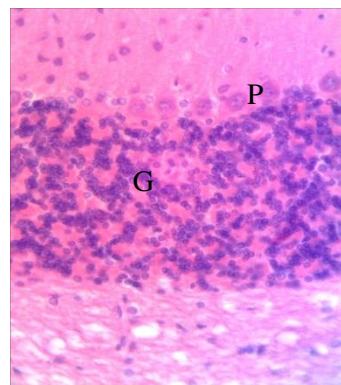


Fig.2: A photomicrograph displaying the Purkinje cell layer of a control adult rat cerebellar cortex comprises large pyriform cells with vesicular nucleus (P) and the granular layer comprises crowded small cells with intensely stained nucleus (G) (H&E, X400)

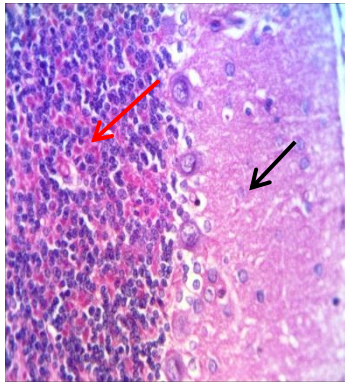


Fig.3: A photomicrograph of a control cerebellar cortex of adult albino rat displaying strong PAS +ve reaction in neuronal cell bodies ,in neurons cell membranes (red arrows) and in glial cells (black arrow).(PAS, X400)

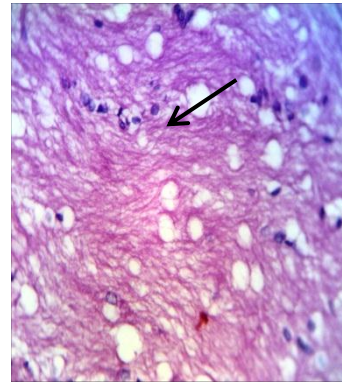


Fig.4: A photomicrograph of the adult rat control cerebellar medulla displaying a heavy PAS reaction of normal neurons (black arrow). (PAS, X400)

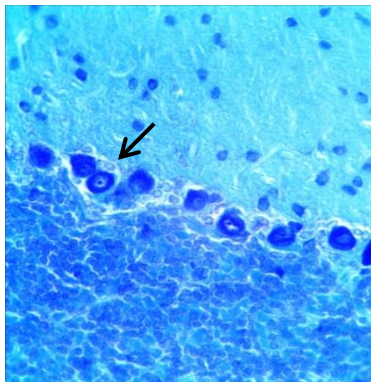


Fig. 5: A photomicrograph of the adult rat control cerebellar cortex displaying a heavy basophilic stained cytoplasm surrounding the nucleus indicating high cellular content of Nissel granules in the perikarya of Purkinje cells (black arrow). (Toluidine Blue, X400)

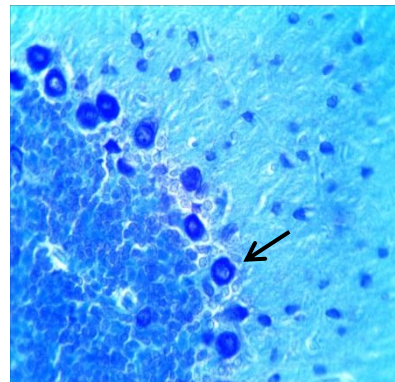


Fig. 6: A photomicrograph of the adult rat control cerebellar cortex displaying a heavy basophilic stained cytoplasm surrounding the nucleus indicating high cellular content of Nissel granules in the perikarya of Purkinje cells (black arrow). (Toluidine Blue, X400)

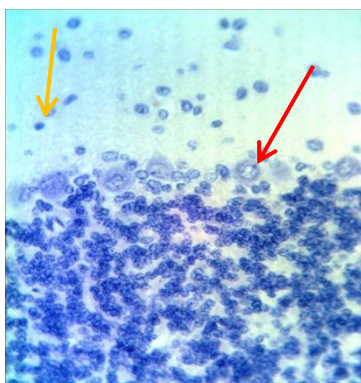


Fig.7: A photomicrograph of a control cerebellum of adult albino rat displaying mild expression of Caspase-9 immunostaining in neurons (red arrows) and in glial cells (yellow arrows) of the cerebellar cortex. (Caspase-9 immunostaining, X400).

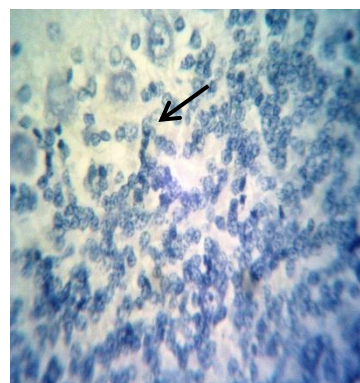


Fig. 8: A photomicrograph of a control cerebellum of adult albino rat displaying mild expression of Caspase-9 immunostaining in neuronal cell bodies of the cerebellar cortex (black arrow). (Caspase-9 immunostaining, X400)

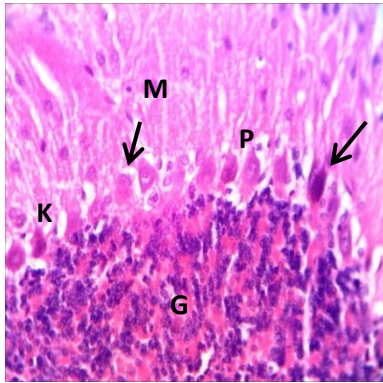


Fig.9: A photomicrograph of the molecular layer (M), the Purkinje cell layer (P), and the granular layer (G) of the irradiated adult rat cerebellar cortex. With different shapes, most of the Purkinje cells appear distorted, (black arrow) and others with Pyknotic and karyolytic nuclei (K). (H&E, X400)

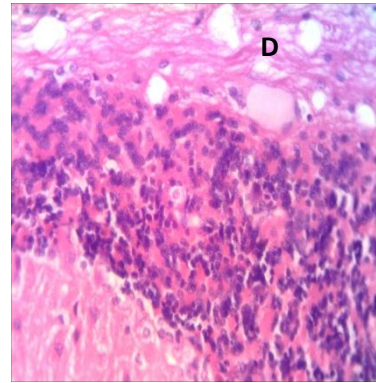


Fig.10: A photomicrograph of degenerated neurons (D) of the irradiated adult rat cerebellar medulla. (H&E, X400)

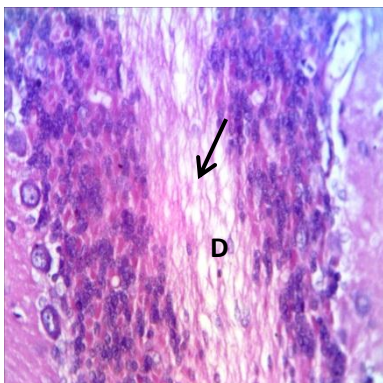


Fig.11: A photomicrograph displaying a moderate PAS reaction of some normal neurons (black arrow) and a mild PAS reaction in degenerated neurons (D) of an irradiated adult rat cerebellar medulla. (PAS, X400)

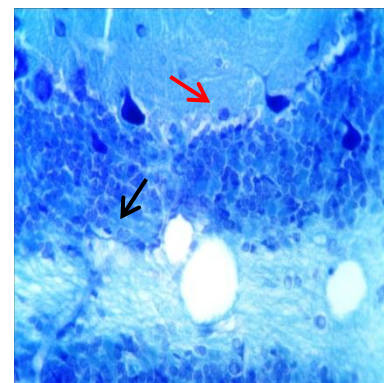


Fig.12: A photomicrograph displaying a weak reaction of Nissel granules in the perikarya of some Purkinje cells (red arrow) and degenerated cells (black arrow) of the irradiated cerebellar cortex of an adult rat (Toluidine Blue, X400)

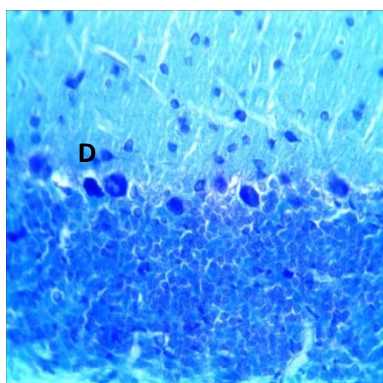


Fig. 13: A photomicrograph of Irradiated adult rat cerebellar cortex displaying weak basophilic stained cytoplasm surrounding the nucleus indicating low cellular content of Nissel granules in the perikarya of Purkinje cells (D). (Toluidine Blue, X400)

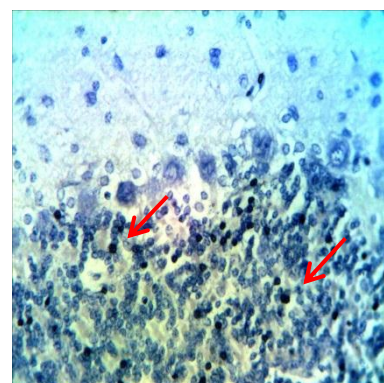


Fig. 14. A photomicrograph of the irradiated cerebellum of adult albino rat showing strong expression of Caspase-9 immunostaining in degenerating neuronal cell bodies (Red arrow) (Caspase-9 immunostaining, X400).

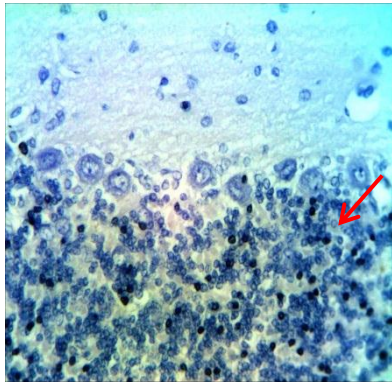


Fig. 15. A photomicrograph of the irradiated cerebellum of adult albino rat showing strong expression of Caspase-9 immunostaining in degenerating neuronal cell bodies (Red arrow). (Caspase-9 immunostaining, X400).

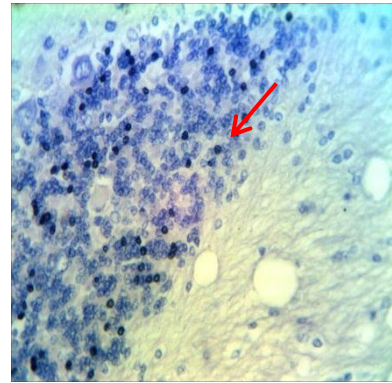


Fig. 16. A photomicrograph of the irradiated cerebellum of adult albino rat showing strong expression of Caspase-9 immunostaining in degenerating neuronal cell bodies (Red arrow). (Caspase-9 immunostaining, X400).

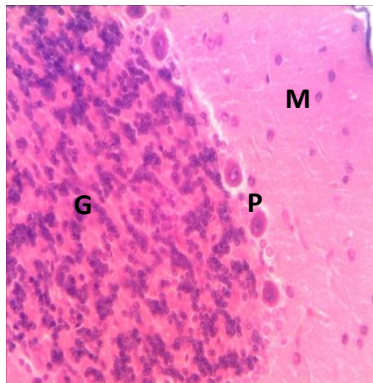


Fig. 17. A photomicrograph of Irradiated+AFA extract treatment adult rat cerebellar cortex displaying the molecular layer (M), the Purkinje cell layer (P) and the granular (G). There are almost near normal cells in the Purkinje cell layer. (H&E, X400).

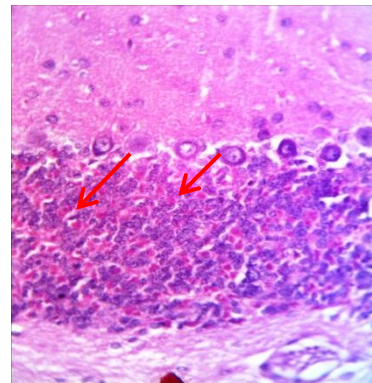


Fig.18. A photomicrograph of the treatment of adult rat cerebellar medulla with Irradiated+AFA extract shows a strong PAS reaction of almost normal neurons (Red arrow). (PAS, X400)

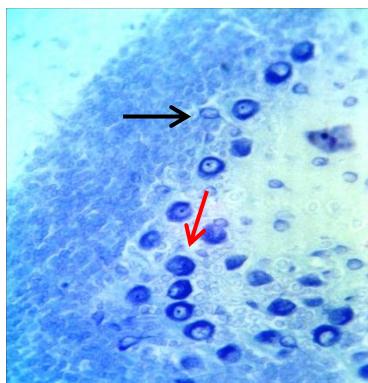


Fig. 19. A photomicrograph of Irradiated+AFA extract treatment adult rat cerebellar cortex showing strong basophilic stained cytoplasm surrounding the nucleus indicating high cellular content of Nissel granules in the perikarya of Purkinje cells (Red arrow). Nearly similar to control group. Note: weak reaction in one degenerated Purkinje cell (black arrow) (Toluidine Blue, X400)

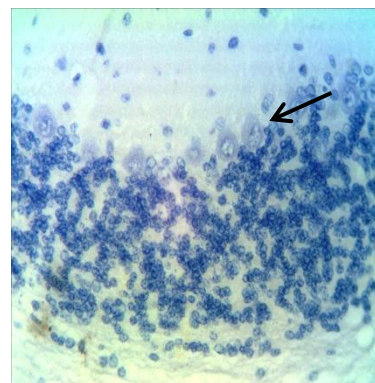


Fig. 20. A photomicrograph of the irradiated cerebellum of adult albino rat treated with AFA extract showing mild expression of Caspase-9 immunostaining in the cerebellar cortex cells (black arrow) in comparison to the irradiated group. (Caspase-9 immunostaining, x400).

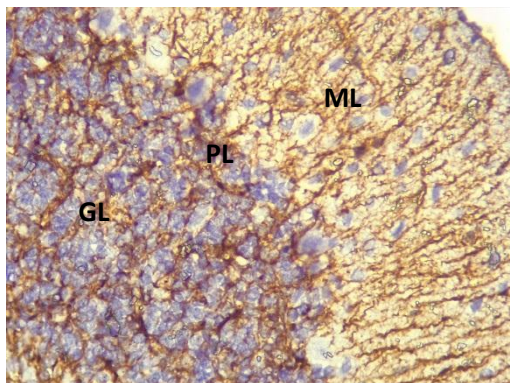


Fig. 21. A photomicrograph of a control cerebellum showing the major intermediate filament-rich astroglial processes in dark brown in the molecular layer (ML), Purkinje layer (PL) and granular layer (GL) of the cerebellar cortex of adult albino rat. (GFAP, X400)

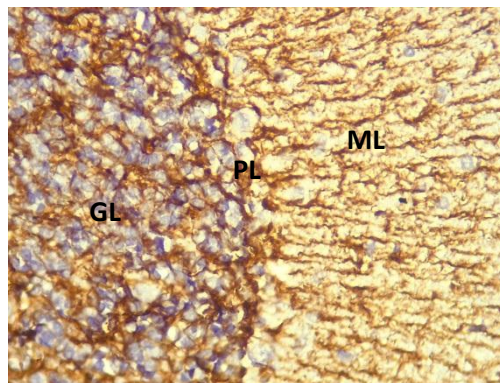


Fig. 22. A photomicrograph of a group II (AFA extract treatment) cerebellum showing the major intermediate filament-rich astroglial processes in dark brown in the molecular layer (ML), Purkinje layer (PL) and granular layer (GL) of the cerebellar cortex of adult albino rat. (GFAP, X400)

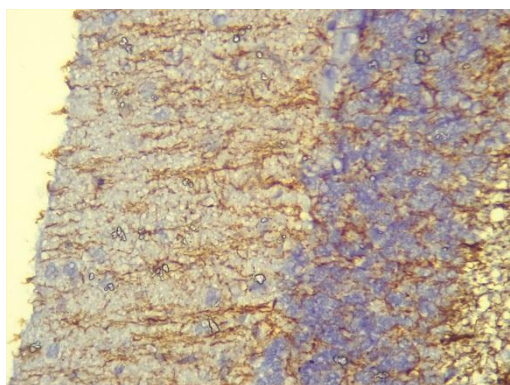


Fig. 23. A photomicrograph of the irradiated cerebellum showing weak expression of GFAP immunostaining in comparison to the control group of adult albino rat. (GFAP, X400)

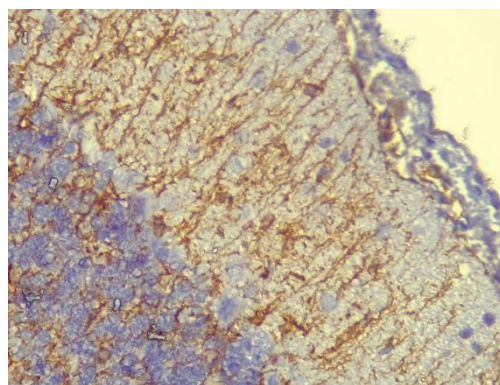
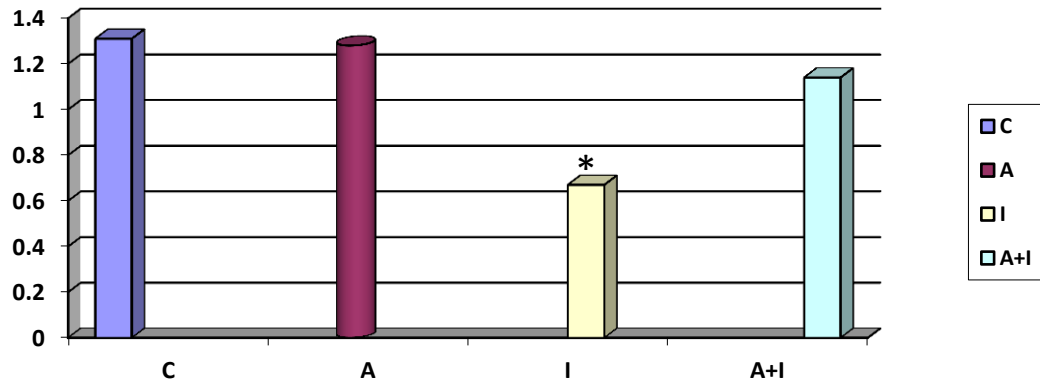


Fig. 24. A photomicrograph of Irradiated+AFA extract treatment showing strong expression of GFAP immunostaining in comparison to the irradiated group adult rat cerebellar cortex. (GFAP, X400)

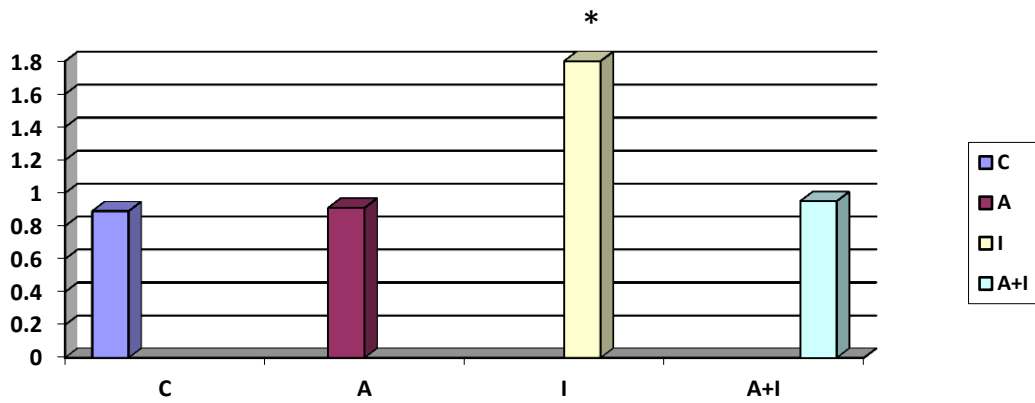
| Parameters Study Groups | Optical Density of the PAS+ve expression in the cerebellar neuronal cells. | Optical Density of the Caspase-9+ve expression in the cerebellar neuronal cells. | Optical Density of the GFAP+ve expression in the cerebellar neuronal cells. |
|-------------------------|--|--|---|
| Group 1(C) | 1.31±0.01 | 0.89±0.01 | 1.43±0.01 |
| Group 2 (A) | 1.28±0.01 | 0.92±0.01 | 1.39±0.01 |
| Group 3 (I) | 0.67±0.01 | 1.82±0.01 | 0.72±0.01 |
| Group 4 (I+A) | 1.14±0.01 | 0.99±0.01 | 1.19±0.01 |

Table 1: Optical Density of the PAS+ve, Caspase-9+ve and GFAP+ve expressions in the in the cerebellar neuronal cells for the different groups of the study expressed as mean ± SD.



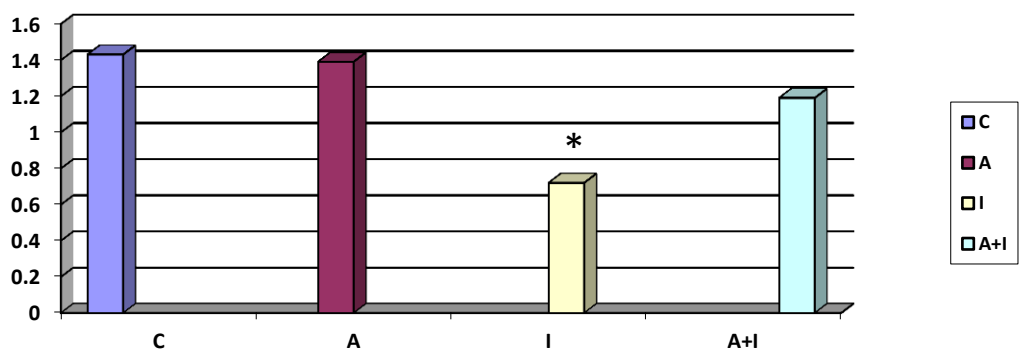
* Significant decrease in the level of parameters relative to the control group ($P < 0.05$).

Fig. 25: The Optical Density of the PAS+ve expression in the cerebellar neuronal cells for the different groups of the study relative to the control group.



*Significant increase in the level of parameters relative to the control group ($P < 0.05$).

Fig. 26: The Optical Density of the Caspase-9+ve expression in the cerebellar neuronal cells for the different groups of the study relative to the control group.



*Significant decrease in the level of parameters relative to the control group ($P < 0.05$).

Fig. 27: The Optical Density of the GFAP+ve expression in the cerebellar neuronal cells for the different groups of the study relative to the control group.

DISCUSSION

Degenerative impacts of ionizing radiation produced on human body should be taken into consideration as it is used on a large scale in diagnosis, therapy and industry.^{20,21} Experimental animal studies have shown that exposure to ionizing radiation causes oxidative stress in different tissues.^{22,23} Water is the substance most common in our bodies. The splitting of radiation and radiolysis of water molecules is the key event in inducing biological damage to the different tissue types.²⁴ Water molecules absorb energy and produce free radicals.²⁵

The interaction between ionizing radiation and the biological system has produced reactive oxygen species (ROS).^{26,27} ROS affects the cell membrane significantly, inducing peroxidation of the lipids that damage the cells.^{28,29} ROS is produced in living organisms from water and oxygen which reacts with different intracellular components including DNA, protein, lipids, carbohydrates. This reaction causes genetic damage and abnormal function of the cells.^{30,31}

Cerebellar neuronal cells are at particular risk of destruction by induced free radicals for two reasons; first, brain contain high amount of iron (free form) that is catalytically involved in production of ROS and second, brain has a relatively deficient antioxidant defence mechanisms.³² The goal of the current research was to evaluate the protective potential impact of AFA using simple techniques of histology, histochemistry and immuno-histochemistry on the cerebellar toxic model induced in irradiated tissue.

This work demonstrated that normal overall structure of the control rats' cerebellar cortex and medulla. The reported histological organization of the normal cerebellum structure was consistent with these observations.³³ This suggested that the rats being examined were healthy.

In the present study, histopathological analysis of irradiated rats' cerebellar cortex showed various effects; distorted Purkinje cells, often organized into two layers. Their nucleus pyknosis and vacuolation areas imply cell loss with their cytoplasm shrinking, some Purkinje cells have degenerated. Immuno-histochemical study of the irradiated cerebellum showed strong expression of Caspase-9 immunostaining in degenerating neuronal cell bodies, in degenerating neurons and in degenerating glial cells of the cerebral cortex in comparison to the control group. Purkinje cell degeneration might refer to cerebellar dysfunction these disturbances are because of the overt adverse impact of irradiation on the biological system or the indirect impact following irradiation of the released free radicals in the body.^{30,31}

Some laboratory studies attributed this effect to the increased ROS production associated with C.N.S complications such as cerebrovascular complications, reduced cerebral blood flow, blood-brain barrier disturbance and cerebral oedema.^{30,31} These complications eventually are the base for the long-

term complications that associated with radiation exposure such as histological and morphological abnormalities. Cerebellum susceptibility to oxidative stress induced by ROS is attributable to the fact that it uses around one-fifth of the body's overall oxygen demand and is relatively low in antioxidant enzymes.³⁴

In the current study it was found that the architecture of the irradiated group cerebellar medulla was altered in shape (degenerated neurons with congested dilated capillaries). The congested capillary can impair the cerebellar tissue's supply of nutrition and oxygen. Since neurons need relatively large amounts of oxygen because of their high metabolic rate.³⁵ Oxygen deprivation (anoxia) may contribute to the degenerative changes found in the irradiated treatment group's neurons.

Reaction of Periodic Acid Schiff (PAS) in which regions of accumulation of mucopolysaccharide emit a red color will reveal mucopolysaccharides content in the neuronal cytoplasm.³⁶

In the current study, the cerebellar medulla of irradiated rats displayed a weak PAS reaction, indicating a decrease in the quantity of mucopolysaccharides in their cytoplasm. Some authors stated this earlier.³⁷ In their research, where the content of glycogen in the whole brain was documented to decline after lithium therapy.

In the present study, the irradiated group cerebellar cortex examination indicated a pale toluidine blue staining reaction in cytoplasm indicating low cellular content of Nissel granules in the degenerated Purkinje cells compared to that of the control group. This result was associated with a reduced protein synthesis rate under ageing, stress, and toxicity of drugs in the rat cerebellum.⁹

The fact that dietary antioxidants have a significant role in the defense against the harmful impacts of oxidative stress on cells is well known.³⁰ Essential fatty acids are more commonly present in AFA, such as Omega-3 and Omega-6 fatty acids. Omega-3 usage was observed to scavenge free radicals and ROS.³² Also, Omega-3 usage showed a good therapeutic effect in some neuropsychiatric disorder in which ROS are accused to be a key physiopathogenetic factor.³⁰

Moreover, AFA can protect Cerebellum via production of low molecular weight peptides that are neurotransmitters precursors which initiate secretion of other substances (such as hormones) and influence metabolic functions.^{7,8}

Inspection of the cerebellar cortex of protected group of rats undergoing Irradiated + AFA extract therapy in the current study revealed that the majority Purkinje cell layer appear similar to normal, the layers of granular and molecular cells were nearly normal. Furthermore, in the cerebellar medulla, most of the neurons maintained their usual looks, but there were still reports of some degenerated neurons and slightly congested capillaries. As dopaminergic toxicity is inhibited by its supplementation and protects neurons against oxidative stress, this could

be attributable to the AFA extract's protective impact.⁸

AFA extract is concerned with protecting against reactive oxygen species (ROS) inducing cell damage.^{7,8} and thus attenuating the toxic impact on the cerebellum of rats. AFA extract's beneficial antioxidant effects on cells in the brain were due to its effect on glutathione elevation, Lipid peroxidation reduction and protection against the death of cells.^{7,8}

By minimizing oxidative stress and restoring the status of antioxidants, AFA extract may thus effectively prevent tissue damage.

Also, we suggest that increases of GFAP expression in Irradiated+AFA group in comparison to the adult rat irradiated group cerebellar cortex which observed is a mechanism for neuroprotection this observation was in agreement with.³⁸

CONCLUSION

The negative effect of radiation exposure should be kept in mind through chronic use. Significant effects of AFA supplement against the degenerating effects of radiation on cerebellum. Thus, these results indicate that AFA supplement can be used as an efficient tool for radio protection and cellular safety.

REFERENCES

- Alugoju P., Dinesh B. J. and Latha P.: Free Radicals: Properties, Sources, Targets, and Their Implication in Various Diseases. *Indian J Clin Biochem.* 2015; 30(1): 11–26.
- Norma FS, Raúl SC, Claudia VC et al. Antioxidant Compounds and Their Antioxidant Mechanism, Open access peer-reviewed chapter. 2019. DOI: [10.5772/intechopen.85270](https://doi.org/10.5772/intechopen.85270)
- Asima B, Ranajoy C, Sankar M et al. Oxidative Stress: An Essential Factor in the Pathogenesis of Gastrointestinal Mucosal Diseases. *Physiol Rev.* 2104; 94(2): 329–54.
- Tolman, KG., Fonseca, V., Tan, MH. et al. Narrative review: hepatobiliary disease in type 2 diabetes mellitus. *Ann Intern Med.*, 2004; 141: 946-56.
- Hall, EJ. A radiation biologist looks to the future. *Int J Radiat Oncol Biol Phys.*, 2000; 46: 1-2.
- Bancroft, D. and Gamble, M. Bancroft's Theory and Practice of Histological Techniques. 6th Ed. Elsevier, Churchill Livingst one, Edinburgh, Scotland. 2008; Pp 178-186, 221-4.
- Amber LC, Shelley S and Curtis C. A Systematic Literature Review for Evidence of Aphanizomenon flos-aquae Toxicogenicity in Recreational Waters and Toxicity of Dietary Supplements: 2000–2017. *Toxins (Basel).* 2018; 10(7): 254.
- Bruno, J.: Edible microalgae. a review of the health research. Center of Nutritional Psychol Press. 2001. Available: www.ediblemicroalgae.com 13 June 2014.
- Gouda S., Naim M., El-Aal H. et al. Effect of alpha-phenyl-n-tert-butyl nitron on aging of the cerebellum of male albino rats (Histological and Immuno-histochemical study). *Egypt. J. Histol.* 2010; 33(3): 495-507
- Keshavarz M., Emamghoreishi M., Nekooeian A. et al. Increased bcl2 protein levels in rat primary astrocyte culture following chronic lithium treatment. *Iran J. Med. Sci.* 2013; 38(3): 255-62.
- Cunnane SC., Plourde M., Pifferi F., et al. Fish, docosahexaenoic acid and Alzheimer's disease. *Prog Lipid Res.*, 2009; 48(5): 239–56.
- Sampath P., Nadya KM., Meera P. et al. Oxidative stress in cardiovascular disease. *Journal of Nuclear Cardiology.* 2001; 8(3):379-89.
- Jicha, GA.: Omega-3 fatty acids: potential role in the management of early Alzheimer's disease; *Clinical Interventions in Aging.* 2010; 5: 45–6.
- Olena Y. Glushakova, Alexander V. Glushakov, Rebekah Mannix, et al. Handbook of Neuroemergency Clinical Trials (2nd Edition). Chapter 8 - The Use of Blood-Based Biomarkers to Improve the Design of Clinical Trials of Traumatic Brain Injury. 2018; Pp: 139-66.
- Mansour S. Z.: Protective Effect of Low Dose Gamma Irradiation against Oxidative Damage in Rats Administrated with Ferric-Nitritolriacetate. *J. Rad. Res. Appl. Sci.*, 2009; Vol. 2, No. 2, pp. 255-76.
- Paget GE. and Barnes JM.: Evaluation of drug activities. *Pharmacometrics:* 1964; Vol.1. New York Academic Press. Pp 161.
- Donald W, William T, Joanna S, et al. Apoptosis and Beyond: Cytometry in Studies of Programmed Cell Death. *Methods Cell Biol.* 2012; 103: 55–98.
- Rama G, Satyavir K, Sumiti G, et al. Immunohistochemical expression of glial fibrillary acidic protein and CAM5.2 in glial tumors and their role in differentiating glial tumors from metastatic tumors of central nervous system. *J Neurosci Rural Pract.* 2015; 6(4): 499–503.
- Hammer O., Harper DAT. and Ryan PD. PAST: Paleontological Statistics Software Package for Education and Data Analysis. *Palaeontologia Electronica*, 2001; 4(1): 9-15.
- Jagetia GC.: Radioprotective potential of plants and herbs against the effects of ionizing radiation. *J. Clin. Biochem. Nutr.*, 2007; 40: 74-81.

21. Kunwar A., Bansal P., Kumar SJ., et al. *In vivo* radio protection studies of 3, 3'-diselenodipropionic acid, a selenocystine derivative. *Free Rad. Biolo. Medic.* 2010; 48: 399-410.
22. Azab KhSh. Modulation of radiation injuries in rats receiving multiple doses of Aloe Vera. *Egypt. J. Rad. Sci. and Applic.*, 2007; 20:17-28.
23. Ammar AA. Evaluation of the protective role of wheat germ oil in irradiated rats. *Isotope Rad. Res.*, 209; 41: 911- 20.
24. Win M. and Philippe L.: Radiation-Induced Bioradicals: Physical, Chemical and Biological Aspects, Physics and Chemistry Basis of Biotechnology, 2001; pp 249-76.
25. Sophie Le Ca.: Water Radiolysis: Review: Influence of Oxide Surfaces on H₂ Production under Ionizing Radiation. *Water*, 2011; 3, 235-53; doi:[10.3390/w3010235](https://doi.org/10.3390/w3010235)
26. El-Masry FS. and Saad TM.: Role of selenium and vitamin E in modification of radiation disorders in male albino rats: *Isotope Rad. Res.* 2005; 37(5): 1261-73.
27. Kasumi K, Fei Q, Junya K.: Potential relationship between the biological effects of low-dose irradiation and mitochondrial ROS production. *Journal of Radiation Research*, 2018; Volume 59, Issue suppl_2, Pp: ii91-7. <https://doi.org/10.1093/jrr/rxx091>
28. Lian-Jiu S, Jia-Hao Z, Hernando G, et al. Reactive Oxygen Species-Induced Lipid Peroxidation in Apoptosis, Autophagy, and Ferroptosis. *Oxid Med Cell Longev.* 2019; 5080843. doi: [10.1155/2019/5080843](https://doi.org/10.1155/2019/5080843)
29. El-Tahawy NA. and Rezk RG. Effectiveness of oregano oil in ameliorating oxidative damage and ultrastructure changes in brain of irradiated rats. *Egypt. J. Rad. Sci. Applic.* 2008; 21(2):265-80.
30. Leelavinothan P. and Munioppan L. Protective role of scope riadulcis plant extract on brain antioxidant status and lipid peroxidation in STZ diabeticmalewistarrats. *BMC Complementary and Alternative. Med.* 2004; 4:16.
31. Hagen V. Biochemical aspects of radiation biology. *Experientia.*, 1989; 45:7.
32. Vinay K, Ahmed AK, Anu T, et al. Role of oxidative stress in various diseases: Relevance of dietary antioxidants. *The Journal of Phytopharmacology*; 2015; 4(2): 126-32.
33. Eltony S.A., Othman M.A. and Mohamed A.A.: Histological study on the effect of low level perinatal lead exposure on the cerebellar cortex of adult male albino rat. *Egypt.J.Histol.* 2010; 33 (4): 781-97.
34. Vincent, EG. Protection against radiation-the second line of defense. 2008. http://www.vincegiuliano.name/PROTECTION%20AGAINST%20RADIATIONc.htm#_ftn1
35. Gold B.G., Voda J., Yu, X. et al. The immunosuppressant FK 506 elicits a neuronal heat shock response and protects against acrylamide neuropathy. *Exp. Neurol.* 2004; 187(1): 160-70.
36. Manar A.: Effect of lithium on the cerebellum of adult male albino rat and the possible protective role of selenium (Histological, Histochemical and immunohistochemical study). *J Am Sci*; 2013; 9(11):167-76.
37. Souza A.A., Da Silva G.S., Velez B.S., et al. Glycogen synthesis in brain and astrocytes is inhibited by chronic lithium treatment. *Neurosci Lett.* 2010; 27; 482(2):128-32.
38. Li L., Lundkvist A., Andersson D., et al. Protective role of reactive astrocytes in brain ischemia. *J. Cereb. Blood Flow Metab.* 2008; 28, 468-81.