

# ASDJ

AINSHAMS DENTAL  
JOURNAL

Print ISSN 1110-7642

Online ISSN 2735-5039

AIN SHAMS DENTAL JOURNAL

Official Publication of Ain Shams Dental School

September 2020 • Vol. XXIII

## Intraoral Scan Based versus Cast Scan Based Surgical Guides

*Randa Hussein Ezzat Dabbous<sup>1</sup>, Marwa Ezzat Sabet<sup>2</sup>, Hebatallah Tarek Mohammed<sup>3</sup>*

### Abstract

**Aim:** The aim of this study was to compare the accuracy of implant placement using both intraoral scan based and cast scan based completely limiting surgical guide.

**Materials and Methods:** 20 implants divided equally into two groups, group A implants inserted using intraoral scan based surgical guides while group B implants inserted using cast scan based surgical guides. A pre-operative CBCT was taken to determine the virtual implant location regarding coronal and apical and angular positions, after implant placement, a postoperative CBCT was taken and the DDS-Pro computer software was used to match the pre and postoperative CBCT images, to compare angular, coronal, and apical deviations of the virtual and the actual implants positions by superimposition with the post-operative CBCT.

**Results:** Cast scan based surgical guide gave better results over intraoral scan based; however the difference in accuracy was statistically insignificant between group A and group B.

**Conclusion:** Both methods can be used in manufacturing surgical guides, as difference in accuracy is statistically insignificant.

**Keywords:** accuracy, intraoral scan, cast scan, surgical guides, dental implants, partially edentulous.

1. Master student, Faculty of Dentistry, Ain Shams University.
2. Professor of Prosthodontics, Faculty of Dentistry, Ain Shams University.
3. Assistant Professor of Prosthodontics, Faculty of Dentistry, Ain Shams University

## Introduction:

Partially edentulous patients have problems with aesthetics, speech and eating abilities. Many biomechanical sequelae are usually associated with teeth and periodontal ligament loss leading to health complications<sup>(1,2)</sup>. Accordingly, the construction of highly retentive and stable partial denture for these patients is an essential requirement to improve their life style and satisfaction<sup>(3)</sup>. In comparison with conventional partial denture, dental implant supported partial overdentures showed a decreased rate of bone resorption, hence better retention, stability and support<sup>(4,5)</sup>.

The osseointegration of dental implant is predictable and it is related to the surgical technique and implant handling. The success of dental implant is mainly dependent on the proper treatment planning and perfect placement of the implant. Surgical guide templates help in diagnosis and treatment planning. In addition, they also facilitate proper positioning and angulation of the implants in the bone. Fabrication of CAD/CAM based surgical guides involves several steps. The optical impression of the surgical guide can be taken directly to the ridges or indirectly by making a conventional impression, pouring the casts and thereafter, scanning them. Proving the accuracy of the direct intraoral scan based technique in making the surgical stents will have a major impact on the patient comfort and will help in decreasing the overall time of the treatment plan, thus saving the time for both dentist and patient. Accordingly, this study was done to compare the accuracy of both intraoral scan based and indirect cast scan based completely limiting CAD/CAM-based surgical guide for locating dental implants in implant supported mandibular partial overdenture.

## Materials and Methods:

Ten mandibular partially edentulous patients were selected from the out-patient clinic of Prosthodontics Department, Faculty of Dentistry, Ain Shams University to receive twenty implants (Two implant for each patient).

Patients were selected according to the following criteria, (1) Age ranging from 35-55 years; (2) All patients had mandibular Kennedy class I; (3) Angle class I maxilla-mandibular relationship and sufficient inter-arch spaces; (4) Residual alveolar ridge covered with healthy mucosa of even thickness and free of any inflammation; (4) Good oral hygiene.

Patients having any of the following conditions were excluded from the study, (1) Uncontrolled systemic diseases that contraindicate the surgical procedures, complicate the procedure or delay the healing period time; (2) Renal diseases or diuretics consumption; (3) Bone diseases; (4) Abnormal and para-functional habits; (6) Muscular or TMJ disorders; (7) Heavy smoking; (8) Chemotherapy or Radiotherapy; (9) Flabby ridge. **Patients' Grouping:** Selected patients were randomly divided into two groups: **Group (A):** Included ten implants inserted to support mandibular partial overdentures using completely limiting intraoral scan based surgical guide during implant insertion. **Group (B):** Included ten implants inserted to support mandibular partial overdentures using completely limiting cast based surgical guide during implant insertion. All patients were informed in details about the nature of the investigation and the purpose of the study; they agreed to take part in the study and signed on an informed consent form. Preliminary impressions were made for upper and lower arches using irreversible hydrocolloid impression material\* in

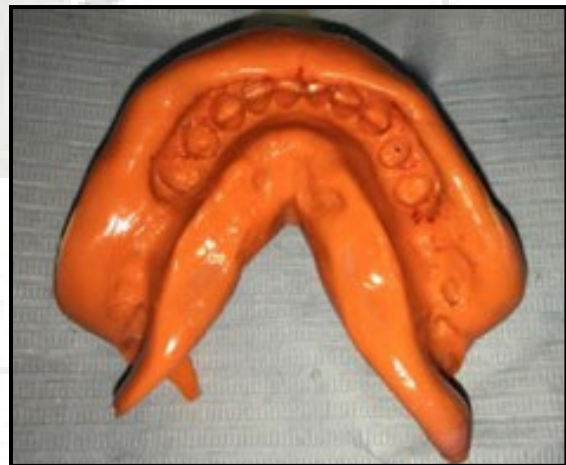---

Cavex impression alginate – Holland BV. \*

properly selected and adjusted stock trays. The impressions were poured in dental stone\*\* to produce study casts. Which were mounted on a semi adjustable articulator\*\*\* for occlusal analysis. **For group (A) patients:** Open system intraoral scanner (TRIOS 3shape)\*\*\*\* was used to scan the teeth and soft tissues of the lower dental arch.(fig.1) Scanning started from the most left distal point of the lower arch and continued to the anterior teeth and ended at the most right distal point in the arch. It was noted that scanning the soft tissues in the free end saddle area was not that easy as the scanner kept losing the track because there was no reference to help for continuous scanning. STL file was created and sent to the lab to start the implant planning. **For group (B) patients:** Preliminary impression was made for lower arch using irreversible hydrocolloid impression material in properly selected and adjusted stock trays. The impression was poured in dental stone to produce study cast. (fig.2) Cast was sent to the lab for scanning using Planmeca ProMax\*\*\*\*\* imaging unit. **For both groups:** After finishing the previous steps for each group both were gone through the following steps: **Virtual Implant planning procedures:** Planmeca ProMax 3D Mid imaging unit was used to take the CBCT image for the patient.



**Figure (1):** Intraoral scanner 3shape TRIOS basic scanner for obtaining three-dimensional data.



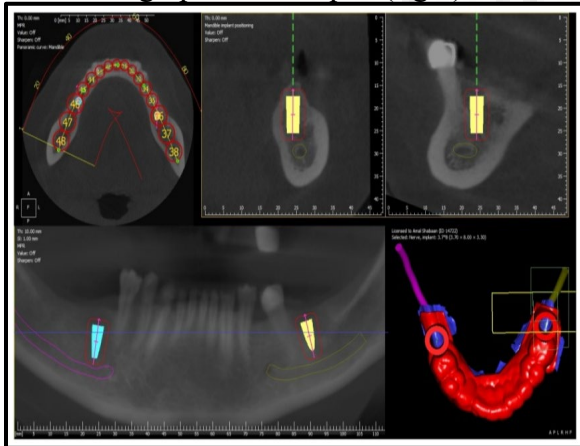
**Figure (2):** Preliminary impression for lower arch.

The CBCT image and the scanned image were superimposed together and the ideal position of the implant was chosen using the DDS-Pro software\* in DICOM (Digital Imaging and Communications in Medicine) format.(fig.3) The proposed implant sites were the mandibular first molar area bilaterally. The proposed implant sites were evaluated for sufficient bone height and sufficient buccolingual width. Two virtual implants of the required length & diameter were placed into their proposed sites and parallelism between them was considered.

Durguix, hard natural stone, Spain. \*\*  
Semiadjustable articulator, Bioart, Brazil. \*\*\*  
3Shape, Denmark. \*\*\*\*

Planmeca ProMax® 3D Mid, Planmeca OY, \*\*\*\*\*  
Finland.  
Poland \* DDS-Pro version 2.0\_2018©.

Once the positions of implants were accepted, the virtual surgical guide with two holes was designed on the DDS-Pro software. These two holes were made to receive prefabricated metallic sleeves to guide implant installation. Once the computer planning is accomplished; this plan is saved as a “STL” file format and sent to the processing or printing center for fabrication of the surgical guide, using stereolithographic technique. (fig.4)



**Figure (3):** Planning the implant position by DDS-Pro software and designing the surgical guide.



**Figure (4):** The fabricated surgical guide by stereolithographic technique.

### Pre-surgical patient management

Prophylactic antibiotic (Augmentin\* 1 gm capsules) was prescribed two times per day and anti-inflammatory and analgesic (Brufen\*\* 600 mg tablet) was prescribed three times per day 24 hours before surgical operation and was continued five days after surgery. The patient was asked to rinse with 0.2% chlorohexidine mouth wash immediately before the operation and two times daily one week after operation.

### Implant insertion:

Mandibular nerve block as well as ring infiltration anaesthesia was given at the surgical region. After checking the local anaesthesia, the surgical stent was disinfected and inserted into the patient's mouth; and checked for stability. The guide was supported by the remaining anterior teeth. (fig.5)

The osteotomy was performed using sequential drills of the universal kit till reaching the final drill of 3.4 mm diameter and 8 mm length.

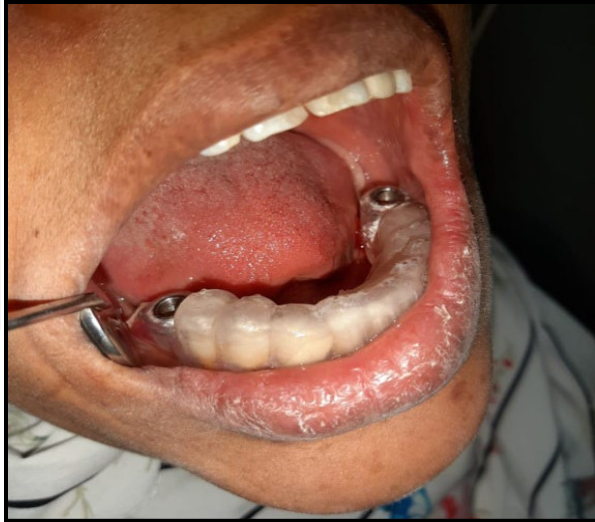A tapered self-tapping threaded implants\*\*\* were used with diameter 3.7 mm and length 8 mm. The implant was threaded in a clock-wise direction using finger pressure then by a ratchet until the implant top flushed with the bone surface (fig.6).

**Post-operative care :** Patient was instructed to use antiseptic mouthwash 2-3 times daily for three successive days. Cold soft diet was recommended. Antibiotic, analgesic and anti-inflammatory that were prescribed to the patient before the surgery, continued for the following five days. The patient was instructed to come back the next day to check.

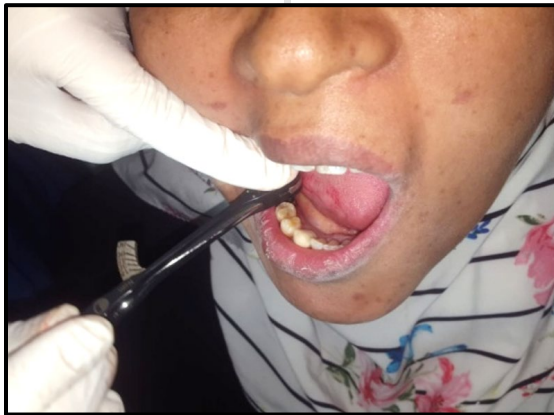\* Augmentin, medical union pharmaceutical Co, Egypt under the license of Beecham pharmaceutical, England.

\*\* Abbott International Egypt under the license of Abbott Laboratories Inc. USA.

\*\*\* Cylindrical implant internal hex - Leader - Italy.



**Figure (5):** Fixation of the surgical guide in the patient's mouth.

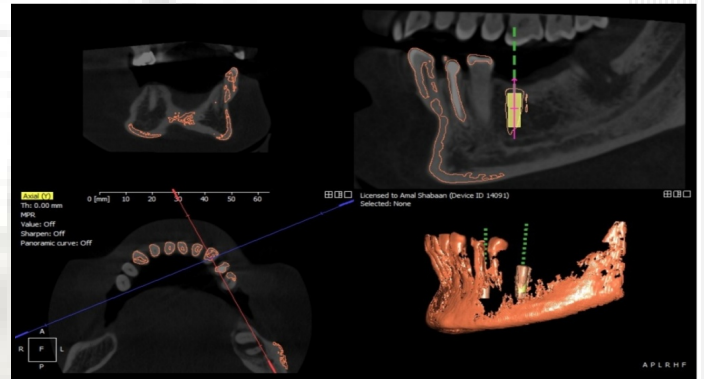


**Figure (6):** Threading the implant in place by the ratchet.

### Post-operative Imaging & Image Super-Imposition:

Patients were recalled three days after implant insertion for another CBCT scan. This postoperative CBCT was performed using the same pre-operative CBCT parameters and the same machine. The DDS-Pro software was used to match the pre and postoperative CBCT images by means of the reference markers which are the teeth (fig.7) to compare angular deviation, coronal deviation, and apical deviation of the virtual and the actual implants positions. Coronal/apical deviation is defined as the difference in position of the coronal/apical

part of the planned and placed implant in mesiodistal(x), buccolingual(y) and coronal(z) directions. It is calculated by the mean sum of difference in the three directions. The angular deviation is calculated as the angle between the longitudinal axis of the planned and placed implant. Two vertical planes across the long axis of the virtual and final implants were drawn and the angle between them was calculated.



**Figure (7):** Superimposition of pre- & post-operative CBCT scans with means of reference points.

### Prosthetic phase:

Three months after implant installation, patients were recalled for second stage surgery. The implants were exposed with a small crestal incision and the all attachments were inserted onto the implant fixture. Then the partial denture was fabricated following the usual steps.

### Results:

Statistical analysis was performed using IBM SPSS Statistics Version 2.1 for Windows. Data was presented as mean, and standard deviation (SD). The significance level was set at ( $P \leq 0.05$ ). Kolmogorov-Smirnov and Shapiro-Wilk tests were used to assess data normality.

Since all data showed normal distribution, Independent Student t-test (2 independent samples) was performed to compare angular, coronal and apical deviation between intraoral and cast scan based surgical guides.

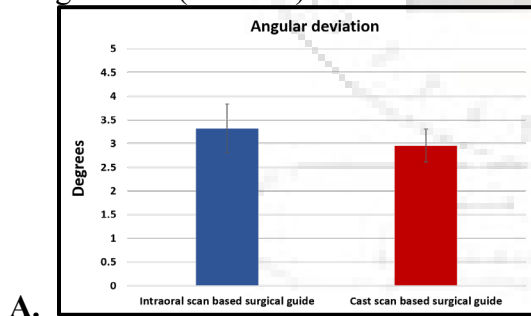
**I. Comparison of angular deviation between intraoral and cast scan based surgical guides:**

**Table (I):** Mean, Standard deviation and P-value for the effect of surgical guide technique on angular deviation (degrees).

Group	Mean	SD	P-value
Intraoral scan based surgical guide	3.319	0.514	0.080NS
Cast scan based surgical guide	2.955	0.345	

NS: non-significant at  $P > 0.05$

Table (I) shows higher angular deviation for intraoral scan based surgical guide than cast scan based surgical guide however, by using independent student t-test this difference was statistically insignificant ( $P=0.080$ ).



A.

**Figure (8):** Bar chart for angular deviation in intraoral scan based and cast scan based surgical guides.

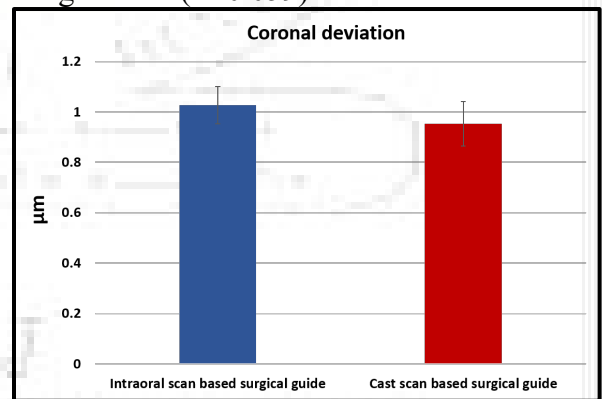
**II. Comparison of coronal deviation between intraoral and cast scan based surgical guides:**

**Table (II):** Mean, Standard deviation and P-value for the effect of surgical guide technique on coronal deviation ( $\mu\text{m}$ ).

Group	Mean	SD	P-value
Intraoral scan based surgical guide	1.026	0.073	0.059NS
Cast scan based surgical guide	0.952	0.088	

NS: non-significant at  $P > 0.05$

Table (II) shows higher coronal deviation for intraoral scan based surgical guide than cast scan based surgical guide however, by using independent student t-test this difference was statistically insignificant ( $P=0.059$ ).



**Figure (20):** Bar chart for coronal deviation in intraoral scan based and cast scan based surgical guides.

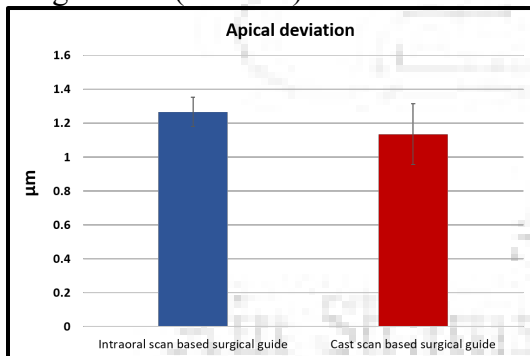
### III. Comparison of apical deviation between intraoral and cast scan based surgical guides:

**Table (III):** Mean, Standard deviation and P-value for the effect of surgical guide technique on apical deviation ( $\mu\text{m}$ ).

Group	Mean	SD	P-value
Intraoral scan based surgical guide	1.266	0.085	0.051NS
Cast scan based surgical guide	1.134	0.179	

NS: non-significant at  $P > 0.05$

Table (III) shows higher apical deviation for intraoral scan based surgical guide than cast scan based surgical guide however, by using independent student t-test this difference was statistically insignificant ( $P=0.051$ ).



**Figure (21):** Bar chart for apical deviation in intraoral scan based and cast scan based surgical guides

### Discussion:

Even though guided surgery is assumed to have high accuracy and precision compared to freehand techniques (6,7,8,9), deviation of implant position from the planned position still occurs. Possible explanations for the deviation that occurs may include the fit and the stability of the surgical guide, types of surgical guide, experience of the surgeon and the protocols for measuring the implant positions (10,11,12).

Tooth supported surgical guide was selected for the study as the accuracy of implant placement with the use of tooth-supported surgical guides is reportedly superior to that with the use of bone- and mucosa-supported guides.

To accurately compare pre- and post-operative CT images, the superimposition of the images was done using identical reference points. Using identical machines and superimposing with at least three fixed reference points were minimally required for an accurate CT comparison.

DDS-Pro was the software of choice as it provided the facility of construction of 3D images, accurate and easier superimposition than other softwares and easy angular measurements. Surgical guide was completely designed by DDS-Pro and exported directly as STL file for prototyping.

In this study, the mean angular deviations of the placed implants in-group A and B were  $3.3^\circ \pm 0.51^\circ$  and  $2.9^\circ \pm 0.34^\circ$  respectively. The mean coronal and apical deviations in distance between the planned and placed implants were  $1.02 \pm 0.07$  mm and  $1.26 \pm 0.08$  mm for Group A;  $0.95 \pm 0.08$  mm and  $1.13 \pm 0.17$  mm for Group B respectively. Mean apical, coronal and angular deviations in Group B were smaller than that of Group A although it did not reach a significant level ( $p > 0.05$ ).

The deviation of implants in the intraoral scan group may be due to problems

during scanning like reflection of light, presence of saliva, patient movement, inadequate visualization of subgingival margins and the inaccurate scanning of the soft tissue<sup>(13,14)</sup>. These affect the accuracy of the fitting of the guide and thus affect the implant placement.

It is worth noting that the length, angle, and proper position of an implant play critical roles in the placement procedure. The results of the present study found that the apical deviation between the planned and actual implant position was 1.2 mm and 1.1 mm for group A and B respectively, appreciably less than the well-known standard “safety zone” of 2 mm away from vital structures<sup>(15,16)</sup>.

In this study – for both groups - the mean coronal, apical and angular deviations were 0.98 mm, 1.1 mm and 3.1° respectively.

A systematic review was conducted to assess the accuracy of static surgical guides, it showed that the mean error was 0.99 mm at the coronal center, 1.24 mm at the apical center, and the axis deviation was 3.81°<sup>(17)</sup>. Another in vitro study was comparing the accuracy of various surgical guides. In that study, the mean error was 1 mm at the coronal center and 1.15 mm at the apical center and the axis deviation was 2.26°<sup>(18)</sup>. Thus, the results of the deviation measurements in this study are consistent with the findings of previous studies.

#### **Declaration of Competing Interest**

The authors declared that there is no conflict of interest.



## References

1. **Cunha TR, Della Vecchia MP, Regis RR, Ribeiro AB, Muglia VA, Mestriner WJr, et al.** A randomized trial on simplified and conventional methods for complete denture fabrication: Masticatory performance and ability. *J Dent* 2013; 41:133-42.
2. **Della Vecchia MP, Regis RR, Cunha TR, Andrade IM, Matta JCS, Souza RF.** A Randomized Trial on Simplified and Conventional Methods for Complete Denture Fabrication: Cost Analysis. *J Prosthodontics* 2013; 26:1-10.
3. **Cooch BF, Dolan TA, Bourque LB.** Correlates of self-reported health status upon enrollment in Rand Health Insurance experiment. *J Dent Educ* 1989; 53:629–637
4. **Rodrigues RCS, Faria ACL, Macedo AP, de Mattos MDGC, Ribeiro RF.** Retention and stress distribution in distal extension removable partial dentures with and without implant association. *J Prosthodont Res* 2013; 57:24-29.
5. **Ohkubo C, Kobayashi M, Suzuki Y, Hosoi T.** Effect of implant support on distal-extension removable partial dentures: in vivo assessment. *Int J Oral Maxillofac Implants* 2008; 23:1095-1101.
6. **Pozzi A, Polizzi G, Moy PK.** Guided surgery with tooth-supported templates for single missing teeth: A critical review. *Eur J Oral Implantol.* 2016;9 Suppl 1:S135-53.
7. **Tan PLB, Layton DM, Wise SL.** In vitro comparison of guided versus freehand implant placement: use of a new combined TRIOS surface scanning, Implant Studio, CBCT, and stereolithographic virtually planned and guided technique. *Int J Comput Dent.* 2018;21(2):87-95.
8. **Al Yafi F, Camenisch B, Al-Sabbagh M.** Is Digital Guided Implant Surgery Accurate and Reliable? *Dent Clin North Am.* 2019;63(3):381-97.
9. **Choi W, Nguyen BC, Doan A, Girod S, Gaudilliere B, Gaudilliere D.** Freehand Versus Guided Surgery: Factors Influencing Accuracy of Dental Implant Placement. *Implant Dent.* 2017;26(4):500-9.
10. **Zhou W, Liu Z, Song L, Kuo CL, Shafer DM.** Clinical Factors Affecting the Accuracy of Guided Implant Surgery-A Systematic Review and Meta-analysis. *J Evid Based Dent Pract.* 2018;18(1):28-40.
11. **Cushen SE, Turkyilmaz I.** Impact of operator experience on the accuracy of implant placement with stereolithographic surgical templates:

---

an in vitro study. *J Prosthet Dent.* 2013;109(4):248-54. 74

- 12. Marei HF, Abdel-Hady A, Al-Khalifa K, Al-Mahalawy H.** Influence of surgeon experience on the accuracy of implant placement via a partially computer-guided surgical protocol. *Int J Oral Maxillofac Implants.* 2019.
- 13. Lee JJ, Jeong ID, Park JY, Jeon JH, Kim JH, Kim WC.** Accuracy of single-abutment digital cast obtained using intraoral and cast scanners. *J Prosthet Dent.* 2017;117(2):253-9.
- 14. Christensen GJ.** Will digital impressions eliminate the current problems with conventional impressions? *J Am Dent Assoc.* 2008;139(6):761-3.

- 15. Valente F, Schioli G, Sbrenna A.** Accuracy of computer-aided oral implant surgery: a clinical and radiographic study. *Int. J. Oral Maxillofac. Implants* 2009;24:234–42.
- 16. Worthington P.** Injury to the inferior alveolar nerve during implant placement: a formula for protection of the patient and clinician. *Int. J. Oral Maxillofac. Implants* 2004;19:731–4.
- 17. Van Assche N, Vercruyssen M, Coucke W, Teughels W, Jacobs R, Quirynen M.** Accuracy of computer-aided implant placement. *Clin. Oral Implants Res.* 2012;23:112–23.
- 18. Giacomo GAPD, Cury PR, Araujo NS de, Sendyk WR, Sendyk CL.** Clinical Application of Stereolithographic Surgical Guides for Implant Placement: Preliminary Results. *J. Periodontol.* 2005;76:503–7.

ASDJ  
Arabian Society of Dental Journal