

## Assessment of Misplaced Intrauterine Contraceptive Devices by Different Imaging Modalities: A Cross-sectional Study

Hesham E. Elsheikh<sup>a</sup>, Manal A. ElRefaei<sup>b</sup>, Sara F. Abd Elfattah<sup>a</sup>

### Abstract:

<sup>a</sup> Department of Radiology, Benha faculty of medicine, Benha University, Egypt.

<sup>b</sup> Department of Radiology, Al Ahrar teaching hospital, Cairo, Egypt.

**Correspondence to:** Sara F. Abd Elfattah, Department of Radiology, Benha faculty of medicine, Benha University, Egypt.

### Email:

dr\_saraelsemary@yahoo.com

**Received:** 12 December 2020

**Accepted:** 23 December 2020

**Background:** Radiology plays a vital role in the diagnosis of intrauterine contraceptive device (IUCD) migration. Ultrasound (US) is used for initial evaluation. It is inexpensive and widely available. The X-ray is required for the diagnosis of (IUCD) expulsion as all (IUCDs) are radiopaque and rarely computed tomography (CT) is used. **Aim of the study:** Evaluation of the role of different radiological modalities in the assessment of mal-positioned (IUCDs). **Subjects and methods:** A Cross-sectional study in the radiology department at Al Ahrar teaching hospital. Fifty patients were included with suspected misplaced (IUCD) over one year. **Results:** (US) was able to detect (IUCD) position in 88%, while in 12% (IUCD) could not be localized. X-ray was performed for 42 % and could confirm (US) result and exclude (IUCD) expulsion. (CT) was performed for 18% and could detect (IUCD) location when not seen in (US) and detect the associated complications. There was a significant agreement between the three diagnostic techniques and intraoperative findings. **Conclusion:** (US) is the first modality used in the diagnostic workup of the misplaced (IUCD), but it is not reliable if the omentum and bowel loops surround the device. The X-ray can help confirm (US) result and exclude expulsion. Rarely (CT) is used for (IUCD) localization. However, (CT) is the best for the evaluation of complications associated with intra-abdominal (IUCDs) and has a role in determining the proper method of removal.

**Key words:** Misplaced intrauterine contraceptive devices, Ultrasound, X-Ray, Computed tomography.



---

## Introduction

(IUCDs) are a frequently used method for contraception worldwide. They are highly effective, inexpensive, can be used for an extended period and rapidly reversible form of contraception. Two types of (IUCDs) are available: a copper-containing (IUCD) and a hormone-releasing (IUCD) [1].

The upper fundal part of the uterine cavity is the optimal position of the (IUCD). Malposition occurs if the (IUCD) is not positioned in the fundus uteri [2]. Migration of the (IUCD) from its normal position in the uterine fundus is a frequently encountered complication, varying from uterine expulsion to displacement into the endometrial canal to uterine perforation [3].

Radiology plays a vital role in the diagnosis of (IUCD) migration [1]. (US) is appropriate for initial evaluation; it is widely available and inexpensive and does not involve radiation. It easily helps determine whether an (IUCD) is correctly positioned and can often help identify (IUCD)-related complications such as contraceptive failure (pregnancy) and detection of fragmentation and calcification. (IUCD) displacement and myometrial perforation can be fully evaluated by performing (US) alone [4]. The X-ray can help demonstrate an extra-uterine

(IUCD). It is required for the diagnosis of (IUCD) expulsion as all (IUCDs) are radiopaque [5]. Rarely (CT) is used for the assessment of (IUCD) position. It is the best for the evaluation of complications associated with intra-abdominal (IUCDs), such as visceral perforation, abscess formation, and bowel obstruction [6].

This work aimed to evaluate the role of different radiological modalities in the assessment of improperly positioned (IUCD).

---

## Subjects and methods

This cross sectional study included 50 patients with suspected misplaced (IUCD). They were referred from the gynecology department to the radiology department at Al Ahrar teaching hospital during the period from June 2019 to March 2020. All clinical information was collected from the patient's files. After approval from the ethical committee, informed consent was obtained from all patients in the research. Inclusion criteria: patients clinically and radiologically suspected to have misplaced IUCD and this suspicion had been proved by different radiological modalities and patients approved to participate in the study. Exclusion criteria: patients that finally

proved to have IUCD in place and patients refused to participate in the study.

All patients were subjected to grey-scale (US) examination of the abdomen and pelvis, first trans-abdominally then trans-vaginally using 3.5 (MHz) and 5–7.5 (MHz) transducers respectively. Cases with suspected penetration or negative (US) findings were subjected to X-ray, using traditional radiography machine with low doses of radiation. Cases with suspected complications were examined by (CT) (16 slice) according to the clinical supervision and sonographic findings. The (CT) examination was done while the patient lying in the supine position, cuts taken every 0.5-1 cm.

IBM SPSS statistics (V. 23.0, IBM Corp., USA, 2015) was used for data analysis. Data were expressed as both percentage and number for categorized results. Diagnostic validity test was used, including an agreement between the studied radiological techniques and the intraoperative results. The probability of error equal to 0.05 was considered significant; while value at 0.01 and 0.001 are highly significant.

---

## Results:

This study included 50 instances of misplaced (IUCD). We found that, as

confirmed by operative results, 45 cases (90%) had an unusual location within the pelvis (27cases (54%) intrauterine, 18 cases (36%) extra-uterine). Moreover, only 5 cases (10%) had it in the intra-abdominal cavity.

The mean age of the included cases was 33.82 years (range 21-48years) (table 1). The parity of the studied group ranged from one to six (Fig. 1). The most frequent (IUCD) type was copper T 66%. The most frequent complaint among the studied group was abdominal and pelvic pain 34%, followed by the inability to feel the threads 22 % (Fig. 2). The most common methods of removal founded among the studied cases were hysteroscopy 40%, followed by laparoscopy 36% (Fig. 3).

According to (US), in 12% of the studied cases the (IUCD) was invisible, in 32% was embedded in the myometrium, in 14% in Douglas pouch. There was highly statistical significant strong agreement between (US) and intraoperative findings among the studied cases with sensitivity 88% (table 2). 58% of the studied cases had not done X-ray. Among cases had X-ray most frequent places for (IUCD) was midline pelvis, (Lt) pelvis and (Rt) pelvis (16%, 10% & 6% respectively). 82 % of the studied cases had not done (CT). Among cases had (CT) 8%

had (IUCD) intra-abdominal within omentum without perforation. There was highly statistical significant perfect

agreement between (CT), X-ray and intraoperative findings among the studied cases (Table 3) (Table 4).

Table (1): Age of the studied cases.

Variable	(n=50)
<b>Age : (year)</b>	
Mean ± SD	33.82 ± 7.45
Range	21 - 48

SD: Standard deviation

Table (2): Agreement between (US) & Intraoperative findings among the studied cases.

Variable	US		Intraoperative		Kappa	P
	(n=50)		(n=50)			
	No	%	No	%		
<b>Intraoperative:</b>						
<i>Low IUD</i>	5	10	5	10		
<i>Displaced by fibroid</i>	4	8	4	8		
<i>Displaced by pregnancy</i>	2	4	2	4	0.92	<0.001
<i>Embedded to myometrium</i>	16	32	16	32		**
<i>Perforating myometrium</i>	2	4	2	4		
<i>Adnexa</i>	3	6	3	6		
<i>Douglas Pouch</i>	7	14	7	14		
<i>Perforating UB</i>	1	2	1	2		
<i>Pelvic cavity</i>	4	8	5	10		
<i>Not in the pelvic cavity (intraabdominal)</i>	0	0	5	10		
<i>Not Visualized</i>	6	12	0	0		
<b>Sensitivity=88% PPV=100%</b>						

Kappa: Cohen's kappa test of agreement

\*\* : Highly significant P<0.001)

**Table (3):** Agreement between X-ray & Intraoperative findings among the studied cases.

Variable	X-ray (n=21)							Kappa	P
	Midline	Rt	Lt p	Rt	Rt	Lt	Lt		
		p		UA	LA	UA	LA		
<b>Intraoperative:</b>									
<i>Embedded to myometrium</i>	5								
<i>Perforating myometrium</i>	2								
<i>Adnexa</i>			2					1	<0.001
<i>Douglas Pouch</i>		2							**
<i>Perforating UB</i>	1								
<i>Pelvic cavity</i>		1	3						
<i>Intar-abdominal</i>				1	2	1	1		

Kappa: Cohen's kappa test of agreement      \*\*: Highly significant P<0.001)

**Table (4):** Agreement between (CT) & Intraoperative findings among the studied cases.

Variable	CT (n=9)		Intraoperative (n=9)		Kappa	P
	No	%	No	%		
<b>Intraoperative:</b>						
<i>Perforating myometrium</i>	2	22.2	2	22.2		
<i>Perforating UB</i>	1	11.1	1	11.1		
<i>Intraabdominal, Perforating Bowel</i>	1	11.1	1	11.1	1	<0.001
<i>Intraabdominal, within omentum without perforation</i>	5	55.6	5	55.6		**

Kappa: Cohen's kappa test of agreement      \*\*: Highly significant P<0.001)

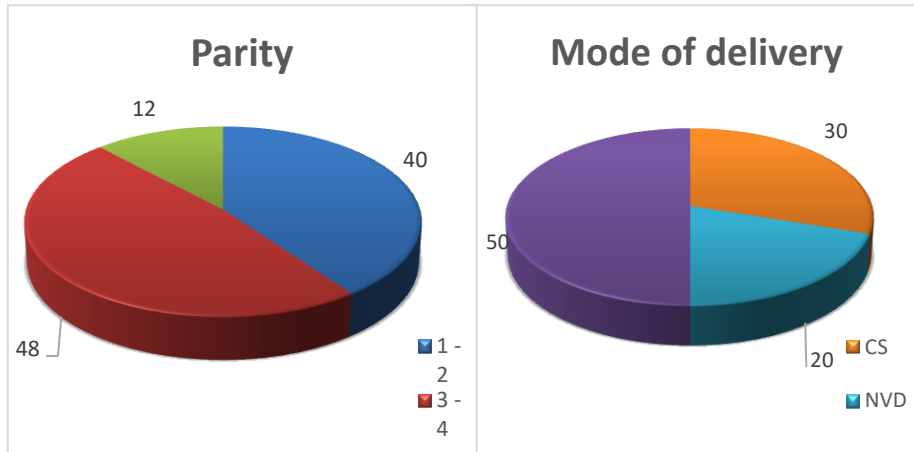


Figure (1): Parity & mode of delivery among the studied cases.

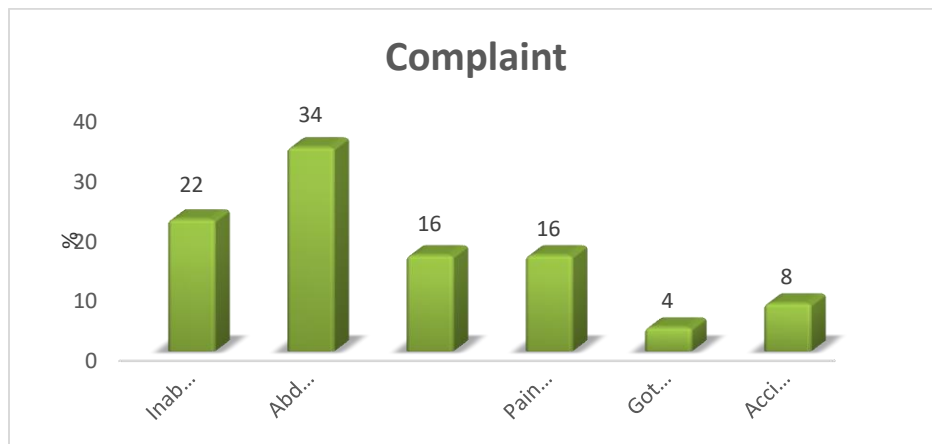


Figure (2): Complaint among the studied cases.

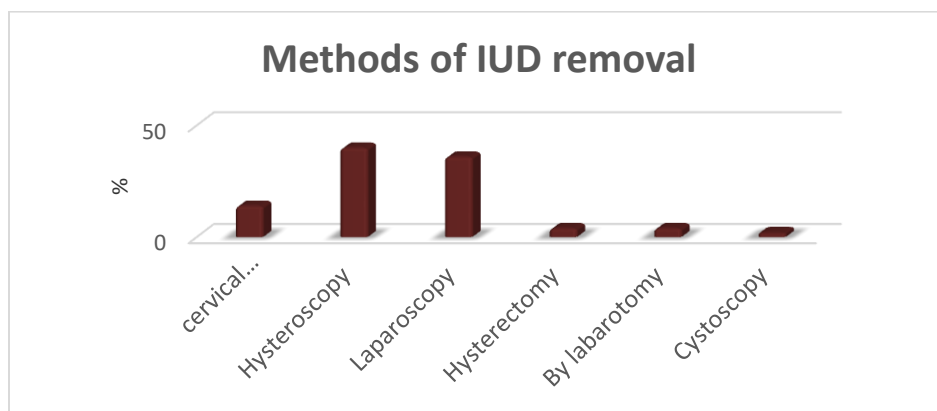


Figure (3): Methods of IUD removal among the studied cases.





---

## Discussion

(IUCDs) are commonly used for contraception worldwide. They are highly effective, inexpensive, can be used for an extended period and rapidly reversible form of contraception [1]. A copper or hormone-releasing (IUCD) optimal position is in the upper fundal portion of the uterine cavity. Malposition occurs if the (IUCD) is not positioned in the fundus uteri [2]. Migration of the (IUCD) from its normal position in the uterine fundus is a frequently encountered complication, ranging from uterine expulsion to displacement into the endometrial canal to uterine perforation [3]. Ultrasound (US) is appropriate for initial evaluation; it is widely available and inexpensive and does not involve radiation [4]. (IUCD) displacement and myometrial perforation can be fully evaluated by performing (US) alone. However, (US) is not reliable if the device is surrounded by the omentum and bowel loop [7, 8].

The X-ray can help demonstrate an extra-uterine (IUCD) and is required for the diagnosis of (IUD) expulsion [5]. Rarely (CT) is used for the assessment of (IUCD) position. However, it is best for the evaluation of complications associated with intra-abdominal (IUCDs) [6].

This study included fifty patients with misplaced (IUCD); their age ranged from (21 to 48) years with a mean age of 33.82 years. In a study done in 2018 [9], the majority of the studied cases were aged 30–39 years while in a study done in 2015 on 21 patients the mean age was of 29.4 years [10].

The most frequent (IUCD) type in the studied cases was copper T 66% followed by hormonal 24 % and only 10 % had a multi-load type. Our findings are similar to other reported studies [10, 11]. In this study, the time from insertion till diagnosis of missing ranged from 1 to 168 months with mean 31.18 months. According to another study done in 2016, the maximum number of patients had time interval of 18-24 months between insertion and diagnosis of missing [12].

The parity of the studied group ranged from one to six, with 48 % had parity three to four times that are similar to another reported results [12, 10]. Regarding delivery mode, the mean cesarean section (CS) times was 1.93, and the mean normal vaginal delivery (NVD) times were 1.97. According to a study done in 2015, the mean number of births by (NVD) was 2.5, while the mean number of (CS) births was 0.4 [10]. The

most frequent complaint among the studied group was abdominal and pelvic pain 34%, followed by the inability to feel the threads 22%. These results are in agreement with some reported studies [11, 13] while is controverted with another one [14].

(US) was performed for all patients as an initial evaluation to detect (IUCD) location. X-ray was performed for 42 % of patients either to confirm (US) result or to exclude expulsion if (IUCD) could not be seen. (CT) was performed for 18% of patients to detect (IUCD) location when not seen in (US) and detect the associated complications. It also has a role in determining the proper method of removal. The results of US, X-ray and (CT) were correlated with that of operative procedures. Similarly, a study done in 2011 suggested using different radiological investigative modalities for localization of the missed (IUCD) [15].

According to (US), the (IUCD) was correctly positioned in 88% of cases to be found embedded in myometrium in 32%, in Douglas pouch in 14%, low displaced in 10%, displaced by fibroid and in the pelvic cavity in 8% for both, in adnexa in 6% and displaced by pregnancy in 4%. (IUCD) perforated myometrium in 4% and urinary bladder in 2%. (IUCD) could not be localized in 12%. There was a highly

significant strong agreement between (US) and intraoperative findings among the studied cases. According to a reported study on 74 patients [16], misplaced (IUCD) could be properly diagnosed by (US), and this also was going with other previous studies [11, 9] in which 85%, 50% of cases respectively could be properly diagnosed by (US).

Twenty-one (42%) cases had X-ray examination, the most frequent places for (IUCD) was midline pelvis, left pelvis and right pelvis (16%, 10% & 6% respectively). In 10% of cases, the (IUCD) was found in the abdomen. There was highly statistical significant perfect agreement between X-ray and intraoperative findings among the studied cases. According to a study done in 2018, 15% of cases could be diagnosed by X-ray [9]. Use of X-ray was the commonest mode of diagnosis (50%) in a study reported in 2011 [15].

Nine (18%) cases had (CT) examination, 8% had (IUCD) intra-abdominal within omentum without perforation, 4% (IUCD) had it perforating myometrium and 2% had it extra-uterine in the pelvic cavity. Also, two cases had (IUCD) perforating urinary bladder and bowel one 2% for each. There was highly statistical significant perfect agreement between (CT) and intraoperative

findings among the studied cases. Those findings are in agreement with studies which suggested using (CT) with other investigative modalities for localization of the missed (IUCD) [15, 17] but another study reported that (CT) might be required very rarely in cases of transmigrated/misplaced (IUCD) [11].

The most common methods used for removal among the studied cases were hysteroscopy; laparoscopy and cervical dilatation and retrieval hook (40%, 36% & 14% respectively). According to a study done in 2019, 65% of patients required hysteroscopic guided removal. In 20% of patients (IUCD) was removed using long artery forceps under anesthesia. 15% of patients had laparoscopic removal and none required laparotomy [11].

Our study included 50 instances of Misplaced (IUCD). We found that, as confirmed by operative results, 90% had an unusual location within the pelvis, (54% intrauterine and 36% extra-uterine). Only 10% had it in the intra-abdominal cavity. In 32% of cases (IUCD) was embedded in the myometrium, in 10% was low displaced, in 8% was displaced by fibroid, in 4% was displaced by pregnancy. Additionally in 14% (IUCD) was in Douglas pouch, in 10% was in the pelvic cavity, in 6% was in

adnexa, in 4% (IUCD) perforated the myometrium, in 2% perforated the urinary bladder, in 8% (IUCD) was seen within omentum without perforation and in 2% perforated bowel wall. According to another study, 38.8% of the studied cases had (IUCD) within omentum without perforation, 22.2% had it in Douglas pouch, 16.6% had it embedded to the myometrium, 11.1% had it perforating bowel and only one case (5.5%) had it in adnexa and perforating UB for both of them [18]. A study done in 2015 reported that the most common extra-uterine (IUCD) location was the Douglas pouch in 52.3% of the studied patients. The (IUCD) was found in adnexa and within omentum in 19% of cases for both of them and the rare location of the retro-peritoneum was seen in two cases [10].

---

## Conclusion

(US) is the first modality used in the diagnostic workup of the misplaced (IUCD); but it is not reliable if the omentum and bowel loops surround the device. The X-ray can help confirm (US) result and exclude expulsion. Rarely (CT) is used for (IUCD) localization. However, the (CT) is the best for the evaluation of complications associated with intra-abdominal (IUCDs)

and also has a role in determining the proper method of removal.

---

## References

1. Boortz HE, Margolis DJA, Ragavendra N, Patel MK and Kadell BM. Migration of Intrauterine Devices: Radiologic Findings and Implications for Patient Care. *RadioGraphics* 2012; 32:335–352.
2. Wildemeersch D, Hasskamp T and Norman D Goldstuck. Malposition and displacement of intrauterine devices diagnosis, management and prevention. *Clin Obstet Gynecol Reprod Med*. 2016; Volume 2(3): 183-188.
3. Michelle L, Stalnaker and Andrew M. Kaunitz. How to identify and localize IUDs on ultrasound. *OBG Management* 2014; Vol. 26 No. 8.
4. Rowlands S, Oloto E and David H Horwell. Intrauterine devices and risk of uterine perforation: current perspectives. *Open Access Journal of Contraception* 2016; 7 19-32.
5. Peri N, Graham D and Levine D. Imaging of Intrauterine Contraceptive Devices. *J Ultrasound Med*. 2007; 26:1389–1401.
6. El Saadi A , Mohandes I , Emad M and Abdulbaqim H .The role of CT scan in laparoscopic retrieval of a perforated intrauterine device (IUD). *Gynecol Surg* 2004; 1:248–250.
7. Devassy R, Golpalakrishnan S, Torres-de la Roche LA, Verhoeven H, De Wilde MS and De Wilde RL. The missing intrauterine device. *Int J Reprod Contracept Obstet Gynaecol* 2016; 5:3587-9.
8. Ikechebelu JI and Mbamara SU. Laparoscopic retrieval of perforated intrauterine device. *Niger J Clin Pract* b. 2008; 11:394-5.
9. Adewale FB and Ashimi A. Missing intrauterine contraceptive device string. Diagnosis and management at Federal Medical Centre, Bida Northcentral Nigeria. *Trop J Obstet Gynaecol* 2018; 35:298-303. 91.
10. Kaplanoglu M, Bülbul M, Yüce T, Kaplanoglu D and Aban M Mislocated extrauterine intrauterine devices: Diagnosis and surgical management. *J Turk Ger Gynecol Assoc* 2015; 16: 91-5.
11. Varun N, Jain A, Nigam A, Noor S, Gupta N and Sharma S. Approach Towards Misplaced or Malposition IUCD: Lessons Learned. *Journal of Clinical and Diagnostic Research* 2019; 40534.12835.
12. Gupta M and Jain G. Misplaced IUCD: Challenges and Management. *PJSR*. 2016; 9(2):14-17.
13. Elahi N and Koukab H. Diagnosis and Management of Lost Intrauterine Contraceptive Device. *JPM* 2002; 52:18.
14. Adebayo AA, Olumide AT, Akujuobi OR, Oluseyi AI, Adewumi B and Olabisi AT, et al. Misplaced ("Missing") Intrauterine Contraceptive Device Among Clients at a Rural Tertiary Hospital in South Western Nigeria. *Journal of Gynecology and Obstetrics* 2019; 7(2): 51-55.
15. Ezegwui HU, Ikeako LC and Egbuji C. Missing Intrauterine Contraceptive Device among Clients in Enugu. *Niger J Surg* 2011; 17(2):60-63. 90.
16. Montaser H, Elhelwand E and Hamed A. Role of VCI –OMNIVEIW (4D Ultrasound technology) in accurate and fast detection of IUCD complications. *Ejpmr* 2017; 4(06), 17-25.
17. Ibitoye BO, Aremu AA, Onuwaje MA and Ayoola OO. What is the fate of the missing intrauterine contraceptive device? *TROPICAL DOCTOR* 2009; 39: 221–223.
18. Barsaul M, Sharma N and Sangwan K. 324 Cases of misplaced IUCD - a 5-year study. *TROPICAL DOCTOR* 2003; 33, 11-12.

**To cite this article:** Hesham E. Elsheikh, Manal A. ElRefaei, Sara F. Abd Elfattah. Assessment of Misplaced Intrauterine Contraceptive Devices by Different Imaging Modalities: A Cross-sectional Study. *BMFJ* 2021;38(Radiology): 137-146. DOI: 10.21608/bmfj.2021.53109.1357