

# Effect of Using Densah Burs on Implant Stability and Peri-implant Marginal Bone Loss in Maxillary Implant Supported Partial Overdentures

Original  
Article

Marwa Kothayer<sup>a,b</sup> and Ahmed Mostafa Abdelfattah<sup>a</sup>

Department of Oral and Maxillofacial Prosthodontics, Faculty of Dentistry, <sup>a</sup>Ain Shams University, Cairo, Egypt, <sup>b</sup>Taibah University, Al-Madinah Al-Munawarah, Saudi Arabia

## ABSTRACT

**Background:** This study investigated the effect of Densah Burs on the primary and secondary implant stability, in addition to periimplant mean marginal bone loss in maxillary implant supported partial overdentures.

**Materials and Methods:** Ten patients with posteriorly edentulous maxillae following Kennedy class I classification were selected. Each patient received two implants; one in each side. On one side, the implant osteotomy was prepared using conventional surgical drills while on the other side, Densah burs were used. Implant stability was measured at implant insertion and time of loading using Osstell device. Mean marginal bone loss was measured at 6 and 12 month interval using Cone Beam CT scan.

**Results:** Statistical Significant difference was noted between both types of drills on primary implant stability but not on secondary implant stability or mean marginal bone loss at 6 and 12 month interval.

**Conclusion:** Densah drilling Burs may improve initial implant stability; a situation that may help when immediate loading of implants is planned especially if they are splinted. Moreover, they might not have a different effect rather than conventional drilling burs on marginal bone loss.

**Key Words:** Densah burs, Implant stability, Marginal bone loss and Osstell.

**Received:** 04 April 2020, **Accepted:** 09 May 2020.

**Corresponding Author:** Ahmed Mostafa Abdelfattah Mohamed, Department of Oral and Maxillofacial Prosthodontics, Faculty of Dentistry, Ain Shams University, Cairo, Egypt, **Tel.:** +2022410778, **Mobile:** +201111191337, **E-mail:** ahmedmostafa@dent.asu.edu.eg.

**ISSN:** 2090-097X, January 2020, Vol. 11, No. 1

## INTRODUCTION

Dental implants are considered one of the most successful treatment options for completely or partially edentulous mandible and maxilla. In maxilla the nature of bone together with the atrophy which occurs after extraction present an obstacle in planning dental implants<sup>[1-2]</sup>.

Osseointegration which is a must for implant loading is defined as the direct structural and functional connection between living bone and the titanium implant surface. Amongst all factors that affects implant success, primary stability is one of the most important ones<sup>[3-4]</sup>.

Primary stability comes from mechanical anchorage between the fixture and the bone walls of the implant bed. Secondary stability is the progressive increase in stability achieved through bone formation and remodeling in contact with the implant surface during the healing period<sup>[5]</sup>.

The primary stability of dental implants depends on bone quantity and quality, implant design, implant surface features and the surgical technique used for preparing the osteotomy<sup>[6]</sup>.

Decreased primary stability may result in defective secondary stability, which is, osseointegration<sup>[7]</sup>.

Poor density bone (D3-D4) is usually noticed in the maxillary posterior regions. This is why the insertion torque values of the implant placed is usually below the acceptable values. This will lead to a low success rate for implants placed in these areas<sup>[8-9]</sup>.

Low bone density is usually noted in the posterior area of the maxilla. In 2015, a technique using a specially designed densifying bur was proposed for implant site preparation. This bur was claimed to improve bone density in the drilling site<sup>[8-10]</sup>.

During the osseodensification process, bone is compacted into open marrow spaces during drilling and thus implant insertion torque is increased by densification of osteotomy site walls<sup>[11]</sup>.

The densifying bur consists of cutting chisel and tapered shank allowing it to progressively increase the diameter as it is moved deeper into the osteotomy. Furthermore, drilling can be operated in two rotation directions; clockwise (CW) and counterclockwise (CCW) rotation directions that

is more efficient at the densification process and can be utilized in low-density bone, while the clockwise drilling direction is suitable for higher-density bone<sup>[12]</sup>.

Percussion, mobility tests and radiographs are methods to assess implant stability. All these methods have the disadvantages of lack of standardization, susceptibility to operator-associated variables and poor sensitivity<sup>[13-15]</sup>.

Recently, a noninvasive technique called resonance frequency analysis has been used for the assessment of the stability of implants. The advantages of this technique are that it is straightforward, rapid, easy to perform and there is no risk of discomfort to the patient<sup>[16]</sup>.

Qualitative and quantitative conditions of alveolar bone can be evaluated by Cone Beam Computed Tomography (CBCT). Advantages of CBCT include three-dimensional visualization of anatomic structures, greater precision for diagnosis and analysis than with traditional 2-dimensional radiography and reduced cost and lower radiation exposure compared with multidetector computed tomography<sup>[17-20]</sup>.

This study was planned to determine the effect of Densah Burs on the primary and secondary implant stability, in addition to peri-implant mean marginal bone loss compared with conventional surgical burs when used for implant osteotomy site preparation. The null hypothesis was that there was no difference in implant stability and peri-implant marginal bone loss between both techniques.

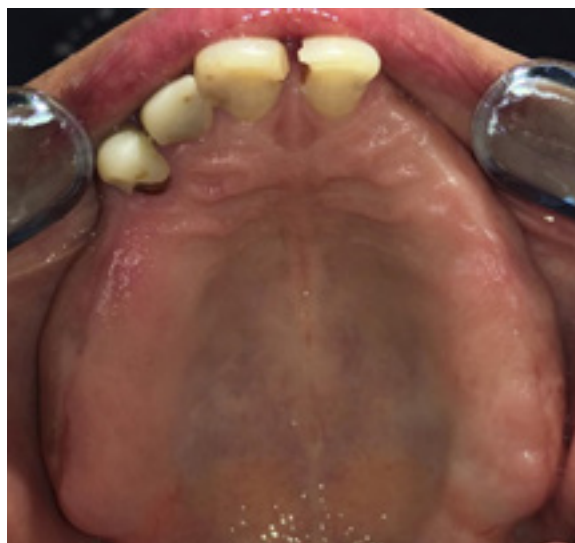## MATERIALS AND METHODS

### *Patient Selection:*

Ten male patients with age range (45 – 60) years old from those attending the out-patient clinic of Oral and Maxillofacial Prosthodontic Department, Faculty of Dentistry - Ain Shams University to participate in the study.

Male patients had Kennedy class I partially edentulous maxillary arch and dentulous or partially edentulous restored with fixed restoration mandibular arch (Figure 1). Patients with systemic diseases that might affect bone quality, increase surgical risk, delay or complicate post-operative healing were excluded. Also patients with any muscular or TMJ disorders, parafunctional habits, severe cardiovascular diseases, metabolic disorders, history of previous radiotherapy and chemotherapy, and smoking patients were excluded.

Clinical extra and intra oral examination were carried out for all patients. Only patients with good oral hygiene were involved in the study. The residual alveolar ridges should be covered with firm healthy mucosa, free from any signs of flabbiness, ulceration or inflammation.



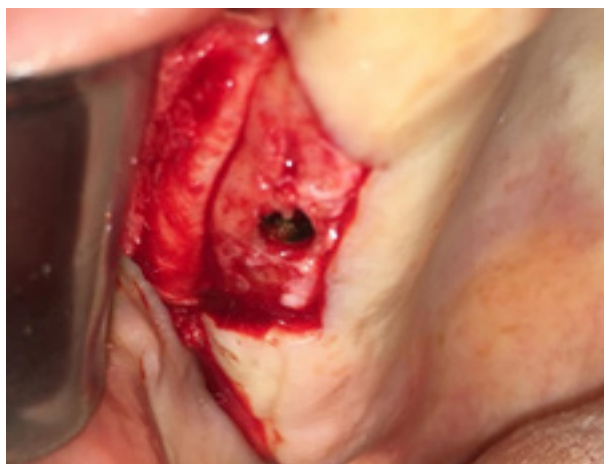**Figure 1:** Kennedy class I partially edentulous maxillary arch.

Preliminary impressions in irreversible hydrocolloids (Cavex CA37 Alginate, Cavex, Netherlands) were taken and diagnostic casts were mounted to evaluate ridge relationship and available interarch space. For all patients maxillary removable partial dentures were then constructed in a conventional method and delivered. Follow up appointments were scheduled for each patient two weeks before implant placement. The maxillary removable partial dentures were duplicated into clear heat cured acrylic resin to be used as a stent. A Cone Beam CT scan was made for each patient while wearing the stent to determine bone dimensions at proposed implant sites.

### *Surgical steps:*

Implants (Nucleoss Implant system, Turkey) with 4.1 mm diameter and 10 mm lengths were used in this study. Two implants were placed in each patient; one in each side in the molar region. For each patient implant drilling was carried out in a conventional method in one side while in the other side osseodensification drilling with Densah Bur (Versah, Jackson, MI, USA) was carried out. After administration of infiltration anesthetic solution (Mepicaine local anaesthesia, Alexandria company for pharmaceuticals and chemical industry), a three-line trapezoidal incision was made and a full thickness mucoperiosteal flap was reflected. The stent was used to mark the proposed conventional implant sites.

For the side where the osteotomy preparation was made using the conventional drills a round bur was used to mark the implant sites guided by the surgical stent. Preparation of implant sites started with the 2.3 mm diameter pilot drill. The osteotomy preparation was continued using a drill 2.8 mm in diameter followed by 3.4 mm drill and finally by a 3.8 mm drill at 800 rpm speed with copious irrigation (Figure 2).



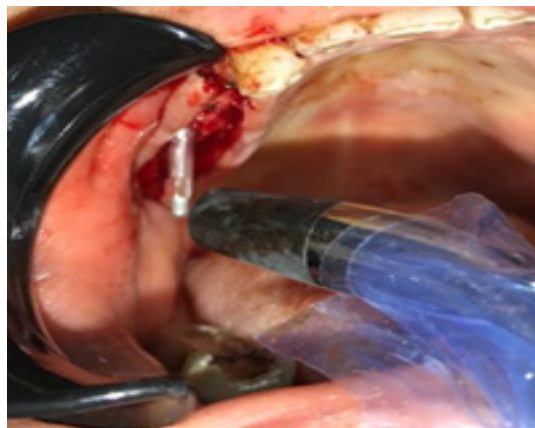
**Figure 2:** Flap reflection and osteotomy preparation.

For the other side after marking the implant site, the osseodensification protocol was followed. Osteotomy was prepared to the desired depth using the pilot drill in a clockwise rotation direction at speed 800 rpm with copious irrigation. Thereafter osseodensification drills were used in sequence. Drilling was performed in a clockwise direction using VT1828, and then the drill motor was reversed counter clockwise drill speed 800 rpm with copious irrigation. Gradually wider diameter bur (VT2838) was used in the same manner as (VT1828) (Figure 2).

The implants were picked up from the sterile vial and directly inserted into the prepared site and then a torque wrench was used until the implant top flushed with the ridge crest.

The smart peg was then secured to the implant fixture on each side and the initial implant stability was then measured using the Osstell device (Osstell TM, Integration Diagnostics, Savedalen, Sweden) that records implant stability quotient (ISQ). The Osstell probe was located close to the smart peg and the ISQ value was recorded. (Figure 3) Smart peg was then retrieved and the cover screws were secured to the fixture. The mucoperiosteal flap

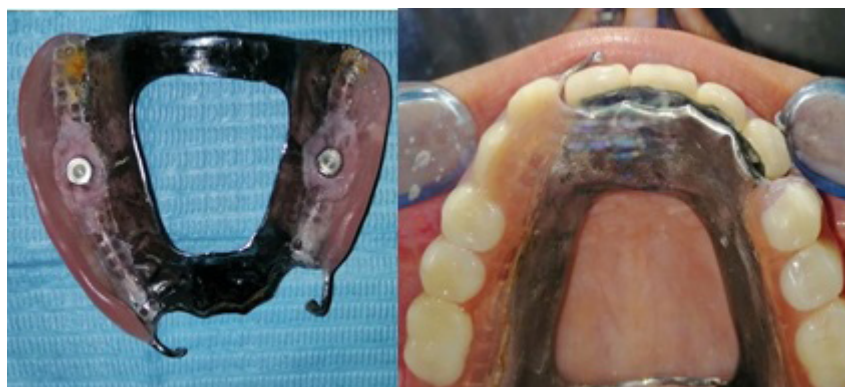was repositioned and sutured using 000 interrupted black silk suture.



**Figure 3:** Resonance frequency analysis.

Seven days after surgery patients were recalled to remove the sutures. Six months later, the second stage started in which exposure of the implant fixtures took place and healing abutments were secured to the implant fixture. Upon soft tissue healing, the healing abutments were removed and the smart pegs were reattached to the implant fixture and ISQ value was recorded using the Osstell device to measure secondary implant stability. The smart peg was then removed and ball abutments were secured to the implants.

Prior to the pick-up of the metal housings, block-out shim was adapted to each abutment to block out the undercut areas inferior to the ball abutments, then the metal housings were placed in place. A recess was made in the denture base opposite to each ball abutment and hard denture lining material was used for chair-side pick-up of the metal housings. The lining material bonding agent was applied into the recess of the denture base, the lining material was then added and the denture was fully seated in the patient's mouth. The patient was guided to close in centric relation till complete curing of the hard denture liner occurred (Figure 4).



**Figure 4:** Implant supported maxillary partial overdenture after pick up.

The mean marginal bone loss for each implant was measured using cone beam CT (K.V.P 85, M.A 16, resolution 100150- voxel, F.O.V 7\*14.5\*14.5 and scanning time 20 Sec) at the time of 6, and 12 month interval. The mean marginal bone loss was the mean of the marginal bone loss on the mesial, distal, buccal and lingual sides of the implant. The amount of bone loss was calculated from the implant platform to the level of bone crest in mm on each side of the implant using the Cone beam CT software ruler (Figure 5).

**RESULTS**

The paired t test was used for comparison between primary and secondary implant stability in each group. Similarly, paired t test was used for comparison of

marginal bone loss at 6 and 12 months intervals in each group. However, unpaired t test was used for comparison of primary implant stability, secondary implant stability and marginal bone loss at 6 and 12 months interval between both groups. P value of 0.05 was chosen as level of significance in which values < 0.05 were considered significant.

Regarding primary implant stability when using conventional surgical drills, the mean ISQ value was  $55.75 \pm 10.44$  while for the Densah burs was  $67.63 \pm 5.73$ . These results show a statistical significance as the p value was 0.01. However, the values for secondary implant stability while using the conventional surgical drills and the Densah burs were  $68.88 \pm 4.70$  and  $70.75 \pm 4.89$  respectively and the P value was 0.44 showing no statistical significance as shown in Figure 6 and Table 1.

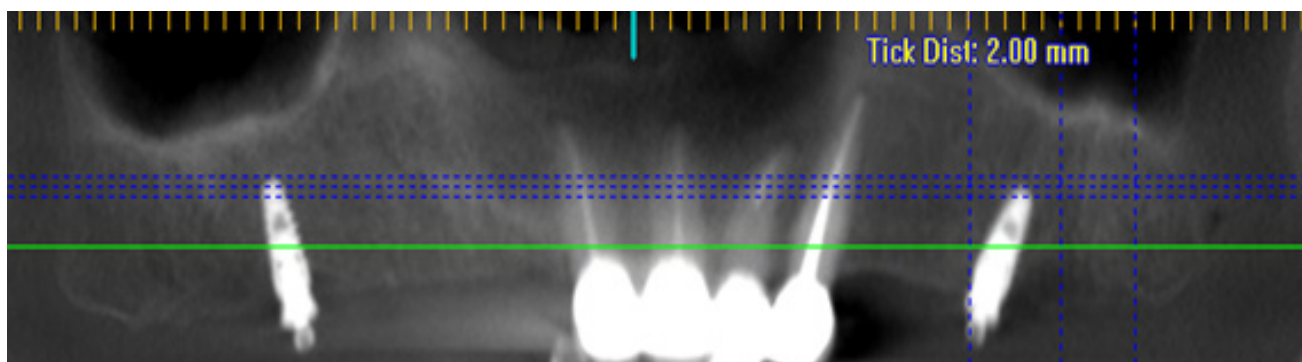


Figure 5: Cone beam computed tomography at follow up appointments after implant loading.

Table 1: Mean and standard deviation for primary, secondary implant stability, mean marginal bone loss at 6 and 12 month interval for conventional surgical drills and Densah burs:

Implant stability		Primary	Secondary	Test value*	P-value	Sig.
Conventional surgical drills	Mean ± SD	55.75 ± 10.44	68.88 ± 4.70	3.2	0.012	S*
	Range	32 – 60	63 – 78			
Densah burs	Mean ± SD	67.63 ± 5.73	70.75 ± 4.89	1.244	0.284	NS**
	Range	60 – 76	63 – 77			
	P-value	0.01 (S)*	0.44 (NS)**			

Mean Marginal bone loss		6 month follow up	12 month follow up	Test value	P-value	Sig.
Conventional surgical drills	Mean ± SD	0.65 ± 0.23	1.36 ± 0.21	7.1	0.001	S*
	Range	0.33 – 0.93	1 – 1.6			
Densah burs	Mean ± SD	0.65 ± 0.25	1.2 ± 0.18	5.6	0.002	S*
	Range	0.3 – 0.98	0.95 – 1.5			
	P-value	0.990 (NS)**	0.27 (NS)**			

\*Statistical significant difference

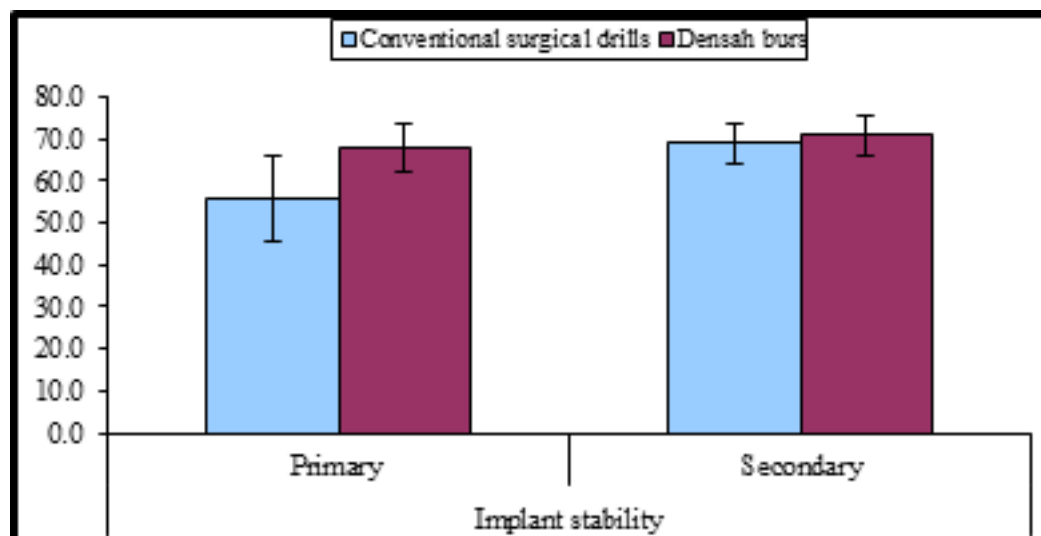
\*\*Non statistical significant difference

On comparing the primary and secondary implant stability when the osteotomy site was prepared using the conventional surgical drills, the *P* value was 0.012 showing a statistical significance. However, it was 0.284 on comparing the primary and secondary implant stability when the osteotomy site was prepared using the Densah burs (Figure 6).

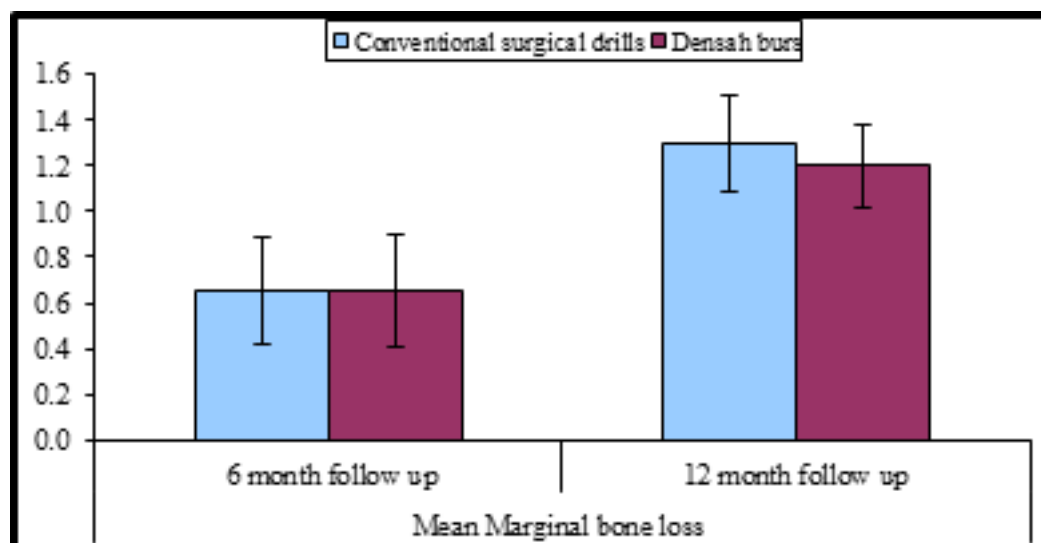
The mean marginal bone loss at the first 6 month follow up was  $(0.65 \pm 0.23)$  mm when the osteotomy site was prepared using conventional surgical drills and  $(0.65 \pm 0.25)$  mm when it was prepared using the Densah burs. The *P* value was 0.990 showing no statistical

significance. At 12 months follow up, the mean marginal bone loss was  $(1.36 \pm 0.21)$  mm when using conventional surgical drills for osteotomy preparation and  $(1.20 \pm 0.18)$  mm when using the Densah burs. There was no statistical significance as the *P* value was 0.27.

On comparing the mean marginal bone loss at the 6 and 12 month intervals when the osteotomy site was prepared using the conventional surgical drills, the *p* value was 0.001 showing a statistical significance. However, it was 0.002 when the osteotomy site was prepared using the Densah burs showing a statistical significance too as shown in Figure 7 and Table 1.



**Figure 6:** Bar chart showing mean and standard deviation of primary and secondary implant stability using conventional surgical drills versus Densah burs.



**Figure 7:** Bar chart showing mean and standard deviation of mean marginal bone loss at 6 and 12 month interval using conventional surgical drills versus Densah burs.

## DISCUSSION

This study investigated the effect of osseodensification instrumentation on the primary and secondary implant stability in addition to mean marginal bone loss in low-density bone.

Bad oral hygiene is one of the most risk factors leading to implant failure so only patients with good oral hygiene are selected to participate in this study. Age range for the selected patients was 45 to 60 years old to avoid effect of age on muscle tone, oral mucosa and residual ridge<sup>[21, 22]</sup>.

Only male patients were included due to high prevalence of post-menopausal osteoporosis in females, which might alter bone metabolism and reduce healing capacity<sup>[23]</sup>. Patients with systemic diseases that might affect bone quality, increase surgical risk, delay or complicate post-operative healing, cardiovascular diseases, metabolic disorders, history of previous radiotherapy and chemotherapy were excluded to decrease risk of implant failure<sup>[24, 25]</sup>.

In a study, specially designed condensers and expanders were employed for condensation of low-density bone. In this way, it was assumed that the bone is condensed apically and laterally by using the osteotomes. Bone density was reported to increase in the periapical area only and not along the lateral walls<sup>[26]</sup>. However, hammering with a mallet is involved in the technique of bone condensation. Such a way may be difficult for the operating surgeon to control and may result in unintentional displacement<sup>[27]</sup>.

An osseodensification drilling technique that allowed expansion of the drilling site was proposed in 2015. This technique used specially designed burs operating in a counterclockwise direction instead of hammering with a mallet<sup>[10, 28]</sup>.

High temperature during drilling causes bone necrosis in the osteotomy site. so precautions were taken during drilling as using refrigerated saline, sharp drills and sequential drilling. High temperature during osteotomy site preparation causes bone necrosis and affects implant osseointegration<sup>[29]</sup>.

Drilling was also operated in both counterclockwise (CCW) and clockwise (CW) rotation directions. the counterclockwise drilling can be utilized in low density bone as it was reported to be efficient in the densification process<sup>[12]</sup>. During drilling with Densah burs, both clockwise initially and then counterclockwise drilling was employed. However, during drilling with conventional surgical drills, clockwise drilling only was used.

Delayed loading was adopted in this study as the rates of implant loss when using immediate loading with ball attachments are higher in comparison to delayed loading<sup>[30]</sup>. Implant stability quotient was measured in this study using the Osstell device as it is straightforward, rapid

and easy to perform and there is no risk of discomfort to the patient<sup>[16]</sup>.

Cone Beam CT scan was used in this study as it can be used to measure alveolar bone height with accuracy and reliability. Therefore, Cone Beam CT was used in this study for the evaluation of marginal bone loss<sup>[31 - 33]</sup>.

Surgical technique is one of the important factors affecting primary stability<sup>[34 and 35]</sup>. The results of this study match that of another study regarding primary implant stability in which there was statistically significant difference between both techniques of drilling<sup>[36]</sup>. However, another study showed no statistical significant difference although the values attained by using Densah bur for drilling was slightly higher than that attained by using conventional surgical drills<sup>[37]</sup>.

The results of the present study showed that Densah bur drilling significantly increased primary implant stability compared to conventional drilling. This may be due to the claim that this technique preserve bone by two ways, first by compacting cancellous bone by its plastic deformation second by autografting of bone particles at the apex and length of osteotomy<sup>[38]</sup>.

This technique utilizes a specially designed drills with several negative rake angles acting as noncutting edges and have four or more lands that smoothly compact the bone along the osteotomy<sup>[38]</sup>.

Densah bur osteotomy diameter was also found to be smaller than conventional osteotomies due to the spring back action of bone and elastic strain. This increased the percentage of available bone at the implant site by about three times. Histomorphological analysis showed autologous bone chips in the osseodensified osteotomy sites especially in bone of low density relative to conventional drills<sup>[39]</sup>.

The low primary stability of the conventional drilling implants may be due to the nature of the bone in the region of the posterior maxilla which characterized by low density (D3-D4 bone) in addition to the fact that conventional drilling does not allow bone densification<sup>[8 and 9]</sup>.

Regarding secondary implant stability, similar results were attained by another study that showed no statistically significant difference between both techniques of drilling as this study<sup>[40]</sup>.

However, another study showed a statistically significant difference between both types of drilling; a study in which sinus floor elevation was attempted. This study postulated that more traumatic damage in bone was caused by osteotome sinus floor elevation used with conventional drilling; a condition that lead to delayed achievement of secondary implant stability due to the more time needed for the repair of microdamage that stimulated osteoclast activation. However, in the present study, no sinus floor elevation was attempted<sup>[41]</sup>.

Osseointegration or secondary stability is affected by the quality and quantity of bone at bone-implant interface. Osseodensification leads to increase bone at implant surface by increasing bone mineral density in peri-implant area. This explained why secondary stability of implants placed by Densah bur drilling was slightly higher than when the conventional drilling burs were used<sup>[42]</sup>.

The results of this study for marginal bone loss after 6 months follow up match that of other studies in which there was no significant difference between both types of drills used<sup>[40 and 41]</sup>.

A 12 month follow up showed that the peri-implant mean marginal bone loss was slightly higher when osteotomy sites were prepared using conventional drills compared to Densah burs. However, this difference was not statistically different. This may be due to the different healing pattern as it was found that the Densah bur drilling had no negative effect on bone healing compared to conventional drilling. The autografted bone chips in the osteotomy wall of densah bur side were also nuclei for more and dense bone formation as compared to conventional drilling side<sup>[40]</sup>.

## CONCLUSION

Densah drilling burs may improve initial implant stability; a situation that may help when immediate loading of implants is planned especially if they are splinted. Moreover, they might not have a different effect rather than conventional drilling burs on marginal bone loss.

## CONFLICT OF INTEREST

The authors declare no conflict of interest.

## REFERENCES

1. Agarwal R and García A G: Biomaterial strategies for engineering implants for enhanced osseointegration and bone repair *Adv. Drug Deliv. Rev.* 2015; 94: 53 - 62.
2. Summers RB: A new concept in maxillary implant surgery: The osteotome technique. *Compendium.* 1994; 15: 154 - 6.
3. Ferro KJ, Morgano MS, Driscoll CF *et al.*: The glossary of prosthodontic terms ninth edition. *J Prosthet Dent.* 2017; 117: 1 - 105.
4. Rossi F, Botticelli D, Cesaretti G *et al.*: Use of short implants (6 mm) in a single-tooth replacement: a 5-year follow-up prospective randomized controlled multicenter clinical study. *Clin Oral Implants Res* 2016; 27: 458 – 464.
5. Lopez CD, Alifarag AM, Torroni A *et al.*: Osseodensification for enhancement of spinal surgical hardware fixation. *J Mech Behav Biomed Mater.* 2017; 69:275 - 81.
6. Almutairi AS, Walid MA and Alkhodary MA: The effect of osseodensification and different thread designs on the dental implant primary stability. *F1000Res.* 2018; 7: 1 - 10.
7. Palaskar J N, Joshi N, Shah P *et al.*: Influence of different implant placement techniques to improve primary implant stability in low-density bone: A systematic review. *J Indian Prosthodont Soc.* 2020; 1: 20 - 25.
8. Bra-nemark PI, Zarb GA, Albrektsson T *et al.*: Tissue-integrated prostheses. Osseointegration in clinical dentistry. *J Prothet Dent.* 1985; 54:199 – 209.
9. Mameno T, Wada M, Otsuki M *et al.*: Risk indicators for marginal bone resorption around implants in function for at least 4 years: A retrospective longitudinal study. *J Periodontol.* 2019; 91:37 - 45.
10. Huwais S and Meyer E: Osseodensification. A novel approach in implant preparation to increase primary stability, bone mineral density and bone to implant contact. *Int J Oral Maxillofac Implant.* 2015; 32: 27 - 36.
11. Paula GF, Pessôa de Oliveiraa, Edmara TP *et al.*: Osseodensification outperforms conventional implant subtractive instrumentation: A study in sheep. *Mater Sci Eng C.* 2018; 90: 300 – 7.
12. Lahens B, Neiva R, Tovar N *et al.*: Biomechanical and histologic basis of osseodensification drilling for endosteal implant placement in low density bone. An experimental study in sheep, *J Mech Behav Biomed Mater.* 2016; 63: 56 – 65.
13. Lages F S, Douglas-de Oliveira D W and Costa F O.: Relationship between implant stability measurements obtained by insertion torque and resonance frequency analysis: A systematic review. *Clin Implant Dent Relat Res.* 2017; 12.1 - 10.
14. Meredith N, Book K, Friberg B *et al.*: Resonance frequency measurements of implants stability in vivo. A cross-sectional and longitudinal study of resonance frequency measurements on implant in the edentulous and partially dentate maxilla. *Clin Oral Implants Res.* 1997; 8: 226 – 33.

15. Gehrke SA, da Silva Neto UT, Rossetti PH *et al.*: Stability of implants placed in fresh sockets versus healed alveolar sites: early findings. *Clin Oral Implants Res.* 2016; 27 :577 – 582.
16. Neto UT, Joly JC and Gehrke SA: Clinical analysis of the stability of dental implants after preparation of the site by conventional drilling or piezosurgery. *BRIT J ORAL & Maxillofacial Surgery.*2014; 52 :149 – 53.
17. Kapila S, Conley RS and Harrell JR: The current status of cone beam computed tomography imaging in orthodontics. *Dento Maxillo Fac Radiol.* 2011; 40: 24 - 34.
18. Signorelli L, Patcas R, Peltomaki T *et al.*: Radiation dose of cone-beam computed tomography compared to conventional radiographs in orthodontics. *J Orofac Orthoped.* 2016; 77: 9 - 15.
19. Kaeppler G.: Applications of cone beam computed tomography in dental and oral medicine. *Int J Comput Dent.* 2010; 13: 203 - 219.
20. Wen J, Liu S, Ye X, *et al.*: Comparative study of cephalometric measurements using 3 imaging modalities. *J Am Dent Assoc.* 2017; 148: 913 - 21.
21. Clark D and Levin L: Dental implant management and maintenance: how to improve long-term implant success? *Quintessence Int.* 2016; 47: 417 - 423.
22. Ahuja S, Wicks R and Selecman A: Fabrication of new restorations with a consideration of oral hygiene. *J Indian Prosthodont Soc.* 2016; 16: 307 – 10.
23. Gallagher JC and Tella SH: Prevention and treatment of postmenopausal osteoporosis. *J Steroid Biochem Mol Biol.* 2014; 142: 155 - 170.
24. Gheorghiu I and Stoian I: Implant surgery in healthy compromised patients-review of literature. *J Med Life.* 2014; 7: 7 – 10.
25. Vissink A, Spijkervet F K L and Raghoobar G M: The medically compromised patient: Are dental implants a feasible option? *Medicine Oral diseases.*2018; 24: 253 - 260.
26. Wang, L, Wu, Y, Perez KC *et al.*: Effects of condensation on peri-implant bone density and remodeling. *J Dent Res.* 2017; 96:413 – 420.
27. Dragonas P, Katsaros T, Avila-Ortiz G *et al.*: effects of leukocyte–platelet-rich fibrin (L-PRF) in different intraoral bone grafting procedures: a systematic review. *Int J Oral Maxillofac Implant.* 2019; 48: 250 - 262.
28. Kanathila H and Pangi A: An Insight into the Concept of Osseodensification-Enhancing the Implant Stability and Success. *J Clin Diag Research.* 2018; 12: 1 - 3.
29. Montero-Aguilar A, Sibaja-Ruiz L, Avendaño E *et al.*: Evaluation of Surgical Bur Deformation and Bone Surface Roughness after Multiple Uses. *J Oral and Maxillofac Surg.* 2019; 77: 1894 - 903.
30. Ravidà A, Barootchi S, Askar H, *et al.*: Long-Term Effectiveness of Extra-Short ( $\leq 6$  mm) Dental Implants: A Systematic Review. *Int J Oral & Maxillofac Implants.* 2019; 34: 68 - 84.
31. Amarnath GS, Kumar U, Hilal M *et al.*: Comparison of cone beam computed tomography, orthopantomography with direct ridge mapping for pre-surgical planning to place implants in cadaveric mandibles: an ex-vivo study. *J Int Oral Health.* 2015; 7: 38 - 42.
32. Cook VC, Timock AM, Crowe JJ *et al.*: Accuracy of alveolar bone measurements from cone beam computed tomography acquired using varying settings. *Orthod Craniofac Res.* 2015; 18: 127 - 36.
33. Gupta S, Patil N, Solanki J, *et al.*: Oral Implant Imaging: A Review. *Malays J Med Sci.* 2015; 22: 7 – 17.
34. Chrcanovic BR, Albrektsson T and Wennerberg A: Reasons for failures of oral implants. *Journal of Oral Rehabilitation.* 2014; 41: 443 – 76.
35. Bosshardt DD, Chappuis V and Buser D.: Osseointegration of titanium, titanium alloy and zirconia dental implants: current knowledge and open questions. *Periodontol.* 2017; 73: 22 – 40.
36. Arafat SW and Elbaz MA.: Clinical and radiographic evaluation of osseodensification versus osteotome for sinus floor elevation in partially atrophic maxilla: A prospective long term study. *Egy Dent J.* 2019; 65: 189 - 95.
37. Sultana A, Makkar S, Saxena D *et al.*: To compare the stability and crestal bone loss of implants



- placed using osseodensification and traditional drilling protocol: A clinicoradiographical study. *J Indian Prosthodont Soc.* 2020; 20: 45 - 51.
38. Padhyea NM, Padhyeb AM and Bhatavadekarc NB: Osseodensification — A systematic review and qualitative analysis of published literature. *J Oral Biol Craniofac Res.* 2020; 10: 375 – 80.
39. Pai UY, Agarwal N and Agarwala S: Indirect sinus lift of atrophic posterior maxilla using osseodensification: a case report. *J Indian Prosthodont Soc.* 2018; 18: 1 - 4.
40. Sultana A, Makkar S, Saxena D *et al.*: To compare the stability and crestal bone loss of implants placed using osseodensification and traditional drilling protocol: A clinicoradiographical study. *J Indian Prosthodont Soc* 2020; 20: 45 - 51.
41. Arafat SW and Elbaz MA.: Clinical and radiographic evaluation of osseodensification versus osteotome for sinus floor elevation in partially atrophic maxilla: A prospective long term study. *Egy Dent J* 2019; 65: 189 - 95.
42. Vignoletti F and Abrahamsson I: Quality of reporting of experimental research in implant dentistry. Critical aspects in design, outcome assessment and model validation. *J Clin Periodontol.* 2012; 39: 6 – 27.