

Effect of Ultrasound-Guided Injection of Local Ozone or Platelet Rich Plasma (PRP) Versus Corticosteroid in Plantar Fasciitis

Ahmed Gamal Salah Elsayy¹ MD; Hesham Said Abdelraouf¹ MD

*** Corresponding Author:**

Ahmed Elsayy

drahmedelsawy@azhar.edu.eg

Received for publication December 3, 2020; **Accepted** January 17, 2021; **Published online** January 17, 2021.

Copyright 2020 The Authors published by Al-Azhar University, Faculty of Medicine, Cairo, Egypt. All rights reserved. This an open-access article distributed under the legal terms, where it is permissible to download and share the work provided it is properly cited. The work cannot be changed in any way or used commercially.

doi: [10.21608/aimj.2021.52095.1368](https://doi.org/10.21608/aimj.2021.52095.1368)

¹ Anaesthesia and Intensive Care Department, Faculty of Medicine, Al-Azhar University, Egypt.

Disclosure: The authors have no financial interest to declare in relation to the content of this article. The Article Processing Charge was paid for by the authors.

Authorship: All authors have a substantial contribution to the article.

ABSTRACT

Background : Plantar fasciitis or recently called plantar fasciopathy, generally observed with heel spurs because of the deposition of calcium, although the definite pathology is still unknown. Ultrasound-guided injection of conventional corticosteroids was the primary treatment modality, with other emerging substances (e.g. Ozone or Platelet Rich Plasma PRP).

Aim of the study: This study was conducted to evaluate the effect of ultrasound-guided injection of local Ozone or Platelet Rich Plasma (PRP) versus conventional corticosteroid in the management of plantar fasciitis.

Patient and methods: this a randomized Prospective comparative study has done Al-Azhar university hospitals (Al-Hussein and Sayed Galal), where fifty-one patients have been diagnosed to have plantar fasciitis were included and allocated into one of three groups (17 patients in each group) to receive an ultrasound-guided injection of corticosteroid (control group), platelet-rich plasma (PRP) or Ozone O2-O3. Clinical evaluation and ultrasonographic measurement of the plantar fascia thickness was done before, at one, three and six months next to the injection. Primary outcome included: pain score using the visual analogue score (VAS). While secondary outcomes were plantar fascia thickness and foot quality health status.

Results: There was a highly significant decrease in VAS score and plantar fascia thickness, and an increase in foot pain domain of the foot health status (FHSQ) score in corticosteroid and Ozone groups ($p < 0.01$ respectively) in one month. Regarding 3-month results, there was a highly significant decrease in VAS score plantar fascia thickness, and an increase in FHSQ score in the corticosteroid group ($p < 0.01$ respectively). Regarding long-term 6-month results, there was a highly significant decrease in VAS score, plantar fascia thickness, and an increase in FHSQ score in the PRP group ($p < 0.01$ respectively).

Conclusion: Corticosteroid and Ozone injections were effective at short-term assessment, but PRP was more valuable at long-term assessment regarding pain management in plantar fasciitis patients.

Key Words: Plantar Fasciitis; Ultrasound; Corticosteroids; Ozone; Platelet- Rich Plasma

INTRODUCTION

Plantar fasciopathy is an inflammation of the thick ligament bridging between the heel and forefoot, substantiate foot arch and absorb shocks. The definite pathogenesis still not clear, but many causes are there as prominent heel spurs, overuse, repetitive microtrauma which could cause such pain and pathology.¹

Plasma is the liquid part of the blood in which the blood cells and platelets are suspended; it is a watery component that contains the different proteins and electrolytes.²

Platelet-rich plasma (PRP) is a high concentration of autologous platelets in a small volume of plasma produced by centrifugation of the patient's blood.

Due to the rich content of growth factors and mediators of their alpha granules (reworking boom aspect [TGF]-b1, platelet-derived boom aspect, simple fibroblast growth factor, vascular endothelial growth component, epidermal growth issue, insulin-like growth thing [IGF]-1), the (PRP) is being used to induce natural healing in injured tissues.³

Although the exact mechanism of action is unknown, The therapeutic effects of oxygen-ozone injection were reported in the management of various musculoskeletal diseases including low lower backache, herniated disc, failed low back syndrome, degenerative spine sickness, knee osteoarthritis and plantar fasciitis.⁴

One of the most common methods for management of PF is the local injection of long-acting

corticosteroid as it has rapid transitory pain relief. However, it may cause spontaneous rupture.⁵

Aim of the study: This study conducted to evaluate the effect of injection of local Ozone or Platelet Rich Plasma (PRP) versus conventional corticosteroid in the management of plantar fasciitis pain.

PATIENT AND MATERIALS

This a Prospective, randomized comparative study has done from January 2018 to June 2018 at Al-Azhar university hospitals (Al-Hussein and Sayed Galal).

Inclusion criteria: Patients ASA I-III, Patients aged 25-70, Patients with Plantar Fasciopathy for \geq six months not coping with medication for six weeks, morning pain score $>$ 5 on a visual analogue score (VAS).

Exclusion criteria: Patients ASA IV, repeated corticosteroid injections within the past three months, using Anti-inflammatory (NSAIDs) drug during the one week before receiving an intervention, BMI $>$ 40, foot deformity, previous foot surgery, peripheral neuropathy.

Fifty-one plantar fasciitis patients were included, and allocated randomly by opaque, closed envelopes into one of three groups (17 patients in each group) to have an ultrasound-guided injection of the plantar fascia with either corticosteroid (control group), platelet-rich plasma (PRP) or ozone O₂-O₃ after approval of the local and institutional ethics committee and written informed consent has signed by the participants.

Clinical evaluation and an ultrasound-guided measurement of the plantar fascia thickness was done before, at 1-month, 3-months, and 6-months following the injection.

Primary outcome measures included: pain Score using the visual analogue score (VAS). Secondary outcome measures included an ultrasonographic measurement of plantar fascia thickness, foot quality health by the foot pain domain of the foot health status (FHS) questionnaire.

FHSQ which is a diagnostic tool to determine the different aspects of foot health status as it contains 13 questions, which graded on a scale of 5 degrees (0-4); 4 for pain assessment, 3 for footwear, 4 for foot function evaluation, and two questions for the health of the foot .

Then each question score was recorded and analyzed by The Foot Health Status Questionnaire Data Analysis Software (Version 1.04) to give a score of 0-100 for each item.⁶

Clinical assessment and ultrasound-guided measuring the thickness of the plantar fascia was done before

the injection and at 1-month, three and 6-months following the injection.

A linear array transducer (6-13 MHz) (Acuson Freestyle, Siemens, Germany) figure (1) was used to measure the plantar fascia thickness and injection of the study drugs. To minimize the pain during the intervention: a pre-procedure block of posterior tibial was done guided by the ultrasound using 2ml 1% lidocaine hydrochloride figure (3).

Using (10 mm,22 G) needle has been inserted at in-plane approach toward the peak of fascia thickness figure (2),

Participants in the control group received an ultrasound-guided injection of 2 mL of 0.25% Bupivacaine, and 2 mL of 80 mg methylprednisolone acetate (Depo-Medrol, Pfizer, UK) into the medial calcaneal tubercle.

In the PRP group a (10-15cc of patient's blood was collected and centrifuged in a Rotofix 32A at 1500 cycles/minute for 5 minutes to separate the platelets and prepare 4 cc of concentrated platelets to be injected near the medial calcaneal tuberosity. The third group (Ozone) injected with a blend of 3 mL O₂/O₃ (15 μ g/mL) (Ozonibaric P® machine; Sedecal, Spain) and 2 mL of 0.25% Bupivacaine. Participants were instructed to stop running for no fewer than two weeks next to the therapy.

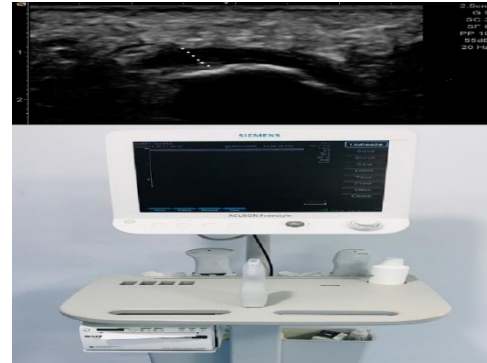

Figure 1: Ultrasound- guided measurement of plantar fascia thickness (white dots) and Acuson Freestyle Ultrasound System, Siemens .

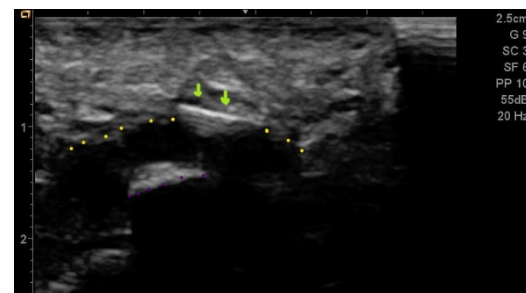


Figure 2: Ultrasound- guided Plantar fascia injection. yellow dots: plantar fascia, violet dots: calcaneus, green arrows: needle.

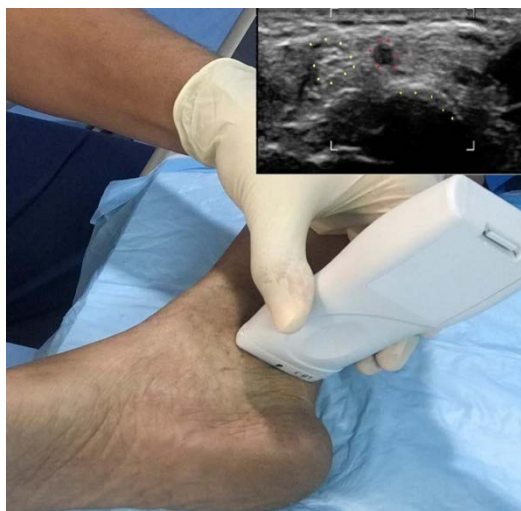

Figure 3: Ultrasound-guided posterior tibial nerve (PTN) block. yellow dots (PTN), red dots: posterior tibial artery, green dot: medial malleolus

This is a study of a continuous response variable from independent control and interventional participants with one control(s) for interventional ones. McMillan et al., in a similar study, found that the distribution of the response is normal within the study groups with a standard deviation of 0.2. Suppose the proper difference in the interventional and control means is 0.2^i . So, we would need to study 17 participants in each group to be able to reject the null hypothesis that the population means of the interventional and control groups are equal with probability (power) 0.8. The Type I error probability associated with this test of this null hypothesis is 0.05.

Statistical analysis:

Data entry and statistical analysis carried out using MedCalc ver. 18.11.3 (MedCalc, Belgium). Tests of significance (ANOVA, Kruskal-Wallis and Chi-square tests) were used.

Sample size calculation:

RESULTS

In the studied population, the average age of all patients was (38.11 ± 8) years.

Regarding the gender of the patients, the majority (60.8%) of patients were females; while (39.2%) were males. Regarding baseline (pre-injection) data;

The average BMI of all patients was (26.85 ± 3.8) ; the average duration of symptoms was (12.4 ± 2.47) months, the average VAS score was (7 ± 0.77) , the average FHSQ score was (49.11 ± 5.43) , and the average plantar fascia thickness was (5.92 ± 0.2) mm. Regarding short-term outcome data (1-month post-injection) data;

The average VAS score was (3.27 ± 1.5) , the average FHSQ score was (71 ± 12.6) , and the average plantar fascia thickness was (5.3 ± 0.4) mm. Regarding long-term outcome data (3-months post-injection) data; the average VAS score was (2.82 ± 1.3) ,

The average FHSQ score was (72.66 ± 10) , and the average plantar fascia thickness was (5 ± 0.43) mm. Regarding long-term outcome data (6-months post-injection) data; the average VAS score was (3.84 ± 1.89) , the average FHSQ score was (69.2 ± 14.2) , and the average plantar fascia thickness was (4.79 ± 0.54) mm.

Comparative studies: The 51 plantar fasciitis patients were classified according to outcomes into 4 independent groups: Control group "corticosteroid" (17 patients), Ozone group "O2-O3" (17 patients) and PRP group "PRP" (17 patients)

| | Control group (17) | Ozone Group (17) | PRP group (17) | ANOVA test |
|----------------------------------|--------------------------|------------------------|----------------------|---------------|
| | Mean \pm SD | Mean \pm SD | Mean \pm SD | P-value |
| Age (years) | 37.76 ± 7.1 | 36 ± 7.7 | 40.4 ± 8.9 | = 0.267 |
| BMI | 26.5 ± 3.4 | 26.2 ± 4.2 | 27.8 ± 3.7 | = 0.435 |
| Duration of symptoms (months) | 12.8 ± 2.6 | 12.4 ± 2.5 | 11.9 ± 2.3 | = 0.591 |
| VAS score ## Median (IQR) | 7 (7 – 8) | 7 (6.7 – 8) | 7 (6 – 7.2) | = 0.6523 |

| | | | | | |
|--------------------------------------|--------|--------------------|------------------|----------------|-----------------|
| FHSQ score | | 51.2 ± 6.3 | 47.7 ± 4.3 | 48.4 ± 5 | = 0.134 |
| Plantar fascia thickness (mm) | | 5.93 ± 0.21 | 5.9 ± 0.22 | 5.93 ± 0.17 | = 0.846 |
| | | Control group (17) | Ozone group (17) | PRP group (17) | Chi-square test |
| | | | | | P-value |
| Gender | Female | 10 (58.8%) | 11 (64.7%) | 10 (58.8%) | = 0.9210 |
| | Male | 7 (41.2%) | 6 (35.3%) | 7 (41.2%) | |

ANOVA: analysis of variance. * Percentage of Column Total. BMI: body mass index). FHSQ: foot health

Table 1: Comparison between the 3 groups as regards baseline (pre-injection) data using ANOVA and Chi-square tests:

| | | Control group (17) | Ozone group (17) | PRP group (17) | ANOVA test |
|-----------------|--------------------------|--------------------|------------------|----------------|------------|
| | | Mean ± SD | Mean ± SD | Mean ± SD | P-value |
| 1-month | VAS score | 2 (1 – 2.2) | 3 (2 – 3) | 5 (4 – 6) | < 0.01** |
| | FHSQ score | 79.88 ± 5.5 | 77.9 ± 5.1 | 55.3 ± 6.7 | < 0.01** |
| | Plantar fascia thickness | 5 ± 0.12 | 5.1 ± 0.22 | 5.78 ± 0.28 | < 0.01** |
| 3-months | VAS score | 1 (1 – 2) | 4 (3 – 5) | 3 (3 – 4) | < 0.01** |
| | FHSQ score | 84.88 ± 2.99 | 66.1 ± 5 | 67 ± 6.48 | < 0.01** |
| | Plantar fascia thickness | 4.6 ± 0.28 | 5.24 ± 0.27 | 5.3 ± 0.36 | < 0.01** |
| 6-months | VAS score | 4 (3 – 4) | 6 (6 – 6.2) | 2 (1 – 2) | < 0.01** |
| | FHSQ score | 77.3 ± 2.9 | 50 ± 4.5 | 80.3 ± 3.3 | < 0.01** |
| | Plantar fascia thickness | 4.42 ± 0.25 | 5.47 ± 0.2 | 4.48 ± 0.29 | < 0.01** |

Table 2: Comparison between the 3 groups as regards short and long-term outcome data (1, 3 and 6-months post-injection) using ANOVA test

1-month post-injection: Comparative study between the 3 groups revealed; a highly significant decrease in 1-month VAS score and plantar fascia thickness in corticosteroid and Ozone groups; compared to the PRP group (p < 0.01 respectively).

Comparative study between the 3 groups revealed; a highly significant increase in 1-month FHSQ score in corticosteroid and Ozone groups; compared to the PRP group (p < 0.01), Table (2); Figure (4).

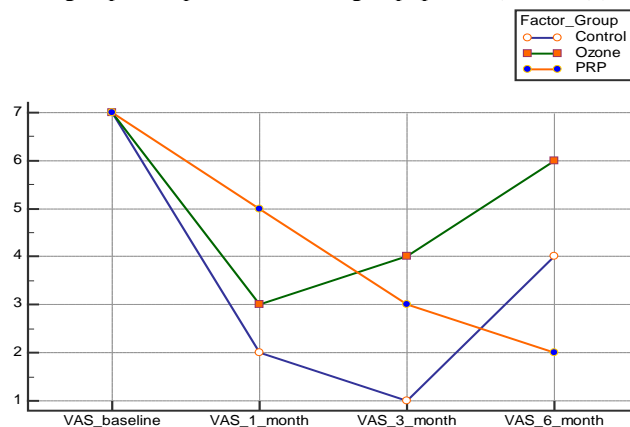


Figure 4: Comparison between the 3 groups of patients regarding serial VAS score assessments.

(3-month post-injection results): Comparative study between the 3 groups revealed; a highly significant decrease in 3-month VAS score and plantar fascia thickness in the corticosteroid group; compared to Ozone and PRP groups ($p < 0.01$ respectively).

Comparative study between the 3 groups revealed; a highly significant increase in 3-month FHSQ score in the corticosteroid group; compared to Ozone and PRP groups ($p < 0.01$), table (2); Figure (5).

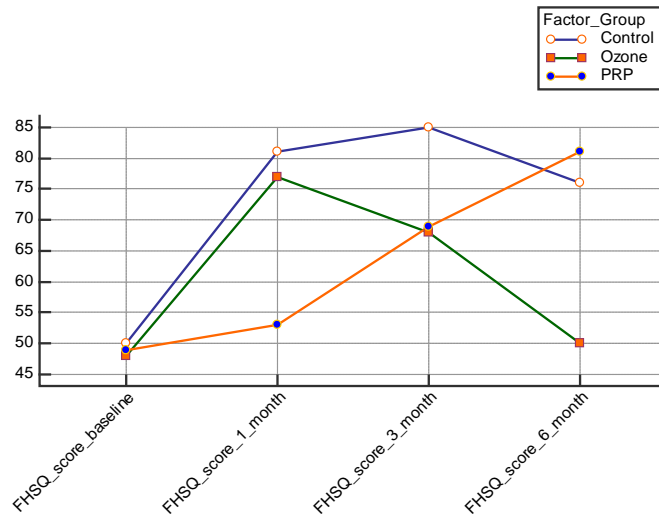


Figure 5: Comparison between the 3 groups of patients regarding serial FHSQ score assessments.

(6-month post-injection results): Comparative study between the 3 groups revealed; a highly significant decrease in 6-month VAS score and plantar fascia thickness in the PRP group; compared to corticosteroid and Ozone groups ($p < 0.01$

respectively). Comparative study between the 3 groups revealed; a highly significant increase in 6-month FHSQ score in the PRP group; compared to corticosteroid and Ozone groups ($p < 0.01$), table (2); Figure (6).

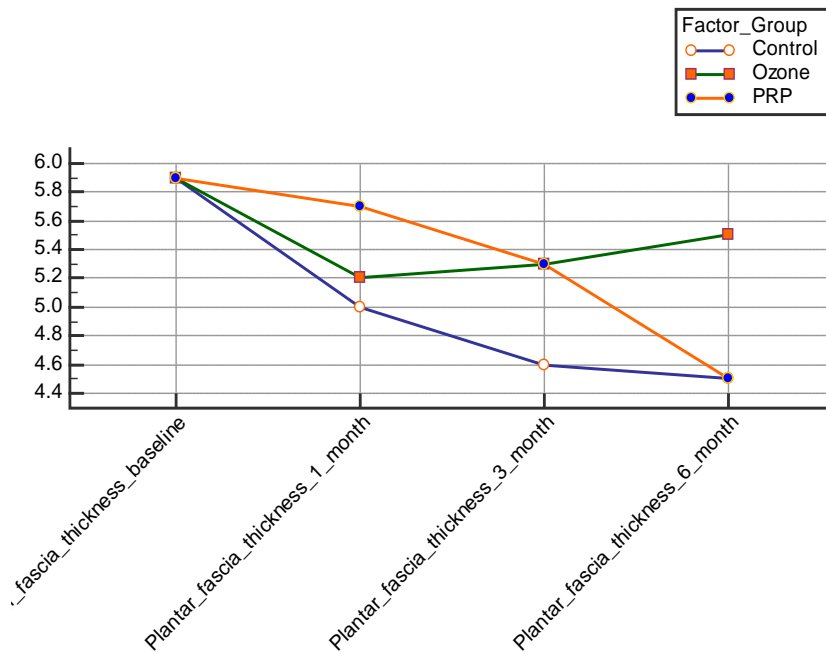


Figure 6: Comparison between the 3 groups of patients regarding serial plantar fascia thickness assessments.

DISCUSSION

Fifty-one plantar fasciitis patients were classified according to outcomes into three independent groups: Control group "corticosteroid" (17 patients), Ozone group "O₂-O₃" (17 patients), and PRP group "PRP" (17 patients).

In the studied population, the average age of all patients was (38.11 ± 8) years. Regarding the gender of the patients, the majority (60.8%) of patients were females and (39.2%) were males, which came in agreement with Johal et al., 2019ⁱⁱ, Babaei-Ghazani et al. and Bahrami et al.^{1&4}

Johal et al., reported that the study of PRP effect in different orthopaedic indications revealed 78 RCTs in the last 10 years, 60 RCTs (73%) have done after 2012. 47.9 years was the average age (range, 22.9-76 years) with a sample size ranges from 9 to 380 Patients and follow up duration from 5 days to 6 years post-treatment .10 RCTs studied this effect in Plantar fasciitis.⁸

Babaei-Ghazani et al., compared steroid and Ozone injection and reported that 52 (83.9%) patients were female and 10 (16.1%) were males with an average age was 57.9 ± 9.2 years⁴. Also, Bahrami et al., 2019 reported that (65.9%) of their study were females (29 patients) in the agreement of this study and almost similar average age 47±9.0 years.¹

Regarding 1-month results, a comparative study between the 3 groups revealed; a highly significant decrease in 1-month VAS score and plantar fascia thickness in corticosteroid and Ozone groups; compared to the PRP group (p < 0.01 respectively), which came in agreement with Bahrami et al., 2019.¹

Bahrami et al., reported that, in a similar pattern, that CS group exhibited a highly substantial difference regarding PPT (p=0.019 and p=0.003, respectively) and VAS (p<0.001, and p=0.035, respectively) at the first week and month after injection as opposed to ozone group.¹

Regarding 3-month results, a comparative study between the 3 groups revealed; a highly significant decrease in 3-month VAS score and plantar fascia thickness in the corticosteroid group; compared to Ozone and PRP groups (p < 0.01 respectively), which came in agreement with Raeissadat et al, Babaei-Ghazani et al and Bahrami et al., 2019.^{1,4&5}

Raeissadat et al., reported that HA group displayed significant difference regarding the ultrasonographic measurement of the fascial thickness (P <0.001) and PPT (P <0.001) than done in CS group after 6-weeks of the injection.⁵

Babaei-Ghazani et al., 2018 reported that steroid injection improved the VAS score at 1 week and 1 month in comparison to the baseline. Nevertheless,

the VAS score got higher again at 3 months as compared to the results of 1 month (P=0.008) (worsening of pain)⁴. Bahrami et al., 2019 reported that both groups were comparable as regards to VAS score changes (about 58%) in 3-month follow-up (p=0.890).¹

Comparative study between the 3 groups revealed; a highly significant increase in 3-month FHSQ score in the steroid group Versus O₂/O₃ and PRP groups (p < 0.01), which came in agreement with Raeissadat et al., and Barile et al.⁸

Raeissadat et al., reported that CS injection is widely used due to its rapid pain relief; however, recent literature proved that spontaneous rupture of fascia in athletes could occur after this injection⁵. Barile et al., reported that there was a marked pain reduction after 1 week.⁸

Regarding 6-month results, a comparative study between the 3 groups revealed; a highly significant decrease in 6-month VAS score and plantar fascia thickness in the PRP group; compared to corticosteroid and Ozone groups (p < 0.01 respectively)⁹, which came in agreement with Anz et al.¹⁰

Anz et al., reported that PRP injection had a significant reduction of VAS at six months compared to hyaluronic acid (HA) in hip OA. However, they were comparable regarding the functional recovery as proved by Meta-analysis results of a randomized clinical trial¹⁰. Comparative study between the three groups revealed; a highly significant increase in 6-month FHSQ score in the PRP group; compared to corticosteroid and Ozone groups (p < 0.01), which came in agreement with Anz et al., Raeissadat et al, Johal et al., , and Le et al.^{5,8,10&11}

Filardo et al., Gobbi et al., Kon et al. and others reported that there was a short-term improvement in pain score, function and quality of life for a period ranging from two months to twelve months after the PRP therapy followed by regression of that level but still higher than the baseline. However, a long period of improvement (18 months) demanded a repetition of injection year after year. Also, they showed that the results were better in younger patients than the older ones (above -80-years) as PRP proved to induce anti-ageing mechanism, decrease the pain and enhance the functional status regardless the level of cartilage affection as verified by MRI.^{12,13&14}

Raeissadat et al., reported that the fast and short-term improvement of plantar fasciopathy pain was achieved by corticosteroid. Nevertheless, hyaluronic acid and CS had the same effect in 6- months follow-up.⁵

Johal et al., reported that the overall analysis across all indications demonstrated a statically but not clinically significant reduction in pain with PRP compared with controls at three months. This effect grew at six months and one year. However, the CIs

overlapped the 0.5 effect size threshold for a clinically meaningful difference⁸.

Le et al., mentioned that PRP could be an excellent substitute to corticosteroid as regards to the effectiveness as finalized by two meta-analyses studied the PRP versus the steroid injection in the management of plantar fasciitis¹¹.

CONCLUSION

To conclude, corticosteroid and Ozone injections were effective at short-term assessment, but PRP was more valuable at long-term assessment regarding pain management in plantar fasciitis patients.

REFERENCES

1. Bahrami MH, Raeissadat SA, Barchinejad M, Elyaspour D, Rahimi-Dehgolan S. Local ozone (O₂-O₃) versus corticosteroid injection efficacy in plantar fasciitis treatment: a double-blinded RCT. *Journal of Pain Research* 2019;12:2251.
2. Lehn A. Platelet-rich plasma in tissue engineering. *Biomaterials for Organ and Tissue Regeneration*, Elsevier; 2020, p. 477–496.
3. Le AD, Enweze L, DeBaun MR, Dragoo JL. Platelet-rich plasma. *Clinics in Sports Medicine* 2019;38:17–44
4. Babaei-Ghazani A, Najarzadeh S, Mansoori K, Forogh B, Madani SP, Ebadi S, et al. The effects of ultrasound-guided corticosteroid injection compared to oxygen-ozone (O₂-O₃) injection in patients with knee osteoarthritis: a randomized controlled trial. *Clinical Rheumatology* 2018;37:2517–2527.
5. Raeissadat SA, Nouri F, Darvish M, Esmaily H, Ghazihosseini P. Ultrasound-Guided Injection of High Molecular Weight Hyaluronic Acid versus Corticosteroid in Management of Plantar Fasciitis: A 24-Week Randomized Clinical Trial. *Journal of Pain Research* 2020;13:109.
6. Riskowski JL, Hagedorn TJ, Hannan MT: Measures of foot function, foot health, and foot pain. *Arthritis Care Res* 2011, 63: S229-S239. 10.1002/acr.20554F
7. McMillan AM, Landorf KB, Gilheany MF, Bird AR, Morrow AD, Menz HB. Ultrasound guided corticosteroid injection for plantar fasciitis: randomised controlled trial. *BMj* 2012;344.
8. Johal H, Khan M, Yung SP, Dhillon MS, Fu FH, Bedi A, et al. Impact of platelet-rich plasma use on pain in orthopaedic surgery: a systematic review and meta-analysis. *Sports Health* 2019;11:355–366.
9. Barile A, La Marra A, Arrigoni F, Mariani S, Zugaro L, Splendiani A, et al. Anaesthetics, steroids and platelet-rich plasma (PRP) in ultrasound-guided musculoskeletal procedures. *The British Journal of Radiology* 2016;89:20150355.
10. Anz HA, Ahmad HA, Kozemchak AM, Rao M, Warth RJ, Harner CD. Funding sources are under-reported in randomized clinical trials of biological treatments in sports medicine: a systematic review. *Journal of ISAKOS: Joint Disorders & Orthopaedic Sports Medicine* 2020.
11. Le AD, Enweze L, DeBaun MR, Dragoo JL. Current clinical recommendations for use of platelet-rich plasma. *Current Reviews in Musculoskeletal Medicine* 2018;11:624–634
12. Filardo G., Kon E., Buda R., Timoncini A., Di Martino A., Cenacchi A., Fornasari P.M., Giannini S., Marcacci M. Platelet-rich plasma intra-articular knee injections for the treatment of degenerative cartilage lesions and osteoarthritis. *Knee Surg. Sports Traumatol. Arthrosc.* 2011;19:528–535. doi: 10.1007/s00167-010-1238-6.
13. Gobbi, A.; Karnatzikos, G.; Mahajan, V.; Malchira, S. Platelet-rich plasma treatment in symptomatic patients with knee osteoarthritis: Preliminary results in a group of active patients. *Sports Health* 2012,4, 162–172.
14. Kon, E.; Buda, R.; Filardo, G.; Di Martino, A.; Timoncini, A.; Cenacchi, A.; Fornasari, P.M.; Giannini, S.; Marcacci, M. Platelet-rich plasma: Intra-articular knee injections produced favorable results on degenerative cartilage lesions. *Knee Surg. Sports Traumatol. Arthrosc.* 2010,18, 472–479.