



Evaluation of 3D Printed Computer Assisted Patient's Specific Scaffold Seeded by Autologous Bone Marrow Mononuclear Cells in Mandibular Reconstruction

Wafaa A. Mohammed^{1*}, Susan A.Hassan², Hatem H. ALahmady³, Wael M. Shawkat ⁴, Ahmad F. Abd Elazeem⁵, Ibrahim M. ELsharabasy⁶, Ismail O. Nazif⁷.

Codex : 14/21.01

azhardentj@azhar.edu.eg

http://adjg.journals.ekb.eg

DOI: 10.21608/adjg.2021.23389.1237

Oral Medicine & Surgical Sciences
(Oral Medicine, Oral & Maxillofacial
Surgery, Oral Pathology, Oral Biology)

ABSTRACT

Purpose: This study was carried out to evaluate both clinically and radiographically the use of 3D printed computer assisted patient's specific scaffold seeded with ABMMCs in mandibular reconstruction. **Materials and methods:** The present study was conducted on eight patients who needed mandibular reconstruction. All patients in this study were subjected to mandibular reconstruction using 3D printed computer assisted patients specific scaffold using PLLA scaffold seeded with ABMMCs combined with osteoplastic materials of biological origin as Osteomatrix (LLC Konectbiopharm, Russia) which composed of natural collagen and hydroxyapatite with affinity-bound sulfated glycosaminoglycan (SGAG). All patients underwent preoperative cranial-maxillofacial CT scans, immediate postoperative and after six months for assessment of bone density and volume changes. **Results:** The reduction in bone density (17.4%) and bone volume (14.5%) from immediate to six months was statistically significant. There was an increase in bone density in the area near the autogenous bone of the patient than the area far from the autogenous bone of the patient. **Conclusion:** Using 3D printed computer assisted patient's specific scaffold seeded with ABMMCs combined with Osteoplastic materials of biological origin in mandibular reconstruction is useful in small defects.

KEYWORDS

*Mandibular reconstruction,
Poly (L-lactide) lactic acid,
3D printed.*

- Paper extracted from master Thesis titled "Evaluation of 3D Printed Computer Assisted Patient's Specific Scaffold Seeded by Autologous Bone Marrow Mononuclear Cells in Mandibular Reconstruction"
- 1. Demonstrator of Oral and Maxillofacial Surgery, Faculty of Dental Medicine for Girls, Al-Azhar University, Cairo, Egypt.
- 2. Professor of Oral and Maxillofacial Surgery, Faculty of Dental Medicine for Girls, Al-Azhar University, Cairo, Egypt.
- 3. Professor of Oral and Maxillofacial Surgery and Head of Department, Faculty of Dental Medicine for Girls, Al-Azhar University, Cairo, Egypt.
- 4. Head of Oral and Maxillofacial Surgery Department, Health insurance hospital, Cairo, Egypt.
- 5. Assistant researcher of regenerative medicine and genetics, Oro-dental Genetics Department, Human Genetics Division National Research Center, Cairo, Egypt.
- 6. Consultant Oral and Craniomaxillofacial Surgery
- 7. Electrical and Medical 3D Printing Engineer.

* Corresponding author email: wafaaanwar89@yahoo.com

INTRODUCTION

Mandibular bone defect is a common problem encountered secondary to tumor, trauma, and atrophy⁽¹⁾. Reconstruction of mandibular defects is a difficult and challenging problem and aims to maintain the best possible function and esthetic outcomes^(2,3,4).

Mandibular defects are reconstructed either by using bone grafting or artificial materials. Several methods have been described for mandibular reconstruction which include (alloplastic biocompatible plates, free bone grafts, pedicled bone grafts, particulate cancellous bone marrow grafts, micro vascular free tissues transfer, distraction osteogenesis, bone graft substitutes alone or the combination of two or more of these techniques⁽⁵⁾). Alloplastic reconstruction plates have disadvantages for reconstruction of mandibular bone especially in the anterior aspect of the mandible due to insufficient support to the overlying soft tissues, which leads to poor esthetic outcomes⁽¹⁾.

Autogenous bone grafts are characterized by osteogenic, osteoinductive, and osteoconductive properties, but have several drawbacks, including the need of bone harvesting, prolonged surgical times, and increased biological costs and postoperative morbidity for the patient⁽⁶⁾. The allograft is not considered an "ideal" option for bone reconstruction due to their lack of osteogenic capacity, the risk of triggering host immune response and the risk of transmission of infectious agents. To overcome these shortcomings in bone grafts, scientists used the traditional triad of tissue engineering that include sufficient osteocompetent cell transfer, scaffold that maintains space and provides osteoconduction, and the application of growth factors that can induce adjacent mesenchymal osteogenesis to develop a bone construct⁽⁷⁾.

Bone tissue engineering aims to regenerate osseous tissue using a combination of stem cells, biomaterials and bioactive molecules⁽⁸⁾. Friedenstein et al first identified mesenchymal stem cells in bone

marrow of human⁽⁹⁾. In bone tissue engineering, the bone marrow stem cells are the most widely-used seed cells, with a multiple advantages as minimal damage to the donor, and good adhesion to a biological scaffold⁽¹⁰⁾.

Regeneration of large volumes of bone needs bone active proteins and drugs that are provide cells with sufficient stimulus. Simvastatin is one of the most popular prescribed drugs for the treatment of hypercholesterolemia as it prevents the synthesis of cholesterol. It can modulate the process of bone regeneration by election of pleiotropic effects at the molecular and cellular levels⁽¹¹⁾.

Different materials of biological origin are developed by tissue engineering as substitutes for autologous bone⁽¹²⁾. The ideal 3D scaffold is composed of a biodegradable, biocompatible materials that have mechanical properties similar to the tissue which it is to be implanted in to support cell adhesion, proliferation and differentiation⁽¹³⁾.

The use of technology of 3-D printing in medicine has grown from diagnosis of diseases and educational models for teaching, to medical devices and surgical applications for patient specific needs⁽¹⁴⁾. The 3D printing technology depended on imaging of computed tomography (CT) and magnetic resonance imaging (MRI), the 3D images of the bones can be reconstructed, according to the anatomy of human, and the software used can mimic the 3D images of the bones of the missing parts, therefore customized manufactured bone prostheses can be implanted into human body. Using specialized 3D printing technology custom scaffolds for bone repair can be constructed⁽¹⁵⁾.

The area of tissues engineering that has received the most attention for the craniomaxillofacial region is bone regeneration depending on cellular techniques, replacement of biomaterials, or using of signaling molecule. This study was conducted to investigate the application of 3D printed patient's specific scaffold in regeneration of mandibular bony defect.

SUBJECTS AND METHODS

This study included eight patients who needed reconstruction of mandibular bone. They were selected from the Outpatient Clinic of the Oral and Maxillofacial Surgery Department, Faculty of Dental Medicine for Girls, Al-Azhar University and from El Zahraa University Hospital. This study was approved by the ethical committee of the Faculty of Dental Medicine for Girls, Al-Azhar University. Indications, goals of treatment, risks and benefits associated with this treatment were explained to all patients. A written informed consent was obtained from all the patients. Patients suffering from active infections, immunosuppression, metastatic disease, malignant tumor and had other systemic conditions associated with bone health like hyperparathyroidism were excluded from this study.

Patient Management Protocol:

All patients were subjected to clinical and radiographic examination, clinical examination include general examination, extraoral examination and intraoral examination. During the history taking, note any facial asymmetries, lesions or scars. Radiographic examination, Preoperative orthopantomogram (OPGs) and multislice CT scans were taken for all the patients: For the assessment of size, shape of the defect and to evaluate the reconstruction plate (in case of delayed reconstruction), CT scans with a slice thickness of 0.5 mm were used to establish treatment plan and for construction of the patient's specific scaffold and surgical models for pre adaptation of reconstruction plates. Immediate postoperative multislice CT scans and postoperative multislice CT scans were taken after 6 months for all the patients to evaluate bone density and volume.

Surgical Procedure:

All the patients enrolled in the present study were operated on at AL Zahraa University Hospital. After admission, lab investigation, and anesthesiology

consultations were done. Preoperative instruction were given at the day before surgery. At the day of surgery patients were brought to the operating theater. Intra and extra oral antiseptic procedures and draping were done.

Marking the incision and subcutaneous injection of vasoconstrictor adrenaline (1ampoule/200ml saline) for hemostasis. Submandibular incision was done (skin, subcutaneous tissues) to the level of the platysma muscle and undermining the skin with scissor dissection to facilitate closure. The platysma muscle was then undermined with the scissors deep to the muscle and the scalpel was used to incise the muscle from one end of the skin incision to the other. Dissection was done through superficial layer of deep cervical fascia with care to preserve the facial artery and vein. Exposure of resected area of the mandible and refreshment of the edges.

Seeding the cells on the scaffold: The isolated bone marrow mononuclear cells were seeded on synthetic bone Block with a 5ml syringe with a gauge 14 needle obtained from a cannula set. The PLLA scaffolds were packed into the mandibular defect and fixed by ligature wires to the reconstruction plate (Fig. 1).

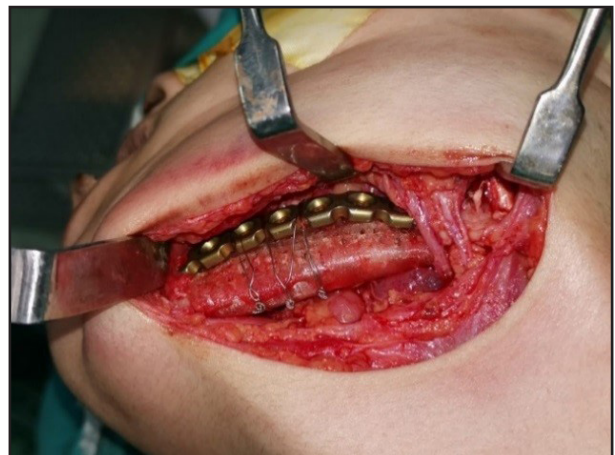


Figure (1): A photograph showing reconstruction of mandible by PLLA scaffold and fixation with ligature wires.

Assessment of bone volume:

After multislice CT scans were done immediate and after 6 months, The DICOM files were imported to Medical 19.0 software (Materialise NV, Leuven, Belgium) and calculation of 3D to compare the volumetric changes.

Assessment of bone density:

After the multislice CT scans were done. The DICOM files were imported to software (OnDemand-3DApp) for fusion of all cuts (axial, coronal, and sagittal). Assessment of bone density was carried out: immediate postoperative and after 6 months.

RESULTS

Clinical Evaluation

The present study showed no infection, wound dehiscence, pus formation and graft exposure. However, Post-operative edema continued until six months postoperative in seven cases. One case suffered from severe extra oral swelling with pus

formation and wound dehiscence due to history of exposure to trauma on the side of grafting.

Radiographic Evaluation:

Bone Density

The bone density measured immediately after surgery was higher than after 6 months with mean of 666.3(61.4) vs 550.4(80.3) respectively (Table 1). The difference between immediate and after 6 months bone density was statistically significant (p<0.01)

Bone volume

The bone volume measured immediately after surgery was higher than after 6 months with mean of 4488.5(526.3) vs 3836.7(442.3) (Table 1). The difference between immediate and after 6 months bone volume is statistically significant (p<0.01). The difference between immediate and after 6 months either in bone density or in bone volume is considered statistically significant (p<0.01) (Fig. 2)

Table (1): Comparison between the immediate and after 6 months responses after reconstruction among studied patients according to bone density and bone volume:

Variable	Immediate Mean±SD	After 6 months Mean±SD	Mean difference (percent change)	Paired t test	P value
Bone density	666.3±61.4	550.4±80.3	-115.9 (17.4%)	4.237	0.005**
Bone volume	4488.5±526.3	3836.7±442.3	-651.8 (14.5%)	5.575	0.001**

**statistically highly difference p<0.01

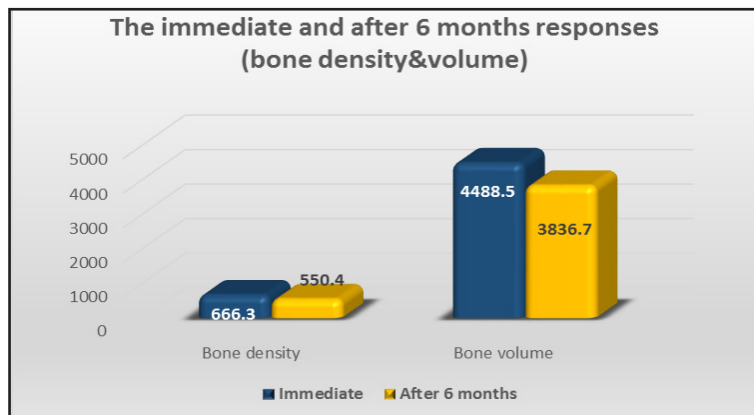


Figure (2): A bar chart showing the mean values of bone density and bone volume comparing between immediate and after 6 months.

DISCUSSION

Reconstruction of mandibular defects represent a difficult and challenging problem. Different techniques for reconstruction of critical size defects of bony of the mandible include autologous bone grafts, vascularized bone grafts, and vascularized free flaps. But these techniques have some disadvantages as donor-site morbidity and more time to shape the graft to the complex 3D defect configuration⁽¹⁶⁾.

Currently, bone tissue engineering has tremendous advantage in mandibular reconstruction as an alternative bone source⁽¹⁷⁾. In this study, patient's specific PLLA scaffold was used. PLLA has been widely used for bone regeneration as it is a biodegradable and biocompatible but, there were several aspects of PLLA that remain problematic with respect to its application in biomedical fields, including hydrophobicity, lack of bioactivity, and may cause inflammation due to release of acidic degradation by-products when implanted in vivo⁽¹⁸⁾.

The present study has shown that the inflammatory reaction occurred in the form of swelling in all cases, only one case suffered from the presence of infection and pus formation but this patient had a history of exposure to trauma after surgery, this is in agreement with the study that reported that non-specific foreign-body reactive swelling was observed during PLLA degradation 3–5 years after fixation of zygomatic fracture with PLLA plates⁽¹⁹⁾. On the other side, another study showed that no delayed swelling was observed in any patient after using a poly (L-lactide) mesh combined with autogenous particulate cancellous bone and marrow in mandibular reconstruction. This could be attributed to the larger contact area between the tissue and the surface of the PLLA mesh compared to the PLLA plate, which would maintain the balance between fragmentation and absorption of the mesh by the surrounding tissue⁽²⁰⁾. Another study reported that no complications including (infection, swelling, nonunion, malunion) occurred after fixation of zy-

gomatic fractures by using thin flat-type bioresorbable plate system composed of a monopolymer of PLLA⁽²¹⁾.

In the current study, mandibular reconstruction using PLLA scaffold seeded with ABBMCs combined with osteoplastic materials of biological origin and simvastatin as osteoinductive material was evaluated clinically and radio graphically.

Clinically; this technique provides excellent adaptation to the recipient site, easy application of the graft, excellent restoration of the esthetic curve of the mandible, reducing the surgery time as not need two teams and postoperative complications related to donor sites as the conventional bone graft harvest approach but, there were signs of inflammatory reaction in all cases as discussed before. Radiographically; bone density and volumetric difference that significantly decreased from immediate to six months postoperative, the bone density measured immediately after surgery was higher than that measured after 6 months with mean of 666.3 ± 61.4 vs 550.4 ± 803 respectively and the bone volume measured immediately after surgery was higher than that measured after 6 months with mean of 4488.5 ± 526.3 vs 3836.7 ± 442.3 .

There was a reduction in bone density by 17.4% and bone volume by 14.5% which is similar to the normal bone remodeling process. Some authors found that the bone density is at its lowest level within 6 months postoperatively after non-vascularized iliac bone grafting and new bone formation is latent due to active bone resorption and remodeling according to the theory of creeping substitution, which is characterized by the initial resorption of bone grafts, followed by bone regeneration⁽²²⁾. Histologic and histomorphometric analysis of regeneration of bone with bovine grafting material have reported that ABBMM presents a markedly faster resorption in the initial period (3/6 months) after graft insertion⁽²³⁾. Bone remodeling was very active in all grafts⁽²⁴⁾. Other authors reported that a volume reduction of the initial augmented a

xenogeneic bone substitute material in split-mouth sinus augmentations after six months while, the bone density increased significantly and reached higher values than the referenced zygomatic bone⁽²⁵⁾.

In the present study, the bone density of the graft was 550.4 ± 80.3 after 6 months, and classified as D3 (350–850 HU) according to Misch classification (D1, D2, D3, and D4) based on Hounsfield units (HU). D1 (>1250 HU) is dense cortical bone; D2 (850–1250 HU) is thick, porous cortical bone with coarse trabeculae; D3 (350–850 HU) is thin, porous cortical bone with fine trabeculae; and D4 (150–350 HU) is fine trabecular bone⁽²⁶⁾.

CONCLUSION

Within the limitations and findings of the present study it could be concluded that: clinical application of tissue engineering in bone reconstruction using 3D printed computer assisted patients specific scaffold seeded with autologous bone marrow mononuclear cells combined with Osteomatrix in mandibular reconstruction is useful in small defects.

REFERENCES

1. Torroni A, Marianetti TM, Romandini M, Gasparini G, Cervelli D, Pelo S. Mandibular reconstruction with different techniques. *J Craniofac Surg*. 2015; 26: 885–90.
2. Bao T, He J, Yu C, Zhao W, Lin Y, Wang H, et al. Utilization of a pre-bent plate-positioning surgical guide system in precise mandibular reconstruction with a free fibula flap. *Oral Oncol*. 2017; 75: 133–9.
3. Yu Y, Zhang WB, Liu XJ, Guo C Bin, Yu GY, Peng X. Three-dimensional accuracy of virtual planning and surgical navigation for mandibular reconstruction with free fibula flap. *J Oral Maxillofac Surg*. 2016; 74:1–10.
4. Kumar BP, Venkatesh V, Kumar KAJ, Yadav BY, Mohan SR. Mandibular Reconstruction: Overview. *J Maxillofac Oral Surg*. 2016; 15: 425–41.
5. Zamiri B, Shahidi S, Eslaminejad MB, Khoshzaban A, Gholami M, Bahramnejad E, et al. Reconstruction of human mandibular continuity defects with allogenic scaffold and autologous marrow mesenchymal stem cells. *J Craniofac Surg*. 2013; 24: 1292–7.
6. Dellavia C, Giammattei M, Carmagnola D, Musto F, Canciani E, Chiapasco M. Iliac crest fresh-frozen allografts versus autografts in oral pre-prosthetic bone reconstructive surgery: histologic and histomorphometric Study. *Implant Dent*. 2016; 25: 731–38.
7. Liu CK, Tan XY, Luo JC, Liu HW, Hu M, Yue W. Reconstruction of beagle hemi-mandibular defects with allogenic mandibular scaffolds and autologous mesenchymal stem cells. *PLoS One*. 2014; 9:1–8.
8. Manimaran K, Sharma R, Sankaranarayanan S, Perumal Sm. Regeneration of mandibular ameloblastoma defect with the help of autologous dental pulp stem cells and buccal pad of fat stromal vascular fraction. *Ann Maxillofac Surg*. 2016; 6: 97–100.
9. Ansari S, Seagroves JT, Chen C, Shah K, Aghaloo T, Wu BM, et al. Dental and orofacial mesenchymal stem cells in craniofacial regeneration: The prosthodontist's point of view. *J Prosthet Dent*. 2017; 118: 455–61.
10. Yan X, Zhou Z, Guo L, Zeng Z, Guo Z, Shao Q, et al. BMP7-overexpressing bone marrow-derived mesenchymal stem cells (BMSCs) are more effective than wild-type BMSCs in healing fractures. *Exp Ther Med*. 2018; 16: 1381–8.
11. Montero J, Manzano G, Albaladejo A. The role of topical simvastatin on bone regeneration: A systematic review. *J Clin Exp Dent*. 2014; 6: 286–90.
12. Zhang L, Yang G, Johnson BN, Jia X. Three-dimensional (3D) printed scaffold and material selection for bone repair. *Acta Biomater*. 2019; 84:16–33.
13. Gallego L, Pérez-Basterrechea M, García-Consuegra L, Álvarez-Viejo M, Megías J, Novoa A, et al. Repair of segmental mandibular bone defects in sheep using bone marrow stromal cells and autologous serum scaffold: A pilot study. *J Clin Periodontol*. 2015; 42: 1143–51.
14. Ghai S, Sharma Y, Jain N, Satpathy M, Pillai AK. Use of 3-D printing technologies in craniomaxillofacial surgery: a review. *Oral Maxillofac Surg*. 2018; 22: 249–59.
15. Ishack S, Mediero A, Wilder T, Ricci JL, Cronstein BN. Bone regeneration in critical bone defects using three-dimensionally printed β -tricalcium phosphate/hydroxyapatite scaffolds is enhanced by coating scaffolds with either dipyrindamole or BMP-2. *J Biomed Mater Res - Part B Appl Biomater*. 2017; 105: 366–75.
16. Ahn G, Lee JS, Yun WS, Shim JH, Lee UL. Cleft alveolus reconstruction using a three-dimensional printed bioresorbable scaffold with human bone marrow cells. *J Craniofac Surg*. 2018; 29: 1880–3.

17. Chanchareonsook N, Junker R, Jongpaiboonkit L, Jansen JA. Tissue-engineered mandibular bone reconstruction for continuity defects: A systematic approach to the literature. *Tissue Eng - Part B Rev.* 2014; 20: 147–62.
18. Ceonzo K, Gaynor A, Shaffer L, Kojima K, Vacanti CA, Stahl GL. Polyglycolic acid-induced inflammation: Role of hydrolysis and resulting complement activation. *Tissue Eng.* 2006; 12: 301–8.
19. Bergsma JE, de Bruijn WC, Rozema FR, Bos RR, Boering G. Late degradation tissue response to poly (L-lactide) bone plates and screws. *Biomaterials* 1995; 16:25–31.
20. Yagihara K, Okabe S, Ishii J, Amagasa T, Yamashiro M, Yamaguchi S, et al. Mandibular reconstruction using a poly (l-lactide) mesh combined with autogenous particulate cancellous bone and marrow: A prospective clinical study. *Int J Oral Maxillofac Surg.* 2013; 42: 962–9.
21. Sukegawa S, Kanno T, Nagano D, Shibata A, Sukegawa-Takahashi Y, Furuki Y. The clinical feasibility of newly developed thin flat-type bioresorbable osteosynthesis devices for the internal fixation of zygomatic fractures: Is there a difference in healing between bioresorbable materials and titanium osteosynthesis? *J Craniofac Surg.* 2016; 27: 2124–9.
22. Pan Jin, Zhang Yi, Yu Guang Yan. Bone density of non-vascularised iliac bone grafts in mandibular reconstruction: long-term evaluation. *Asian J Oral Maxillofac Surg* 2003; 15:162-70.
23. Guarnieri R, Belleggia F, DeVillier P, Testarelli L. Histologic and histomorphometric analysis of bone regeneration with bovine grafting material after 24 months of healing. A case report. *J Funct Biomater.* 2018; 9: 1-11.
24. Tadjoedin ES, De Lange GL, Bronckers ALJJ, Lyaruu DM, Burger EH. Deproteinized cancellous bovine bone (Bio-Oss®) as bone substitute for sinus floor elevation. A retrospective, histomorphometrical study of five cases. *J Clin Periodontol.* 2003; 30: 261–70.
25. Lorenz J, Eichler K, Barbeck M, Lerner H, Stübinger S, Seipel C, et al. Volumetric analysis of bone substitute material performance within the human sinus cavity of former head and neck cancer patients: A prospective, randomized clinical trial. *Ann Maxillofac Surg.* 2016; 6: 175-81.
26. Yavuz MS, Buyukkurt MC, Tozoglu S, Dagsuyu IM, Kantarci M. Evaluation of volumetry and density of mandibular symphysis bone grafts by three-dimensional computed tomography. *Dent Traumatol.* 2009; 25: 475-9.