



Effect of Simultaneous Vomerine Flap and Lip Repair on the Palatal Dimensions in Unilateral Complete Cleft Lip and Palate Patients

Nesma M Abd El Fattah^{1*}, Susan A.Hassan², Emad H Elsayed³, Nahed A Abd El Moniem⁴

Codex : 13/21.01

azhardentj@azhar.edu.eg

http://adjg.journals.ekb.eg

DOI: 10.21608/adjg.2021.23218.1228

Oral Medicine & Surgical Sciences
(Oral Medicine, Oral & Maxillofacial
Surgery, Oral Pathology, Oral Biology)

ABSTRACT

Purpose: to evaluate the effect of simultaneous vomerine flap and lip repair on the palatal dimensions in unilateral complete cleft lip and palate patients. **Patients and Method:** this study included 12 patients complaining of primary unilateral complete cleft lip and palate. They were classified randomly into two groups: Group I: included 6 cases, in which simultaneous cleft lip and hard palate repair was done using single layer vomerine flap. Group II: included 6 cases, in which separate repair of cleft lip and hard palate was done. Syndromic patients and patients with previous trial of repair were excluded. **Results:** showed reduction in A-A` alveolar cleft width and C-C` anterior palatal width occurred in both groups, while E-E` posterior palatal width increased in group 1 and decreased in group2 and the reverse occurred in BZ antro-posterior palatal width. **Conclusion:** Vomer flap is an easy, safe technique, with less time consuming and provides complete healing with less fistula formation.

INTRODUCTION

Cleft lip and palate patients are complaining of both functional and aesthetic problems. We are focusing on two areas in treatment plan: facial growth and speech improvement. The problems of cleft repair are timing of surgical intervention, the effects of surgery on facial growth, and speech development after various surgical procedures. The major aims of surgical repair are normal speech, minimizing

KEYWORDS

Vomer flap,
Cleft lip and palate,
palatal dimensions.

- Paper extracted from Master Thesis titled “Effect of Simultaneous Vomerine Flap and Lip Repair on The palatal dimensions in unilateral Complete Cleft Lip and Palate Patients”
- 1. Demonstrator of Oral and Maxillofacial Surgery, Faculty of Dental Medicine for Girls, Al-Azhar University, Cairo, Egypt.
- 2. Professor of Oral and Maxillofacial Surgery, Faculty of Dental Medicine for Girls, Al-Azhar University, Cairo, Egypt.
- 3. Assistant Professor at Plastic and Reconstructive Surgery Department, Faculty of Medicine for Girls, Al-Azhar University, Cairo, Egypt.
- 4. Lecturer of Oral and Maxillofacial Surgery, Faculty of Dental Medicine for Girls, Al-Azhar University, Cairo, Egypt.

* Corresponding author email: neamaabdefatah.26@azhar.edu.eg

growth disturbances, and establishing a competent velopharyngeal sphincter⁽¹⁾.

Pichler 1934 used a single-layer cranial-based vomerine mucoperiosteum flap and mucoperichondrium of nasal septal in repairing the hard palate, which placed under the oral mucoperiosteum margin on the opposite side of the cleft, the raw surfaces of the nasal septum and the flap healed by epithelialization with minimal dissection of palatal mucoperiosteum⁽²⁾.

Using a vomerine flap for palatal repair minimizes the need for releasing incisions at the time of palatal repair and minimizes area of bare bone of palatal; it also provides tissue for a closure without tension⁽³⁾.

The surgical intervention causing scar tissue formation in the palatal area with the other surgical techniques creates a rigid fibrous region that would impair the separation of the maxillary bones required for maxilla development. The vomer flap has excellent outcomes for craniofacial morphology due to limited elevation of the mucoperiosteal flap of the hard palate and the reduction of the exposed area of palate that needs to heal. Vomer flap is simple and easy procedure, with minimal surgical trauma and surgical time. The vomer flap is very similar to the nasal mucosa in quality. The flap has good vascularity⁽⁴⁾.

PATIENTS AND METHODS

The present study was conducted on 9 patients aged 1-9 months old with mean age 4.0 ± 2.1 . These patients were selected from those attending at Oral and Maxillofacial Surgery clinic, Faculty of Dental Medicine for Girls, Al Azhar University, Plastic and Reconstructive Surgery clinic, Al Zahraa hospital, Cleft lip and palate center, Faculty of Dental Medicine for Girls. This study was approved from the Ethical Committee of the Faculty of Dental Medicine for Girls, Al-Azhar University. The selected patients fulfilled the following criteria: non syndromic patients with unilateral complete cleft

lip and palate. No history of previous trial of cleft repair.

Study groups: The patients randomly divided into two groups: Group I: Included 6 cases, in which lip was repaired were palate was repaired, and Group II: Included 6 cases, in which lip was repaired in 1st operation and after 6 months palate was repaired. 3 cases were excluded as they didn't come back for follow up so our statistical analysis was done on 9 patients. A total of 6 patients were males and 3 were females.

Surgical protocol: Endotracheal tube was inserted orally centrally; patient was placed supine on the table with extended neck. Intraoral upper jaw impressions with rubber base were taken then oral cavity was widely opened by using "Dingmans retractor" Fig.(1)

Oral pack was placed around the endotracheal tube Adrenalin 1: 100,000 were injected along the vomer and palatal bone. In unilateral clefts, an incision was made on non-cleft side at the junction of vomerine mucosa and palate from premaxilla anteriorly, the incision was made continues with the lateral lip incision and continued posteriorly to the crest of the vomer.

Another incision was done at the cleft margin at the junction of nasal mucosa and palatal mucoperiosteum which was made continues with the c flap of the lip repair. The vomerine flap was elevated and inserted under the palatal mucoperiosteum and sutured in a double breasted fashion.

Cast measurement: Impression was used to make a cast for scanning. We used 3-matic Medical 13.0 program to measure the following maxillary dimensions: - A-A': Alveolar cleft width, C-C': Intercanine arch width, E-E': Posterior arch width, B-Z: palatal length as B: is incisal point and Z: the virtual point at the intersection of E-E' indicated by a perpendicular line started from the B point. These records were done on 1ry cast & 2ry cast which is taken after 6 months with intra oral photograph for the palate Fig.(2)

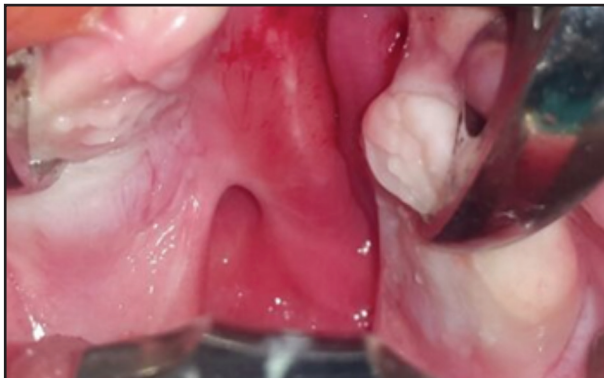

Figure (1): Oral cavity was widely opened by using Dingmans retractor

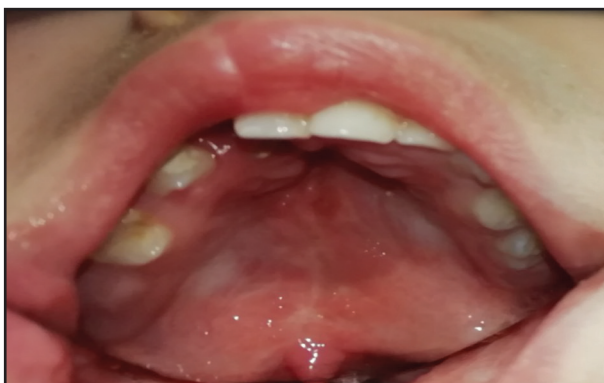

Figure (2): Intra oral photograph for the palate after 6 months of repair

RESULTS

In comparison between the two studied groups according to postoperative dimensions: the results revealed that there were statistically significant differences in A-A` (mm) alveolar cleft width where the mean is lower in the first group (4.4±2.4) compared to the mean of the second group (6.75±2.1), while E- E` (mm) posterior arch width and BZ (mm) perpendicular from B to EE` show statistically significant differences between the two groups where the mean is higher in the first group (37.1±3.1, 33.6±2.7 respectively) compared to the mean of the second group dimensions (34.0±3.3, 30.25±4.1). On the other hand, the C-C` (mm) anterior arch width shows no statistically significant difference between the two groups. Table (1) and Fig (3)

Table (1): Comparison between the two groups of patients according to postoperative dimensions.

Postoperative dimensions (in mm)	Group 1 Mean±SD	Group 2 Mean±SD	t test	P value
A-A` (mm) alveolar cleft width	4.4±2.4	6.75±2.1	1.546	0.033*
C-C` (mm) anterior arch width	27.45±4.1	26.5±5.2	0.307	0.648
E-E` (mm) posterior arch width	37.1±3.1	34.0±3.3	1.459	0.042*
BZ (mm) palatal length	33.6±2.7	30.25±4.1	1.478	0.04*

* Statistically significant difference p<0.05

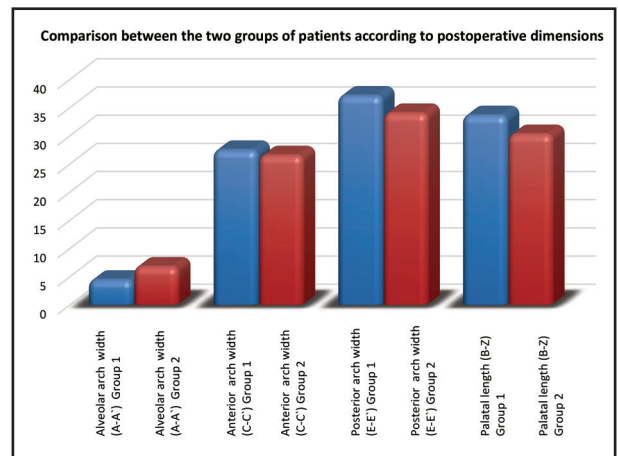


Figure (3): Bar chart representing comparison between the two groups of patients according to postoperative dimensions

DISCUSSION

The focus of this study was done to evaluate early transverse and longitudinal palatal changes in UCLP patients after simultaneous repair of lip and vomerine flap.

Single-layer repair of the hard palate by a vomerine flap (VF) at the time of lip repair was advocated by Pichler in 1926, but the unfavorable effect reported on maxillary growth limited its use. Later the modified vomer flap was described where the vomerine flap was suture to nasal mucosa⁽⁵⁾.

Using a flap of the vomer mucoperiosteum for palatal closure at lip repair reduces the need for releasing incisions at palate repair and therefore minimizes the bare palatal bone; it also yields enough tissue for a tension-free closure⁽⁶⁾.

In this study, double breasted mucosal closure was used by reverse horizontal mattress in all of the cases revealed postoperative complete lip and palate soft tissue healing without any post-operative complication as bleeding, wound dehiscence, infection, flap necrosis, fistula formation contrary to any other complications reported in other studies^(3,7,8). Performing the vomer flap with a “double breasted mucosa” closure, they have never seen a complete dehiscence of the flap. Sometimes a small partial dehiscence of the most dorsal part has been observed, but this is of little clinical consequence⁽⁹⁾.

CONCLUSION

Vomer flap is an easy, safe technique, with less time consuming and provides complete healing with less fistula formation.

REFERENCES

1. Souza VR, Gauthier J, Lézy P, Vacher C. Vascularization of the palate: anatomical study *Surg Radiol Anat.* 2015; 24:13–7.
2. Martin-Smith JD, Fitzgerald L, Orr DJA. How reliable is the vomer flap in early hard palate repair? *JPR* 2017; 70:828-32.
3. Maggiulli F, Hay N, Mars M. Early effect of vomerine flap closure of the hard palate at the time of lip repair on the alveolar gap and other maxillary dimensions. *Cleft Palate –Craniofac J.* 2013; 50:5-7.
4. Agrawal K, Panda K. Use of Vomer Flap in Palatoplasty: Revisited *Cleft J Palate–Cranio-fac.* 2006; 43:16-39.
5. Leow A, Lo L. Palatoplasty: Evolution and Controversies *Craniofac Center and Department of JPR* Chang Gung Memorial Hospital, Chang Gung Med J 2008; 31: 4-8.
6. Maggiulli F, Hay N, Mara N, Worrell E, Green J, Sommerlad B. Early effect of vomerine flap closure of the hard palate at the time of lip repair on the alveolar gap and palatal dimensions. *Cleft Palate Cranio- Fac J* 2014; 51: 43-8.
7. Magdy A, Ahmed T, Moustafa SA, Ibrahim A. Simultaneous repair of cleft lip and hard palate by vomer flap in unilateral complete cleft lip and palate. *Plastic Surgery Department, Al-Azhar University. Eur J Pharm Med Res.* 2017;2:17-8.
8. Deshpande G, Wendby L, Jagtap R. The efficacy of vomer flap for closure of hard palate during primary lip repair. *JPR* 2015; 68: 940-5.
9. De Jong JP, Breugem CC. Use of early hard palate closure using a vomer flap in cleft lip and palate patients *J Cranio-Maxillo-Fac Surg.* 2016; 44:912-18.