

Surgical Correction of Alar Collapse with Alar Batten Graft: Technique and Results

Abdel Aziz Kamal Saad* and Ahmed Taha**

Departments of Otolaryngology* and Plastic & Reconstructive Surgery**

Faculty of Medicine, Al-Azhar University, Cairo, Egypt

*Corresponding author: Abdel Aziz K. Saad, e-mail: aksaad@hotmail.com

ABSTRACT

Background: nasal valve collapse has great perception of nasal obstruction. The alar batten graft technique has proven to be a valid method for treatment of external and internal valve collapse. **Aim:** the aim of the present study was to evaluate a two year experience and follow up for external nasal valve collapse treatment using alar batten graft technique regarding results and complications. **Patients and Methods:** this prospective study was carried out on 18 patients attended the ENT and Plastic Surgery outpatient clinics of Al-Azhar University hospitals from January, 2014 to January 2016. Written consent was taken from every patient. All patients were complaining of nasal obstruction of gradual onset and progressive course with 7 years average. All patients were subjected to detailed history taking and questionnaire including the NOSE scale. Surgical correction was performed to all patients using the alar batten graft harvested from the septa cartilage or conchal cartilage. Postoperative results recorded in relation to subjective sensation of nasal obstruction and aesthetic appearance of the nose. **Results:** eleven patients (61.1%) were males and seven (38.9%) were females. Their age ranged from 18 to 45 years with a mean of 32 ± 2 . Bilateral obstruction was found in 33.3% of cases and unilateral obstruction in 66.7% of cases. There were 22.2%, 27.8%, and 50.0% of the cases had moderate, fair, and severe obstruction, respectively. Postoperatively, these figures were changed to no obstruction 77.8% ($P=0.0$), mild 0.0%, moderate 11.1%, fair 11.1%, and severe 0.0% ($P=0.0005$). The technique significantly abolishes the severe nasal obstruction. Postoperative complications include 1 case with graft resorption (4.2%) and 1 case of graft displacement (4.2%). Both were improved on subsequent surgery. Regarding postoperative findings there was tenderness and hypertrophic postauricular scar in 5.5% of patient and nasal tip edema in 22.2%, all resolved. In the early postoperative period, 33.3% of patients complained of fullness in the supraalar region. **Conclusion:** Successful surgical correction of nasal obstruction requires the precise diagnosis of the anatomic point of collapse. Alar batten graft improves the rigidity of lower lateral cartilage preventing collapse of the lateral nasal wall preventing collapse during moderate and deep inspiration. The graft varies according to the severity of the obstruction and size of the collapsible area of the lateral nasal wall. The septal cartilage is usually sufficient. The technique significantly improves nasal breathing.

Keywords: Alar Collapse, Alar Batten Graft, Functional rhinoplasty.

INTRODUCTION

Functional rhinoplasty describes the collection of techniques that surgically addresses the airflow by correcting nasal valve disturbances [1]. The nasal valves have been proposed to be a major regulator of nasal airflow from exceeding the capacity to warm and humidify inspired air [2]. It has been reported that patients with nasal valve collapse have greater perception of nasal obstruction than those with septal deviation alone [3].

The external nasal valve refers to the distal most aperture of the nasal airway, serving essentially as the nostril orifice. It consists mainly of fibrofatty tissue of the nasal valve in conjunction with the lower lateral cartilages, collumella, medial crural footplates, the caudal septum, and the pyriform aperture [4]. The

contribution of the external valve to nasal obstruction varies considerably depending on the individual anatomy of the nose [4]. External nasal valve collapse is described as collapse of the nostril margin of the nose (alar collapse) during moderate to deep inspiration through the nose [5]. Weakness of the external valve or excessive negative airway pressure during inhalation can result in collapse of the nasal valve with resultant obstruction [6].

The internal nasal valve is the area between the caudal border of the upper lateral cartilages and the dorsal septum. This angle is usually 10-15 degrees in the Caucasian nose [7]. Internal nasal valve collapse is usually observed after previous reductive rhinoplasty in older patients who show weakness of the supportive structures of the nose (upper and lower lateral cartilages). Patients typically have

pinching or medial collapse of the supraalar region^[8]. Unlike the internal nasal valve collapse, the external valve collapse seen in patients with narrow nostrils, a projecting tip and thin weak sidewalls, who did not have previous surgery^[9]. The most common cause of nasal valve dysfunction is iatrogenic following a rhinoplasty. It can also occur due to trauma or idiopathic weakness of the lower lateral cartilages. Non-iatrogenic cases of alar collapse is seen in older patients as aging can weaken the fibroareolar tissue of the nasal sidewall leading to its sagging and collapse on inspiration^[10].

Some commonly used procedures for management of alar valve include alar batten grafts for external valve collapse and spreader grafts for internal valve collapse. Other techniques include butterfly onlay grafts, sutures suspension and flaring sutures^[11].

Sheen^[12] was the first to describe malrotation of the alar cartilages with a weak lateral alar wall, leading to the characteristic "parenthesis" deformity of the nasal tip. The most effective methods to treat collapse of this difficult anatomic area have been the use cartilage grafts to restore function and enlarge the diameter of the internal nasal valve, to strengthen the lateral crura of the lower lateral cartilages or to support the connection of this cartilage to the pyriform aperture. Of the cartilage grafts, the alar batten graft has proven to be a valid technique for treatment of external and internal valve collapse. Alar batten grafts are useful for correction of the boxy nasal tip, malpositioned lateral crura, alar rim retraction, alar rim collapse and concave lateral crura^[6].

Accurate preoperative diagnosis of the specific anatomic problems and subsequent selection of the appropriate surgical technique will ensure the best possible results for patients undergoing functional rhinoplasty.

AIM OF THE STUDY

The aim of the present study is to evaluate a two year experience and follow up for external valve collapse treatment using alar batten graft technique regarding results and complications.

PATIENTS AND METHODS

This prospective study was carried out on eighteen patients attended the ENT and Plastic Surgery outpatient clinics of Al-Azhar University hospitals during the period from January 2014 to January 2016. These patients were diagnosed as non-iatrogenic nasal valve collapse. A written consent form was taken from every patient. All patients were complaining of nasal obstruction. All patients were subjected to history taking using a questionnaire including NOSE (Nasal Obstruction Symptom Evaluation) scale^[13]. These obstruction-related items were then grouped into a preliminary instrument, which contained 5 items (**Figure 1**).

All items were scored using a 5-point Likert scale; not a problem (0), very mild problem (1), moderate problem (2), fairly bad problem (3), and severe problem (4) and were phrased, "Over the past one month, how much of a problem did you have? So, the highest (20 points) scale the worst the nasal obstruction.

Nasal Obstruction Symptom Evaluation (NOSE) Instrument					
→ To the Patient		Please help us to better understand the impact of nasal obstruction on your quality of life by completing the following survey . Thank You!			
Over the past 1 month, how much of a problem were the following conditions for you?					
Please circle the most correct response					
	Not a problem	Very mild problem	Moderate problem	Fairly bad problem	Severe problem
1. Nasal congestion or stuffiness	0	1	2	3	4
2. Nasal blockage or obstruction	0	1	2	3	4
3. Trouble breathing through my nose	0	1	2	3	4
4. Trouble sleeping	0	1	2	3	4
5. Unable to get enough air through my nose during exercise or exertion	0	1	2	3	4

Figure (1): The NOSE Scale instrument, according to **Stewart et al.**^[13]

Full general and ENT examination including:

Inspection: External appearance of the nose, observation of the ala during inspiration. Patients with nasal obstruction caused by nasal alar collapse, which improved with modified Cottle's maneuver (A freer elevator was used to retract and hold the nasal sidewall laterally for approximately 2 to 3 mm).

Photographic Analysis: Basic preoperative photographic views; frontal, profile and basal were done for every patient with special attention to view the alar side wall collapse during maximal inspiration (**Figure 2A**). Postoperatively, the same views were taken for comparison (**Figure 2B**).

Nasal examination including endoscopy: After preparation of the nasal cavity with topical decongestant (xylometazoline) and 1:100 lidocain spray, endoscopic examination to assess the nasal airway, nasal septum, lateral nasal wall, signs of infection to find out if there is any associated causes of nasal obstruction. CT scan was done for every case to assess other causes of nasal obstruction.

All patients were subjected to routine preoperative investigation including CBC, blood sugar, coagulation profile, and liver and kidney function tests.

Patients were classified into two groups:

Group I: Isolated alar collapse, 4 patients (22.2%).

Group II: Alar collapse with other causes of nasal obstruction, 14 patients (77.8%).

Surgical Technique

Local Infiltration Anesthesia: Proper local anesthesia is critical to allow atraumatic dissection with minimal bleeding and edema. About 3-10ml of 1% lidocaine with 1:100,000 epinephrine solution (100 ml saline +10 ml lidocaine solution 1% + 1mg epinephrine) is typically injected in the donor and the recipient sites. The anesthetic is allowed for 15 minutes to take the maximal vasoconstrictor effect of epinephrine. The site of infiltration varied according to the approach and the donor site

selected for graft harvesting. For septoplasty, multiple injections in the subperichondrial plane were used.

Graft Harvesting: Septal cartilage is harvested via a hemi-transfixion incision along the caudal edge of the cartilaginous septum with a no. 15 blade to get access to the caudal septum. Alternatively, a Killian incision is done if access to the caudal septum is not necessary. Then, the muco-perichondrial flap is elevated off the lower half of the nasal septum. Septoplasty is then done to correct septal deviation if present or septal cartilage graft is harvested if there is no septal deviation. A curved piece of septal cartilage is taken to use as an alar batten graft.

Conchal Cartilage Harvest: Posterior approach was used in all cases when conchal cartilage is needed as a source of cartilage graft. Postauricular incision was first marked with a marking pen about 3-4 mm anterior to the postauricular sulcus. Local infiltration with 1% lidocaine with 1: 100,000 epinephrine solution injected subcutaneously. Then incision made with number 15 blade, the subcutaneous dissection in the supra-perichondrial plane in all directions to expose the posterior surface of the whole concha. Then marking if the conchal cartilage with the size needed for the graft and according to whether unilateral grafting or bilateral grafting was needed. Then the cartilage is incised and dissected anteriorly in the subperichondrial plane, and then the graft is removed, making sure that the antihelical fold is not transgressed to avoid postoperative deformity. Careful hemostasis was done followed by closure of the incision with 4-0 Prolene sutures. Bolster dressing was then placed in the conchal bowl.

Graft Preparation: The cartilage graft was fashioned from a curved septal cartilage or a conchal cartilage with its natural curve to give the maximal effect, according to the area of supraalar collapse. The convex side of the graft was oriented laterally.

Alar Batten Graft Insertion:

Marking of the alar side wall was done first to indicate the graft position around the point of the greatest weakness of the alar sidewall. The size of the proposed graft may vary according to the severity of nasal obstruction and size of the collapsible area of the lateral wall of the nose. The larger, wider and more curved the graft, the greater the effect on supporting the alar sidewall. The septal cartilage is usually sufficient, but if significant curvature is required, conchal cartilage is more suitable. After local infiltration anesthesia, a limited marginal incision was made at the nasal vestibule unilaterally or bilaterally according to the case, then a precise pocket was dissected subcutaneously caudal to the lateral crura of the lower lateral cartilage at the point of maximal collapse, then the graft was inserted and the incision was closed with single 4-0 Vicryl suture (**Figure 3**).

By the technique mentioned above, alar batten grafts were used in all patients. Donor site for grafts were septal cartilage (n=12, 66.7%) and conchal cartilage (n=8, 33.3%). Lastly, the collected data were tabulated.

Statistical analysis: The collected data were organized, tabulated and statistically analyzed using statistical package for social sciences (SPSS) version 20 (SPSS, Inc., Chicago, USA). Frequency and percent were calculated for categorical data. Chi-square (χ^2) or Fisher exact (FE) test was used to detect significance of the differences. The significance level in χ^2 and FE tests was accepted at P-value <0.05.

RESULTS

Table (3): Frequency distribution of the studied sample with alar collapse according to type of the deformity

Criteria	Number (n=18)	Percentage
Group I: Isolated valve problem	4	22.2
Group II: Nasal valve problem with other causes of nasal obstruction	14	77.8
Deviated Nasal Septum		
Unilateral	2	11.1
Bilateral	6	33.3
Hypertrophy Inferior Turbinate	4	22.2
Droopy tip	2	11.1

Table (1): Frequency distribution of the studied sample with alar collapse according to their sex and side of the deformity

Criteria	Number (n=18)	Percentage
Male:	11	61.1
Bilateral	4	22.2
Unilateral	7	38.9
Female:	7	38.9
Bilateral	2	11.1
Unilateral	5	27.7

Table (2): Frequency distribution of the studied sample with alar collapse according to side of the deformity laterality

Criteria	Number (n=18)	Percentage
Bilateral	6	33.3
Unilateral	12	66.7
Right sided	6	33.3
Left sided	6	33.3
Total number of operated sides	24	100.0

This study was carried out on 18 patients; eleven (61.1%) were males and seven (38.9%) were females. Their ages ranged from 18 to 45 years with a mean of 32 ± 2 . A gradual onset and progressive course with 7 years average of nasal obstruction were the main complaining of the patients. Bilateral nasal obstruction was found in six patients (33.3%) and unilateral obstruction was found in 12 patients (66.7%). Half (6) of the unilateral cases were right sided (33.3% of the total cases) and other half (6) cases were left sided (33.3% of the total cases) with total twenty four operated sides (**Table 1 & 2**).

There were four patients (22.2%) with isolated deformity and fourteen patients (77.8%) with associated cause of nasal obstruction. Of them 8 patients (44.4%) have septal deviation; two patients (11.1%) in unilateral cases and six patients (33.3%) in bilateral cases. Four cases (22.2%) were on the

same side and four cases (22.2%) on the opposite side. The other patients were four patients (22.2%) have hypertrophied inferior turbinates and two patients (11.1%) have drooping nasal tip (**Table 3**). Septoplasty and turbinoplasty were also done for these patients.

Table (4): Distribution of the studied sample with alar collapse according to pre- and postoperative results of nasal obstruction

Nasal obstruction	Preoperative results(n=18)		Postoperative results(n=18)		χ^2 FE	P-value
	No.	%	No.	%		
No obstruction (no problem)	0	0.0	14	77.8	22.91	0.001
Mild obstruction	0	0.0	0	0.0	---	---
Moderate obstruction	4	22.2	2	11.1	FE	0.65
Fair obstruction	5	27.8	2	11.1	FE	0.4
Severe obstruction	9	50.0	0	0.0	FE	0.001

Postoperative results were recorded in relation to subjective sensation of nasal obstruction (**Table 4**). The NOSE scale was applied on all cases postoperatively and the results were compared to the preoperative data. The data were arranged according to the NOSE score (nasal obstruction) as no sense of obstruction, mild, moderate, fair and severe nasal obstruction. Preoperatively, there were no cases having no obstruction (0.0%) or mild (0.0%), while for moderate, fair and severe obstruction there were 22.2%, 27.8%, and 50.0% of the cases respectively. Postoperatively, these figures were changed as follows; no obstruction 77.8%, mild 0.0%, moderate 11.1%, fair 11.1%, and severe 0.0%. The differences were statistically significant in case of no obstruction and severe obstruction ($P=0.0$ and 0.0005 , respectively). So, the technique significantly abolishes the severe nasal obstruction.

For bilateral cases, there were 5 (20.8%) cases (10 operated sides, 41.6%) cases showing good results and 1 (4.2%) case (2 operated sides, 8.3%) with fair result. Meanwhile, for

unilateral cases there were 9 (37.5%) cases showing good results and 1 (4.2%) case showing fair result and 2 (8%) cases showing unsatisfactory results.

Postoperative complications include one graft resorption (4.2%) necessitating further surgery using auricular cartilage graft replacement for the original septal cartilage alar batten graft, and another graft (4.2%) showed displacement. Both improved with subsequent surgery. As regard postoperative findings there was no postoperative infection, while tenderness and hypertrophic postauricular scar occurred in 1 patient (5.5%) and nasal tip edema in 4 cases (22.2%), all resolved within 6 months. During the early postoperative period, 6 patients (33.3%) complained of slight fullness in the supraalar region. This fullness resolved within six month follow up with satisfactory functional and aesthetic results.

Further, we reported that alar batten graft improves the rigidity of lower lateral cartilage preventing collapse of the lateral nasal wall during moderate and deep inspiration (**Figure 2 A&B**).

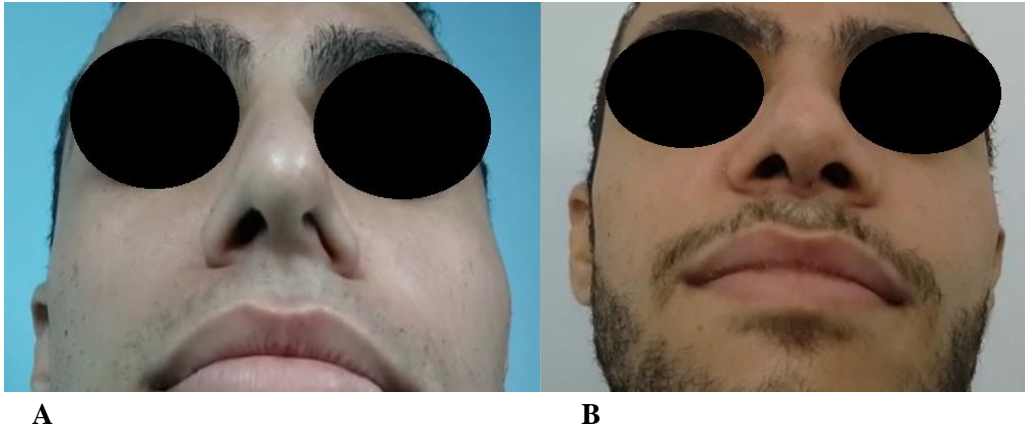


Figure (2): Comparison between the preoperative (A) and postoperative (B) photos after functional rhinoplasty with insertion of left alar batten graft (both pictures were taken during maximal inspiration)

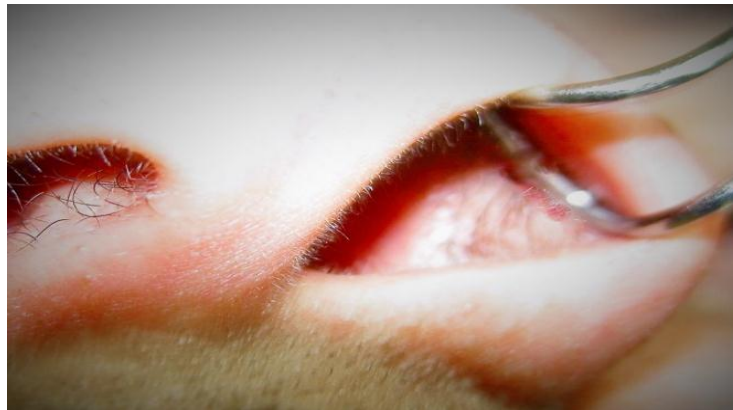

Figure (3): Intraoperative view of the limited marginal incision, the site of insertion of alar batten graft

DISCUSSION

The nasal valves has been proposed to be a major regulator of nasal air flow, causing resistance and preventing airflow from exceeding the capacity to warm and humidity inspired air [2]. The external nasal valve describes an area of the nasal vestibule bounded by the alar rim, nasal sill, and caudal septum [14]. The internal nasal valve is bounded medially by the nasal septum, superiorly and laterally caudal margin of the upper lateral cartilage and more laterally by the anterior portion of the interior nasal turbinate. The nasal valve normally contributes up to 50% of the nasal resistant representing the narrowest point is the upper respiratory tract [15]. Internal nasal valve incompetence results from deficiencies of the structural support of the upper lateral

cartilage. Loss of this support leads to indrawing of the lateral nasal wall in the nasal valve are during inspiration. Small pressure difference between the nose and atmosphere are sufficient to cause collapse of the lateral wall and a decrease in nasal valve cross-sectional area. Symptomatic collapse is predisposed by a narrow internal nasal valve angle, as seen in patients with a narrow middle nasal vault [16]. Alar batten graft technique concentrates on improving the structural integrity of the internal nasal valve rather than increasing its cross-sectional area. This is thought to be the key in treating this condition [17].

Alar batten graft improves the rigidity of the upper lateral cartilage preventing collapse during negative upper airway pressure during inspiration with septoplasty where necessary,

although all patients have undergone a degree of submucous resection for graft harvesting ^[18]. Many underlying factors can contribute to its nasal valves obstruction including trauma, previous surgery or radiation, congenital weakness of the nasal cartilage or aging ^[1]. The incidence of significant postrhinoplasty nasal obstruction has been estimated at 10% ^[19]. This will be due to aggressive resection of the lateral crura during rhinoplasty and the subsequent postoperative soft tissue contraction, which may lead not only to internal, but external nasal valve compromise ^[20].

The present study reports only correction of non-iatrogenic nasal valve collapse by using alar batten graft and the results were recorded in relation to the subjective sensation of nasal obstruction. Preoperatively, there were no cases having no or mild degree of obstruction, while for moderate, fair and severe obstruction, there were 22.2%, 27.8%, and 50.0% of the cases respectively. Postoperatively, these figures were changed as follows; no obstruction 77.8%, mild 0.0%, moderate 11.1%, fair 11.1% and severe 0.0% of the cases.

These results were in consistence with the results reported by **Reddy et al.** ^[10]. They have done their study on 16 consecutive patients undergoing insertion of alar batten grafts for alar collapse causing nasal obstruction had previous history of surgery with some patients (n=8). Subjective nasal obstruction had worsened in 0.0%, unchanged in 16.6%, improved in 16.6% and unsatisfactory in 66.6%. Cosmetic concern showed some obliteration of the supraalar crease, which was not noticed by the patients.

Millman ^[21] reported his results on 21 patients, only one (4.8%) of whom had a previous rhinoplasty and showed 100% improvement at 12 months. Meanwhile, 4 patients (19.1%) were pleased with their aesthetic results.

Toriumi et al. ^[8] reported their results on 46 patients with a mean improvement of nasal airway by 2.5 on a scale of 5 in all patients.

They neither mention about patient demographic nor previous surgery nor the cause of alar collapse. They reported minimal fullness in the supraalar region in some cases.

Becker et al. ^[22] reported excellent results where alar batten grafts were used with septoplasty or septorhinoplasty.

Alar batten grafts are curved cartilaginous supports placed into areas of maximal lateral wall weakness or depression, most typically posterior to the lateral crura. The curvature of the graft is oriented to lateralize the supraalar area. The size of alar graft may vary depending on the severity of obstruction. The larger, wider and more curved the graft, the greater the effect it has on supporting and widening the lateral wall. Septal cartilage usually sufficient for alar batten graft, but if significant curvature is desired, conchal cartilage may be more suitable ^[1].

In the present study, conchal cartilage was used in 8 cases where there was no enough septal cartilage to use taking in consideration the importance of graft dimension as a very important factor in success or failure of the procedure. **Reddy et al.** ^[10] reported that concha was the source of cartilage when the septal cartilage was insufficient or when septoplasty was done in the past. They used conchal cartilage in 4 cases (25%) and both conchal and septal cartilages in 2 cases (12.5%). Furthermore, they described the graft dimension as one of the factors of success of operation. They found significant nasal alar collapse in all failed cases (n=3, 13.75%) and absence of collapse on inspiration was documented in improved cases (n=13, 81.25%). In failed cases the graft size width was 5 to 8mm and in successful cases it was between 18 and 15 mm. Length of the grafts in all cases was between 18 and 24mm. They suggested a minimum graft size of 10 mm, width and 18 mm lengths to improve the success rate.

CONCLUSION

Successful surgical correction of nasal obstruction requires primarily the precise diagnosis of the anatomic point of collapse. Alar batten graft supports the weak lower lateral cartilage, preventing collapse of the lateral nasal wall during moderate and deep inspiration. The graft may vary according to the severity of nasal obstruction and size of the collapsible area of the lateral wall of the nose. The septal cartilage is usually sufficient, but if it is deficient, conchal cartilage is a very good alternative. The technique significantly improves nasal breathing.

REFERENCES

1. **Kim DW and Rodriguez-Bruno K (2009):** Functional rhinoplasty. *Facial Plast Surg Clin North Am.*, 17(1): 115-31.
2. **Spielman PM, White PS and Hussain SSM (2009):** Surgical techniques for the treatment of nasal valve collapse: a systematic review. *Laryngoscope*, 119(7): 1281-90.
3. **Kim CS, Moon BK, Jung DH and Min Y (1998):** Correlation between nasal obstruction symptoms and objective parameters of acoustic rhinometry and rhinomanometry. *Auris Nasus Larynx*, 25 (1): 45-48.
4. **Schlosser RJ and Park SS (1999):** Surgery for the dysfunctional nasal valve: cadaveric analysis and clinical outcomes. *Arch Facial Plast Surg.*, 1:105-10.
5. **Constantine MB (1994):** The incompetent external nasal valve: pathophysiology and treatment in primary and secondary rhinoplasty. *Plast Reconst Surg.*, 93:919-31.
6. **Cervelli V, Spallone D, Bottini D et al. (2009):** Alar batten cartilage graft: treatment of internal and external nasal valve collapse. *Aesth Plast Surg.*, 33: 625-34.
7. **Ballert JA and Park SS (2008):** Functional considerations in revision rhinoplasty. *Facial Plast Surg.*, 24:348-57.
8. **Toriumi DM, Josen J, Weinberger M et al. (1997):** Use of alar batten grafts for correction of nasal valve collapse. *Arch Otolaryngol Head Neck Surg.*, 123(8): 802-8.
9. **Toriumi DM (1996):** Surgical correction of the aging nose. *Facial Plast Surg.*, 12:205-14.
10. **Reddy CEE, Trevor T, Hampals S and Reddy KTV (2009):** Alar batten grafts for non-iatrogenic nasal valve/alar collapse. *Clin Rhinol.*, 2 (3): 1-4.
11. **Fung E, Hong P, Moore C and Taylor M (2014):** The effectiveness of modified Cottle maneuver in predicting outcome in functional rhinoplasty. *Plastic Surg Internat.*, Article ID: 618313.
12. **Sheen JH (1984):** Spreader graft: a method of reconstructing the roof of the middle nasal vault following rhinoplasty. *Plast Reconst Surg.*, 73: 230-9.
13. **Stewart MG, Witsell DL, Smith TL et al. (2004):** Development and validation of the nasal obstruction symptom evaluation (NOSE) scale. *Otolaryngology Head Neck Surg.*, 130: 157-63.
14. **Rhee JS, Weaver EM, Park SS et al. (2010):** Clinical consensus statement: diagnosis and management of nasal valve compromise. *Otolaryngology Head Neck Surg J.*, 134 (1): 48-59.
15. **Kern EB (1973):** Rhinomanometry. *Otolaryngol Clin North Am.*, 6: 863-74.
16. **Faris C, Koury E, Kothari P and Frosh A (2006):** Functional rhinoplasty with batten and spreader grafts for correction of internal nasal valve incompetence. *Rhinology*, 44(2): 114-7.
17. **Weber SM and Becker SR (2010):** Alar cartilage grafts. *Clin Plastic Surgery*, 37 (2): 253-64.
18. **Bewick JC, Buchanan MA and Frosh AC (2013):** Internal nasal valve incompetence is effectively treated by batten graft functional rhinoplasty. *Internatl J Otolaryngology*, Article ID: 734795, Available at: <http://dx.doi.org/10.1155/2013/734795>.
19. **Beekhuis G (1976):** Nasal obstruction after rhinoplasty: etiology, and techniques for correction. *Laryngoscope*, (86): 540-8.
20. **Becker DG and Becker SS (2003):** Treatment of nasal obstruction from nasal valve collapse with alar batten grafts. *J Long Term Eff Med Implants*, 13(3): 259-69.
21. **Millman B (2002):** Alar batten grafting for management of the collapsed nasal valve. *Laryngoscope*, 112 (3): 574-9.
22. **Becker S.S, Dobratz EJ and Stowell N (2008):** Revision septoplasty: review of sources of persistent nasal obstruction. *Am J Rhinol.*, 22: 440-4.