

Role of Rebamipide and \ or Pantoprazole in Preventing Dexamethasone Induced Gastritis in Senile Male Albino Rats

Amgad Ali El Zahaby, Ahmed Abdel Alim and *Ayman F. El Sharawy

Tropical Medicine Department, *Histology and Cell Biology Department, Faculty of Medicine, AlAzhar University

Correspondences: Email: aymanelsharawy@hotmail.com, amgad-elzahaby@.edu.eg

ABSTRACT

Aim of the work: gastritis is the inflammation of the lining of the stomach .It is caused by many factors like infection by *Helicobacter pylori*, drug induced such as aspirin, Non-Steroidal Anti-Inflammatory Drugs (NSAIDs), corticosteroids and alcohol consumption. Pantoprazole prevents HCL formation by blocking proton pumps in parietal cells of the stomach leading to stoppage of pepsinogen enzyme activation. Rebamipide stimulates prostaglandins synthesis so the mucous barrier can be build up to protect the gastric mucosa, so this study aimed to evaluate the efficacy of Pantoprazole and Rebamipide on stomach mucosa protection from the gastritis that was induced by Dexamethasone in rats.

Material and methods: twenty-five male senile albino rats were included in this study and divided into five groups: **G1** (Control group), **G2** (Dexamethasone administrated group), **G3** (Pantoprazole administrated group), **G4** (Rebamipide administrated group) and **G5** (Pantoprazole and Rebamipide administrated group). The collected stomach specimens were subjected to hematoxylin and eosin, PAS and alcian blue stains.

Results: the most weight loss was detected in Dexamethasone administrated group, while the least weight loss was realized in dexamethasone and Rebamipide administrated group. Gastric samples showed improvement in gastric mucosa in **G3** and **G4**, but the best improvement was demonstrated in **G3**.

Conclusion: Rebamipide has a better protective effect than the Pantoprazole in prevention of gastric mucosal injuries.

Keywords: Dexamethasone, Pantoprazole, Rebamipide, mucous barrier.

INTRODUCTION

Gastritis is the inflammation of the lining layer of the stomach ^[1]. It is caused by many factors like infection by *Helicobacter pylori*, drug induced such as aspirin, nonsteroidal anti-inflammatory drugs (NSAIDs) or corticosteroids and alcohol consumption ^[2]. The complications of gastritis may occur over time, especially if gastritis becomes chronic and the underlying causes are not treated. Complications may include peptic ulcer, bleeding ulcers, anemia and gastric cancers ^[3].

Corticosteroid like dexamethasone is one of the important drugs which has many indications in medicine like cases of rheumatoid arthritis, bronchial asthma and in brain tumors (primary or metastatic), as it counteracts the development of edema ^[4,5,6]. Dexamethasone causes gastric erosions by damaging of the surface epithelial cells and rendering the gastric mucosa susceptible to ulceration by inhibiting prostaglandin synthesis which is essential for formation of the mucous barrier layer ^[7].

Many drugs are used for treatment of gastritis. Proton pump inhibitors like Pantoprazole decrease HCL secretion by blocking H⁺/ K⁺ pump

so it prevents the activation of the pepsinogen enzyme to pepsin ^[8]. A Pantoprazole use has an important disadvantage which is elevation of the stomach pH, this is known as hypochlorhydria. Hypochlorhydria may lead to: failure of proper food digestion, failure to absorb important elements like iron and calcium. This will be followed by iron deficiency anemia and osteoporosis. Failure in sterilization of the stomach contents may render the individuals more susceptible to gut infections such as gastroenteritis ^[9,10,11]. Rebamipide stimulates prostaglandins generation in gastric mucosa and improves the speed and quality of ulcers healing, in addition it protects the gastric mucosa against acute injury caused by noxious and ulcerogenic factors. Rebamipide has no effect in changing stomach PH so it avoids the disadvantages of proton pump inhibitor use ^[12, 13].

AIM OF THE WORK

This study aimed to evaluate and compare the protective effect of Pantoprazole and Rebamipide as a single drug or in combination on the gastric mucosa after gastritis induction by Dexamethasone.

MATERIAL AND METHODS

This study was done in Department of Histology, Faculty of Medicine, Al Azhar University at the period from February 2014 till August 2014.

Twenty five senile male albino rats (220 - 300 g) were included in this study; they were housed in cages at room temperature and under aseptic condition and they were feed balanced diet contained 50% carbohydrates, 25% proteins and 25% fat and drink clean water that was continuously changed. They were categorized into five groups (each group contained 5 rats) as the following:

Group 1 (G1): control group.

Group 2 (G2): rats of this group were given Dexamethasone only for four days (Their average weights were 300 g).

Group 3 (G3): rats of this group that were given Dexamethasone and Pantoprazole together for four days (Their average weights were 250 gm).

Group 4 (G4): rats of this group were given Dexamethasone and Rebamipide together for four days (Their average weights were 220 g).

Group 5 (G5): rats of this group were given Dexamethasone, Pantoprazole and Rebamipide for four days (Their average weights were 220 g).

Doses of the used drugs:

Dexamethasone (4 mg/kg) it was given by intraperitoneal route once daily for four days ^[14].

Rebamipide dose (100 mg/kg) it was given by oral route as two divided doses each day ^[15].

Pantoprazole 20mg/ kg it was given by oral route as single dose each day ^[16].

At the 5th day of the experiment the animals were weighted to determine the weight changes, anaesthetized by injection of diazepam intraperitoneally then their abdomen were sectioned and their stomach were taken, the stomachs were examined by naked eye for gross pathological changes and then they were fixed in neutral buffered formal saline for preparing of paraffin technique ^[17]. Sections were stained with:

a. Hematoxylin and Eosin to observe the morphology of the tissue and to detect the number of vesicular nuclei within the high power field ^[18].

b. Periodic acid Schiff (PAS) and alcian blue stains to show the mucous barrier layer of the stomach mucosa for measuring its thickness and optical density ^[19].

Statistical analysis of the following data

1- Weight change of the rats before and after the experiment and their percentage.

2-The mean number of vesicular nuclei was detected in each group in sections prepared from both the body and pylorus. Vesicular nuclei are indicator of the healthy cells.

3-The thickness of the mucous barrier layer was measured in micrometer and its optical density was estimated by using the image program (image J) to detect distribution of PAS materials ^[20].

The obtained results were statistically analyzed and the following values were estimated:

a- Standard error of mean by the following formula:

Standard Error of the Mean = standard deviation of mean / $\sqrt{\text{sample number}}$

b- P value

It was estimated in comparison with the control group by using excel in Microsoft program taking in consideration that the value less than 0.05 was considered as a significant result.

RESULTS

A-Naked eye examination results

In **G1** the mucosa looks healthy and there were no apparent ulcers, no erosions and no hemorrhage. In **G2** the outer wall of the stomach showed severe congestion and engorged blood vessels (**Figure 2a**), while the mucosa showed multiple erosions and marked congestion (**Figure 2b**). In **G3** the outer wall of the stomach showed marked congestion (**Figure 3a**), while the mucosa showed multiple erosions, ulcers in the body and marked congestion (**Figure 3b**). In **G4** the outer wall of the stomach looks healthy with no congestion and no engorged vessels (**Figure 4a**), while the mucosa looks healthy with no apparent ulcers, erosions or hemorrhage (**Figure 4b**). In **G5** the outer wall of the stomach showed moderate congestion (**Figure 5a**), while the mucosa showed scattered erosions and ulcers in the body (**Figure 5b**).

B- Mean weight changes

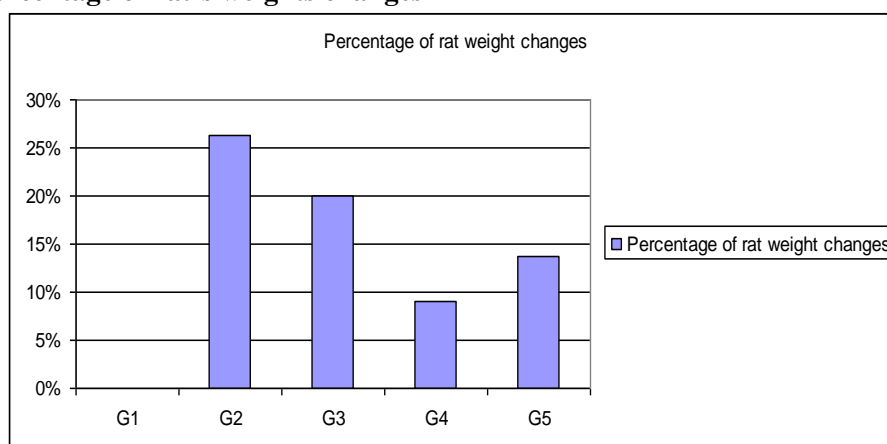
Results represented in **table 1** and **chart1** showed that there was a significant decrease in weights of all the rats which were injected by Dexamethasone, the greatest percentage of weight loss was in the group **G2**, then **G3**, **G5** as they lost 26.66%, 20% and 13.63% percents of their average weight respectively. The weight loss in **G4** was the least among the other groups, as they lost 9.09 %of their average weight.

Table1- Mean weight of the rats and percentage of rat’s weights changes

	G1	G2	G3	G4	G5
Mean weight ± Standard error (grm) before experiment	300±7.87	300±9.54	250±4.94	220±5.48	220±8.26
Mean weight ± Standard error (grm) after experiment	300±5.7	220±3.53	200±18.193	200±12.84	190±11.26
Percentage of rat weight changes	0 %	26.26 %	20 %	9.09 %	13.63 %
p- value	> 0.05	< 0.05*	< 0.05*	< 0.05*	< 0.05*

* Significant: in comparison with the original weight of each group.

Chart 1- percentage of rat’s weights changes



C- Microscopical examination results:

The mean numbers of vesicular nuclei in both the upper surface and basal part of the mucosa of the stomach were estimated under high power field. These numbers were showed in **tables 2&3** and represented in **charts2 &3** for the stomach body and pylorus respectively.

The greatest number of vesicular nuclei was present in **G1** then **G4**, and the least number was present in **G2** with statistically significant difference between group 1 and other groups.

Table 2-Mean number of vesicular nuclei in the mucosa of the stomach body

		G1	G2	G3	G4	G5
Mean number of vesicular nuclei in the mucosa of the stomach body ± Standard error	Upper surface	25±4.685	6±0.355	11±1.63	17±2.841	12±2.16
	Basal part	30±0.707	7±0.455	11±2.193	21±3.841	13±2.26
p- value			<0.05*	<0.05*	<0.05*	<0.05*

Significant in comparison with the G1.

Chart 2-Mean number of vesicular nuclei in the mucosa of the stomach body

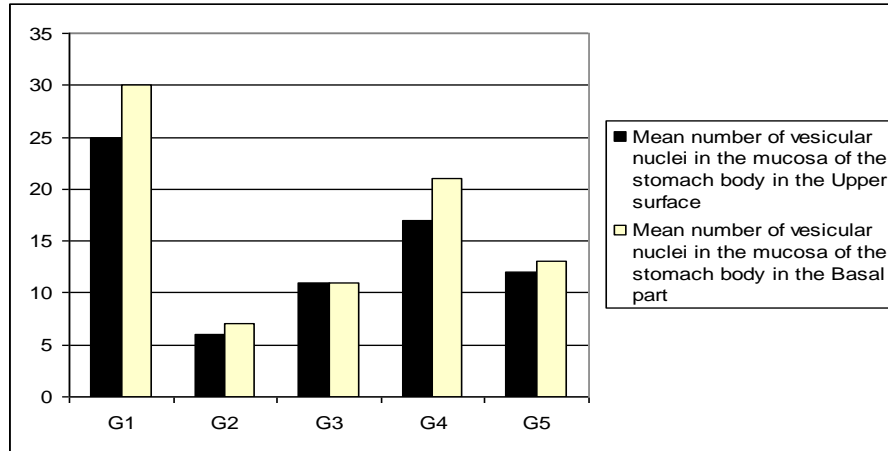
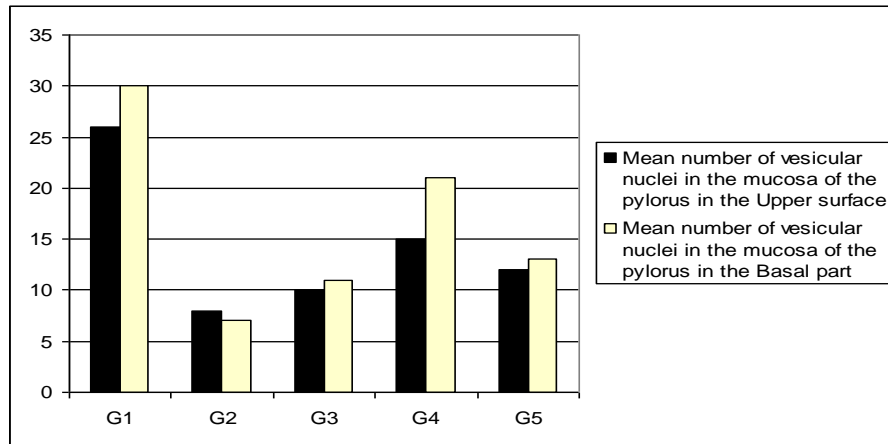


Table 3-Mean number of vesicular nuclei in the mucosa of the pylorus

		G1	G2	G3	G4	G5
Mean number of vesicular nuclei ± Standard error	Upper surface	26±0.938	8±0.535	10±1.193	15±2.841	12±2.016
	Basal part	30±0.707	7±0.455	11±2.193	21±3.841	13± 2.26
p- value			< 0.05*	< 0.05*	< 0.05*	< 0.05*

Significant in comparison with the G1.

Chart 3-Mean number of vesicular nuclei in the mucosa of the pylorus



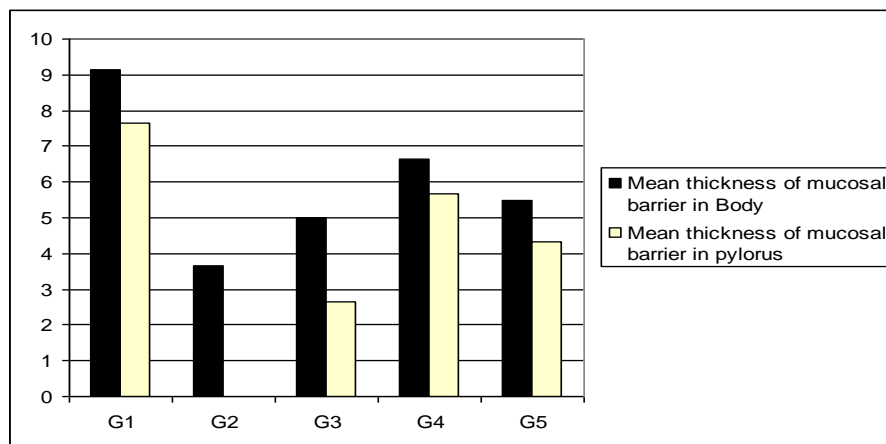
The mean thickness of mucosal barrier in both the body and pylorus were estimated. They were represented in **table 4 chart 4**. The thickest barrier was present in **G1**, then **G4** and the thinnest barrier was present in **G2** in the body and it was lost in the pylorus.

Table 4-Mean thickness of mucosal barrier in the stomach

		G1	G2	G3	G4	G5
Mean thickness of mucosal barrier ± Standard error	Body	9.16± 0.7	3.66±0.45	5± 0.53	6.66±0.65	5.5±0.61T
	pylorus	7.66±0.72	0	2.66±0.43	5.66±0.29	4.33±0.39
p- value			< 0.05*	< 0.05*	< 0.05*	< 0.05*

Significant in comparison with the G1.

Chart 4-Mean thickness of mucosal barrier in the stomach



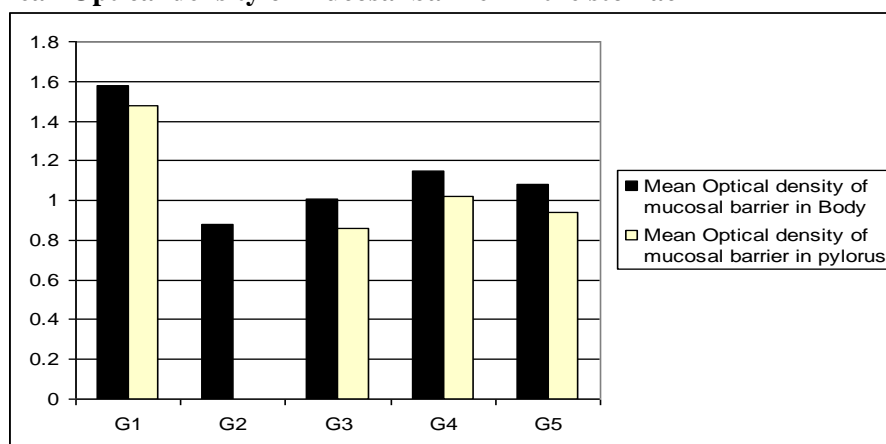
The mean optical density of mucosal barrier in both the body and pylorus was estimated. It was detected in **table5** and in chart5. The well-formed barrier was present in **G1** then **G4** and the thinnest and dissociated barrier was present in **G2** in the body and it couldn't be detected in the pylorus.

Table 5- Mean optical density of mucosal barrier in the stomach

		G1	G2	G3	G4	G5
Mean Optical density ± Standard error	Body	1.58±0.07	0.88±0.06	1.01±0.06	1.15±0.02	1.08±0.04
	pylorus	1.48±0.12	No detected	0.86±0.04	1.02±0.06	0.94±0.07
p- value			< 0.05*	< 0.05*	< 0.05*	< 0.05*

Significant in comparison with the G1.

Chart 5- Mean Optical density of mucosal barrier in the stomach



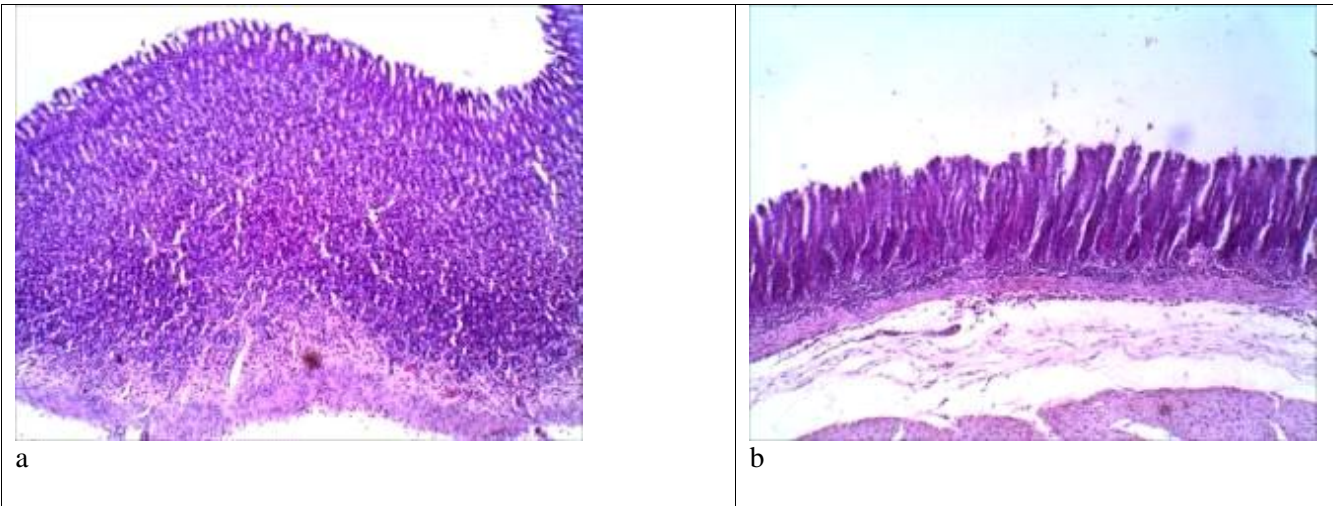


Figure 1: photomicrographs of sections in the mucosa of stomach of the rats of G1 showing intact mucosa without ulcers or blood vessels congestion in both the body (a) and pylorus (b). (H & Ex100).

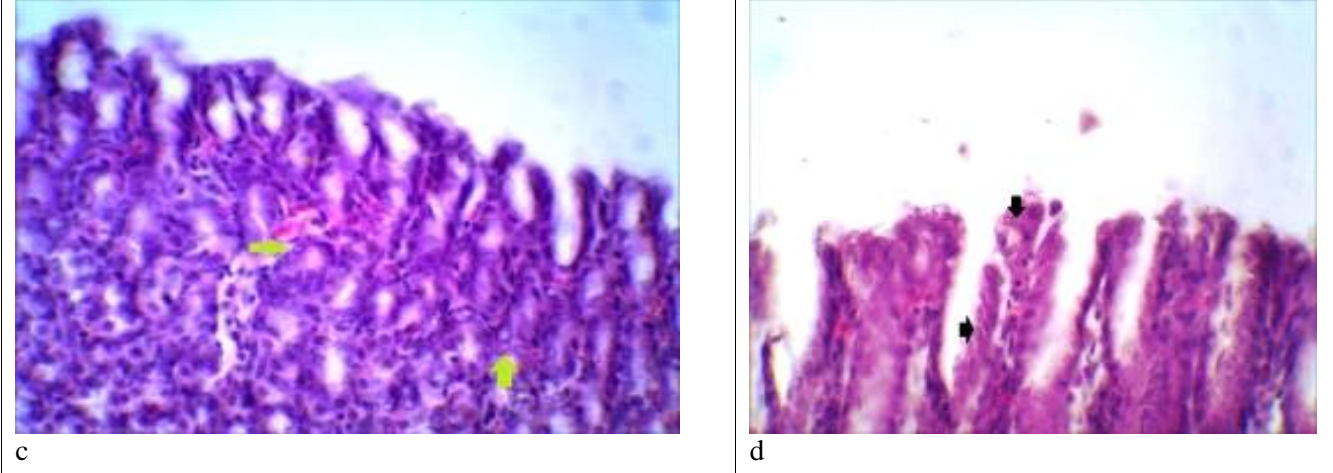


Figure 1: photomicrographs of sections in the upper surface of the mucosa of stomach of the rats of G1 showing intact cells containing vesicular nuclei (green arrows) in the body (c) and pylorus (d). (H & Ex400).

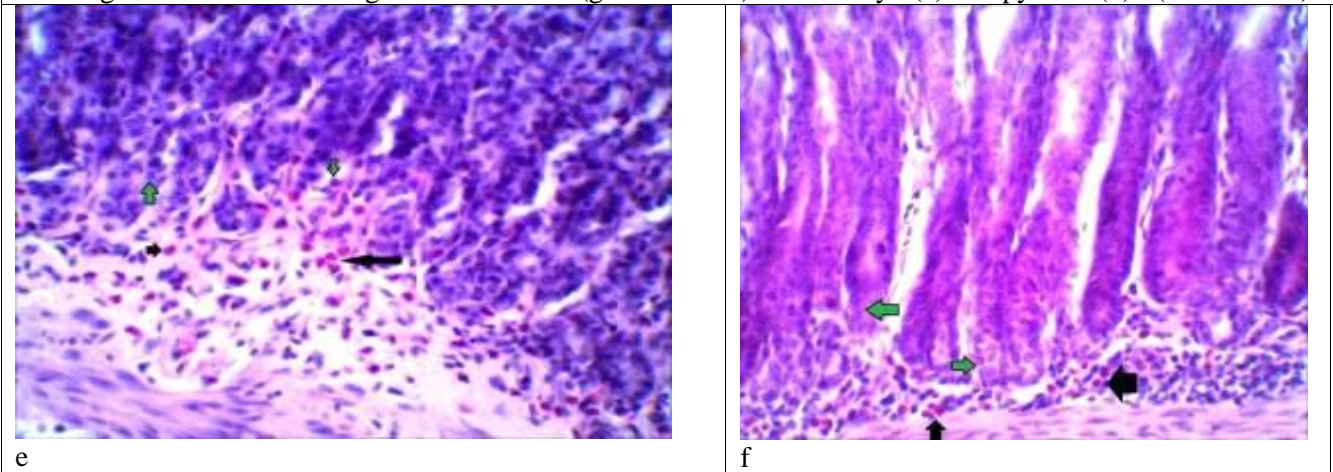


Figure 1: photomicrographs of sections in the basal part of the mucosa of stomach of the rats of G1 showing intact cells with vesicular nuclei (green arrows) in both the body (e) and pylorus (f). The submucosa is rich in eosinophils (black arrows). (H & Ex400).

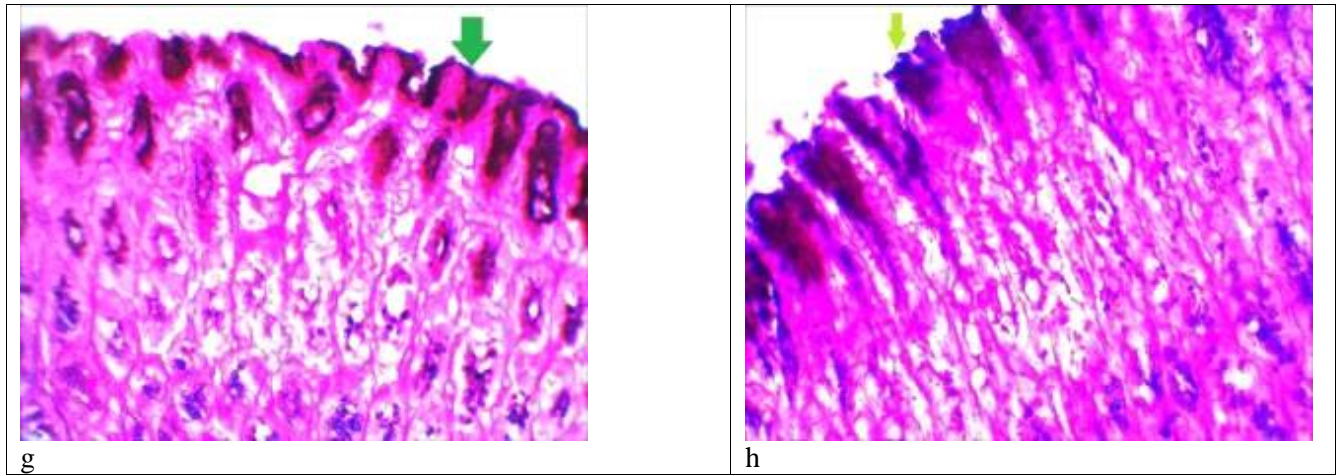


Figure 1: photomicrographs of sections in stomach of the rats of **G1** showing intact PAS +ve mucous barrier layer (green arrows) in both body (g) and pylorus (h) . (PAS & Alcian Blue x400).

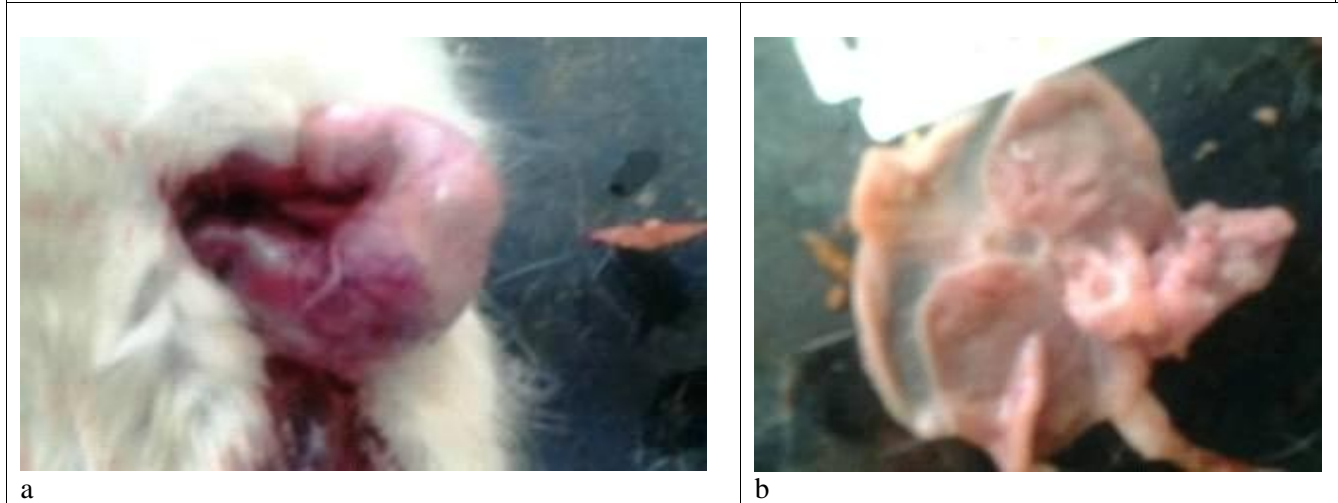


Figure 2: photographs of stomach of rats of **G2**, showing severe congestion in the outer wall of the stomach (a) and multiple erosions in the mucosal surface of the stomach (b).

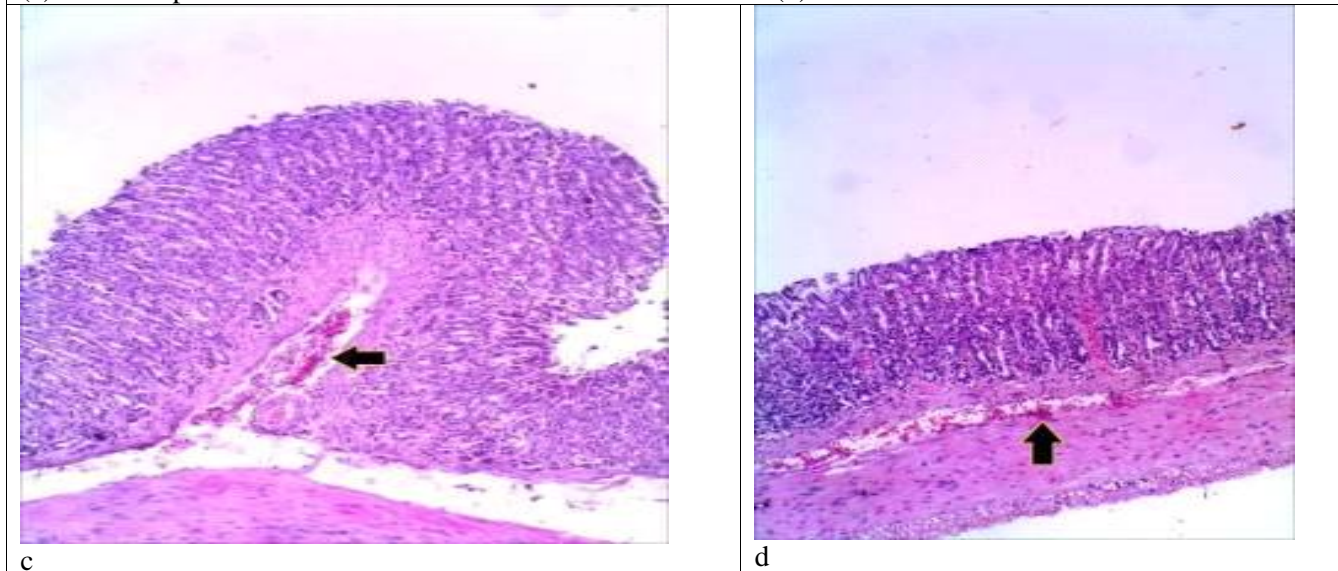


Figure 2: photomicrographs of sections in stomach of rats of **G2**, showing marked blood vessels congestion (black arrows) in the submucosa of both the body (c) and the pylorus (d). (H & Ex100).

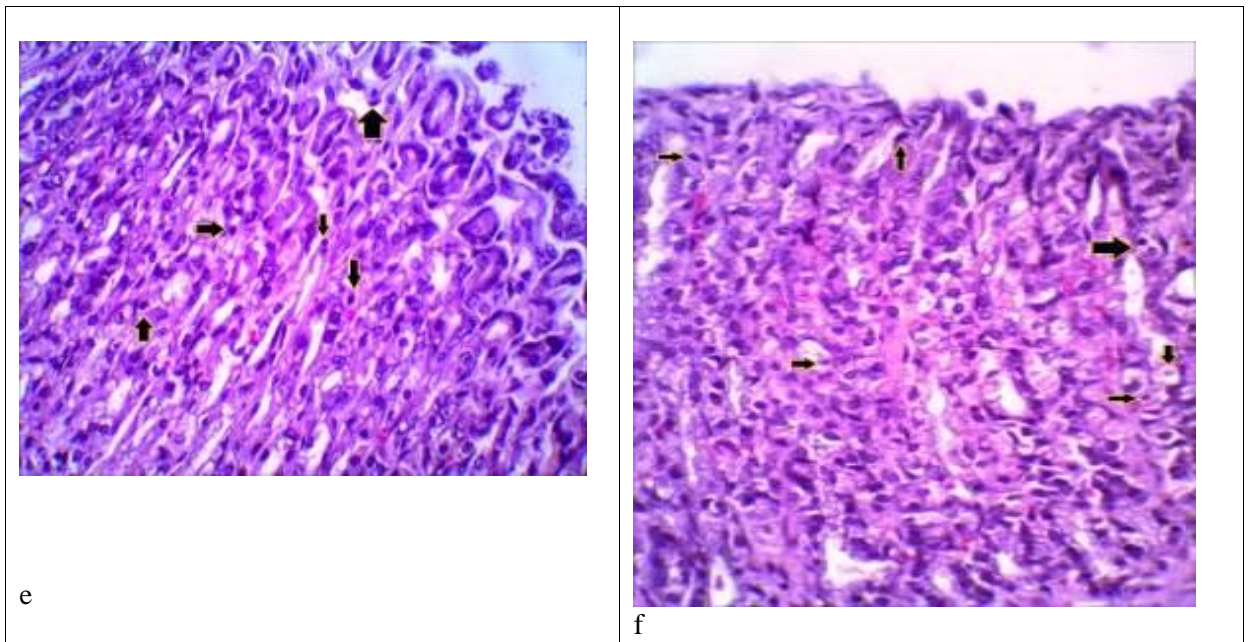


Figure 2: photomicrographs of sections in the mucosa stomach of the rats of **G2**, showing wide spread necrotic cells with pyknotic nuclei (black arrows) in the upper surface of the mucosa in both the body in figure (e) and pylorus in figure (2- f). (H & Ex400).

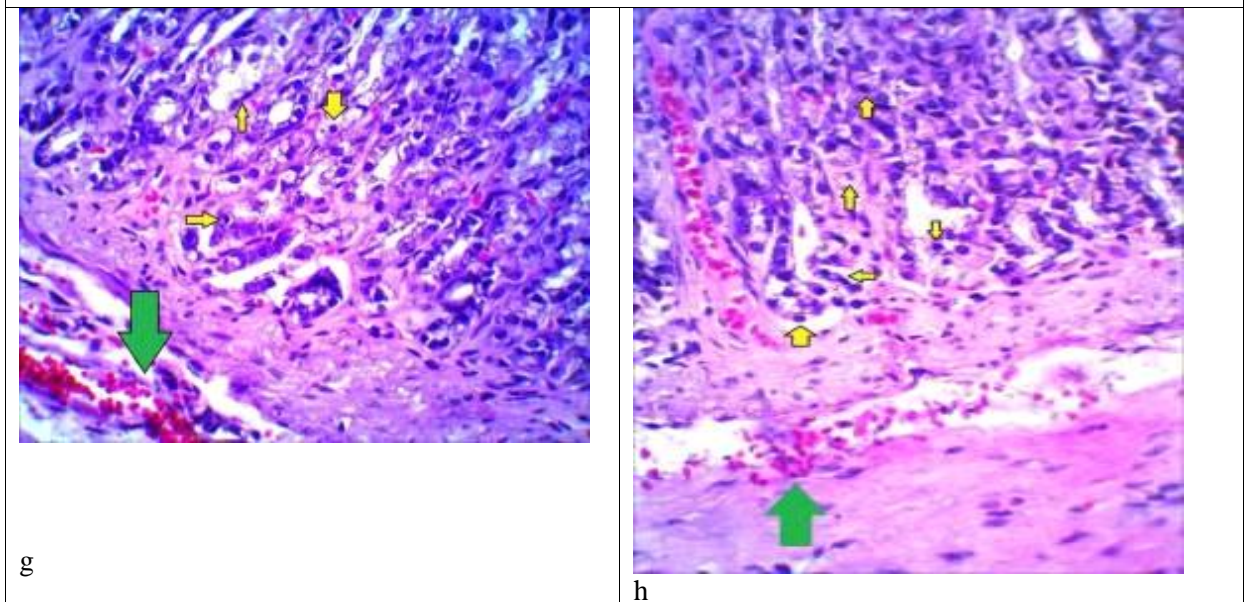


Figure 2: photomicrographs of sections in the mucosa stomach of the rats of **G2**, showing wide spread necrotic cells with pyknotic nuclei (yellow arrows) in the basal part of the mucosa in both the body (g) and pylorus (f h). There is also marked congestion (green arrows) up to interstitial hemorrhage in the pylorus. There were no eosinophils in the lamina propria. (H & Ex400)

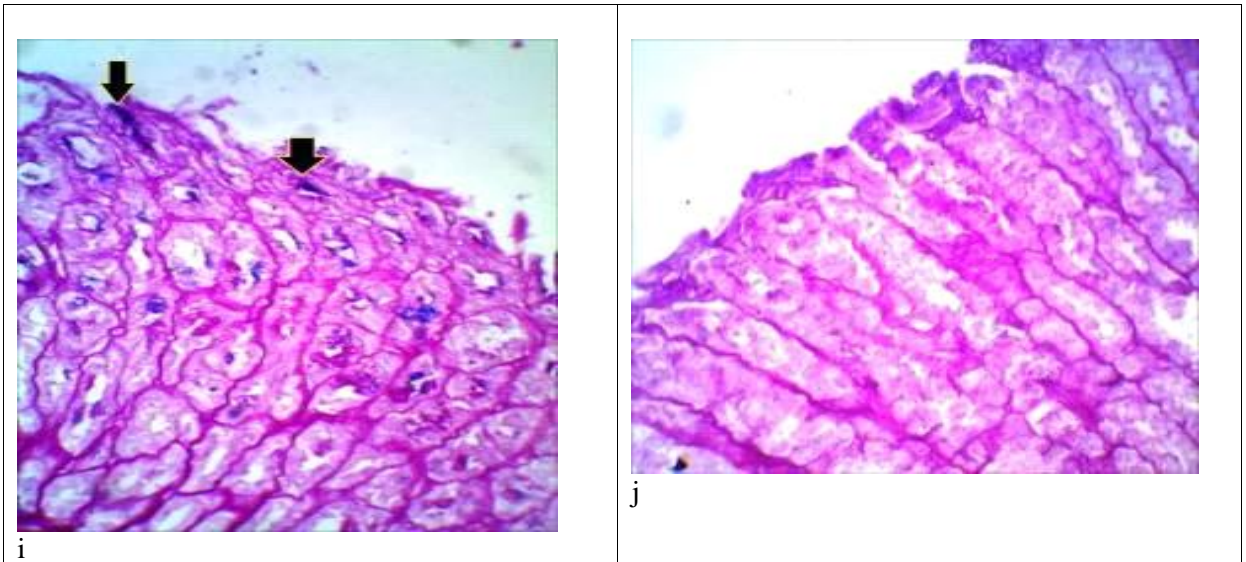


Figure 2: photomicrographs of sections in stomach of rats of **G2** showing remnants of PAS +ve mucous barrier layer (black arrows) in the body (i), while PAS reaction is completely absent in the pylorus (j) due to loss of the mucous barrier. (PAS & Alcian Blue x 400)

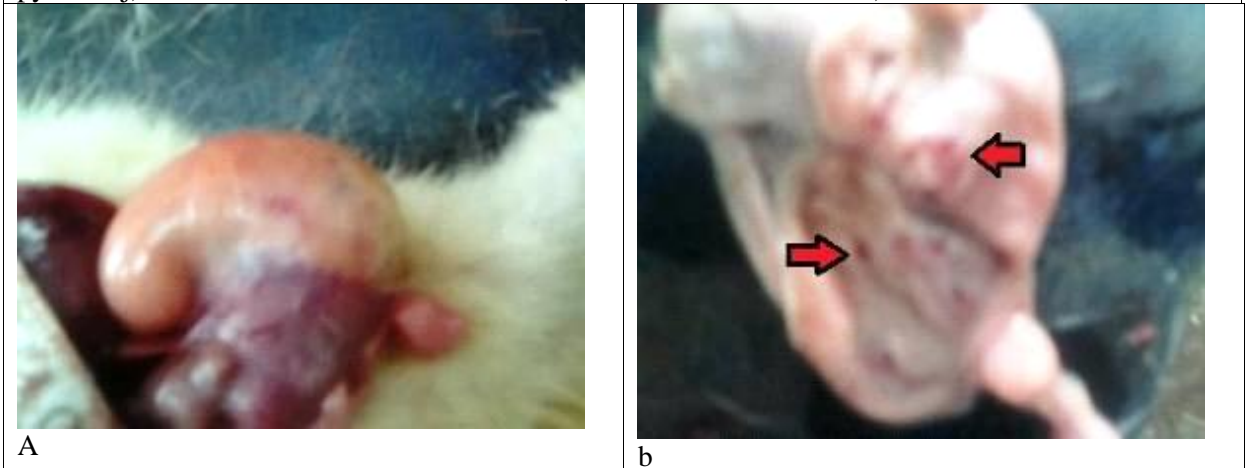


Figure 3: photographs of stomach of rats of **G3** showing marked congestion in the outer wall of the stomach (a) in addition to multiple ulcers (red arrows) in the mucosal surface of the stomach (b).

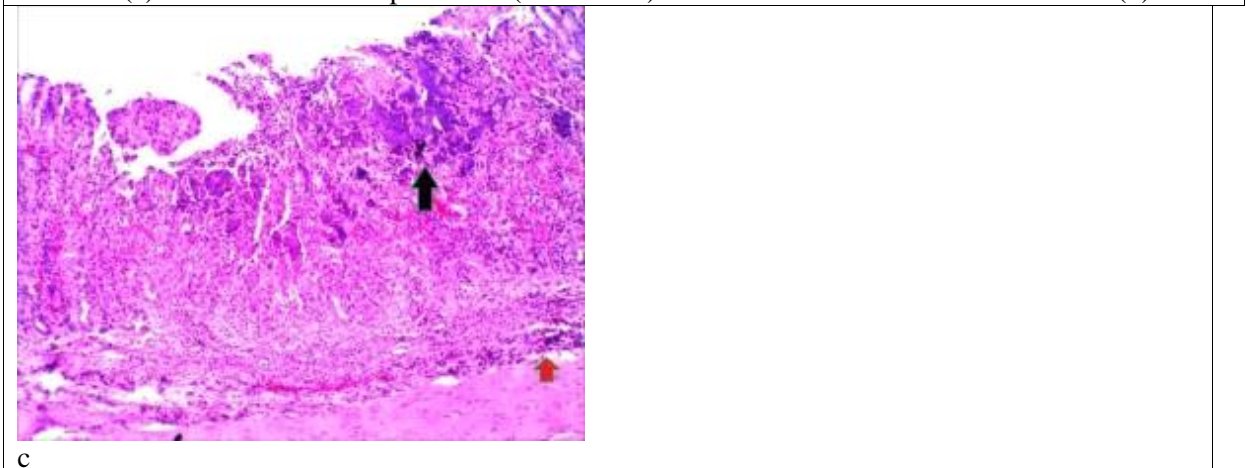


Figure 3: a photomicrograph of a section in stomach body of a rat of **G3** showing ulcerated mucosa (c) with necrotic tissue (black arrow) and lymphocytic infiltration (red arrow). (H & Ex100).

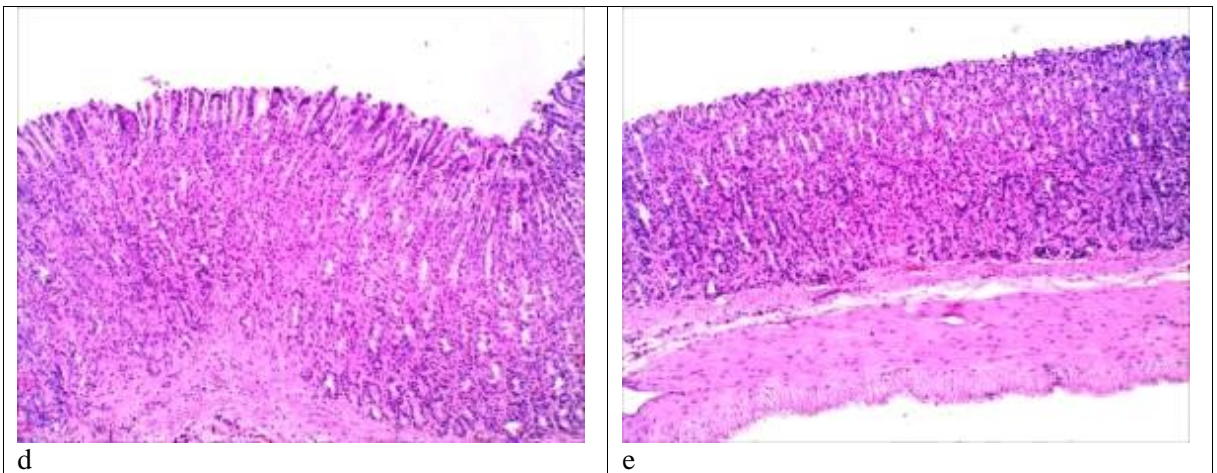


Figure 3: photomicrograph of sections in stomach body of rats of **G3** showing non ulcerated mucosa without congested blood vessels in both the body (d) and pylorus (e). (H & Ex100)

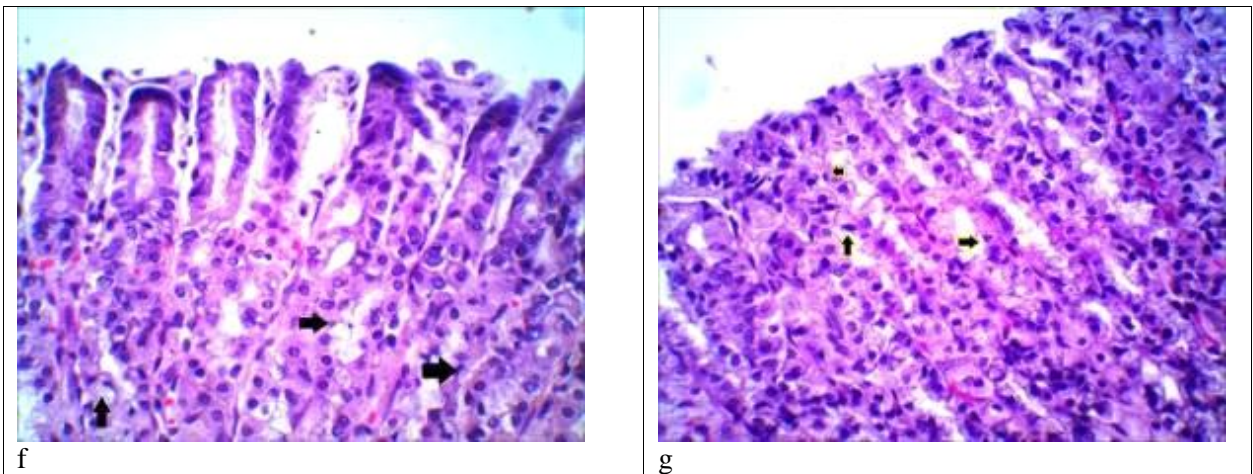


Figure 3: photomicrographs of sections in stomach of rats of **G3** showing the upper surface of the non ulcerated mucosa which contains necrotic cells with pyknotic nuclei (black arrows) in body (f) and pylorus (g). (H & Ex400).

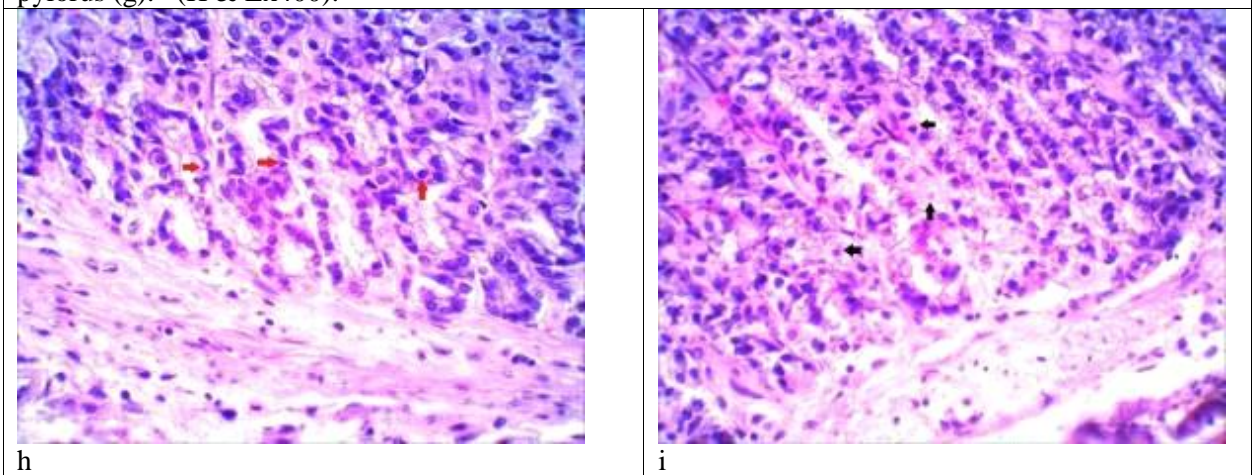


Figure 3: photomicrographs of sections in stomach of rats of **G3** showing the basal part of mucosa which contains necrotic cells with pyknotic nuclei (red arrows) in body (h) and pylorus (black arrows) (i). There were no eosinophils in the lamina propria. (H & E x 400).

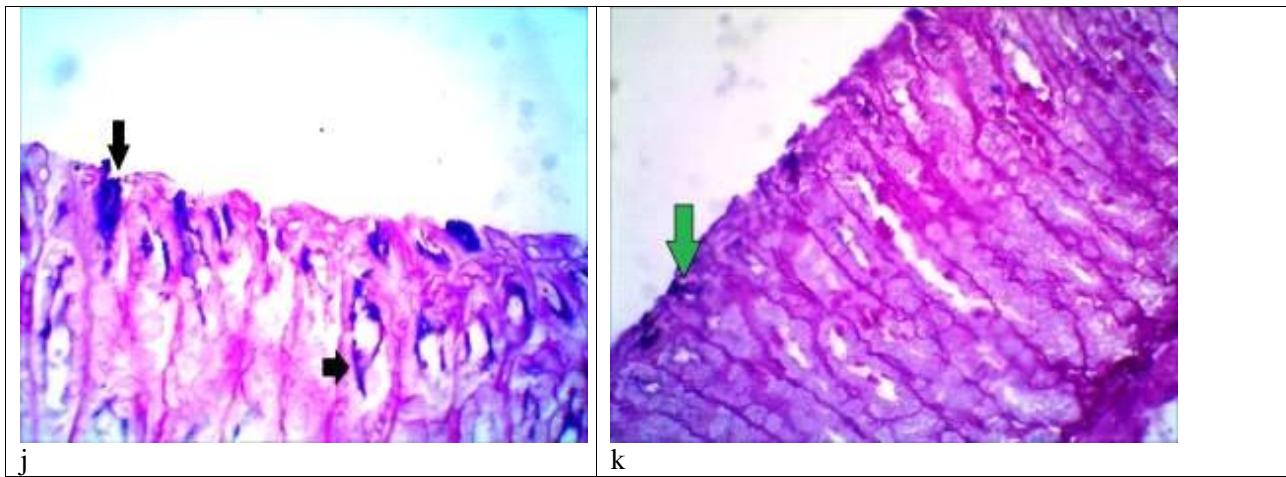


Figure 3: photomicrograph of a section in stomach of a rat of **G3**, showing remnants of PAS +ve mucous barrier layer (black arrows) in the body (j) and the pylorus (figure k) . (PAS & Alcian Blue x 400).

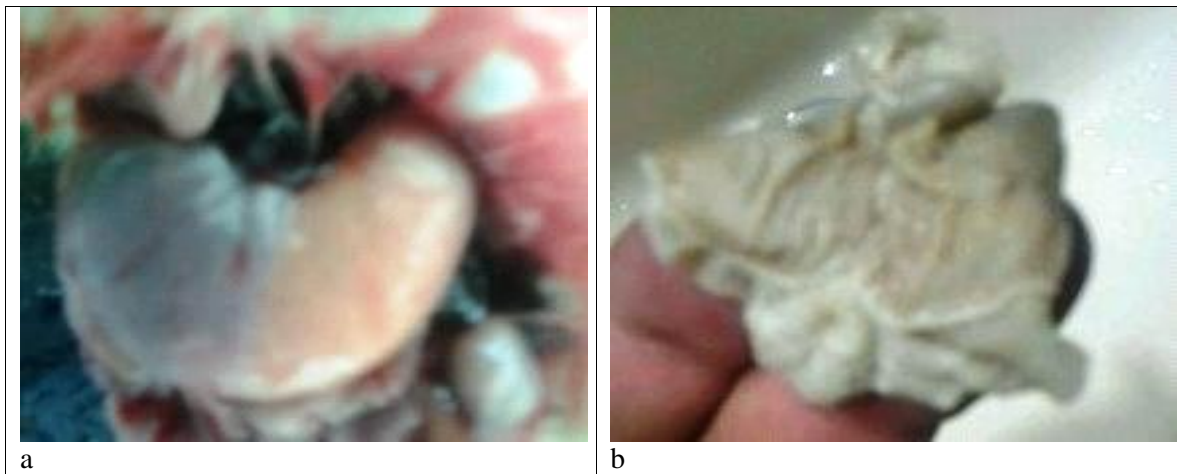


Figure 4: photographs of stomach of rats of **G4** showing free outer wall of the stomach from congestion and vessels engorgement (a) and healthy mucosa without ulcers or erosions (b).

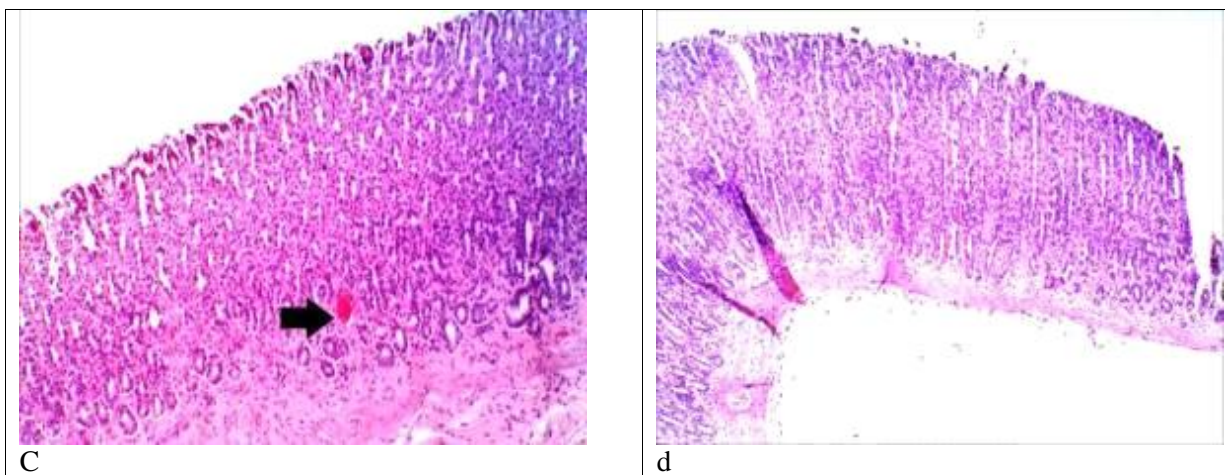


Figure 4: photomicrograph of sections in stomach of rats in **G4** showing congested blood vessels (black arrow) but there was no ulceration in the body (c) while the pylorus appears healthy (d) . (H & E x 100).

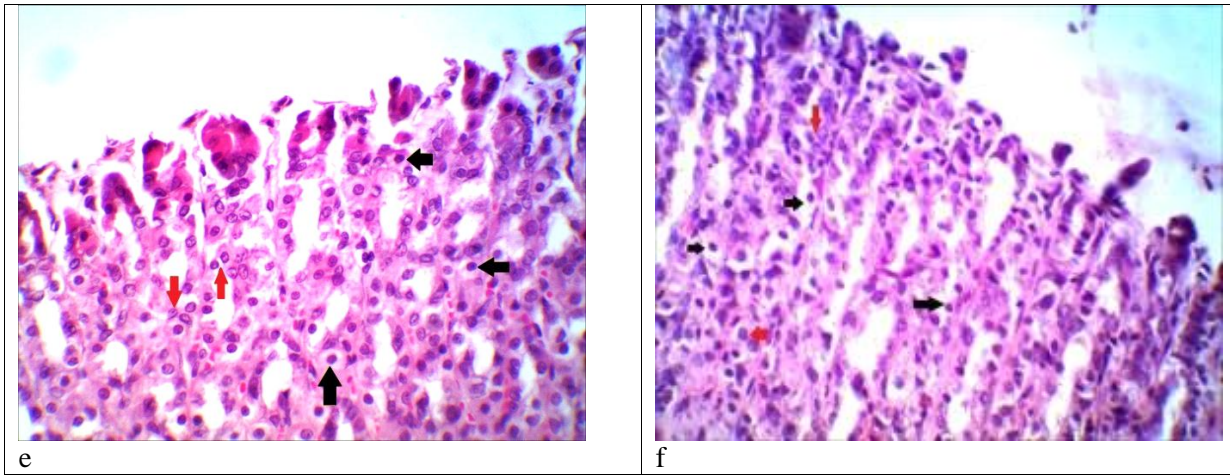


Figure 4 : photomicrographs of sections in the stomach of rats of **G4** showing the upper surface of the mucosa containing healthy cells with vesicular nuclei (red arrows), but there are few necrotic cells with pyknotic nuclei (black arrows) in both the body (e) and pylorus (f). (H & E x 400).

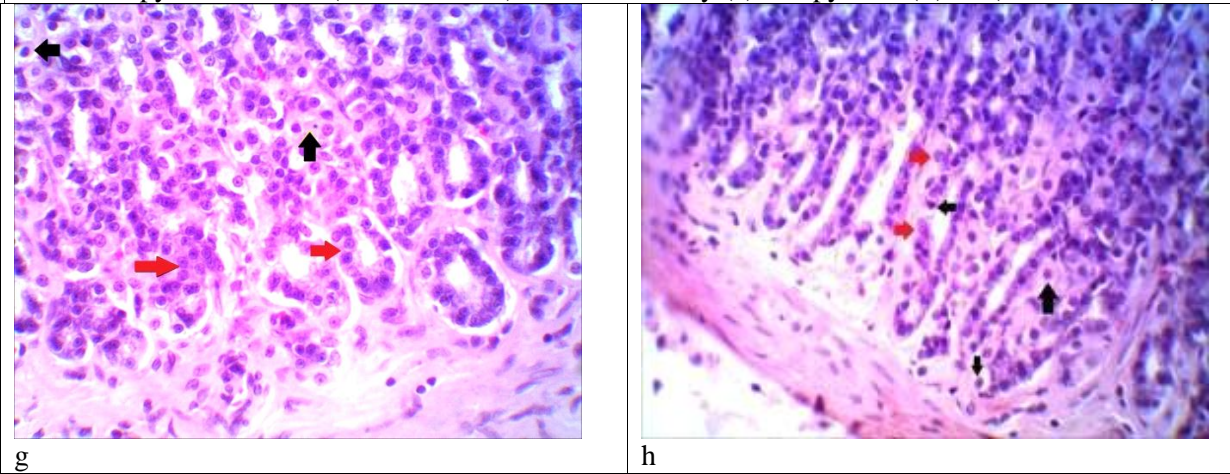


Figure 4: photomicrographs of sections in the stomach of rats of **G4** showing the basal part of the mucosa containing healthy cells with vesicular nuclei (red arrows), but there are few necrotic cells with pyknotic nuclei (black arrows) in both the body (g) and pylorus (h). There are no eosinophils in the lamina propria. (H & E. x 400).

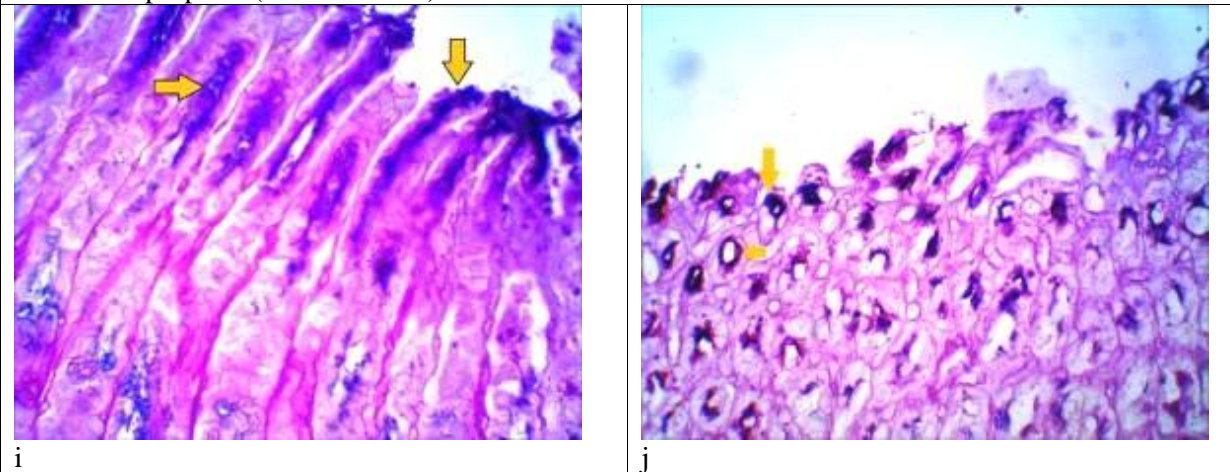


Figure 4: photomicrographs of sections in stomach of rats of **G4** showing well formed PAS +ve mucous barrier layer (yellow arrows) in the body (i), but the mucous barrier appears interrupted (yellow arrows) in the pylorus (j) .(PAS & Alcian Blue x 400) .

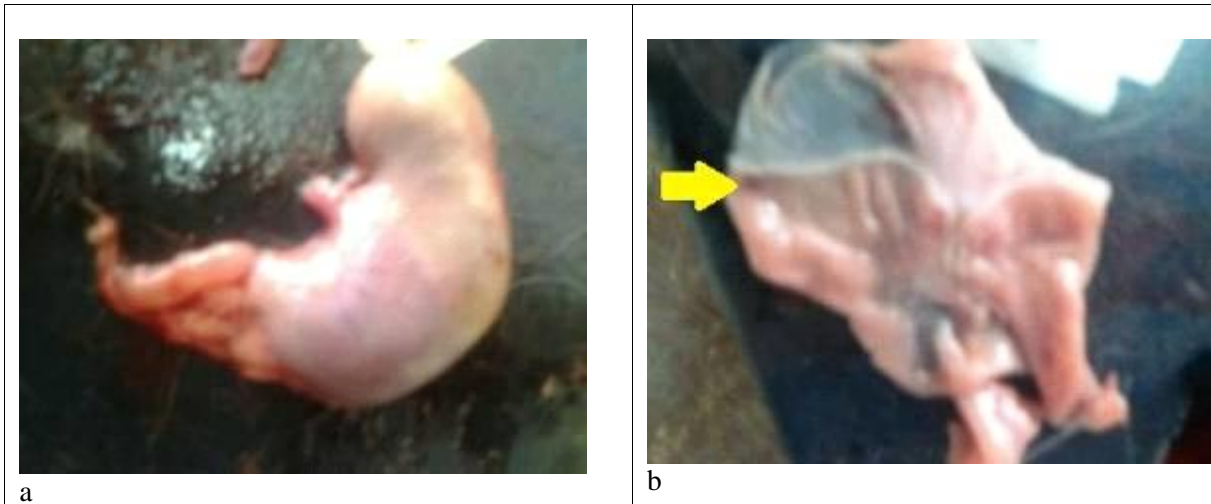
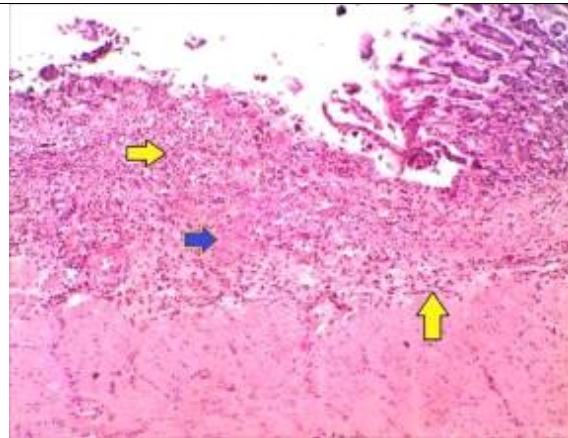


Figure 5: photographs of stomach of rats of G5 showing mild to moderate congestion in the outer wall of the stomach.(a), while the mucosal surface (b) of the stomach showing moderate congestion and some ulcers (yellow arrow).



C

Figure 5: a photomicrograph of a section in stomach body of a rat of G5 showing ulcerated mucosa with necrotic tissue (blue arrow) and lymphocytic infiltration (yellow arrows). (H & E x 100).

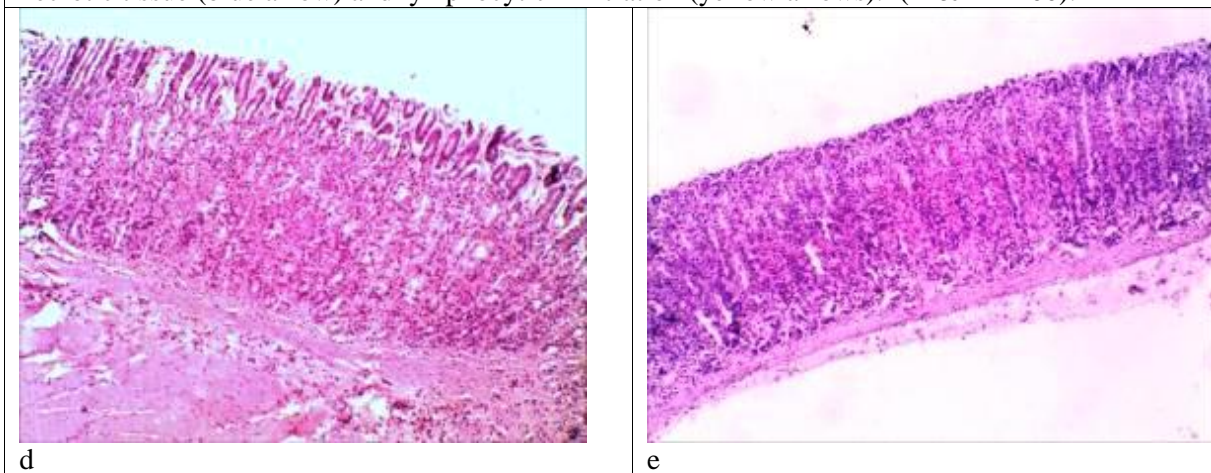


Figure 5: photomicrographs of sections in stomach of rats of G5 showing non ulcerated mucosa without congested blood vessels in both the body (d) and pylorus (e). (H & Ex 100) .

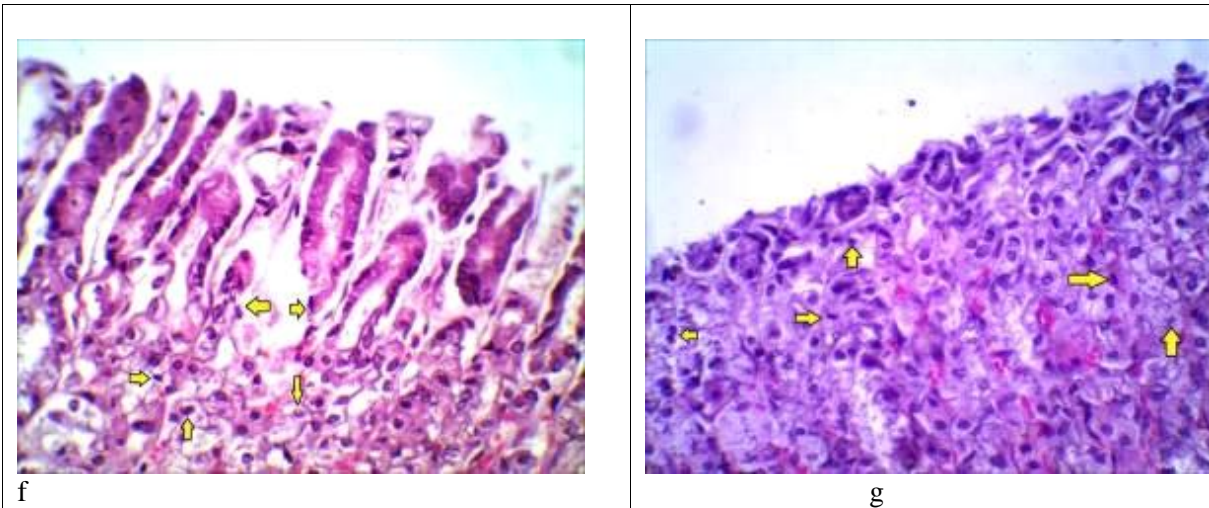


Figure 5: photomicrographs of sections in the stomach of rats of **G5** showing the upper surface of the mucosa which contains many necrotic cells with pyknotic nuclei (yellow arrows) in both the body (f) and the pylorus (g). (H & E x 400).

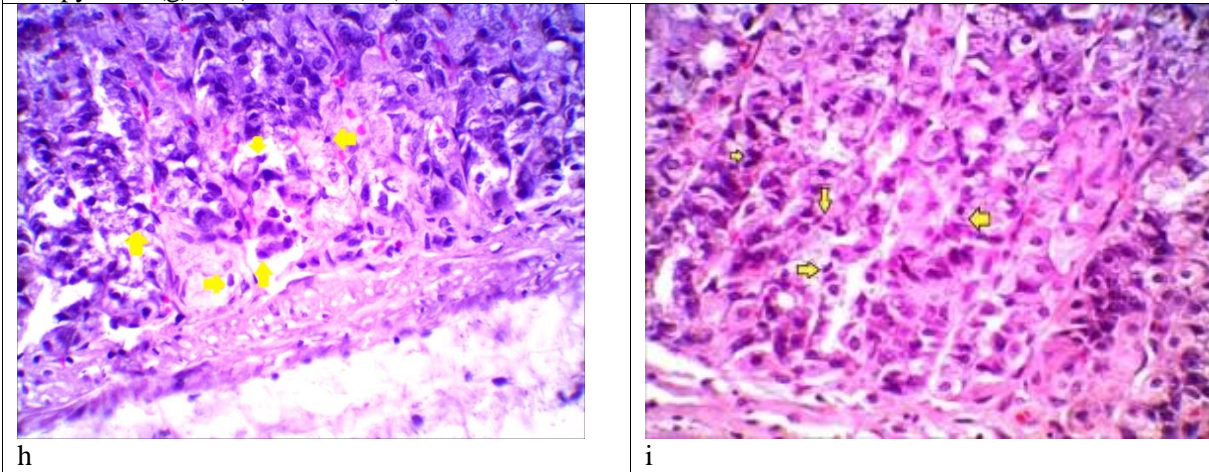


Figure 5: photomicrographs of sections in the stomach of rats of **G5** showing the basal part of the mucosa which contains many necrotic cells with pyknotic nuclei (yellow arrows) in both the body (h) and the pylorus (i) there were no eosinophils in the lamina propria. (H & E x 400).

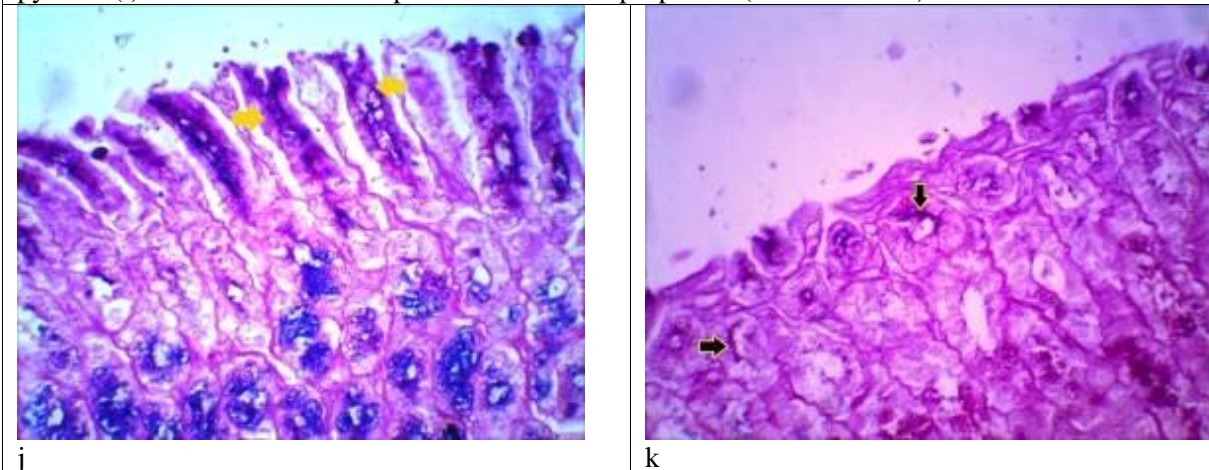


Figure 5: photomicrographs of sections in stomach of rats of **G5**, showing interrupted PAS +ve mucous barrier layer (yellow arrows) in the body (j) and the mucous barrier appears as remnants of PAS +ve reaction (yellow arrows) in the pylorus (k). (PAS & Alcian Blue x 400).

DISCUSSION

Drug administration is one of the most common causes of gastritis occurrence that may be followed with serious complications like bleeding ulcers, anemia and gastric cancers [2,3]. Among that drugs are corticosteroids specially Dexamethasone that has many indications in medicine like rheumatoid arthritis and bronchial asthma [5]. The mechanism by which Dexamethasone causes gastritis is inhibition of prostaglandin synthesis which is essential for formation of the mucous barrier layer. Loss of the mucous barrier makes the stomach mucosa susceptible to the harmful effect of HCl and digestive enzyme pepsin that leads to erosions and ulceration [7].

Pantoprazole prevents HCl formation by blocking of proton pumps in parietal cells of the stomach, so the stomach PH will be elevated which is not favorable for pepsinogen enzymes activation [8].

Pantoprazole leads to elevation of the stomach PH resulting in a syndrome called hypochlorhydria which affect many stomach functions that depend on stomach acidity such as impaired digestion, failure of important minerals absorption like calcium and iron leading to hypocalcaemia, osteomalacia, anaemia, in addition to loss of sterilization ability of the stomach making the gastrointestinal tract susceptible to infections [9,10,21].

Rebamipide is another drug that is used in treatment of gastritis. It's mechanism of action is through stimulation of prostaglandins synthesis, so the mucous barrier can be build up to protect the gastric mucosa [12, 13].

In our work we made a comparative study between Pantoprazole and Rebamipide to evaluate the efficacy of each drug (alone or together) on stomach mucosa protection against the gastritis that was induced by Dexamethasone on the rat's stomach.

We included twenty five male senile albino rats and they were categorized into five groups each group contained five rats.

This study showed that there was a significant reduction of the weights of all the rats which were injected by Dexamethasone. It is a clinical manifestation of gastritis as reported by

Theodoros *et al.* [22]. The greatest percentage of weight loss was in G2, G3 and G5 as they lost 26.66%, 20% and 13.63% of the average weight respectively, the weight loss in G4 was the least among other group, as they lost 9.09% of their average weight and this indicating that Rebamipide alone had the best powerful effect of gastric mucosal protection against the harmful effect of Dexamethasone.

For the gross appearance of the stomach of the rats we found the most severe congestion and gastric mucosal erosions was in rats of G2 group that were given Dexamethasone, so it was a mark for Dexamethasone induced gastritis, these results are in agreement with the results of Bandyopadhyay *et al.* [7].

We also found severe congestion and many ulcers in stomach of rats of G3 that were given Pantoprazole alone and mild to moderate congestion with fewer ulcers in rats of G5 that were given Pantoprazole and Rebamipide, while G4 had apparent healthy mucosa; so these results enforce the thinking about the efficacy of Rebamipide alone in gastric mucosal protection. This result is in agreement with the study of Arakawa *et al.* [12].

Regarding the microscopic examination we noticed disappearance of eosinophils from the lamina propria in all the groups that were injected with Dexamethasone, so it was a guide for us that the dose of Dexamethasone was sufficient as reported by Mullol *et al.* [11].

During examination of G2 group we found disappearance of the mucous barrier as demonstrated by PAS stain. This is in agreement with the results of Bandyopadhyay *et al.* who explained that the mechanism by which the corticosteroids induce gastritis is by affection of the mucous barrier layer [7].

Disappearance of mucous barrier was accompanied by wide spread cell necrosis, nuclear pyknosis and marked decrease in the numbers of viable cells with vesicular nuclei when compared to the control group. In addition to marked blood vessels congestion up to interstitial hemorrhage were noticed in pyloric region, these results are in agreement with those of Allen and Flemström [23] who attributed the serious damage of the

stomach mucosa to the loss or disruption of the mucous barrier layer.

By using of Pantoprazole as a protective drug against Dexamethasone induced gastritis in G3 we found some improvement, in which the mucous barrier had some remnants, its density became stronger. This was accompanied by increased number of vital cells with vesicular nuclei in comparison with G2 that was given Dexamethasone alone, these results indicated that the Pantoprazole gives partial protection against Dexamethasone induced gastritis and this is in agreement with the results of Robinson and Horn [8].

By adding of Rebamipide with Pantoprazole in G5 we found more improvement in which the mucous barrier started to be build up and became more thicker but still interrupted and its density became more stronger, this was accompanied by increase the number of vital cells with vesicular nuclei in comparison with G3 that was given Pantoprazole alone.

This result indicates that combination of Rebamipide with Pantoprazole increases the protection against Dexamethasone induced gastritis.

In our work we noticed presence of frank ulcers containing necrotic tissue in G3 and G5, although there was some improvement in the stomach mucosa when compared to G2 that was given Dexamethasone alone. This notice was explained by Wright et al. [24] who stated that ulcers limit the necrotic areas and spread of tissue damage and leads to the increase in blood flow so encourage mucosal regeneration and repair.

There was marked improvement occurred in G4 that was given Rebamipide alone, the mucous barrier was well formed in the stomach body and pylorus with minimal interruptions, the mucosal barrier thickness increased and the mean optical density was the strongest among the other groups except the control group, the number of vital cells with vesicular nuclei increased also.

This result indicates that the Rebamipide alone can give good protection for the gastric mucosa even without adding proton pump inhibitor, so building up of the mucous barrier was more important for stomach mucosal protection than prevention of HCl secretion; this is in agreement with the results of kawano et al. [15].

CONCLUSION

From our work we concluded that Rebamipide as a single drug has more effective protection of gastric mucosa than Pantoprazole or in combination with Pantoprazole, this may be due to the decrease of acid secretion of the stomach by Pantoprazole and decreasing of its acidic medium which is a natural barrier and defense mechanism against bacteria and microorganisms which might lead to gastritis as reported by Andrew et al. [10]. This assumption is enforced by presence of lymphocytic infiltration in the ulcerated areas.

REFERENCES

1. **Massimo Ruggea B (2011):** Gastritis the histology report. *Digestive and Liver Disease*, 43 (4): 373–384.
2. **Kuipers EJ and Blaser MJ (2007):** Acid Peptic Disease: Epidemiology and Pathobiology. Goldman L, Ausiello D, eds. Cecil Medicine. Philadelphia, P.A. Saunders Elsevier.
3. **Lee Y, Liou J, Wu M, Wu C and Lin J (2008):** Review: eradication of *Helicobacter pylori* to prevent gastroduodenal diseases. *Therapeutic Advances in Gastroenterology*, 1(2):111–120.
4. **Taylor IK and Shaw RJ (1993):** The mechanism of action of corticosteroids in asthma. *Respir. Med.*, 87(4):261–267.
5. **Verhoef C J, van Roon M, Vianen F, Lafeber and Bijlsma J (1999):** The immune suppressive effect of Dexamethasone in rheumatoid arthritis is accompanied by upregulation of interleukin 10 and by differential changes in interferon γ and interleukin 4 productions. *Ann. Rheum. Dis.*, 58(1): 49–54.
6. **Ann E, Nahaczewski B, Fowler S and Hariharan S (2004):** Dexamethasone therapy in patients with brain tumors - A focus on tapering. *J .Neurosci. Nurs.*, 36(6):340-343.
7. **Bandyopadhyay U, Biswasnone K, Bandyopadhyay D, Gangulynone CK and Banerjeenone RK (1999):** Dexamethasone makes the gastric mucosa susceptible to ulceration by inhibiting prostaglandin synthetase and peroxidase - Two important gastroprotective enzymes none. *Mol. Cell Biochem.*, 202:31-46.
8. **Robinson M and Horn J (2003):** Clinical pharmacology of proton pump inhibitors: what the practicing physician needs to know. *Drugs*, 63(24):2739-2754.
9. **Annibale B, G Capurso1, E Lahner, S Passi , R Ricci , F Maggio and (2003):** Concomitant alterations in intragastric pH and ascorbic acid concentration in patients with *Helicobacter pylori* gastritis and associated iron deficiency anaemia. *Gut.*, 52:496-501.

10. **Andrew C, Dukowicz D, Brian E, Lacy D and Gary M (2007):** Small intestinal bacterial overgrowth gastroenterol. Hepatol., 3(2): 112–122.
11. **Mullol J, Xaubet A, and Picado C (1995):** Comparative study of the effects of different glucocorticosteroids on eosinophil survival primed by cultured epithelial cell supernatants obtained from nasal mucosa and nasal polyps. Thorax, 50(3): 270–274.
12. **Arakawa T, Kobayashi K, Yoshikawa T and Tarnawski A (1998):** Rebamipide: overview of its mechanisms of action and efficacy in mucosal protection and ulcer healing. Dig. Dis. Sci., 43:5–13.
13. **Kikuchi S (2002):** Epidemiology of *Helicobacter pylori* and gastric cancer. Gastric Cancer, 5: 6–15.
14. **János G Filep, Ferenc Hermán, Éva Földes-Filep, Ferenc Schneider and Pierre Braquet (1992):** Damage in the rat: possible role of platelet-activating factor. British Journal of Pharmacology, 105 (4) : 912–918.
15. **Kawano S, Sato N, Kamada T, Yamasaki K, Imaizumi T and Komemushi S (1991):** Protective effect of Rebamipide (OPC-12759) on the gastric mucosa in rats and humans. The Japanese Pharmacological Society, 97 (6): 371-380.
16. **Thippeswamy AH, Sajjan M, Palkar MB and Koti BC (2010):** Comparative study of proton pump inhibitors on Dexamethasone plus pylorus ligation induced ulcer model in rats. Short Communication, 72 (3): 367-371.
17. **Gretchen (1979):** Animal Tissue Technique. 4th edition, W.H. Freeman Company. San Francisco U. S. A. pp: 14-15.
18. **Drury RAB and Wallington EA (1980):** Carleton's Histological Technique. Oxford University Press. pp:109-114.
19. **Doggett RG, Bentinack B, and Harrison GM (1971):** Structure and ultra structure of the labial salivary glands in patients with cystic fibrosis. J. Clin. Path., 24:270-282
20. **Schneider CA, Rasband, WS and Eliceiri KW (2012):** NIH Image to Image J, 25 years of image analysis. Nature Methods, 9: 671-675.
21. **Sipponen P and Härkönen M (2010):** Hypochlorhydric stomach: a risk condition for calcium malabsorption and osteoporosis Scand J Gastroenterol., 45(2):133-138.
22. **Theodoros R, Dimitios P and Georgios M (2007):** The long-term impact of *Helicobacter pylori* eradication on gastric histology. Systematic Review and Meta-analysis, 12(2) : 32–38
23. **Allen A and Flemström G (2005):** Gastroduodenal mucus bicarbonate barrier: protection against acid and pepsin. Am. J. Physiol. Cell Physiol., 288: 1–19.
24. **Wright NA, Pike C and Elia G (1990):** Induction of a novel epidermal growth factor-secreting cell lineage by mucosal ulceration in human gastrointestinal stem cells. Nature, 343: 82–85.