

Ultrasound Guided Serratus Anterior Plane Block versus Thoracic Epidural Analgesia in Breast Surgery

Ahmed Elsaied Abd-Elrahman Ali¹, Sherif Kamal Hafez Arafa²,
Amir Abou Zkry Elsayed², Mahmoud Fawzy Shehata El Sharkawy*³

¹Department of Anesthesia and Intensive Care and Pain Medicine, Faculty of Medicine – Sohag University

²Department of Anesthesia and Intensive Care, Faculty of Medicine - Kafr Elsheikh University

³Department of Anesthesia and Intensive Care, Faculty of Medicine - Aswan University

*Corresponding author: Mahmoud Fawzy Shehata, Mobile: (+20) 01011774192, E-Mail: mahmoud83me@gmail.com

ABSTRACT

Background: Breast Surgery is becoming more and more common. Patients are often middle-aged women and with high public awareness around issues of breast cancer. The numbers are increasing. Breast surgery is an exceedingly common procedure and associated with an increased incidence of acute and chronic pain. Regional anesthesia techniques may improve postoperative analgesia for patients undergoing breast surgery.

Objective: To assess the efficacy and safety of ultrasound-guided serratus anterior plane block (SAPB) compared with thoracic epidural analgesia (TEA) for breast surgery. **Patients and methods:** This is a prospective randomized clinical study done at Aswan University Hospitals. The present study was conducted on sixty female patients ASA I-II, their ages ranged from 20-50 years and scheduled for unilateral breast surgery. The patients were allocated randomly into three groups (n=20 each) according to type of regional anesthesia administered. **Results:** There was no significant difference between the studied groups in age, body weight, height and BMI. VAS pain scores throughout the first 24 hrs postoperative showed that there was highly statistically significant decrease in VAS in immediate till 6 hrs postoperative in SAPB group (VAS in group C was less than in groups A and B, P-value < 0.001). As regard to side effects, no complications in the studied groups were recorded such as pneumothorax, vascular puncture, or local anesthetic toxicity. **Conclusion:** Serratus anterior plane block maintained hemodynamic stability as compared to TE and it produced low pain scores and less total morphine consumption in the early postoperative period after unilateral breast cancer surgery. These advantages, suggest the usefulness of SAPB especially in outpatient surgery.

Keywords: Breast Surgery, SAPB, TEA, VAS pain.

INTRODUCTION

Although general anesthesia is the conventional technique used for oncologic breast surgeries and it produces the desired state of unconsciousness, but it does not eliminate the surgical stress response. It may also aggravate immunosuppression and may cause undesirable side effects such as postoperative pain, nausea and vomiting after surgery⁽¹⁾. Opioids, are good option to control postoperative pain, however, these drugs are associated with many side effects such as nausea, vomiting, pruritus, sedation, respiratory depression, delayed channeling, hypotension, urinary retention, as well as immunosuppressive effects and pro-metastatic rule⁽²⁾. The use of regional blocks can not only help to minimize pain, but also improves the pulmonary function and reduce narcotic requirement during the perioperative period⁽³⁾.

Thoracic epidural analgesia is the gold standard technique after breast surgery but the adequacy of thoracic and axillary blockade during lymph node dissection is still a problem⁽⁴⁾.

Currently, thoracic epidural anesthesia (TEA) and thoracic paravertebral block (TPVB) represent the main techniques to manage postoperative analgesia in breast surgery. However, although these techniques allow excellent control of pain, they are not always easy to perform and their clinical effectiveness is limited by the presence of several contraindications, as well as the possible occurrence of systemic side effects or

procedural complications. Literature emphasizes the role of chest wall block in this surgical field as innovative and simple reproducible regional anesthesia (RA) techniques, placed in the context of a multimodal approach⁽⁵⁾.

Blanco *et al.*⁽⁶⁾, first described a new block of the thoracic wall serratus plane block under ultrasound guidance. Local anaesthetic (LA) was deposited in the serratus anterior plane (SAP). The lateral cutaneous branches of the intercostal nerves, before dividing into anterior and posterior branches are blocked as they pass through this plane to supply sensation to the anterolateral chest wall. This novel technique become popular analgesic alternative to multiple puncture intercostals block, epidural and paravertebral block in breast surgery given decreased incidence of adverse events and has the advantage of simultaneous blockade of multiple dermatomes. It is easy to do and decreases rate of local anesthetic absorption⁽⁷⁾. The effectiveness based on our understanding that the brachial plexus nerves are the main component of this painful surgery⁽⁸⁾.

The aim of this study was to assess the efficacy and safety of ultrasound-guided serratus anterior plane block (SAPB) compared with thoracic epidural analgesia (TEA) for breast surgery.

PATIENTS AND METHODS

This is a prospective randomized clinical study done at Aswan University Hospitals.



This article is an open access article distributed under the terms and conditions of the Creative Commons Attribution (CC BY-SA) license (<http://creativecommons.org/licenses/by/4.0/>)

This study was conducted on 60 adult patients scheduled for elective breast surgery divided to equal three groups: Group A (n. 20) received general anesthesia only, group B (n. 20) received combined general anesthesia and thoracic epidural analgesia, by receiving 6–8 ml of 0.25% bupivacaine and 0.05 mg fentanyl via the epidural catheter and group C (n. 20) received serratus anterior plane block combined with general anesthesia

Methods of randomization:

Patients were randomized into three equal groups. An online randomization program was used to generate random number list. Patient randomization numbers were concealed in opaque envelopes which were opened by the study investigator.

Preoperative visit:

One day before surgery all patients were interviewed to explain visual analogue scale (VAS), which is designed to present to the respondent a rating scale in which the respondents mark the location on the 10-centimeter line corresponding to the amount of pain they experienced. This gives them the greatest freedom to choose their pain's exact intensity. It also allows for each respondent to express a personal response style.

Also routine investigations in the form of twelve leads electrocardiography (ECG), complete blood count (CBC), coagulation profile (bleeding time, prothrombin time, international normalized ratio and partial thromboplastin time), liver functions, kidney functions and random blood sugar were fulfilled.

On the day of surgery we also checked if there was any recent change in the patient's condition or therapy particularly one that might affect the surgical event:

- Check that the patient has taken his regular medications.
- Check that the patient fasting for six hours.
- Confirm that the patient has been well since the preoperative assessment visit and does not have any acute illness such as an upper respiratory tract infection.
- The consent form was completed.
- Blood pressure rechecked during preoperative assessment.
- Standard patient monitoring was attached to the patient and an IV access was inserted.

Equipment:

- Ultrasound machine a linear probe of high frequency (6–13 MHz).
- Echogenic needle.
- Tuohy epidural needle 18-gauge (8-10 cm) for thoracic epidural analgesia.
- Drugs – bupivacaine 0.5% vial, xylocaine 2% and fentanyl.

Techniques: One hour before surgery, intravenous access was established and all patients were premedicated with midazolam 0.02 mg/kg.

Monitoring: Noninvasive arterial blood pressure, heart rate (HR), and peripheral oxygen saturation (SpO₂) values were recorded before and after intubation, after

skin incision, after 15 min, 30 min, 1h and 2 h from the start of the operation, and after extubation.

Postoperative:

Postoperative assessment was recorded immediately postoperatively (0, 30, 60 min.) and 2, 4, 6, 8, 12 and 24 hr by the following data:

1. Visual analogue scale (VAS) both relaxed and stressed for pain intensity ranged from 0 = no pain, up to 10 = the worst imaginable pain (Figure 1).

The mark corresponds to the level of pain intensity the patient presently felt at that moment. The distance in cm from the low end of the (VAS) to the patient's mark was used as numerical index of the severity of pain.

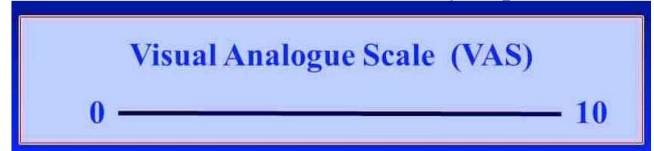

Fig. (1): Visual analogue scale one of universal pain assessment tool.

2. Vital signs: Arterial blood Pressure, heart rate, respiratory rate and arterial oxygen saturation
3. Postoperative nausea and vomiting (PONV) using a 5-point scale (0–4), where 0 = no nausea or vomiting, 1 = mild nausea, 2 = severe nausea (interfere with daily activities as going out of bed), 3 = vomiting once, and 4 = vomiting more than once.
4. Analgesic requirement.
5. Time for 1st dose of analgesia through (2-6) hr.

Postoperative analgesia:

All patients of both groups received paracetamol intravenously just after transferring to ward and every 8 hours. Patients with VAS score 3 or more received 3 mg morphine intravenously as rescue analgesia.

Ethical approval and written informed consent:

An approval of the study was obtained from Aswan University Academic and Ethical Committee. Every patient signed an informed written consent for acceptance of the operation.

Statistical Analysis:

Recorded data were analyzed using the statistical package for the social sciences, version 20.0 (SPSS Inc., Chicago, Illinois, USA). Quantitative data were expressed as mean±standard deviation (SD) and range. Qualitative data were expressed as frequency and percentage. Chi-square (X²) test of significance was used in order to compare proportions between two qualitative parameters. The confidence interval was set to 95% and the margin of error accepted was set to 5%. A p-value < 0.05 was considered statistically significant.

RESULTS

The difference in patients' demographics, with respect to age, body weight, height and BMI, was not significant between the studied groups (Table 1).

Table (1): Comparison between groups according to demographic data

	Group A	Group B	Group C	P. value
Age				
Mean±SD	30.6±8.6	34.7±8.18	34.7±8.18	0.207
Range	20 – 45	22 - 50	22 - 50	
Weight				
Mean±SD	76.6±6.82	74.2±6.52	76.3±6.87	0.475
Range	65 – 85	65 - 85	65 - 85	
Height				
Mean±SD	1.68±0.08	1.69±0.08	1.71±0.05	0.550
Range	1.5 - 1.79	1.5 - 1.8	1.64 - 1.8	
BMI				
Mean±SD	27.13±2.09	25.98±2.32	26.24±2.08	0.217
Range	24.17 - 31.11	23.31 - 30.48	23.31 - 30.48	

There was significant increase in systolic blood pressure in group B than group C 15 min after block (Table 2).

Table (2): Comparison of systolic pressure between the 3 groups

Systolic	Group A	Group B	Group C	P. value
	Mean±SD	Mean±SD	Mean±SD	
Baseline	126.6±9.43	125.77±8.16	124.7±4.68	0.425
5 min.	126.5±9.33	126.27±8.16	124.5±5.38	0.412
After skin incision	130.6±10.48	125.87±8.12	124.3±5.17	0.021*
15 min.	130.2±7.45	124.7±4.68	124.1±3.98	0.003**
1 hr	128.2±10.66	124.9±5.38	123.9±3.89	0.098
End of surgery	127.53±5.25	125.7±5.78	125.12±6.58	0.208

There was also significant increase in diastolic blood pressure in group B than group C 15 min after block (Table 3).

Table (3): Comparison of diastolic pressure between the 3 groups

Diastolic	Group A	Group B	Group C	P. value
	Mean±SD	Mean±SD	Mean±SD	
Baseline	76.3±6.12	75.07±7.3	74.13±7.65	0.328
5 min.	76.7±6.32	76.9±7.9	74.53±7.84	0.347
After skin incision	79.65±8.45	76.02±7.12	74.19±7.92	0.042*
15min.	79.85±8.65	75.55±7.42	73.09±6.82	0.009**
1hr	76.3±6.12	75.14±7.33	73.45±7.01	0.179
End of surgery	75.77±6.75	75.65±7.80	74.02±7.42	0.440

VAS pain scores throughout the first 24 hrs postoperative (Figure 2) showed that there was highly statistically significant decrease in VAS in immediate and 6 hrs postoperatively in SAPB group (VAS in group C less than in group A, B, P-value < 0.001).

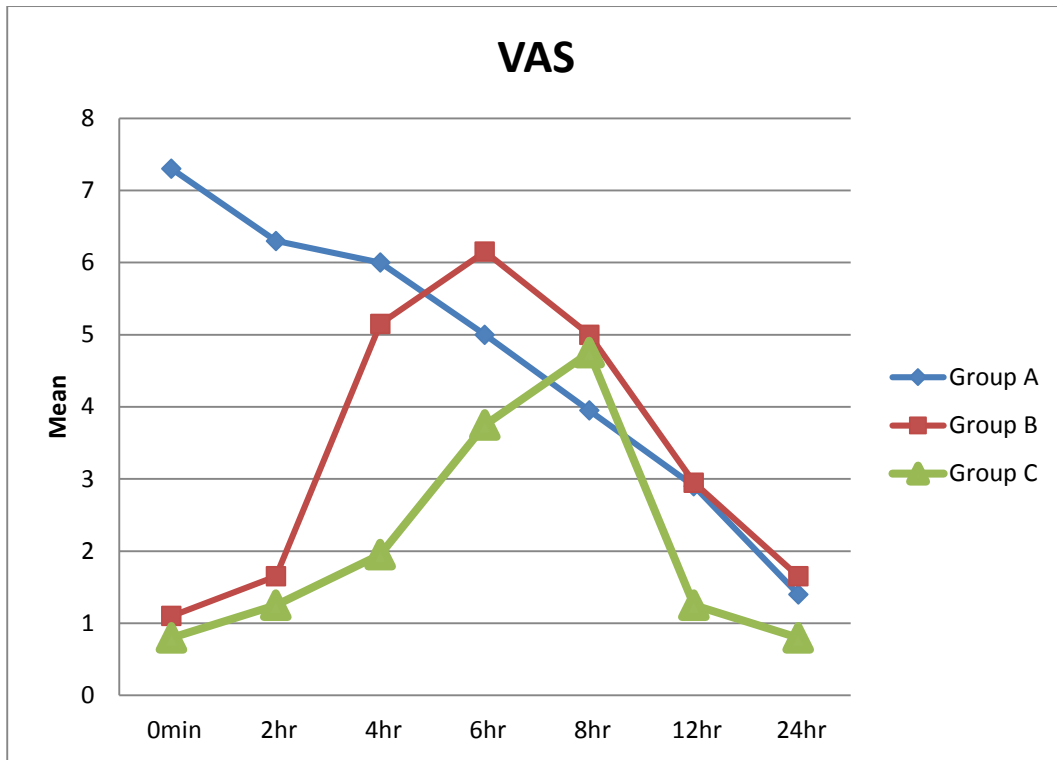


Fig. (2): Line chart between groups according to VAS.

Postoperative analgesia:

The duration from the end of surgery to the first request for analgesia was significantly prolonged in SAPB group (Table 4).

Table (4): Time for the first analgesic dose (min)

	Group A	Group B	Group C	P. value
Time for the first analgesic dose (min)				
Mean±SD	0±0	240±15	360±25	<0.001**

As regard to total dose requirement, table 5 shows that the total dose significantly decreased in group C in comparison to other groups. Table (5) shows also that analgesic requirement started after 6 hr in group C and 4 hr in group B and immediately after extubation in group A.

Table (5): Comparison of given-dose between the 3 groups

Dose	Group A	Group B	Group C	P. value
	Mean±SD	Mean±SD	Mean±SD	
0 min	10.8±0.62	0±0	0±0	-
2 hr	10.3±0.80	0±0	0±0	-
4 hr	10.1±0.64	8.8±0.41	0±0	<0.001**
6 hr	9.85±0.67	9±0	5.2±0.41	<0.001**
8 hr	9.22±0.43	8.8±0.41	5.45±0.51	<0.001**
12 hr	9.21±0.43	8±0	0±0	<0.001**
24 hr	9±0	8±0	0±0	-

PONV showed no significant difference between groups as in post-anesthetic care unit (PACU) there are 2 patients in group C had nausea and vomiting and 3 patients in group B had nausea and 4 patients in group A postoperatively (P value 0.676) which is not statistically significant (Figure 3).

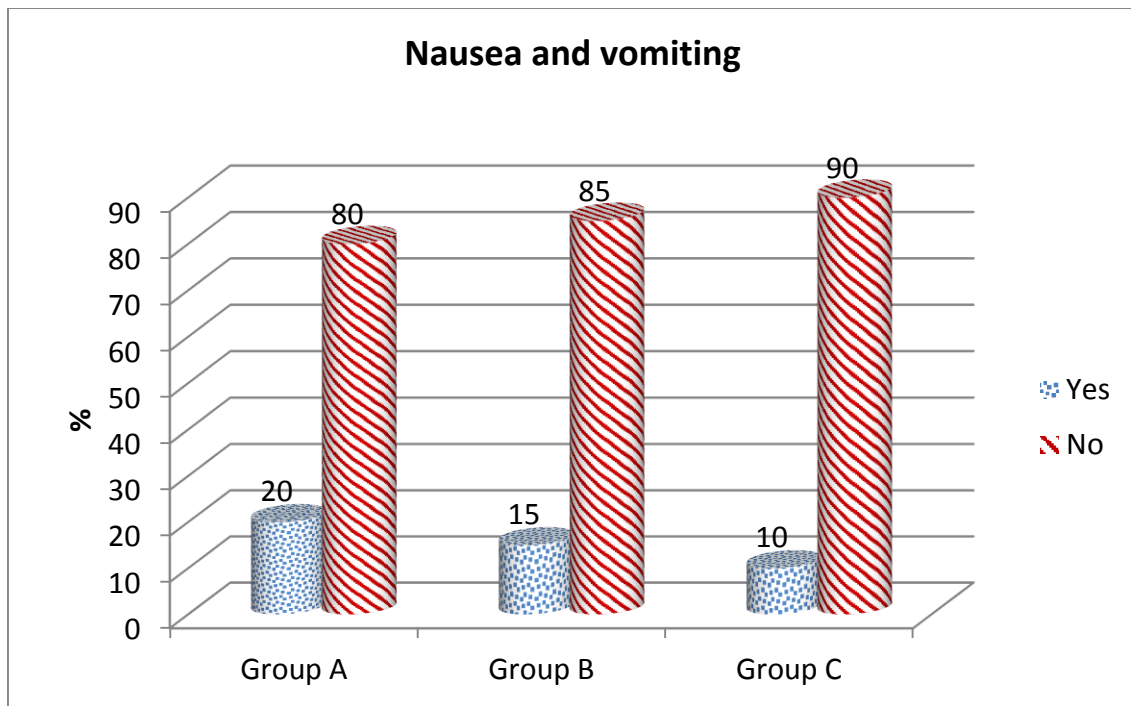


Fig. (3): Bar chart between groups according to nausea and vomiting.

DISCUSSION

In this study pain scores assessed by VAS and the results showed that patients with SAPB experienced less intense pain at 2 hrs, 4 hrs and 6 hrs postoperatively than TEA group with highly statistically significant decrease of VAS in SAPB group. This current study goes with **Khalil et al.**⁽⁹⁾ who compared the ultrasound guided serratus anterior plane block versus thoracic epidural analgesia for thoracotomy pain. The authors found that, the mean arterial pressure in the SAPB group did not change significantly ($p = 0.181$), whereas it decreased significantly ($p = 0.006$) in TEA group. This was attributed to the autonomic block that accompanies paravertebral and epidural blocks, which is not present in SAPB.

In the present study, the efficacy of the SAPB and TEA for analgesic consumption were investigated and the results showed in SAPB group reduced amount of morphine consumption (5.33 ± 47 mg) during the first 24 hours postoperative while in TEA the amount was (8.66 ± 0.48 mg) with a P-value < 0.001 . Where an adequate VAS score of less than 3 was maintained by paracetamol 1 gm intravenously every 8 hours just after transferring to ward for all patients. In agreement with this study **Zhou et al.**⁽¹⁰⁾ found that the patients in the SAPB group required significantly lower total dosages of morphine and tramadol during their first postoperative hour in the PACU than the patients who received the standard pain control protocol.

Also this current study goes with **Hards et al.**⁽¹¹⁾ who studied the effect of serratus plane block performed under direct vision on postoperative pain in breast surgery. The study included 16 patients who had

received a serratus block and 11 patients who only had wound infiltration with levobupivacaine with adrenaline and clonidine. Results demonstrated excellent pain control in patients who had received a serratus plane block under direct vision day 1 postoperatively compared to the control group with 81% experiencing mild pain or no pain at all. All of these patients required no analgesia or only simple analgesia day 1 postoperatively

All of these studies and their results are because TE block produces a dense block of the T2-T6 spinal nerves and the intercostal nerves and all lateral and anterior cutaneous branches but not anesthetize the LPN (C5-C7), the MPN (C8-T1), the long thoracic nerve (C5-C7) or the thoracodorsal nerve (C6-C8) that are blocked by SAPB leading to adequate analgesia.

In contrast to this study; the studies done by **Davies et al.**⁽¹²⁾ and **Júnior et al.**⁽¹³⁾. They compared the analgesic efficacy of epidural blockade versus paravertebral for thoracotomy. They found insignificant difference in pain scores between PVB and epidural groups at 4–8 or 24 hours in the postoperative period. Also, a study done by **Soni et al.**⁽³⁾ found that the quality of analgesia in immediate and 1 hr postoperatively were similar in epidural and paravertebral group. For epidural group it was (0.47 ± 0.49) and (1.2 ± 1.24) respectively. In paravertebral group the values were (0.53 ± 0.56) and (1.03 ± 1.17) respectively. The p-values were 0.323 and 0.304 respectively.

Also a study done by **Moore**⁽¹⁴⁾, who used ultrasound-guided SAPB in the management of post-thoracic surgery acute pain. He found that this block is

easy to perform, has a high success rate, and carries minimal complications when performed by an anesthesiologist who is skilled in ultrasound-guided blocks. SAP block usually requires only a single injection compared to most other regional blocks that often require multiple injections. The duration of thoracic surgery was significantly longer in the patients who received SAP block than in the control patients; where mean procedure duration in the block group (142.67 ± 10.2) vs (111.54 ± 15.1) minutes in the control group ($P=0.04$), but on the other hand, patients benefited by experiencing significantly less pain during the first eight postoperative hours and by requiring lower opioid dosage during that period.

Appropriate analgesia after thoracic surgery results in earlier extubation, improved ventilatory mechanics and gas exchange, and reduced rates of postoperative atelectasis, pneumonia and pain. Also this study goes with **Shokri and Kasem** ⁽¹⁵⁾ who compared the efficacy of postsurgical ultrasound guided SAP block and wound infiltration on postoperative analgesia after female breast surgeries. This study was conducted on 46 female patients undergoing breast surgeries. Patients were divided into two groups: serratus block (SB) group ($n = 23$): patients received induction with serratus intercostal plane block with 0.4 ml/kg bupivacaine 0.25% plus fentanyl 20 ug, and infiltration group ($n = 23$) received induction with the borders of the surgical wound were infiltrated with 0.4 ml/ kg of bupivacaine 0.25% and 20 ug fentanyl at the end of surgery. VAS pain scores, postoperative patient satisfaction score, time to the first analgesic requirement, total dose of rescue analgesic and the incidence of postoperative complications as vomiting were all recorded. Results showed that intraoperative pain scores and postoperative patient satisfaction scores were significantly lower in group SB compared with infiltration group. Total dose of rescue analgesic was significantly lower in SB group compared with infiltration group.

In this study ⁽¹⁵⁾ hypotension occurred in patients with TE group after (15 min) of the block without occurrence in SAPB group (p -value < 0.08). The decrease in mean arterial pressure (MAP) was treated with IV fluid and ephedrine in incremental dose. Also a bradycardia developed in TEA group after (15 min) of the block but not in SAPB group with (p -value < 0.006). The decrease in heart rate was managed by atropine IV (0.01mg/kg) the incidence of hypotension and bradycardia were correlated with bilateral sympathetic block in epidural group.

The results also run parallel to the study done by **Kumar and Rajendran** ⁽¹⁶⁾ in thoracotomy, they reported that 50% of patients showed hypotension in epidural group and 8% paravertebral group and explained their finding by bilateral sympathetic blockade in epidural block and unilateral sympathetic

blockade in paravertebral block ⁽¹³⁾. In meta-analysis study reported that epidural anesthesia was associated with a higher incidence of hypotension compared to paravertebral block. **Oktavia** ⁽²⁾ found that hypotension (80%), bradycardia (40%) was more frequent in TEA. **Lahiry et al.** ⁽¹⁷⁾ found that the incidence hypotension (13.3%), bradycardia (16.6%) in the TEA. **Rajan et al.** ⁽¹⁸⁾ reported that the incidence of hypotension was 8 (26.6%), bradycardia 6 (20%) in the TEA.

On the other hand, in disagreement with our study **Lahiry et al.** ⁽¹⁷⁾ found that there was no statistically significant difference in the hemodynamic parameters of thoracic epidural when compared with general anesthesia (GA) in modified radical mastectomy (MRM) patients. This may be due to selective sympathectomy in TE and the potential to dilate the constricted coronary vessels and reduction of the cardiac workload as well as optimization of the myocardial oxygen delivery have a positive impact on the cardiovascular status. Also **Doss et al.** ⁽¹⁹⁾ found that hypotension and bradycardia, were mild ($< 10\%$ of the baseline) in thoracic epidural patients when compared with GA using 0.2% ropivacaine for perioperative management of modified radical mastectomy. This may be explained by the use small concentration of the local anesthetic to produce a full sensory anesthesia sufficient for the surgery with minimal hemodynamic effect as surgery of the breast does not require motor blockade.

In the present study, as regard to side effects, no complications in the studied groups were recorded such as pneumothorax, vascular puncture, or local anesthetic toxicity.

Postoperative nausea and vomiting, (PONV) can result in serious adverse effects extending the duration of hospital care with decreased patient satisfaction. In this study the difference in PONV between the 3 groups was not significant. Also the study done by **Biswas et al.** ⁽²⁰⁾ found that the incidence of nausea and vomiting was similar in epidural and paravertebral in thoracotomy patients. The use of opioid with LAs infusion may be explained the similarity of the incidence. **Khalil et al.** ⁽⁹⁾ study reported only one case of nausea in the SAPB group.

CONCLUSION

Serratus anterior plane block maintained hemodynamic stability as compared to TE and it produced low pain scores and less total morphine consumption in the early postoperative period after unilateral breast cancer surgery. These advantages, suggest the usefulness especially in outpatient surgery.

Finally, we recommend that future studies are needed using larger number, higher concentration or using local anesthetic adjuvant to increase the duration and intensity of analgesia.

REFERENCES

1. **Cowie B, McGlade D, Ivanusic J et al. (2010):** Ultrasound-guided thoracic paravertebral blockade: a cadaveric study. *Anesthesia & Analgesia*, 110(6):1735-9.
2. **Oktavia E (2015):** A comparative study between thoracic epidural anesthesia and general anesthesia for patients who underwent modified radical mastectomy with axillary lymph node dissection in de la salle university medical center. *The Indonesian Biomedical Journal*, 7(2):111-6.
3. **Soni S, Soni A, Bapugol M et al. (2015):** Comparison of thoracic epidural block vs paravertebral block in patients undergoing breast surgery. *Indian Journal of Clinical Anaesthesia*, 2(1):48-56.
4. **Wahba S, Kamal S (2014):** Thoracic paravertebral block versus pectoral nerve block for analgesia after breast surgery. *Egyptian Journal of Anaesthesia*, 30(2):129-35.
5. **Maxwell C, Nicoara A (2014):** New developments in the treatment of acute pain after thoracic surgery. *Current opinion in Anesthesiology*, 27(1):6-11.
6. **Blanco R, Parras T, McDonnell J et al. (2013):** Serratus plane block: a novel ultrasound-guided thoracic wall nerve block. *Anaesthesia*, 68(11):1107-13.
7. **Fajardo M, López S, Diéguez P et al. (2013):** A new ultrasound-guided cutaneous intercostal branches nerves block for analgesia after non-reconstructive breast surgery. *Cirurgia Mayor Ambulatoria*, 18:3-6.
8. **Mukherjee M, Goswami A, Gupta S et al. (2010):** Analgesia in post-thoracotomy patients: Comparison between thoracic epidural and thoracic paravertebral blocks. *Anesthesia, Essays and Researches*, 4(2):75-80.
9. **Khalil A, Abdallah N, Bashandy G et al. (2017):** Ultrasound-guided serratus anterior plane block versus thoracic epidural analgesia for thoracotomy pain. *Journal of Cardiothoracic and Vascular Anesthesia*, 31(1):152-8.
10. **Zhou Y, Huang J, Lu X et al. (2015):** Patient-controlled intravenous analgesia for non-small cell lung cancer patient after thoracotomy. *Journal of Cancer Research and Therapeutics*, 11(5):128-133.
11. **Hards M, Harada A, Neville I et al. (2016):** The effect of serratus plane block performed under direct vision on postoperative pain in breast surgery. *Journal of Clinical Anesthesia*, 34:427-31.
12. **Davies R, Myles P, Graham J (2006):** A comparison of the analgesic efficacy and side-effects of paravertebral vs epidural blockade for thoracotomy—a systematic review and meta-analysis of randomized trials. *BJA: British Journal of Anaesthesia*, 96(4):418-26.
13. **Júnior A, Erdmann T, dos Santos T et al. (2013):** Comparison between continuous thoracic epidural and paravertebral blocks for postoperative analgesia in patients undergoing thoracotomy: systematic review. *Brazilian Journal of Anesthesiology (English Edition)*, 63(5):433-42.
14. **Moore D (1981):** Intercostal nerve block: spread of india ink injected to the rib's costal groove. *British Journal of Anaesthesia*, 53(4):325-9.
15. **Shokri H, Kasem A (2017):** Efficacy of postsurgical ultrasound guided serratus intercostal plane block and wound infiltration on postoperative analgesia after female breast surgeries. A comparative study. *Egyptian Journal of Anaesthesia*, 33(1):35-40.
16. **Kumar T, Rajendran R (2003):** Comparative evaluation of thoracic epidural versus thoracic paravertebral block for post thoracotomy pain relief with 0.25% bupivacaine. *Indian Journal of Anaesthesia*, 47(4):269.
17. **Lahiry S, Sharma D, Mund M et al. (2016):** Thoracic epidural versus general anaesthesia for MRM surgeries. <http://www.informaticsjournals.com/index.php/ijmnds/article/view/19015>
18. **Rajan R, Gosavi S, Ninave S (2016):** Upper Thoracic Epidural vs General Anaesthesia for MRM surgeries. *International Journal of Biomedical Research*, 7(10):718-20.
19. **Doss N, Ipe J, Crimi T et al. (2001):** Continuous thoracic epidural anesthesia with 0.2% ropivacaine versus general anesthesia for perioperative management of modified radical mastectomy. *Anesthesia & Analgesia*, 92(6):1552-7.
20. **Biswas S, Verma R, Bhatia V et al. (2016):** Comparison between thoracic epidural block and thoracic paravertebral block for post thoracotomy pain relief. *Journal of Clinical and Diagnostic Research*, 10(9):8-13.