 DOI: 10.21608/ADJALEXU.2021.144906

EVALUATION OF CHITOSAN/HYDROXYAPATITE SCAFFOLD ON THE HEALING OF OSSEOUS DEFECTS IN JAW BONES

(CLINICAL STUDY)

Dina M. Abd EL Hafez[1] *BDS*, Tarek M. Ali[2] *PhD*, Adham A. El Ashwah[3] *PhD*

ABSTRACT

INTRODUCTION: The repair and replacement of injured or defective bone is a critical problem in orthopedic treatment. Bone defects in the maxillofacial region are considered a serious health problem. The correct restoration of architecture and function of tissues of this important anatomical region is mandatory. A variety of methods are employed for treating such defects, however, each of the strategies has its own drawbacks. Significant development has been achieved with combining bioceramics and biopolymers. Chitosan/ nano-Hydroxyapatite (CH/nHA) has recently emerged a new strategy for promoting bone regeneration and enhancement of bone healing and remodeling. This composite has increased cell adhesion, cell proliferation, mechanical strength, alkaline phosphatase activity, protein adsorption, type I collagen production as well as expression of other osteogenic differentiation markers.

OBJECTIVES: The aim of the present study is to assess the effectiveness of using Chitosan/ nano-Hydroxyapatite composite on healing and regeneration of bony defects of the jaws radiograhicaly by the aid of Cone beam computed tomography.

METHODOLOGY: This study was performed on 14 patients having bone defects in their maxilla or mandible due to cysts or tumors. Patients were divided into two groups; test group in which patients had removal of bone lesion leaving bone defects treated with Chitosan/nano-Hydroxyapatite, and control group in which bone defects were left to heal spontaneously. Bone defects were examined radiographically using Cone beam computed tomography.

RESULTS: A significant increase in bone density in bone defects treated with Chitosan/nano-hydroxyapatite, as well as significant decrease in bone defect size.

KEYWORDS: Chitosan/ nano-hydroxyapatite, bone defect, bone regeneration.

1- BDS, MS, Faculty of Dentistry, Alexandria University.
2- Professor of Oral and Maxillofacial Surgery, Faculty of Dentistry, Alexandria University.
3- Assistant Professor of Oral and Maxillofacial Surgery, Faculty of Dentistry, Alexandria University.

**Corresponding author*
dinamorsy57@yahoo.com

INTRODUCTION

Bone injuries and defects are severe health complications particularly those caused by complex breaks and pathological fractures arising from malformation, osteoporosis, cysts and tumors. It is considered to be a significant problem in dental treatment and rehabilitation. Despite recent advances in regenerative medicine, reconstruction of maxillofacial defects remains a challenge (1-3).

Bone is able to heal fractures or other local defects with regenerated tissue of equally high structural organization, and without leaving a scar. Nevertheless, spontaneous healing capacity of injured bone has limitations, leaving the idea of critical size defects (CSD) that require adequate therapeutic interventions (4).

Autograft and allograft are considered to be ideal procedures for bone grafting. However, both grafting procedures have their disadvantages such as insufficient donor site, secondary operation, and transmissible diseases (HIV and hepatitis) (5). Consequently, numerous techniques and biomaterials have been employed for orthopedic treatment for the past several decades to overcome these limitations (6).

Tissue engineering (TE) is considered to be an important therapeutic strategy for present and future medicine. It has been used during the last 10 years, offering potential

regeneration of tissues and organs in the human body. Its main goal is to restore, regenerate, maintain, and improve function of defective or lost tissue. Bone tissue engineering (BTE) offered new techniques through using biologic substitutes as biopolymers, and bioceramics that induce bone regeneration (7). One of the best-known biopolymers used in the field of dentistry is chitosan (CH) (8), and one of the best known bioceramics is Hydroxyapatite (HA) (9).

CH is a chitin derivative made of β-1, 4-linked polymer of glucosamine (2-amino-2-deoxy-β-D-glucose) and small amounts of N-acetylglucosamine (10). It has unique properties, such as its ability to be biocompatible with human tissues, nontoxic, biodegradable, osteoconductive, bioactive, has antimicrobial properties, and possesses mechanical and functional properties that support bone and cartilage tissue regeneration (11,12). Moreover, it reduces the operation time, scar size, postoperative pain, and also, improves patient recovery (13). CH became an important ingredient in medicine and medical industries (14).

However, CH scaffolds alone cannot imitate all the properties of natural bone as CH is not osteoinductive. So, the need for another material that mimics the inorganic portion of the tissues became important. Consequently, the composite of CH mixed with bioceramics were introduced (5).

As proven Hydroxyapatite (HA) is one of the best known bioceramics that has osteoconductive as well as osteoinductive properties (15). The biocompatibility and similarity of HA to the mineral composition of the bone has made it a potential candidate in bone tissue engineering showing promising outcomes in the field of dentistry (16). Despite the fact that HA is considered as one of the most attractive inorganic materials for applications in bone regenerative medicine. However, due to the inherent brittleness and very slow degradation rate, its applications are strictly limited when fabricated into porous structures. Therefore, its hybridization with biodegradable polymers has been widely adopted to transform the bioactivity and mechanical properties of the resulting materials for orthopedic applications (17-19). Hence, the composite of CH/HA was introduced as a bone graft substitute (20).

One of the major biomedical composites used in bone repair and bone regeneration is chitosan/nanohydroxyapatite (CH/nHA) (21,22). It has been shown to increase cell adhesion, cell proliferation, mechanical strength, alkaline phosphatase activity, protein adsorption, type I collagen production as well as expression of other osteogenic differentiation markers. It was proved that CH/nHA is a bioactive scaffold that plays a critical role in the development of a completely synthetic, readily accessible, and osteogenic bone substitute that may be considered as a great milestone in the dental clinical field (23).

MATERIALS AND METHODS

Study design

The study design was a simple random sample technique (clinical trial**)** that was conducted on fourteen patients having osseous defects due to bone lesion (cyst or tumor) in their maxilla or mandible measuring from 1cm to 3cm. Patients participated in the study were selected randomly from those attending the outpatient clinic in the Oral and Maxillofacial Department, Faculty of Dentistry, Alexandria University.

The research protocol was approved by the Ethical Committee of the Alexandria University, and an informed consent was obtained from each patient after providing detailed information and description of the study.

Patients were informed about the treatment procedures and follow up examinations. Informed consent was filled out of each patient in accordance with the regulation of Ethics Committee in Faculty of Dentistry, Alexandria University.

These patients were divided into two equal groups:

Group I (Test group): In which the patient undergone removal of the lesion and curettage to the affected bone, then application of CH/nHA composite grafting material.

Group II (Control group): In which the patient undergone removal of the pathology and curettage of the affected bone, then left to heal spontaneously.

Criteria for patient selection includes patients having of cyst or tumor mass measuring from (1-3cm) in the maxilla or mandible, patient's age between 20and 50 years, non-smokers, systemically free of chronic diseases passively affecting healing such as diabetes mellitus, or immunosuppressive diseases, and they should be psychologically accepting the procedures. Patients excluded from this study were uncooperative patients regarding oral hygiene measures, patients having bone disease as osteoporosis, and pregnant or lactating women.

Materials

Chitosan (CH) was prepared with deacetaylation degree of ≥85%, and Hydroxyapatite (HA) was prepared in nanoparticles, the ratio of CH/nHA was 70/30 based on the protocol proposed by **Escobar-Sierra and Martins (2015)** (24). Both materials were prepared by the aid of NanoTech Company. The prepared material was sterilized by plasma sterilization using STERRAD® 100NX® sterilization system. (Figure 1)

Characterization of CH/nHA was done using Scanning electron microscope (SEM), and Transmission electron microscope (TEM). SEM image of CH/nHA showed the material internal microstructure. The scaffold revealed almost spherical, interconnected, regular particles, with size ranging from 10-400 µm. The nHA particles were homogeneously embedded like islands within a high density on the surface of CH particles. TEM showed the morphology and the pore size of nHA particles showed they are mostly rod or needle-like in shape with uniform size. The average particle length the rods were less than 100nm, and their diameter was ranging from 20-25 nm. (Figure 2)

Figure (1): Chitosan/nanohydroxyapatite sterilized by STERRAD® 100NX® Plasma Sterlization System.



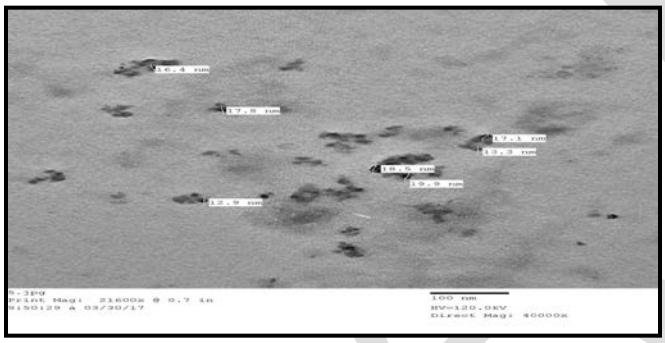

Figure (2): Scanning electron microscope (SEM) illustrating CH that revealed almost spherical, interconnected, regular particles, with size ranging from 10-400 µm, (X 2000) and Transimission Electron Microscope (TEM) illustrating the morphology and size of nHA particles showing mostly rod or needle-like shape with uniform size. The average particle length the rods were less than 100nm, and their diameter was ranging from 10-20 nm.

Methods

1. Preoperative phase

A. Clinical examination

Comprehensive history was taken and all the patients were subjected to a complete intraoral and extraoral examination. History taking includes chief complaint, duration of the lesion, cause of the lesion, site of the lesion, history of previous interventions, history of any type of medication, as well as past medical and dental history, and any other accompanying signs and symptoms. Clinical examination includes extra-oral and intraoral examination by inspection and palpation. Inspection for determining anatomical site of the lesion, size, shape, surface color and texture, facial asymmetry, single or multiple neck mass, as well as examination of oro-pharynx, tongue, floor of the mouth, palate and oral mucosa. Palpation for determining consistency, tenderness, fluctuation, definition of boundaries, pulsation, mobility of the skin or mucosa overlying the lesion, and also lymph nodes examination. All patients were examined by their own physician to exclude any systemic disease contraindicating local anesthesia or surgery. In addition, they were examined for local factors contraindicating grafting or any known hypersensitivity to one of the grafting materials.

B. Radiographical examination

- **Orthopantomogram (OPG)** was taken for all patients to evaluate the size, site, shape, extension and relation to the important structures of bony defects.
- **Cone beam computed tomography (CBCT):** was performed using the high-resolution imaging system 3D J. Morita, to assess the exact site and dimensions of the lesion, also to determine bone density of bone at the site of the lesion. The slice thickness will be set at 0.5 mm, and the pitch will be set at 0.125 mm. Measurements were done to the nearest 0.5 mm using the On Demand 3D software by Cybermed Inc. with a linear measurement tool and a digital magnification lens (20). The radiographic examination using cone beam computed tomography (CBCT) will be performed at the baseline, immediate post-operative, and after six months for follow up.

C. Phase 1 therapy

Scaling and root planning were done to improve oral hygiene prior to surgery. Coronoplasty was done to eliminate trauma from occlusion, if present. Oral hygiene instructions were given to the patients which include teeth brushing using a proper technique 3 times daily. Root canal treatment if needed to teeth related to the periapical lesion.

2. Operative phase (Figure 3)

The operation was performed under local anaesthesia (mepivacaine HCL 2% levonordefrin 1:20000 Alexandria Company for pharmaceuticals, Alexandria, Egypt). A mucoperiosteal flap was incised using Bard-Parker blade no. 15. A full thickness mucoperiosteal flap was reflected with a periosteal elevator atraumatically without laceration. The bone was exposed and the lesion was enucleated or removed. The cavity was curetted using a bone curette to remove any remaining tissues. The wound was irrigated with 0.9% normal saline. CH/nHA was applied in the bony defect in the test group. The flap was repositioned after trimming, and then sutured with Prolene sutures.

3. Post-operative phase

Post-operative instructions were given to the patients including oral hygiene instructions. Postoperative medications

including Postoperative medications including Amoxicillin clavulanate (Augmentin: manufactured by Galaxo Smith Kline, Brentford, United Kingdom) 1 gm; 1 capsule every 12 hours for 5 days and non-steroidal anti-inflammatory drugs: ibuprofen (BRUFEN: manufactured by Abbott, Chicago, USA) 1400 mg, 1 tablet 3 times daily after meals for 4 days. At the day of surgery all patients were advised to apply ice bags on the site of operation for half an hour, five minutes ice applications and five minutes rest. On the second post-operative day of surgery, the patients were instructed to use warm mouthwash three times daily. Sutures were removed ten days post surgically. An immediate CBCT was done at the day of surgery, another one was made after six months for follow up, in order to measure the dimensions of bone defect and density of bone determined at the surgical site. (Figure 4)

Statistical analysis

Data were fed to the computer and analyzed using IBM SPSS software package version 24.0 (Armonk, NY: IBM Corporation). Student t-test was used to compare two groups for normally distributed quantitative variables. F-test (ANOVA) for normally distributed quantitative variables, to compare between more than two groups, and Post Hoc test (Tukey) (LSD) for pairwise comparisons. Paired t-test for normally distributed quantitative variables, to compare between two periods.

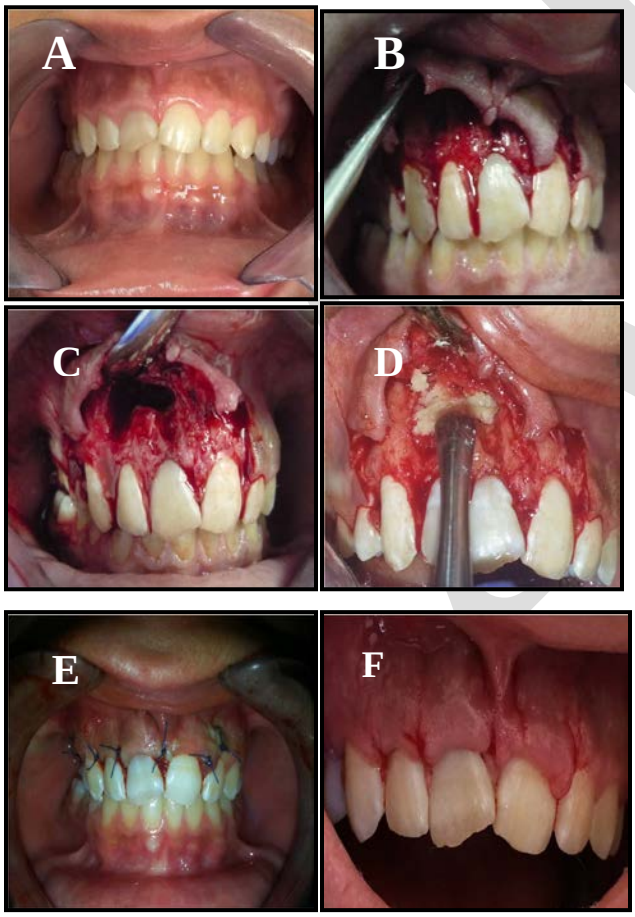

Figure (3): (a) preoperative view, (b) mucoperiosteal flap incision, (c) removal of bone pathology and curettage of bone, (d) application of chitosan/ nano-Hydroxyapatite into bone defect, (e) suturing of mucoperiosteal flap, (f) follow up after 2 weeks.

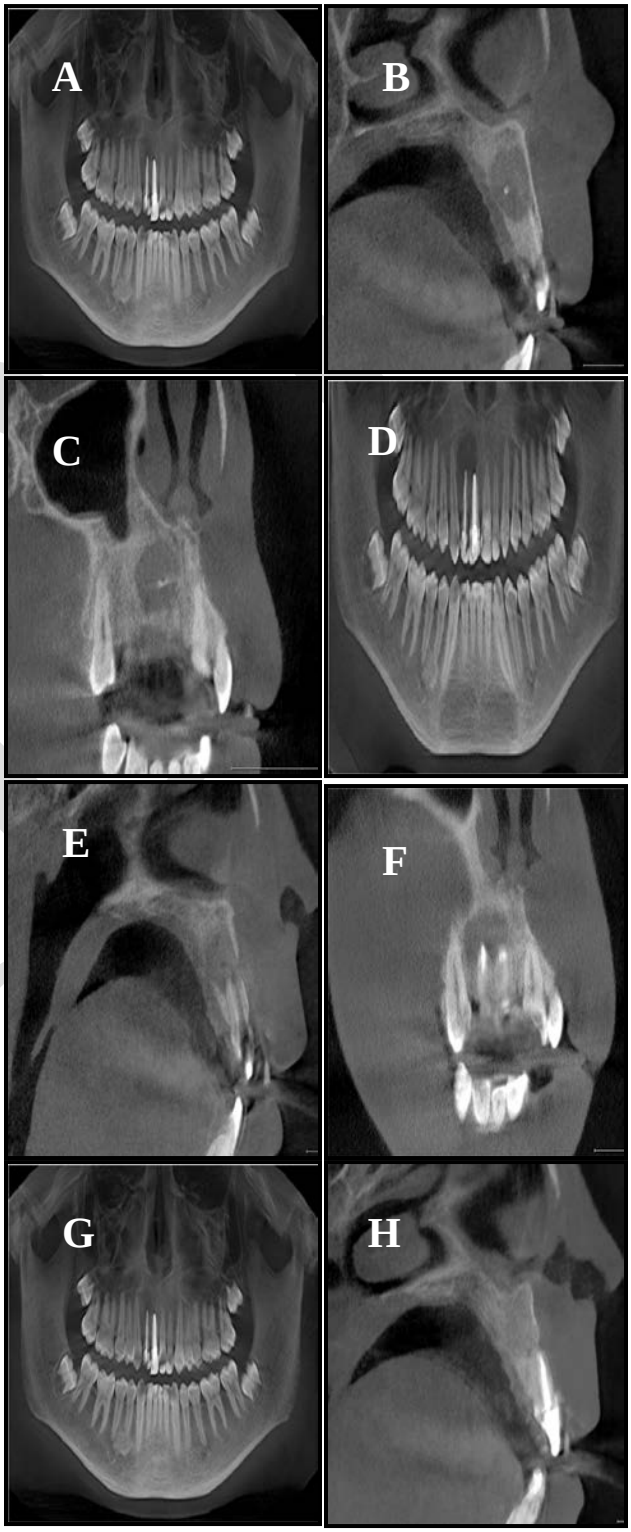

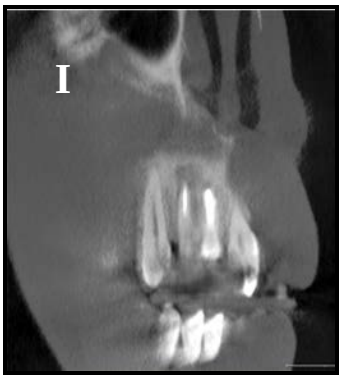

Figure (4): (A),(B)&(C)Preoperative panoramic, sagittal, & coronal CBCT views indicating bone pathology related to upper right central and lateral incisors, (D),(E),&(F)Immediate postoperative panoramic, sagittal,& coronal CBCT after removal of bone pathology and application of CH/nHA,(G)&(H),&(I) Six month postoperative panoramic, sagittal,& coronal CBCT showing bone formation inside the bone defect.

RESULTS

Radiographic results

A. Measuring bone density of bone defect (Table 1, Figure 5)

Each patient had three CBCTs; preoperative, immediate post-operative, then after six months postoperative for the assessment bone density [measured in the terms of Hounsfield units (HU)].

In the test group, the mean values of bone density measured in preoperative, immediate post-operative, and six months postoperative CBCTs were 1491.3 ± 123.71, 1563.3 ± 133.44, 2009.0 ± 173.28 HU respectively. On comparing between different periods of follow up, it was noticed that bone density increased between preoperative CBCT and six months postoperative CBCT (p_2<0.001*), and between immediate postoperative CBCT and six months post-operative CBCT (p_3<0.001*).

On the other hand, in the control group, the mean values of bone density measured in preoperative, immediate post-operative, and six months postoperative CBCTs were 1430.9 ± 192.17, 1444.1 ± 191.02, 1606.1 ± 210.38 HU respectively. On comparing between different periods of follow up, it was noticed that there was also an increase in bone density between preoperative CBCT and six months postoperative CBCT (p_2<0.001*), and between immediate postoperative CBCT and six months follow up (p_3<0.001*).

However, on comparing between both groups, the increase in bone density at six months postoperative follow up was more in the test group than in the control group(p=0.002*).

B. Measuring bone defect size from sagittal C.B.C.T view (Table 2, Figure 6)

In the test group, the mean value of the defect dimensions; average of length and width from the sagittal view in preoperative, immediate post-operative, and six months postoperative CBCTs were 11.05 ± 3.27, 11.93 ± 3.18, 3.57 ± 0.79 mm respectively. On comparing between the preoperative CBCT with immediate postoperative CBCT and six months postoperative (p_1=0.004*), (p_2=0.006*) respectively. Also, there was a significant decrease in defect size between immediate postoperative CBCT and six months follow up (p_3=0.003*).

In the control group, the mean value of the defect dimensions in preoperative, immediate post-operative, and six months postoperative CBCTs were 11.03 ± 2.30, 11.73 ± 2.63, and 8.42 ± 2.27 mm respectively. On comparing between different periods of follow, there was a significant difference between the size of the defect in preoperative CBCT and six months CBCT (p_2=0.002*). Also, there was a decrease in defect size between immediate postoperative CBCT and six months follow up (p_3=0.001*).

On comparing between the two groups, it was noticed that there was a decrease in the defect size in both groups, however, more decrease was detected in the test group at six months postoperative follow up (p< 0.001*).

C. Measuring bone defect size from coronal C.B.C.T view (Table 3)

In the test group, the mean value of the defect dimensions in preoperative, immediate post-operative, and six months postoperative CBCTs were 15.06 ± 4.66, 15.88 ± 5.85, 6.34 ± 1.41 mm respectively. On comparing between different periods of follow up, there was a significant decrease in defect size between preoperative CBCT and six months follow up (p2=0.004*), and between immediate CBCT and six months follow up (p3=0.009*).

In the control group, the mean value of the defect dimensions in preoperative, immediate post-operative, and six months postoperative CBCTs were 16.73 ± 3.45, 18.25 ± 3.42, 13.32 ± 4.06 mm respectively. On comparing between different periods of follow up, there was a decrease in the size of the defect between preoperative CBCT and six months follow up(p_2=0.002*), and between immediate postoperative and six months follow up (p_3<0.001*).

On comparing between the two groups, it was realized that there was a decrease in defect size in both groups, however, more decrease was detected in the test group at six months postoperative follow up (p< 0.003*).

Table (1): Bone density measured in Hounsfield units (HU) in test and control groups through different follow up periods.

F: F test (ANOVA) with repeated measures, Sig. bet. periods was done using Post Hoc Test (Bonferroni), T test: Student's t test

p: p value for comparison between the different periods

p_1: p value for comparison between Preoperative CBCT and Immediate Postoperative CBCT

p_2: p value for comparison between Preoperative CBCT and Six months Postoperative CBCT

p_3: p value for comparison between Immediate and Six months Postoperative CBCT

*: Statistically significant at $p \leq 0.05$

	Preoperative CBCT (n = 7)	Postoperative CBCT		F	p
		Immediate (n = 7)	Six months (n = 7)		
Test group					
Min. – Max	1298.0 – 1678.0	1348.0 – 1768.0	1746.0 – 2260.0		
Mean ± SD	1491.3 ± 123.71	1563.3 ± 133.44	2009.0 ± 173.28	233.142*	<0.001*
Median	1499.0	1587.0	1981.0		
Sig.bet. periods	p_1=0.001*,p_2<0.001*,p_3<0.001*				
Control group					
Min. – Max	1145.0 – 1655.0	1163.0 – 1670.0	1289.0 – 1860.0		
Mean ± SD	1430.9± 192.17	1444.1 ± 191.02	1606.1 ± 210.38	118.942*	<0.001*
Median	1456.0	1468.0	1618.0		
Sig.bet. periods	p_1<0.001*,p_2<0.001*,p_3<0.001*				
P(Ttest)	0.498	0.201	0.002*		

Table (2): Comparison between the three studied periods according to bone defect size in sagittal section.

	Preoperative CBCT (n = 7)	Postoperative CBCT		F	p
		Immediate (n = 7)	Six months (n = 7)		
Test group					
Min. – Max.	6.92 – 14.60	7.59 – 15.29	2.50 – 4.53		
Mean ± SD.	11.05 ± 3.27	11.93 ± 3.18	3.57 ± 0.79	31.297*	0.001*
Median	12.25	13.19	3.60		
Sig. bet. periods	p_1=0.004*,p_2=0.006*,p_3=0.003*				
Control group					
Min. – Max.	6.24 – 13.55	6.45 – 14.10	4.34 – 10.75		
Mean ± SD.	11.03 ± 2.30	11.73 ± 2.63	8.42 ± 2.27	14.795*	<0.001*
Median	11.60	11.99	8.69		
Sig. bet. periods	p_1=0.095,p_2=0.002*,p_3=0.001*				
P(T test)	0.992	0.900	<0.001*		

F: F test (ANOVA) with repeated measures, Sig. bet. periods was done using **Post Hoc Test (Bonferroni) t: Student t-test**

p: p value for comparison between the different periods

p_1: p value for comparison between **Preoperative CBCT** and **Immediate Postoperative CBCT**

p_2: p value for comparison between **Preoperative CBCT** and **Six months Postoperative CBCT**

p_3: p value for comparison between **Immediate** and **Six months Postoperative CBCT**

*: Statistically significant at

Table (3): Comparison between the three studied periods according to bone defect dimensions in coronal section.

	Preoperative CBCT (n = 7)	Postoperative CBCT		F	p
		Immediate (n = 7)	Six months (n = 7)		
Test group					
Min. – Max.	13.86 – 21.05	16.85 – 22.70	4.25 – 8.33		
Mean ± SD.	15.06 ± 4.66	15.88 ± 5.85	6.34 ± 1.41	25.174*	0.002*
Median	15.09	15.37	6.15		
Sig. bet. periods	p_1=0.810,p_2=0.004*,p_3=0.009*				
Control group					
Min. – Max.	13.32 – 22.10	14.21 – 22.50	8.57 – 17.43		
Mean ± SD.	16.73 ± 3.45	18.25 ± 3.42	13.32 ± 4.06	79.176*	<0.001*
Median	17.85	19.82	15.83		
Sig. bet. periods	p_1=0.004*,p_2=0.002*,p_3<0.001*				
P(t-test)	0.463	0.374	0.003*		

F: F test (ANOVA) with repeated measures, Sig. bet. periods was done using **Post Hoc Test (Bonferroni) t: Student t-test**

p: p value for comparison between the different periods

p_1: p value for comparison between **Preoperative CBCT** and **Immediate Postoperative CBCT**

p_2: p value for comparison between **Preoperative CBCT** and **Six months Postoperative CBCT**

p_3: p value for comparison between **Immediate** and **Six months Postoperative CBCT**

*: Statistically significant at $p \leq 0.05$

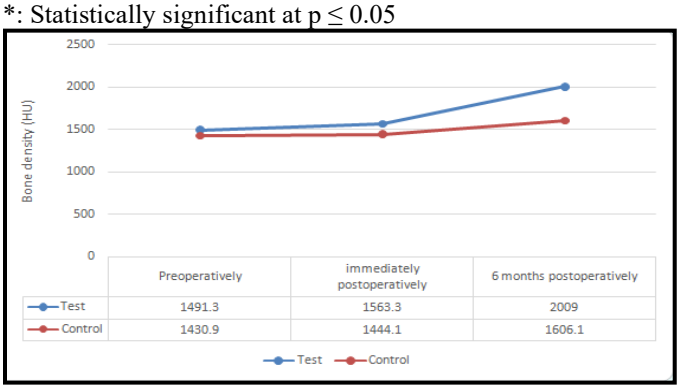

Figure (5): Showing the increase in bone density in test and control groups through different CBCTs.

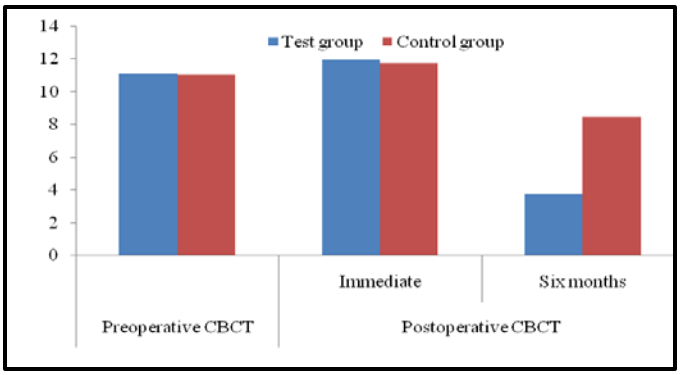

A

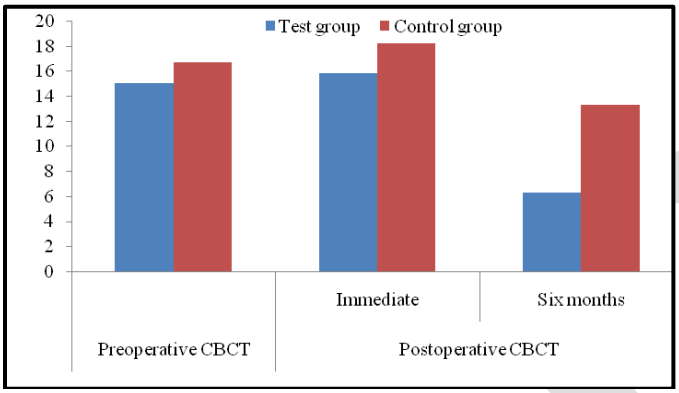

B

Figure (6): Showing the decrease in bone defect size in test and control groups through different CBCTs observed by (a) sagittal, (b) coronal CBCT views.

DISCUSSION

The current study was conducted to evaluate the effect of chitosan/ nano-hydroxyapatite on the healing of jaw osseous defects. Patients participated in the study were divided into two equal groups; **Group I (Test group)** in which patients undergone removal of jaw bone pathology and curettage to the affected bone, then application of CH/nHA, and **Group II (Control group)** in which patients undergone removal of the pathology and curettage of the affected bone, then left to heal spontaneously.

In the current study, patients were selected free from any systemic diseases or a condition that may complicate the surgical procedure or interfere with the healing process of bone defects for e.g: diabetes mellitus can affect bone regeneration as hyperglycemia affects metabolism of phosphorus and calcium which are essential for bone mineralization and remodeling. In addition, diabetes mellitus may inhibit osteoblastic differentiation, impairs circulation, reduces chemotaxis and phagocytosis of neutrophils thus increases the susceptibility for infection (25).

Patients in the current study were non-smokers as nicotine, which is the major component of tobacco, is cytotoxic and prevents differentiation of osteoblasts like cells to osteoblasts thus interferes with healing and bone regeneration. Also, the local absorption of nicotine into blood stream causes vasoconstriction which is a significant factor for healing and regeneration (26).

Moreover, all the selected cases had no parafunctional habits such as bruxism and clenching, which increase the magnitude of the forces and may lead to bone resorption and impaired regeneration (27).

In this study CBCT was used for preoperative and postoperative examinations. Three CBCTs were taken, a preoperative, immediate post-operative, and after six months post-operative. The preoperative CBCT was made to diagnose and investigate bone pathology from many aspects, for example, whether it is from endodontic or non-endodontic origins, evaluation of root shape and its relation to alveolar bone, also the contents of the pathosis if exist; cysts could be distinguished from periapical granulomas by CBCT as there is a difference in density between the content of the cyst cavity and granulomatous tissue, and finally presurgical planning to the ideal surgical method to remove it (28).

The second CBCT was done immediately after the surgery; it was done to indicate the exact size of the bone defect after removal of bone pathology. Finally, the last CBCT was done after six month post-operatively. According to **Ellis et al., (2002)** (29), and **Newman et al., (2001)** (30) it is believed that the best time to detect bone formation by radiographs was four to six months after surgery. This is may be related to the fact that at least 40% of bone mineralization should happen into the defect to be visible by radiographs (31). Also, a study conducted by **Smiesezek-Wilczewska et al., (2010)** (32) compared between density of bone defects that left to heal spontaneously, and other defects that was filled with bone grafts. They detected bone density by radiographs after six months postoperatively for follow up, it showed an increase in bone density in defects filled with bone grafts more than the ones that left to heal spontaneously.

Radiographical results of the current study shows progress in healing of bone defects and increase in bone density in both test and control groups. However, the increase was more in the test group than the control group 2009.0 ± 173.28 and 1606.1 ± 210.38 HU respectively. Results of the current study are in agreement with another study conducted by **Vaca-Cornejo et al., (2017)** (33) that used CH/HA in patients having bone defects resulting from chronic periodontitis. They evaluated the defects radiographically by the aid of CBCT and found an increase in bone density in bone defects more in the test group, and that the density of bone is similar to that found in normal neighboring teeth. They emphasized the high efficacy of CH/nHA in regeneration and healing of bone defects.

Also, results of the present study are in consistence with another one conducted by **Chatzipetros et al., (2019)** (34) they generated the study on rat models to visualize the effect of CH/nHA on regeneration of bone defects by CBCT. After eight weeks postoperatively there was a significant increase in bone density in the experimental group more than the control group, concluding that CH/nHA contributes to new

bone formation and it also can be visualized by CBCT successfully.

Furthermore, another study detected enhancement in bone formation was done by **Huang et al., (2011)** (35) that used an implant of CH/HA combined with collagen (CH/HAC) and allogeneic mesenchymal stem cells (MSC) in a rabbit's femur bone, they found larger areas of new bone. The new bone was observed radiographically twelve weeks postoperatively and an increase in bone density was detected.

Since CBCT is the most valuable, accurate and successful imaging modality for three dimensional and cross-sectional evaluation, therefore, measuring bone defects from cross-sectional view is favorable in assessing bone defects healing and regeneration (36). In the current study measuring bone defects from the sagittal and coronal views of CBCT showed a decrease in bone defect dimensions (length and width) in both control and study groups, however, it was obvious that in the study group the decrease of bone defect size was much more than that in the control group. These results are in consistence with the results observed by **Chatzipetros et al., (2019)** (34) that used CH/nHA that used rat models to visualize the effect of CH/nHA on regeneration of bone defects by CBCT. They used sagittal, coronal, and axial views to observe the change in the defect size. In eight weeks postoperatively there was significant decrease in defect size (p=0.001), concluding that CH/nHA contributes in new bone formation.

Finally, we recommended the use of CH/nHA composite in bone regeneration of jaw bony defects, due to the satisfactory results concluded by this study. We also recommend the use of the material in more clinical trials after proving its safety and biocompatibility to human tissues.

CONCLUSION

Chitosan/nano-Hydroxyapatite has many biological properties that make it one of the most promising inexpensive bone grafts for bone and tissue regeneration.

CONFLICT OF INTEREST

The authors declare that they have no conflicts of interest.

REFERENCES

1- Shakir M, Jolly R, Khan AA, Ahmed SS, Alam S, Rauf MA, et al. Resol based chitosan/nano-hydroxyapatite nanoensemble for effective bone tissue engineering. Carbohydr Polym 2018;179:317-27.
2- Sandor GK, Lindlom TC, Clokie CM. Bone Regeneration of the Cranio- maxillofacial and Dento-alveolar Skeletons in the Framework of Tissue Engineering. Topics in Tissue Engineering 2003;7:1-46.
3- Alan S, Miller M, Signorino F. Maxillofacial Defects and the Use of Growth Factors. Oral Maxillofacial Surg Clin N Am 2017;29:75-88.
4- Sculean A, Stavropoulos A, Bosshardt DD. Self-regeneration capacity of intra-oral bone defects. J clinc periodontolo 2019;46:S21.
5- Venkatesan J, Kim S. Chitosan composites for Bone Tissue Engineering-An overview. Mar Drugs 2010;8:2252-66.
6- Sowmya S, Bumgardener JD, Chennazhi KP, Nair SV, Jayakumar R. Role of nanostructured biopolymers and bioceramics in enamel, dentin and periodontal tissue regeneration. Prog Polym Sci 2013;38:1748-72.
7- Rodríguez-Vázquez M, Vega-Ruiz B, Ramos-Zúñiga R, Saldaña-Koppel DA Q-OL. Chitosan and Its Potential Use as a Scaffold for Tissue Engineering in Regenerative Medicine. Biomed Res Int 2015;2015:821279.
8- Chambers P, Dunne NJ. Emerging areas of bone repair materials: nucleic acid therapy and drug delivery. In: Bone Repair Biomaterials (Second edition). 2019. p. 411-46.
9- Mohd pu'ad NA., Koshy P, Abdullah H., Idris M., Lee T. Syntheses of hydroxyapatite from natural sources. Heliyon 2019;5: e01588.
10- Elieh-Ali-komi D, R Hamblin M. Chitin and Chitosan: Production and Application of Versatile Biomedical Nanomaterials. Int J Adv Res 2016;4:411-27.
11- Panos I, Acosta N, Heras A. New drug delivery systems based on chitosan. Curr Drug Discov Technol 2008;5:333-41.
12- Beck SC, Jiang T, Nair LS, Laurencin CT. Chitosan for bone and cartilage regenerative engineering. In Chitosan Based Biomaterials Vol. 2. Woodhead Publishing; 2017. pp. 33-72.
13- Ezoddini-Ardakani F, Navabazam A, Fatehi F, Danesh-Ardekani M, Khadem S, Rouhi G. Histologic evaluation of chitosan as an accelerator of bone regeneration in microdrilled rat tibias. Dent Res J (Isfahan) 2012;9:694-9.
14- Rinaudo M. Chitin and chitosan: Properties and applications. Prog Polym Sci. 2006;31:603-32.
15- Aoki H. Medical application of Hydroxyapatite. Ishiyaku Euro America 1994;13-74.
16- Krishnamurithy G. A review on hydroxyapatite-based scaffolds as a poteintial bone graft substitute for bone tissue engineering applications. J Univ Malaya Med Centre 2013;16:22-7.
17- Gao X, Song J, Ji P, Zhang X, Li X, Xu et al. Polydopamine-templated hydroxyapatite reinforced polycaprolactone composite nano fibers with enhanced cytocompatibility and osteogenesis for bone tissue engineering. Applied Materials & Interfaces 2016;8:3499-515.
18- Murugan, R., & Ramakrishna S. Bioresorbable composite bone paste using polysaccharide based nano hydroxyapatite. Biomaterials 2004;25:3829-35.
19- Wang H, Li Y, Zuo Y, Li J, Ma S, Cheng L. Biocompatibility and osteogenesis of biomimetic nano-hydroxyapatite/polyamide composite scaffolds for bone tissue engineering. Biomaterials 2007;28:3338-48.
20- Wang F, Zhang YC, Zhou H, Guo YC, Su XX. Evaluation of in vitro and in vivo osteogenic differentiation of nano-hydroxyapatite/ chitosan/ poly (lactide-co-glycolide) scaffolds with human umbilical cord mesenchymal stem cells. J Biomed Mater Res 2014;102:760-8.

21- Cai B, Zou Q, Zuo Y, Li L, Yang B. Li Y. Fabrication and cell viability of injectable n-HA/chitosan composite microspheres for bone tissue engineering. Rsc Advances 2016;6:85735-44.
22- Fan T, Chen J, Pan P, Zhang Y, Hua Y, Liu X, et al. Bioinspired double polysaccharides-based nanohybrid scaffold for bone tissue engineering. Colloids Surf B Biointerfaces 2016;147:217-223.
23- Fang X, Xie J, Zhong L, Li J, Rong D, Li X. Biomimetic gelatin methacrylamide hydrogel scaffolds for bone tissue engineering. J Mater Chem 2016;4:1070-80.
24- Escobar-Sierra DM, Martins J, Ossa-Orozco CP. Chitosan/hydroxyapatite scaffolds for tissue engineering manufacturing method effect comparison. Rev Fac Ing Univ Antioquia 2015;75:24-35.
25- Leonhardt A, Dahlen G, Renvert S. Five-year clinical, microbiological and radiological outcome following treatment of peri-implantitis in man. J Periodontol 2003;74:1415-22.
26- Patel R, Wilson R, Palmer R. The Effect of Smoking on Periodontal Bone Regeneration: A Systematic Review and Meta-Analysis. J Periodontol 2012;83:143-55.
27- Manfredini D, Poggio CE, Lobbezoo F. Is bruxism a risk factor for dental implants? A systemic review of the literature. Clin Implant Dent Relat Res 2012;16:460-9.
28- Estrela C, Bueno MR, Azevedo BC, Azevedo JR, Pécora JD. A New Periapical Index Based on Cone Beam Computed Tomography. J Endod 2008;34:1325-31.
29- Ellis E, Hupp J, Tucker M. Contemporary Oral and Maxillofacial surgery. 4th (ed). Philadelphia: Mobsy. 2002.
30- Newman M, Takei H, Carranza F. Carranza's clinical periodontology. 9th (ed). Pjiladelphia: Saunders. 2001.
31- Haghighat A, Hekmatian E, Abdinian M, Sadeghkhani E. Radiographic evaluation of bone formation and density changes after mandibular third molar extraction: A 6 month follow up. Dent Res J (Isfahan) 2011;8:1-5.
32- Smieszek-Wilczewska J, Koszowski R, Pajak J. Comparison of postoperation bone defects healing of alveolar processes of maxilla and mandible with the use of Bio-Gen and Bio-Oss. J Clin Exo Dent 2010;2:62-8.
33- Vaca-Cornejo F, Reyes HM, Jiménez SHD, Velázquez RAL, Jiménez JMD. Pilot Study Using a Chitosan-Hydroxyapatite Implant for Guided Alveolar Bone Growth in Patients with Chronic Periodontitis. J Funct Biomater 2017;8:e29.
34- Chatzipetros E, Yfanti Z, Christopoulos P, Donta C, Damaskos S, Tsiambas E, et al. Imaging of nano-hydroxyapatite/chitosan scaffolds using a cone beam computed tomograhydevice on rat calvarial defects with histological verification. Clin Oral Invest 2019;18:1–10.
35- Huang Z, Chen Y, Feng QL, Zhao W, Yu B, Tian J, et al. In vivo bone regeneration with injectable chitosan/hydroxyapatite/collagen composites and mesenchymal stem cells. Front Mter Sci 2011;5:301-10.
36- Shenoy N, Ahmed J, Mallya SM. Add a third dimension to your patient care with cone beam computed tomography. J Interdiscip Dentistry 2014;4:118-22.