

## RECENT TECHNIQUES IN VARICOCELE EMBOLIZATION

*Mina Emil Edward, Osama Mohamed Abd El Hamed,  
Mohamed El Gharib Abou El Maaty and Haytham Mohamed Nasser*

### ABSTRACT:

Radiology Department, Faculty  
of Medicine, Ain Shams  
University, Cairo, Egypt

#### Corresponds:

Mina Emil

#### e.male:

[mina.emil.edward@hotmail.com](mailto:mina.emil.edward@hotmail.com)

Tel.: 201285220139

Received: 6/2/2019

Accepted: 1/3/2019

**Background:** *Varicoceles; dilation of veins within the pampiniform plexus, are present in 15% of the general male population. It is also one of the most frequent causes of male-factor infertility, with a prevalence of 30%–40% among men presenting for primary infertility evaluation and up to 85% in secondary infertility.*

**Aim of work:** *The purpose of this study is to measure the success rate of the embolization technique in patients with clinical and radiological varicocele by U/S.*

**Patients and Methods:** *This cross sectional study included 13 patients with varicocele presented by pain, infertility or recurrence after surgery. The diagnosis was confirmed by ultrasound. Patients were operated at various centers from August 2017 to December 2018.*

**Results:** *varicocele embolization has significant role in improving scrotal pain and infertility with technical success of 93.75%.*

**Conclusion:** *Embolization is an effective way comparable to surgery in treating varicocele.*

**Keywords:** *Varicocele (VC), Gonadal Vein (GV), Butyl Cyanoacrylate (BC), Primary Infertility (PI), Percutaneous Embolization (PE).*

### INTRODUCTION:

A varicocele consists of abnormally dilated and tortuous veins within the pampiniform plexus of the spermatic cord<sup>[1]</sup>.

Varicocele is prevalent, occurring in approximately 15% of all men, 35% of men with primary infertility, and up to 80% of men with secondary infertility. While the majority of men with varicocele are asymptomatic, there is clear evidence that varicocele is associated with a progressive decline in testicular function resulting in impaired semen parameters and possibly decreased serum testosterone<sup>[2]</sup>.

It is likely to be multifactorial. Recent studies showed that it resulted mainly in

higher levels of reactive oxygen species (ROS)<sup>[3]</sup>.

This excessive ROS is associated with sperm DNA fragmentation, which may mediate the clinical manifestation of poor sperm function and fertilization outcome related to varicocele<sup>[4]</sup>.

Accordingly, treatment of varicocele has been shown to arrest continued decline in testicular function, improve semen parameters and, in some reports, serum testosterone<sup>[5]</sup>.

Thus, in some men with primary or secondary infertility, treatment of varicocele may obviate the need for assisted reproduction, thereby sparing additional interventions, cost, and psychological stress.

Varicocele can also lead to scrotal pain, and correction of varicocele can benefit men with scrotal pain who have failed conservative measures<sup>[6]</sup>.

Both surgical and nonsurgical approaches to the treatment of varicocele have been described. The conventional inguinal or subinguinal operative approach involves an inguinal incision with surgical ligation of all visibly dilated spermatic veins and careful avoidance of the testicular artery. Laparoscopic varicocelectomy utilizes a minimally invasive operative technique to ligate the internal spermatic veins proximally<sup>[2]</sup>.

Radiographic approaches involve venography to identify the internal spermatic and collateral veins with subsequent venous occlusion via a variety of occlusion and embolization techniques. Efficacy of varicocelectomy for the treatment of infertility is determined based upon improvement in serum testosterone levels, semen parameters, and, ultimately, pregnancy rates following treatment. In patients with scrotal pain, the primary objective is alleviation of pain<sup>[2]</sup>.

Percutaneous embolization is the least invasive of all treatment approaches. In contrast to traditional surgical therapies, percutaneous interventional approaches do not require surgical incisions and thus, can be performed under local anaesthesia, whereas surgical approaches require more extensive anaesthetic preparations. Surgical failure may be the result of pre-existing collateral gonadal veins, Varicocele embolization is therefore better suited to identify and eliminate these collaterals<sup>[7]</sup>.

The use of venography enables the precise identification of the internal spermatic veins, in addition to any collateral venous vascular supply that may contribute to the clinical pathology<sup>[8]</sup>.

In addition, the transvenous method virtually eliminates the potential for damage

to the testicular artery, which results in theoretically reduced complications related to testicular pain and atrophy<sup>[2]</sup>.

---

### **AIM OF WORK:**

The purpose of this study is to measure the success rate of the embolization technique in patients with clinical and radiological varicocele by U/S.

---

### **PATIENTS AND METHODS:**

#### **Patients:**

From August 2017 to December 2018, thirteen patients were enrolled in the study. All patients with varicocele, diagnosed by ultrasound and scrotal Doppler, 6 patients presented with infertility (46.2 %), 6 patients presented with pain (46.2 %), and one patient presented with recurrence after surgery (7.7%).

#### **Inclusion criteria:**

- Patients with unilateral or bilateral varicocele diagnosed by U/S and confirmed during the operation with venography.
- No age predilection.

#### **Exclusion criteria**

- Bleeding tendency.
- Any contraindication to the injection of contrast: high serum creatinine or allergy.

#### **Ethical consideration:**

- An informed consent is obtained from the patient concerning the complication of the procedure, the complication of the glue and the acceptance to be enrolled in the study.

#### **Ultrasound imaging:**

- U/S examination revealed 10 patients to have unilateral left varicocele and 3 patients to have bilateral varicocele.

**Semen analysis:**

- 6 patients had infertility, 3 patients with low number only, 3 patients with low motility and 1 patients with both.

**Statistical analysis**

Data were coded and entered using the statistical package SPSS (Statistical Package for the Social Sciences) version 23. Data were summarized using mean, standard deviation, median, minimum and maximum in quantitative data and using frequency (count) and relative frequency (percentage) for categorical data. Comparisons between quantitative variables were done using Chi<sup>2</sup> and paired t test.

**Chi-square test**

P-value > 0.05 Non significant

P-value < 0.05 Significant

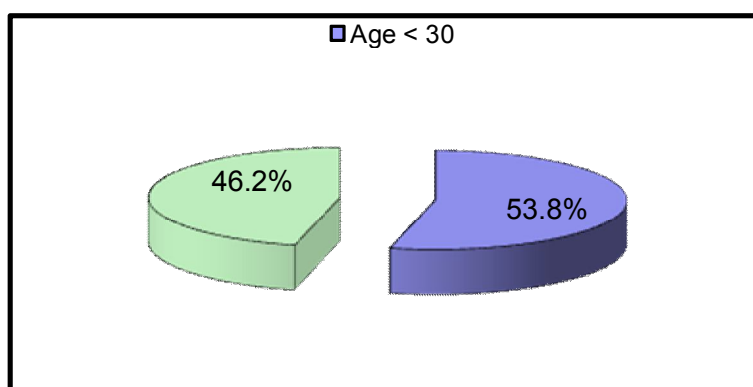
P-value < 0.01 Highly significant

**RESULTS**

The 13 patients enrolled in this study were ranging from 16 to 42 years with mean age of 28.6 years.

Table (1): Representing the statistical data analysis for different ages enrolled at our study.

Age(years)	No.= 13
Mean ± SD	28.60 ± 7.61
Range	16 – 42
Age< 30	7 (53.8%)
Age> 30	6 (46.2%)



**(Diagram-1):** Showing that in our study 7 patients were less than 30 years (53.8%), and 6 patients were older than 30 years (46.2%).

**Presenting complain:**

6 patients presented with infertility (46.2 %), 6 patients presented with pain

(46.2 %) and 1 patient presented with recurrence after surgery (7.7%).

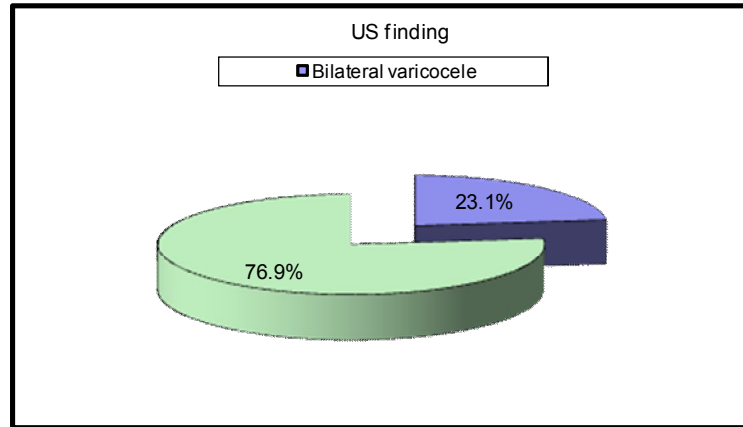
(Table 2): Demonstrating statistical analysis as regard the clinical indication for varicocele embolization.

Clinical indication		No.	%
Pain	No	7	53.8%
	Yes	6	46.2%
Infertility	No	7	53.8%
	Yes	6	46.2%
Recurrence	No	12	92.3%
	Yes	1	7.7%

**By imaging assessment:**

All patients were examined by U/S, the examination revealed, 3 of them had

bilateral varicocele, 10 cases had unilateral varicocele.



(Diagram-2): Representing the percentage of patient with unilateral varicocele (76.9 %), and bilateral varicocele (23.1%).

(Table 3): Demonstrating the percentage of patients with right and left side varicocele according to the grade.

		No.	%
Right Side Grade	I	1	7.7%
	II	2	15.4%
	III	0	0.0%
Left Side Grade	I	2	15.4%
	II	6	46.2%
	III	2	15.4%

**Semen analysis:**

Three patients had low number only, 2 patients had low motility and 1 patients had low number and decreased motility.

(Table 4): Demonstrating the statistical data for patients presented with infertility, abnormal number range from (3-11 million/ml), and abnormality in motility range from 5-15 %.

		No.= 13
Semen analysis abnormality	Low	3 (23.1%)
	Decrease motility	2 (15.4%)
	Both	1 (7.7%)
Number (million/ml)	Mean ± SD	7.00 ± 2.65
	Range	3 – 11
Motility %	Mean ± SD	11.80 ± 4.15
	Range	5 – 15

The procedure done for 10 patients was left ISV embolization, 3 cases underwent bilateral ISV.

**Recent techniques in varicocele embolization**

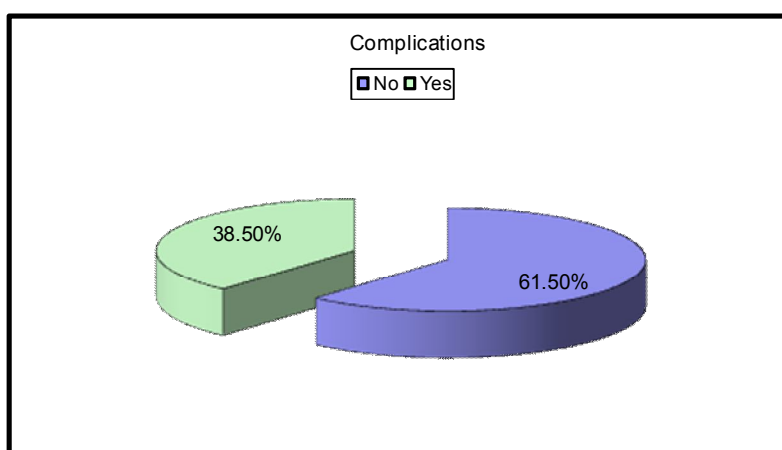
(Table 5): Demonstrating the data for the procedure either embolization of left and bilateral ISV. All patients were done via right jugular approach.

		No.	%
Procedure	Left	13	100.0%
	Right	3	23.1%
Approach	Jugular	13	100.0%

(Table 6): Concerning the complications occurred.

		No.	%
Complications	No	8	61.5%
	Yes	5	38.5%
Pain		5	38.5%

It occurred in 5 case (38.5%) in the form of self limited hypochondrial pain after the procedure for one week that resolved over analgesics.



(Diagram-3): Representing the percentage of patients with and without complications.

(Table 7): Comparison between pre-procedure and post procedure regarding pain.

		Pre		Post		Test value*	P-value	Sig.
		No.	%	No.	%			
Pain	No	7	53.8%	11	100%	2.889	0.031	S
	Yes	6	46.2%	0	0%			

\*: Chi-square test:

P- value > 0.05 Non significant

P- value < 0.05 Significant

P-value < 0.01 Highly significant

The previous table shows that there was statistically significant decrease in percentage of pain from 53.8% pre-procedure to 0% post procedure with p-value= 0.031.

(Table 1): Comparison between pre-procedure and post procedure regarding number and motility.

		Pre	Post	Test value*	P-value	Sig .
Number (million/ml)	Mean ± SD	7.00 ± 2.65	28.00 ± 10.89	-3.909	0.030	S
	Range	3 – 11	15 – 37			
Motility %	Mean ± SD	11.80 ± 4.15	45.80 ± 6.94	-7.641	0.002	HS
	Range	5 – 15	34 – 50			

\*: Paired t-test:

HS: Highly significant; S: Significant; NS: Non significant

The previous table shows that there was statistically significant increase in number and motility of the studied cases with p-value= 0.030 and 0.002 respectively.

Concerning three months follow up, one patient had improvement of the motility but the number is not improved, all patient with pain are improved.

same situation concerning the morphology<sup>[11]</sup>. *In our study*, we had 6 patients with infertility (46.2 %), 3 patients had low number only, 2 patients had low motility and 1 patients had low number and decreased motility, our results after embolization showed that there was statistically significant increase in number and motility of the studied cases with P-value = 0.030 and 0.002 respectively.

## DISCUSSION

The methods of varicocele repair continue to evolve. Many favour the percutaneous trans-catheter technique as a first-line treatment because it is a minimally invasive outpatient procedure and has minimal complication rates<sup>[9]</sup>.

*Trombetta et al., 2013* mentioned that the targeted overall reported technical success rate, as cited by the Journal of Vascular and Interventional Radiology quality improvements guidelines, is 83 to 96%<sup>[10]</sup>. *In our study*, we included 13 patients, we failed to catheterize the right internal spermatic vein in one case with technical success rate of 93.75%.

*Gat et al., 2005* concluded that clinical outcomes of percutaneous ISV embolization or sclerotherapy are quite similar to surgical procedures. Semen parameters such as sperm concentration and motility improve in 70 to 82% of patients, which is almost the

*Nabi et al., 2004*, regarding improvement of semen parameters after varicocele embolization recorded improvement in semen motility and morphology in those with retreatment semen density 10-30 million/ml<sup>[12]</sup>. *Gandini et al., 2008*, Another study performed on 244 patients also concluded improvement in all semen parameters after treatment<sup>[13]</sup>.

*Jargiello et al., 2015* answered the question of how we manage recurrent varicocele after surgery as he said: if the varicocele recurs, endovascular treatment is still performed via a retrograde way by accessing the left gonadal vein via the left renal vein, either from a right internal jugular or right femoral vein approach<sup>[14]</sup>. *Jargiello et al., 2015* published 100 % technical success in the endovascular treatment of surgically recurrent varicocele. *In our study*, we have one case of recurrence after surgery that we treated via right jugular approach successfully.

*Alqahtani et al., 2002* patients with cardio-pulmonary comorbidities can undergo varicocele embolization using only local anaesthesia, whereas general anaesthesia is routinely necessary with surgical repair. Additionally, bilateral varicocele patients can undergo catheter-based embolization with only one single jugular vein access, in contrary to two separate surgical incisions with operative interventions. Without the need to create a surgical incision, catheter-based varicocele embolization is associated with a significant lower risk for wound complications such as infection or dehiscence <sup>[15]</sup>. **In our study**, we included patients from different age groups without any restrictions, because there is no contraindication to perform our procedure in patients with other comorbidities or systemic diseases. We also did bilateral embolization in 3 cases successfully without any need for hospital stay or complications.

*Cassidy et al., 2012* discussed the technical and clinical success based on a larger scale, and his results were quite similar to us as he published a review with the largest recent series of the outcomes currently available in the literature regarding varicocele embolization. The overall technical failure rate 13.9% is consistent with the published meta-analysis rate of 13.05%. However, the high technical failure rate seen in patients with right-sided embolization attempts of 19% in Cassidy's series hadn't been previously addressed. The 3.2% overall failure rate for left-sided embolization attempts is comparable to the 3.25% published failure rate for surgical varicocele repair; for that these two options are equally effective, however embolization offers some advantages in terms of recovery time and safety <sup>[16]</sup>.

*In our study*, as regard post procedural complications: 5 of our 13 patients had hypochondrial pain related to the site of gonadal vein embolization that last from 5

days to week that was controlled with analgesics.

*Nabi et al., 2004* agreed with our rates of complications as he mentioned that the complications of percutaneous therapy are infrequent and typically mild. Complication rates in recent literature have been reported from 0%, to 5% and 11% <sup>[12]</sup>.

*Reiner et al., 2011* concluded that occurrence of post-embolization pain seems to be more frequent when using cyanoacrylate and sclerosing agents rather than coils, and this symptom is related to the secondary phlebitis that they cause <sup>[17]</sup>.

#### **Limitations of the study :**

A limitation of this study is that it's small sample size. It would be beneficial to conduct a comparative study with the standard treatment using coil embolization or surgery.

#### **Conclusion**

In our study there was significant improvement in patients complaining of scrotal pain, with significant improvement regarding the sperm count /ml in comparison to pre and post procedural data, and highly significant improve of motility in 3 months follow up.

In conclusion, the use of NBCA as an embolic agent for percutaneous treatment of varicoceles is a therapeutic alternative that is effective, safe, simple. NBCA triggers a local inflammatory reaction that promotes sclerosis and thrombosis. The liquid nature of the embolization product allows diffusion through the gonadal vein and their collaterals, which appears to reduce recurrence and improve results.

---

#### **REFERENCES**

1. Wein AJ, Kavoussi LR, Campbell MF, editors. Campbell □ Walsh Urology. Philadelphia, PA: Elsevier Saunders; 2012.
2. Halpern J, Mittal S, Pereira K, Bhatia S,

- Ramasamy R. Percutaneous embolization of varicocele: technique, indications, relative contraindications, and complications. *Asian J Androl.* 2016 Mar-Apr;18(2):234-8
3. Zini A, Azhar R, Baazeem A, Gabriel MS. Effect of microsurgical varicocelectomy on human sperm chromatin and DNA integrity: a prospective trial. *Int J Androl.* 2011;34(1):14–9.
  4. Cho CL, Esteves SC, Agarwal A. Novel insights into the pathophysiology of varicocele and its association with reactive oxygen species and sperm DNA fragmentation. *Asian J Androl.* 2016; 18(2): 186–93. doi:10.4103/1008-682X. 170441. PMID: 26732105.
  5. Tanrikut C, McQuaid JW, Goldstein M. The impact of varicocele and varicocele repair on serum testosterone. *Curr Opin Obstet Gynecol* 2011; 23: 227–31.
  6. Puche Sanz I, Flores Martin JF, Vazquez Alonso F, Pardo Moreno PL, Cozar, Olmo JM. Primary treatment of painful varicocele through percutaneous retrograde embolization with fibred coils. *Andrology* 2014; 2: 716–20.1
  7. Jargiello T, Drelich-Zbroja A, Falkowski A, Sojka M, Pyra K, Szczerbo-Trojanowska M. Endovascular transcatheter embolization of recurrent postsurgical varicocele: anatomic reasons for surgical failure. *Acta Radiol* 2015; 56(1):63–9.
  8. Moon KH, Cho SJ, Kim KS, Park S, Park S. Recurrent Varicoceles: Causes and Treatment Using Angiography and Magnification Assisted Subinguinal Varicocelectomy. *Yonsei Med J* 2012; 53 (4): 723–8.
  9. Hargreave T.B.: Varicocele—a clinical enigma. *Br J Urol.* 1993;72(4):401–408.
  10. Trombetta C, Liguori G, Bucci S, Ciciliato S, Belgrano E.:Percutaneous treatment of varicocele.,*Urol Int.* 2003; 70(2):113-8.
  11. Gat Y, Zukerman Z, Chakraborty J, Gornish M.: Varicocele, hypoxia and male infertility. Fluid mechanics analysis of the impaired testicular venous drainage system. *Hum Reprod* 2005; 20:2614–9.
  12. Nabi G, Asterlings S, Greene DR, Marsh RL.: Percutaneous embolization of varicoceles: outcomes and correlation of semen improvement with pregnancy., *Urology.* 2004 Feb; 63 (2): 359-63.
  13. Gandini R, Konda D and Reale CA: Male varicocele: transcatheter foam sclerotherapy with sodium tetradecyl sulfate—outcome in 244 patients. *Radiology* 2008; 246: 612–618.
  14. Jargiello T, Drelich-Zbroja A, Falkowski A et al. Endovascular transcatheter embolization of recurrent postsurgical varicocele: anatomic reasons for surgical failure.(2014) *Acta Radiol* Jan 10. PMID: 24413222
  15. Alqahtani A., Yezbeck S., Pubois J.,et al. Percutaneous embolization of varicocele in children: a canadian experience. *J Pediatr Surg,* 2002; 37:783-785.
  16. Cassidy D., Jarvi K., grober E., et al. Varicocele surgery or embolization: Which is better?. *can Urol assoc J,* 2012;6 (4):266-8.
  17. Reiner E., Jeffrey S., and Robert I. Varicocele Embolization In Kandarpa K. and Machan L.(eds): Handbook for interventional radiologic procedures. a lippincott Williams & wilkins, 4th edition. 2011; p.416- 423.



## **التقنيات الحديثة في غلق دوالي الخصية**

مينا إميل إدوارد ، أسامة محمد عبد الحميد ، محمد الغريب أبو المعاطي ، هيثم محمد ناصر

قسم الأشعة ، كلية الطب ، جامعة عين شمس ، القاهرة ، مصر

**المقدمة:** دوالي الخصية: تمتد الأوردة داخل الضفيرة البامبينيفورم ، موجودة في ١٥ ٪ من السكان الذكور عامة. كما أنها واحدة من أكثر أسباب العقم عند الذكور شيوعاً ، مع انتشار من ٣٠ ٪ إلى ٤٠ ٪ بين الرجال الذين يقدمون لتقييم العقم الأولي وما يصل إلى ٨٥ ٪ في العقم الثانوي.

**الهدف من العمل:** الغرض من هذه الدراسة هو قياس معدل نجاح تقنية غلف دوالي الخصية في المرضى الذين يعانون من دوالي الخصية المشخصة بالفحص الكلينيكي و السونار.

**المرضى والطرق:** شملت هذه الدراسة ١٣ مريضاً يعانون من دوالي الخصية منها من يشتكى من الألم أو العقم أو تكرار بعد الجراحة. تم تأكيد التشخيص بواسطة الموجات فوق الصوتية. تمت العمليات المرضى في مراكز مختلفة من أغسطس ٢٠١٧ إلى ديسمبر ٢٠١٨.

**النتائج:** غلق دوالي الخصية له دور هام في تحسين الألم أو العقم مع نجاح تقني قدره ٩٣.٧٥ ٪.

**الخلاصة:** غلق دوالي الخصية هو وسيلة فعالة مماثلة لعملية جراحية في علاج دوالي الخصية.

**الكلمات المفتاحية:** دوالي الخصية (VC) ، الغدد التناسلية الوريدية (GV) ، البوتيل (BC) Cyanoacrylate ، العقم الأولي (PI) ، الانصمام الجلدي (PE).