

## Prevalence of Internal Hernia Post Laparoscopic Surgery

Wail Omar AlGorashi<sup>1</sup>, Zina Abdulkareem Al Zahidy<sup>1</sup>, Amal Mohamed Sharton<sup>2</sup>,  
Sara Abdullah Turki<sup>2</sup>, Aisha Omar Aljiffry<sup>1</sup>, Alaa Khalid Al-jehani<sup>2</sup>, Rasis Khalid Saber<sup>2</sup>,  
Dina Alamin Gaber<sup>2</sup>, Asmaa Yaseen Nassir<sup>1</sup>, Rahaf Tarik Dashash<sup>2</sup>, Wadha Saad Almohamdi<sup>1</sup>,  
Bayan Hamdan AlGhamdi<sup>1</sup>, Ahmed Zaki Alaidaroos<sup>2</sup>, Fahad Noraldeen Kahilah<sup>1</sup>

1 Ibn Sina National College, 2 Battarjee Medical College

### ABSTRACT

**Background:** Laparoscopic approach for colorectal resections is now very popular. Internal small bowel herniation (SBH) through a mesenteric defect has been recorded especially if the mesentery is not repaired. Although it's rare, it is a severe complication. Lack of postoperative adhesions is one advantage of minimally invasive surgery but it's also responsible for a higher incidence of internal hernias. These patients often present with intermittent abdominal pain or small bowel obstruction with completely normal contrast radiographs. Laparoscopic surgery is a minimally invasive approach with good treatment outcomes and is currently the standard surgery for colorectal cancer in Saudi Arabia.

**Objective:** the aim of our study was to evaluate the incidence and outcome of internal hernias after laparoscopic procedure in King Abdul-Aziz Hospital & Oncology Center.

**Patients and methods:** a total of 372 patients underwent laparoscopic colon resection surgery for colon cancer during the study period from August 2015 to October 2016 in King Abdul-Aziz Hospital & oncology center. Results: our result found that internal hernia was reported 48 times.

**Keywords:** Internal hernias; closed colon cancer resection surgery.

### INTRODUCTION

Laparoscopic surgery for colon cancer resection complications is very different to those in open surgery [1]. On the other hand laparoscopic operation has minimal invasion and minimal scars that benefits the patients [2]. Intra-abdominal adhesions are also markedly reduced following laparoscopic surgery. Some of the side effects that can be presented from laparoscopic procedure such as peritonitis and internal herniation [3, 4, 5]. The major cause of the internal herniation is the mesenteric defect because it doesn't repair completely in laparoscopic surgery as it does in open surgery [6, 7, 8]. Lately laparoscopic surgery has become more popular and more performed than open surgery. In both laparoscopic and open surgeries the mesenteric will be closed. However, numerous reports indicate that mesenteric defects are often not closed during laparoscopic surgery [6]. We have reported a lot of cases of an internal hernia projecting through a mesenteric defect following laparoscopic resection of the colon. Ironically, the advent of laparoscopic surgery has increased the incidence of this problem, but also has simplified the diagnosis and treatment of these cases.

### METHODOLOGY

During the study period from August 2015 to October 2016, 372 patients underwent laparoscopic colon resection surgery for colon cancer in King Abdul-Aziz Hospital & Oncology Center. The vast majority were primary laparoscopic colon cancer resection procedures. Patients were informed about the procedure and signed on a written consent. Some hernias were found incidentally during exploring for the pathologies and some patients were found to have a mesenteric defect without herniation of bowel. Patients who had the hernia were presented with symptoms with or without intestinal obstruction. We have evaluated the patients according to their signs and symptoms at presentation. Patients who presented with clear signs of herniation and intestinal obstruction were offered to have re-operation to repair the hernia and close the mesenteric defect. Patients who presented with intermittent abdominal pain with no signs of obstruction underwent further investigations such as contrast for upper GI, Computed tomography (CT) scan, Ultrasonography and Endoscopy. We also had to do exploration for all those with unclear symptom and for those with post-surgery

abdominal pain for no apparent reason. All defects that have been found during the exploration have been repaired and the hernia has been reduced before closure. Patients went to radiograph after the re-operation so the radiologist and the surgeons would compare between the findings before and after the surgery. The study was done after approval of ethical board of King Abdulaziz University.

## RESULTS

A total of 372 laparoscopic colorectal resections were performed from August 2015 to October 2016. As shown in table (1), Total of 18 (4.84%) patients were found incidentally to have hernia during the procedure and 90 (24.19%) were found to have mesenteric defect without hernia.

Regarding Figure(1), complication following laparoscopic procedure; We report 48 (12.9%) internal hernias occurred out of the all patients through one year following the procedure, 28 (7.53%) patients developed Bowel obstruction and 2 (.54%) of them were due to adhesion. Furthermore 8 (2.15%) patients developed bowel ischemia due to the obstruction. Out of the all patients 2 (.54%) faced death due to complication.

As Clear in Table (2) laparoscopic colon resection was performed on 372 patients. Incidence of conversion to open surgery was (1.08%) which recorded only in 4 patients. However, 70.97% of patients had a normal radiograph after the laparoscopic surgery.

In graph (2) shown patients who had recorded to have incidental hernia or internal hernia followed the procedure in three areas: the transverse mesocolon, the jejunal mesenteric defect and Petersen's space (34.85%, 53.03%, and 12.12% respectively).

## DISCUSSION

Internal hernia is a rare but fatal complication after laparoscopic colonic resection. To confirm this diagnosis it requires emergency re-operation because most of the patients come with non-specific symptoms. Lately laparoscopic surgeries for colon cancer resection have been very common in Saudi Arabia, as shown by the results of a survey conducted by the Japan Society for Endoscopic

Surgery. Laparoscopic surgery now has proved that it's as more effective as the open surgery and it's used for the management of colon cancer resection <sup>[1,2]</sup>. Internal hernia is a major side effect that was recorded after the laparoscopic procedure which it leads to intestinal obstruction if it didn't repaired early <sup>[9,19,11]</sup>. In our study we have reported that most of the patients had no symptoms or defects after laparoscopic surgery. Although we have found that there are a number of internal hernias that have been recorded after laparoscopic surgeries it could be due to the mesenteric defect was not initially closed in most of the cases.

We have found 48 cases of internal hernia; patients who presented with clear signs of herniation and intestinal obstruction were offered to have re operation to repair the hernia and close the mesenteric defect. Internal hernia might have developed due to protrusion of the bowel into the mesenteric defect due to the higher intraperitoneal pressure <sup>[12]</sup>. However all patients with internal hernia should go for re-operation to repair the mesenteric defect and the hernia should be repaired without any injury to the herniated bowel <sup>[3]</sup>. A CT image has played an important role in diagnosing the internal hernias <sup>[7]</sup>, however in our study patients who presented with intermittent abdominal pain with no signs of obstruction underwent further investigations such as contrast for upper GI, CT scan, Ultrasonography and Endoscopy . We also had to do exploration for all those with unclear symptom and for those with post-surgery abdominal pain for no apparent reason. If the mesentery hasn't been repaired and the herniation reduced the herniated bowel will be obstructed leading to ischemia of the bowel which can lead to death.

Internal hernias rarely occurred after open surgeries due to presence of adhesions <sup>[13]</sup>. It's more common with laparoscopic surgeries. Most of the patients who had developed internal hernias will complain of intermittent non-specific abdominal pain and abdominal complains. Furthermore, patients with intermittent abdominal pain may in fact have an anatomic explanation for their complaints. These patients suggest that the benefits of mesenteric closure after laparoscopic colorectal surgery

should be examined further in patients with risk factors for development of internal hernia.

#### ACKNOWLEDGMENTS

The authors would like to thank King A Abdul-Aziz Hospital & Oncology Center for their cooperation and support and participants who cooperate for success of the study.

#### REFERENCES

1. **N Engl ,Med J(2004):** The Clinical Outcomes of Surgical Therapy Study Group: A comparison of laparoscopically assisted and open colectomy for colon cancer, *cancer*,350: 2050-2059.
2. **Lacy AM, Garcia-Valdecasas LC, Delgado S, Castells A, Taura P, Pique JM, Visa J (2002):**Laparoscopy-assisted colectomy versus open colectomy for treatment of non-metastatic colon cancer: a randomized trial. *Lancet*, 359: 2224-2229.
3. **Masubuchi S, Okuda J, Tanaka K, Kondo K, Asai K, Kayano H, Yamamoto M, Uchiyama K – (2013):** An internal hernia projecting through a mesenteric defect following laparoscopic-assisted partial resection of the transverse colon to the lesser omental cleft: report of a case. *Surg Today*, 43: 814-817.
4. **Blanc P, Delacoste F, Atger J- (2003) .** A rare cause of intestinal obstruction after laparoscopic colectomy. *Ann Chir.*,128: 617-621.
5. **Elio A, Veronese E, Frigo F, Residori C, Salvato S, Orcalli F (1998):** Ileal volvulus on internal hernia following left laparoscopic-assisted hemicolectomy. *Surg Laparosc Endosc.*, 8: 477-478.

6. **Cabot JC, Lee SA, Yoo J, Nasar A, Whelan RL, Feingold DL (2010):** Long-term consequences of not closing the mesenteric defect after laparoscopic right colectomy. *Dis Colon Rectum*, 53: 289-292.
7. **Sereno Trabaldo S, Anvari M, Leroy J, Marescaux J (2009):** Prevalence of internal hernias after laparoscopic colonic surgery. *J Gastrointest Surg.*,13: 1107-1110.
8. **Hosono S, Ohtani H, Arimoto Y, Kanamiya Y (2007):** Internal hernia with strangulation through a mesenteric defect after laparoscopy-assisted transverse colectomy: report of a case. *Surg Today*. 37: 330-341.
9. **Steele KE, Prokopwicz GP, Magnuson T, Lidor A, Schweitzer M (2008):** Laparoscopic antecolic Roux-en-Y gastric bypass with closure of internal defects leads to fewer internal hernias than the retrocolic approach. *Surg Endosc.*, 22: 2056-2061.
10. **Coleman MH, Awad ZT, Pomp A, Gagner M (2006):** Laparoscopic closure of the Petersen mesenteric defect. *Obes Surg.* ,16: 770-772.
11. **Row D, Maddineni S, Maffucci L, Rangraj M (2006):** Late sigmoid colon internal herniation into the jejuno-jejunostomy mesenteric defect after laparoscopic Roux-en-Y gastric bypass. *Obes Surg.*, 16: 208-210.
12. **H.S. Nair, □ K.A. Watt, and D.N. Anderson (2015):** Internal hernia and small bowel obstruction following open ileoanal pouch formation: A case report, 11: 68–70.
13. **G. Faria, □ J. Preto, M. Oliveira, T. Pimenta, M. Baptista, and J. Costa-Maia (2011):** Petersen's space hernia: A rare but expanding diagnosis, 2(6): 141–143.

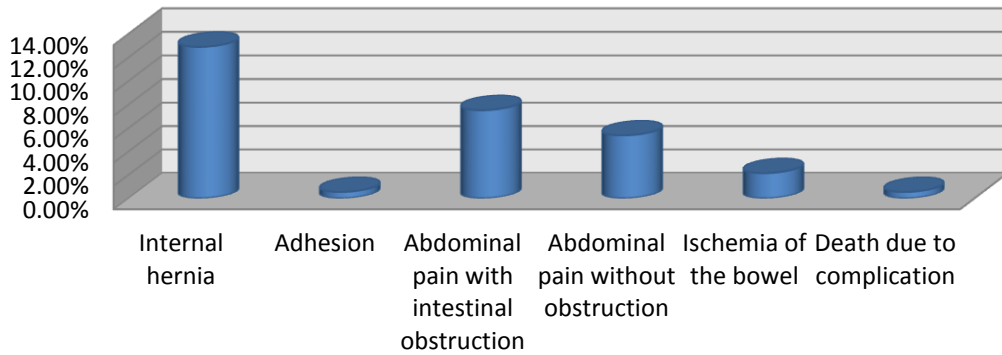
**Table (1): shows the Finding during Laparoscopic Procedure**

<b>Finding during Laparoscopic "exploring" for pathologies</b>		
Incidental hernia	18	4.84%
Mesenteric defect without hernia	90	24.19%
<b>Table (1): Finding during Laparoscopic Procedure</b>		

**Table (2): shows the incidence of conversion to open surgery**

<b>Mood of colorectal resection</b>	Number	Percentage
Laparoscopic	372	
Conversion to open Surgery	4	1.08%

**Fig (1) Incidence of Compliation followed Laprosopic Precedure**



**Fig (2) Location of the Hernia**

