

Role of Myxovirus Resistance Protein 1 (MXA) in Psoriatic Skin

Rehab Monir Samaka¹, Mohamed Ahmed Basha², Yara Mahmoud*²

Departments of ¹Pathology and ²Dermatology, Faculty of Medicine, Menoufia University

*Corresponding author: Yara Mahmoud, Telephone: +2- 01005538249, Email: yaramahmoud_1267@gmail.com

ABSTRACT

Background: Myxovirus-resistance protein 1 (MXA) is a key mediator of the interferon-induced antiviral response and is tightly regulated by type I IFNs. The expression of type I IFN signaling components is markedly increased in psoriasis skin lesions. The role of MXA in psoriasis pathogenesis is still poorly understood.

Objective: The aim was to investigate the role of MXA in psoriatic skin.

Material and Methods: Medline databases (PubMed, and Medscape) and all materials available in the internet were searched. The search was performed in December 2020.

Study selection: The initial search presented 120 articles. The number of studies that met the inclusion criteria was 17. The articles included diagnosed patients with chronic plaque psoriasis of both genders.

Data synthesis: Significant data were collected. Then a structured review was performed.

Data extraction: If the studies did not fulfill the inclusion criteria, they were excluded. Data from each eligible study were independently abstracted in duplicate using a data collection form to capture information on study characteristics, interventions, and quantitative results reported for each outcome of interest.

Finding: In total 9 potentially relevant publications were included; it was found that cytoplasmic localization of MXA in the keratinocytes of the psoriatic skin might play a private role in psoriasis pathogenesis.

Conclusion: Cytoplasmic localization of MXA in the keratinocytes of the psoriatic skin might play a private role in psoriasis pathogenesis. This can open a new gate for a target therapy in psoriasis.

Keywords: Myxovirus resistance protein 1, Psoriasis, Skin.

INTRODUCTION

Psoriasis is a chronic, inflammatory skin condition that affects between 2–4% of the general population, with recent estimates suggesting over one hundred twenty-five million patients worldwide. It is associated with a number of comorbidities as well as a high socioeconomic burden. Psoriasis patients also experience a decreased quality of life as a result of this disease. The pathogenesis of psoriasis is currently under active investigation, with studies aiming to identify genetic susceptibility loci for psoriasis in order to detect novel targets for systemic therapy. While the exact pathogenesis of psoriasis is not fully understood, basic and translational investigations have led to a renewed understanding of Th-17 and Th-1 pathways involved in the development of psoriasis⁽¹⁾.

Psoriasis is a chronic inflammatory also systemic disease with various co-morbidities, having been recently considered as a comprehensive disease named psoriatic disease or psoriatic syndrome. The autoimmune diseases are one form of its co-morbidities. In addition to the genetic background, shared pathogenesis including innate immunity, neutrophil extracellular trap (NETs), and type I interferon, as well as acquitted immunity such as T helper-17 (Th17) related cytokines are speculated to play a significant role in both psoriasis and

connective tissue diseases⁽²⁾.

The etiology of psoriasis is multifactorial and recently, researches on psoriasis pathogenesis have increased in a trial to get targeted and highly effective therapies⁽³⁾.

Type I interferons (IFNs) are an immunomodulatory class of cytokines that serve to protect against viral and bacterial infection. In addition there is evidence suggests IFNs, particularly type I but also IFN γ , are important to the pathogenesis of autoimmune and inflammatory skin diseases, such as cutaneous lupus erythematosus (CLE). Type I IFNs (α and β) are produced by recruited inflammatory cells and by the epidermis itself (IFN κ) and have important roles in autoimmune and inflammatory skin disease such as psoriasis⁽⁴⁾.

Myxovirus resistant protein 1 (Mx1) is the main IFN-induced intracellular restriction factor against influenza and influenza-like viruses in mice, and the Mx homologs in human serve similar functions⁽⁵⁾. Their expression is strictly controlled by type I and III IFNs. In humans, MX1 (also known as MxA) and MX2 (also known as MxB) are encoded by closely linked genes on the long arm of chromosome 21 (map position 21q22.3)⁽⁶⁾. Opposite to other IFN-stimulated genes, mx genes generally are not induced directly by viruses and are not expressed constitutively. In contrast, their expression is strictly



This article is an open access article distributed under the terms and conditions of the Creative Commons Attribution (CC BY-SA) license (<http://creativecommons.org/licenses/by/4.0/>)

dependent on IFN signaling⁽⁷⁾. Although some viruses like HIV may induce MxA without IFN type1, in general mx genes are excellent markers for IFN action⁽⁸⁾.

Psoriasis can often be triggered upon skin injury, known as Koebner phenomenon. Type 1 interferons (IFN α and IFN β), key cytokines that activate autoimmunity during viral infection, have been suggested to play an indispensable role in initiating psoriasis during skin injury. Type 1 IFN-inducible gene signature has been identified as one of the major upregulated gene signatures in psoriatic skin. Type 1 IFNs treatments often directly induce or exacerbate psoriasis, whereas blocking type 1 IFNs signaling pathway in animal models effectively inhibits the development of T cell-mediated skin inflammation and psoriasis-like inflammatory diseases⁽⁸⁾.

The expression of type I IFN signaling components is markedly increased in psoriatic skin lesions. Triggering this pathway through its physiologic receptor, however, it does not result in the induction of the regenerative epidermal phenotype of psoriatic lesions. Furthermore, responses to IFN- α stimulation do not differ between healthy, non-lesional, and lesional psoriatic skin⁽⁹⁾.

The aim was to investigate the localization of MXA in the keratinocytes of psoriatic skin by immunohistochemical study.

MATERIALS AND METHODS

Ethical approval:

This review was conducted according to guidance developed by the Center for Review and Dissemination. It was used to assess the methodology and outcome of the studies. **The study was approved by the Ethical Committee of the Faculty of Medicine, Menoufia University.**

Eligibility criteria:

We evaluated all studies that assessed expression of chronic plaque psoriasis diseases. We also included studies such as a case-control studies, a cross sectional studies, a cohort studies or a systematic reviews and meta-analyses. Both genders included. Diagnosed patients with chronic plaque psoriasis. Articles in English. Exclusion criteria:

Cases of other types of psoriasis. Treated patients with any topical or systemic therapy for at least four months prior to the study. Any dermatological diseases except chronic plaque psoriasis. Any associated inflammatory or autoimmune disease. Articles not in English. We did not restrict the search by date or publication status. During January 2021, we searched PubMed and Google Scholar using the MeSH terms: cytoplasm, immunohistochemistry, localization, myxovirus resistance protein 1, Psoriasis, Skin. We also browsed reference lists. Different methods of assessment were included. The article title and abstract were initially screened. Then the selected articles were read in full and further assessed for eligibility. All references from the eligible articles were reviewed to identify additional studies.

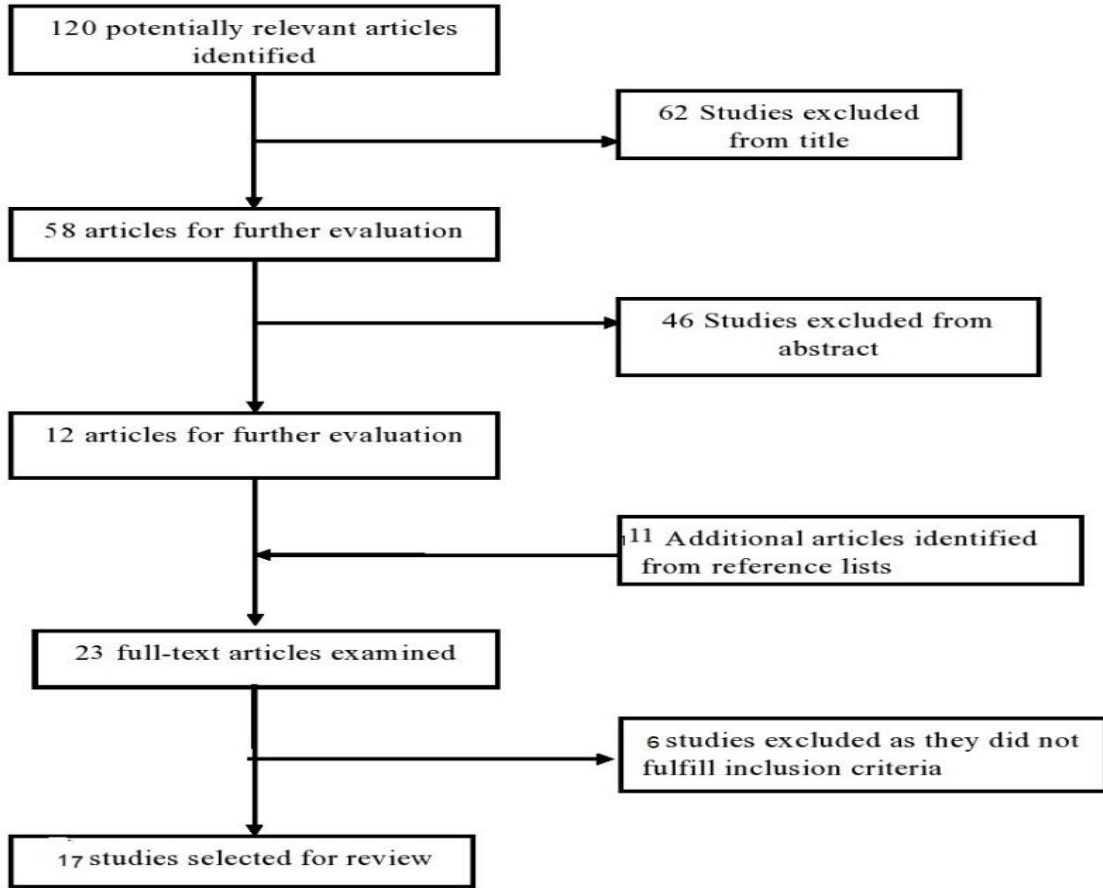
Search strategy: Search was performed in several databases. It included Medline database (articles in Medscape, PubMed) and also materials available in the internet. The search was performed in December 2020 and included all articles published. We used Myxovirus resistance protein 1, Psoriasis, Skin as searching terms. We also examined reference lists in relevant publications.

Quality Assessment: The quality of all the studies was assessed. Important factors included; study design, attainment of ethical approval, evidence of a power calculation, specified eligibility criteria, appropriate controls, adequate information and specified assessment measures. It was expected that confounding factors would be reported and controlled for and appropriate data analysis made in addition to an explanation of missing data.

Data synthesis: A structured systematic review was performed with the results tabulated.

RESULT

In total 120 potentially relevant publications were identified; 111 articles were excluded as they did not meet our inclusion criteria (Fig. 1). A total of 9 studies were included in the review as they were deemed eligible by fulfilling the inclusion criteria. The significant data were collected. A structured systematic review was performed and the results were tabulated in tables 1 and 2.



flow chart of study selection

Figure (1): Flow chart of study selection.

Table (1): Studies Investigating the Immunohistochemical Cytoplasmic Localization of Myxovirus Resistance Protein 1 (MXA) in Psoriatic Skin

Study Name	Type	Level of EBM
Fäh, 1995 ⁽¹⁰⁾	Analytic study	Level II-3
Jurg, 1994 ⁽¹¹⁾	Analytic study	Level II-3
Peter, 1994 ⁽¹²⁾	Systematic review and meta-analysis	Level II -2
Gilliet, 2004 ⁽¹³⁾	Analytic study	Level II-3
Nestle, 2005 ⁽¹⁴⁾	Both experimental and case control study	Level II-3
Emöke, 2011 ⁽¹⁵⁾	Analytic study	Level II-3
Seneschal, 2009 ⁽¹⁶⁾	Cross-sectional	Level II-3
Vyas, 2019 ⁽¹⁷⁾	Systematic review	Level II-2
Gearing, 1990 ⁽¹⁸⁾	Systematic review and meta-analysis	Level II -2

Table (2): Characteristics and results of studies included in the review article.

Study Name	Type	Level of EBM	Results and Conclusions
Fäh <i>et al.</i> 1995⁽¹⁰⁾	Analytic study	Level II-3	The MxA protein was detected immunohistochemically in some inflammatory skin lesions of unknown etiology as psoriasis and not detectable in various other dermatoses (eczema, scleroderma, urticaria, granulomatous and bullous disorders)
Jurg <i>et al.</i>, 1994⁽¹¹⁾	Analytic study	Level II-3	Investigated the MxA expression in biopsy specimens of 12 different dermatoses were therefore screened with an MxA-specific immunohistochemical monoclonal antibody. All eight studied psoriatic lesions in their study were positive for MxA protein. Moderate to strong epidermal staining was always present. In general, the staining was stronger in acute and fainter in chronic lesions. In acute lesions, overexpression of MxA protein were detected in all cells in the epidermis, dermis, and inflammatory infiltrate.
Peter <i>et al.</i> 1994⁽¹²⁾	Systematic review and meta-analysis	Level II - 2	The expression of MxA mRNA protein was observed in psoriatic keratinocytes (The specific mRNAs have been detected by in situ hybridization using antisense RNAs), but not in normal appearing keratinocytes adjacent to the lesions.
Gilliet <i>et al.</i> 2004⁽¹³⁾	Analytic study	Level II-3	The exacerbation of psoriasis was accompanied by a massive induction of lesional type I interferon activity, detected by MxA expression after imiquimod therapy by Immunohistological analysis.
Nestle <i>et al.</i> 2005⁽¹⁴⁾	Both experimental and case control study	Level II-3	Psoriatic plaque lesions, but not uninvolved skin or normal skin, consistently demonstrated by immunohistochemical analysis a significantly overexpression of MxA protein, a marker for IFN- α activity.
Emőke <i>et al.</i> 2011⁽¹⁵⁾	Analytic study	Level II-3	The expression of MxA (a key marker of type I IFN signaling) showed (by immunostaining) a marked decrease in lesional psoriatic skin treated with NB-UVB.
Seneschal <i>et al.</i> 2009⁽¹⁶⁾	Cross-sectional	Level II-3	A study detected strong production of protein MxA (represents a specific marker for IFN signaling) in the inflammatory cells of skin samples of anti-TNF- α -induced psoriasis (by immunohistochemical analysis).
Vyas <i>et al.</i> 2019⁽¹⁷⁾	Systematic review	Level II-2	Expression of MxA in dermal inflammatory infiltrate, was identified in Pustular psoriasis. Expression of MxA in the dermal infiltrate corresponds with a Th1 pathway in PS and may indicate a Th1 component in the early initial phase of acute generalized exanthematous pustulosis (AGEP).
Gearing, 1990⁽¹⁸⁾	Systematic review and meta-analysis	Level II - 2	The MxA staining of psoriatic skin implying the presence of biologically active INF in the psoriatic plaque.

DISCUSSION

Psoriasis is a chronic systemic inflammatory disease with various co-morbidities, having been recently considered as a comprehensive disease named psoriatic disease or psoriatic syndrome ⁽²⁾, while the exact pathogenesis of psoriasis is not fully understood, basic and translational investigations have led to a renewed understanding of Th-17 and Th-1 pathways involved in the development of psoriasis ⁽¹⁾. The etiology of psoriasis is also multifactorial. Recently, research on psoriasis pathogenesis has increased in a trial to get targeted and highly effective therapies ⁽³⁾.

Type I interferons (IFNs) are an immunomodulatory class of cytokines that serve to protect against viral and bacterial infection. In addition, mounting evidence suggests IFNs are important to the pathogenesis of autoimmune and inflammatory skin diseases such as psoriasis ⁽⁴⁾.

Myxovirus Resistant 1 (Mx1) is the main IFN-induced intracellular restriction factor against influenza and influenza-like viruses in mice, and the Mx homologs in human serve similar functions ⁽⁵⁾. Their expression is strictly controlled by type I and III IFNs. In humans, MX1 (also known as MxA) and MX2 (also known as MxB) are encoded by closely linked genes on the long arm of chromosome 21 (map position 21q22.3) ⁽⁶⁾.

The MxA protein was detected immunohistochemically in some inflammatory skin lesions of unknown etiology as psoriasis and not detectable in various other dermatoses (eczema, scleroderma, urticaria, granulomatous and bullous disorders) ⁽¹⁰⁾.

Also the MxA expression in biopsy specimens of 12 different dermatoses were screened with an MxA-specific immunohistochemical monoclonal antibody. All eight studied psoriatic lesions in this study were positive for MxA protein. Moderate to strong epidermal staining was always present. In general, the staining was stronger in acute and fainter in chronic lesions. In acute lesions, overexpression of MxA protein were detected in all cells in the epidermis, dermis, and inflammatory infiltrate ⁽¹¹⁾.

By insitu hybridization using antisense RNAs; the expression of MxA mRNA protein was observed in psoriatic keratinocytes but not in normal appearing keratinocytes adjacent to the lesions ⁽¹²⁾. And also MXA overexpression was detected by immunohistochemical analysis indicating exacerbation of psoriasis that was accompied by a

massive induction of lesional type I interferon activity and that was after imiquimod therapy ⁽¹³⁾.

There is a study that showed by tissue samples, immunohistochemistry, and confocal laser scanning microscopy (CLSM) analysis, significantly over expression of MxA protein, a marker for IFN- α activity and that was in psoriatic plaque lesions, but not uninvolved skin or normal skin ⁽¹⁴⁾. In another study immunostaining verified that the expression of MxA protein (a key marker of type I IFN signaling) showed a marked decrease in lesional psoriatic skin treated with NB-UVB ⁽¹⁵⁾. Another study detected increased immunohistochemical expression of the MxA protein in the inflammatory cells of skin samples of anti-TNF- α -induced psoriasis (by immunohistochemical analysis) ⁽¹⁶⁾. This study suggests that the MXA protein also may distinguish pustular psoriasis (PS) and acute generalized exanthematous pustulosis (AGEP) and can tell about the duration, as the presence of plasmacytoid dendritic cells (PDCs) and expression of MxA in dermal inflammatory infiltrate, as well as absence of eosinophils and presence of tortuous dilated capillaries favored a diagnosis of pustular psoriasis. Also the expression of MxA in the dermal infiltrate corresponds with a Th1 pathway in PS and may indicate a Th1 component in the early initial phase of AGEP (AGEP) ⁽¹⁷⁾. The MxA immunostaining of psoriatic skin implying the presence of biologically active INF in the psoriatic plaque ⁽¹⁸⁾.

Limitations:

This review has some limitations; first, small number of studies investigated the expression of tripartite motif-containing (TRIM) proteins in inflammatory skin diseases. Second, moderate quality of some studies included in this review may affect the reliability of the results. Third, there was shortage in the available clinico-pathological data to compare the expression with the pathological features and patients' outcome. Finally, no prospective studies were available of this meta-analysis.

CONCLUSION

Cytoplasmic localization of MXA in the keratinocytes of the psoriatic skin might play a private role in psoriasis pathogenesis .this can open a new gate for a target therapy in psoriasis.

Conflict of interest:

The authors declare no conflict of interest.

REFERENCES

1. **Gisoni A (2018):** Psoriasis and the metabolic syndrome. *Clin Dermatol.*, 36(1):21-28.
2. **Yamamoto T (2020):** Psoriasis and connective tissue diseases. *International Journal of Molecular Sciences*, 21(16): 5803.
3. **Rendon A, Schäkel K (2019):** Psoriasis pathogenesis and treatment. *Int J Mol Sci.* , 20(6):1475-78.
4. **Grace A, Hile J, Gudjonsson J et al. (2018):** The influence of interferon on healthy and diseased skin. *Cytokine*, 18: 132-36.
5. **Haller O, Staeheli P, Schwemmle M et al. (2015):** Mx GTPases: dynamin-like antiviral machines of innate immunity. *Trends Microbiol.*, 23:154–63.
6. **Horisberger M, Staeheli P, Haller O (1983):** Interferon induces a unique protein in mouse cells bearing a gene for resistance to influenza virus. *Proc Natl Acad Sci USA.*, 80:1910–4.
7. **Verhelst J, Hulpiau P, Saelens X (2013):** Mx proteins: antiviral gatekeepers that restrain the uninvited. *Microbiol Mol Biol Rev.*, 77:551–66.
8. **Zhang L (2019):** Type1 interferons potential initiating factors linking skin wounds with psoriasis pathogenesis. *Front Immunol.*, 10:1440-45.
9. **Chen J, Man X, Li W et al. (2013):** Regulation of involucrin in psoriatic epidermal keratinocytes: the roles of ERK1/2 and GSK-3 β . *Cell Biochem Biophys.*, 66(3):523-8.
10. **Fäh J, Pavlovic J, Burg G (1995):** Expression of MxA protein in inflammatory dermatoses. *J Histochem Cytochem.*, 43(1):47-52.
11. **Jurg F, Jovan P, Gunther B (1994):** Expression of MxA Protein in inflammatory dermatoses. *J Virol.*, 65:968-73.
12. **Peter S, Peter I, David C et al. (1994):** The type I interferon system is locally activated in psoriatic lesions. *Journal of Interferon Research*, 5: 229-234.
13. **Gilliet M, Conrad C, Geiges M (2004):** Psoriasis triggered by toll-like receptor 7 agonist imiquimod in the presence of dermal plasmacytoid dendritic cell precursors. *Arch Dermatol.*, 140(12):1490–1495.
14. **Nestle F, Conrad C, Tun-Kyi A (2005):** Plasmacytoid predendritic cells initiate psoriasis through interferon-alpha production. *J Exp Med.*, 202(1):135-143.
15. **Emöke R, Errol P, Prens A et al. (2011):** Effective treatment of psoriasis with narrow-band UVB phototherapy is linked to suppression of the IFN and Th17 pathways. *Journal of Investigative Dermatology*, 131(7): 1547-1558.
16. **Seneschal J, Milpied B, Vergier B et al. (2009):** Cytokine imbalance with increased production of interferon-alpha in psoriasiform eruptions associated with antitumour necrosis factor-alpha treatments. *Br J Dermatol.*, 161(5):1081-8.
17. **Vyas N, Charifa A, Desman G et al. (2019):** Distinguishing pustular psoriasis and acute generalized exanthematous pustulosis on the basis of plasmacytoid dendritic cells and MxA protein. *J Cutan Pathol.*, 46(5):317-326.
18. **Gearing A, Fincham N, Bird C et al. (1990):** Cytokines in skin lesions of psoriasis. *Cytokine*, 2:68-75.