

A Multi-Level Noncontiguous Vertebral Tuberculosis in Taif Province, Saudi Arabia: A Single Center Study.

Abdullah Ali Al-Zahrany^{1,2}

¹Department of orthopedics, College of Medicine, Taif University PO Box 888 Taif 21947, Kingdom of Saudi Arabia, ²Department of Surgery, King Abdul-Aziz Specialist Hospital, PO Box 10127, Taif, Kingdom of Saudi Arabia

e-mail: abdullazahrani@yahoo.com

ABSTRACT

Background and aim of the study: Multilevel noncontiguous spinal tuberculosis is an atypical form of the spinal tuberculosis, which leaves not less than two adjacent vertebrae intact between the two foci. The aim of this study is to record the incidence, pattern of presentation, risk factors; and diagnostic tools of multi-level noncontiguous vertebral tuberculosis in a single center (King Abdul Aziz Specialist Hospital) Taif, Saudi Arabia.

Patients and method: In this retrospective chart review study, we reviewed the records and data of all patients presented to King Abdul Aziz Specialist Hospital, Taif, Saudi Arabia from January 2009 to January 2014 and their diagnosis were proved to be spinal tuberculosis.

Results: the study included 76 patients with spinal tuberculosis; multilevel noncontiguous tuberculosis was detected in 18.4% and a single spinal lesion was identified in the other 81.6% of patients. There was no statistically significant difference between the 2 groups regarding their demographic, clinical, and their laboratory findings except for the hepatitis B virus (HBV) positivity and elevated serum transaminases which were significantly higher in the multilevel non contagious group of patients. Plain film detected multiple non contagious lesions in 64.3% of patients, and in 35.7% of them, they were first diagnosed as single lesion but MRI detected the multiplicity. The thoracic and lumbar vertebrae were involved in 85.7% of the multilevel lesions and in the other 14.3% of patients the cervical and lumbar involvement was detected. In the single focus group the thoracic and thoracolumbar vertebrae were involved in 75.8% of cases. Diagnosis was confirmed by culture and histopathology.

Conclusion: This study suggested a strong relation between hepatitis B and spinal tuberculosis, specially the multilevel non contagious form, however, till similar results of larger series of patients are obtained, the orthopedic surgeon must be with high index of suspicion in patients with spinal tuberculosis to detect multiplicity by MRI and any co infection with hepatitis B virus.

Keywords: spinal tuberculosis- multilevel non contagious – HBV –Taif

INTRODUCTION

Spinal tuberculosis which represents 50% of extrapulmonary tuberculosis was first described by Percival Pott in 1779.^(1,2) The disease usually results from hematogenous dissemination of the tubercle bacilli from primary foci in lung or lymph node to the vertebrae leading to destruction and collapse of the anterior parts of adjacent vertebrae and the disc spaces in between ending in kyphoscoliotic changes, formation of paravertebral cold abscesses, with or without paraplegia.⁽²⁻⁴⁾ The multilevel noncontiguous form leaves not less than two adjacent vertebrae intact between the affected vertebrae, and its incidence is reported to be 1-16% of spinal tuberculosis.⁽⁵⁾ Diagnosis of noncontiguous lesions can be achieved by plain radiology, however, magnetic resonance imaging (MRI) and computerized tomography (CT) can be

used if plain x-rays are not conclusive.⁽⁶⁻⁹⁾ The aim of this study is to record the incidence, pattern of presentation, risk factors; and diagnostic tools of

multi-level noncontiguous vertebral tuberculosis in a single center (King Abdul Aziz Specialist Hospital) Taif, Saudi Arabia.

Patients and methods:

This is a retrospective chart review study based upon reviewing the records of all patient who were diagnosed as Pott's disease in orthopedic department from January 2009 to January 2014. After approval of the ethical committee of the hospital and taking informed consents from patients or their relatives, data were collected from the patient files focusing on demographic factors, pattern of presentation, and imaging reports in addition to histopathology and

bacteriological culture results. Data were gathered and analyzed and records which were found incomplete or could not be properly evaluated were excluded from the study. After tabulation and coding of the collected data, statistical analysis was performed using SPSS program version 18.0. Descriptive statistics were done and qualitative data were expressed as number, percentage and mean \pm standard deviation. Quantitative variables were analyzed using Mc Nemar test for agreement between paired categorical data. The degree of significance was taken at P value which is considered significant if < 0.050 and non significant if higher.

RESULTS

Patient characteristics are shown in Table 1 and Figures 2 – 6. Study included 76 patients with Pott's disease, 49 males and 27 females, multilevel noncontiguous tuberculosis was detected in 14/76 patients (18.4%) and a single spinal lesion was identified in the other 62 patients, indicating significant prevalence of single spinal lesions amongst patients with Pott's disease. The patients with multilevel noncontiguous lesions; were 9 males and 5 females and their ages ranged between 20 - 65 years with mean age of 39.2 ± 3.4 years. 11/14 patients (78.6%) were hepatitis B positive and all of them had elevated transaminases (more than double the normal), however; 2 of the other 3 patients (HBV negative) had similar elevation in their liver enzymes. No one was HIV positive. The mean ESR was 81.3 ± 13.5 mm/h and the mean white cell count was 6.9 ± 1.3 thousands/ cmm. Four/14 (28.6%) patients were diabetics. Malnutrition was evident in all patients. The mean age of the single focus group was 37.64 ± 7.6 years and they were 38 males and 24 females. Their mean ESR and WBCs were 78.6 ± 17.5 mm/h and 8.1 ± 1.9 thousands/ cmm respectively. No one was HIV positive and 18/62 where HBV positive (29%). All the HBV positive cases had elevated liver enzymes ($>$ Twice the normal) and 7/44 patients (15.9%) who were negative for HBV had elevated liver enzymes. Fourteen patients of the single focus group where diabetics (22.6%). There was no statistically significant difference between the 2 groups regarding their demographic, clinical, and their laboratory findings except for the HBV positivity and elevated liver transaminases. 11/14 (78.6%) multilevel cases were non ambulant versus 39/62 (62.9%) of the single focus lesion ($P > 0.05$).

Plain film detected multiple noncontiguous lesions in 9/14 cases (64.3%), however, the other 5 lesions

(35.7%) were detected by MRI (Figures; 1, A & B). In 10/14 patients 2 noncontiguous lesions were detected (71.4%) and 3 lesions in 3/14 patients (21.4%) while the last patient had 4 lesions (7.2%). In multilevel patients, 12 patients (85.7) had thoracic and lumbar vertebrae involvement, in the other 2 patients (14.3%), the cervical and lumbar involvement was detected. In the single focus group the thoracic and thoracolumbar vertebrae were involved in 47/62 (75.8%), lumbar alone in 9 cases (14.5%) and cervical alone in the other 6 patients (9.7%). Diagnosis was confirmed by skin test, culture, polymerase chain reaction (PCR), and histopathology.

DISCUSSION

The prevalence of single lesion Pott's disease is significantly higher than multilevel variant as recorded in English literature which is in accordance with the findings in this study.⁽¹⁻⁶⁾ The reported incidence of Multi-level noncontiguous spinal tuberculosis varies from 1 to 16%.⁽⁴⁾ In the present series, multilevel noncontiguous lesions represented 18.4% of the cases, which is slightly higher than recorded in literature, however, Kaila *et al.*⁽³⁾, in their study, recorded noncontiguous spinal tuberculosis in 18% of their patients. The present series showed that 71.4% of the patients had 2 noncontiguous lesions and more than 2 in 28.6% of the patients. Similar results were recorded by Kaila *et al.*⁽³⁾, Godlwana *et al.*⁽¹⁰⁾, and Iliyasu and Babashani⁽¹¹⁾. In accordance with other studies, the findings of the present study showed that the spinal tuberculosis tends to affect adults more than children in west and Middle East.⁽⁵⁾

Noncontiguous spinal tuberculosis is proved by many investigators to be related to multiple factors which include; diabetes, malnutrition, ethnic factors and most of the authors found that HIV is not a risk factor.⁽¹²⁻¹⁵⁾ In this study, similar results were obtained; no one was HIV positive, malnutrition was recorded nearly in all patients, and diabetes was recorded in 28.6% and in 22.6% of the multilevel and single focus lesions respectively. Strikingly, it was found that 78.6% of the multilevel patients of this study were hepatitis B positive versus 29% of the single focus patients and over 90% of the multilevel patients had elevated transaminases versus about 40% of the patients with single lesion, No similar results were recorded by other investigators; this may be due to the smaller number of patient in our series but, environmental, genetic, or even ritual factors must be considered; however, most of the

investigators proved that tuberculosis is the most common cause of death in hepatitis B patients, though, the mode of transmission of both diseases are quite different.⁽⁸⁻⁹⁾The relation of hepatitis B infection and spinal tuberculosis, especially multilevel non contagious category must be investigated in a larger studies, and the orthopedic surgeon must be aware about such co infection to avoid its hazards on the patient and the caring staff.

Differentiation between multilevel non contagious spinal tuberculosis and single tuberculous lesion on clinical bases is quite difficult as proved by many authors.⁽¹⁻⁷⁾This study verified that there was no statistically significant difference between the single and multilevel patients regarding their demographic and clinical findings.

Whole spine scanning by MRI or CT is recommended by many investigators to detect noncontiguous vertebral lesions, though in the majority of cases it is evident by plain radiology; however, most of the authors found that histopathology is required to confirm the diagnosis of tuberculous spinal lesions verifying that it is more sensitive than microbiology.^(2-7, 19, 20)

In this retrospective series plain film detected multiple non contagious lesions in 64.3%, and the other 35.7% were detected by MRI, even though, the diagnosis was confirmed by skin test, culture, polymerase chain reaction (PCR), and histopathology which was in agreement with the findings in other studies.

CONCLUSION

This study suggested a strong relation between hepatitis B viral infection and spinal tuberculosis, specially the multilevel non contagious form, however, till similar results of larger series of patients are obtained, the orthopedic surgeon must be with high index of suspicion in patients with spinal tuberculosis to detect multiplicity by MRI and any co infection with HBV.

REFEENCES

1. **Jain AK (2010).** Tuberculosis of the spine: a fresh look at an old disease. *J Bone Joint Surg Br.*,92: 905–13
2. **Talbot JC, Bismil Q, Saralaya D, Newton DA, Frizzel RM, Shaw DL (2007).** Musculoskeletal tuberculosis in Bradford – a 6-year review. *Ann R Col ISurg Engl.*,89:405–9
3. **Kaila R, Malhi AM, Mahmood B, Saifuddin A (2007).** The incidence of multiple level noncontiguous vertebral tuberculosis detected using whole spine MRI. *J Spinal Disord Tech.*,20: 78–81
4. **Lee K Y (2014).** Comparison of Pyogenic Spondylitis and Tuberculous Spondylitis. *Asian Spine J.*, 8: 216–23.
5. **Jain AK, Dhammi IK (2007).** Tuberculosis of the spine: a review. *Clin Orthop Relat Res.*,460:39–49
6. **Garg RK, Somvanshi DS (2011).** Spinal tuberculosis: A review *J Spinal Cord Med.*, 34: 440–54
7. **Burrill J, Williams CJ, Bain G, Conder G, Hine AL, Misra RR (2007).** Tuberculosis: a radiologic review. *Radiographics.*,27: 1255–73
8. **Kuniholm M.H., Mark J., Aladashvili M., Shubladze N., et al. (2007).** Risk factors and algorithms to identify hepatitis C, hepatitis B, and HIV among Georgian tuberculosis patients. *Int. Soc. Inf. Dis.*, 42: 203-8.
9. **Lifson A.R., Thai D., O’Fallon A., Mills K. Hang W.A. (2007).** Prevalence of tuberculosis, hepatitis B virus, and intestinal parasitic infections among refugees to Minnesota. *Public Health Rep.*,117: 69-77.
10. **Godlwana L, Gounden P, Ngubo P, Nsibandze T, Nyawo K, Puckree T (2008).** Incidence and profile of spinal tuberculosis in patients at the only public hospital admitting such patients in KwaZulu-Natal. *Spinal Cord.*,46: 372–4
11. **Iliyasu Z, Babashani M (2009).** Prevalence and predictors of tuberculosis coinfection among HIV-seropositive patients attending the Aminu Kano Teaching Hospital, northern Nigeria. *J Epidemiol.*,19: 81–7.
12. **Polley P, Dunn R (2009).** Noncontiguous spinal tuberculosis: incidence and management. *Eur Spine J.*,18:1096–101
13. **Alavi SM, Sharifi M (2010).** Tuberculous spondylitis: risk factors and clinical/paraclinical aspects in the south west of Iran. *J Infect Public Health.*,3:196–200
14. **Cormican L, Hammal R, Messenger J, Milburn HJ (2006).** Current difficulties in the diagnosis and management of spinal tuberculosis. *Postgrad Med J.*, 82: 46–51.
15. **Owolabi LF, Nagoda MM, Samaila AA, Aliyu I (2010).** Spinal tuberculosis in adults: a study of 87 cases in Northwestern Nigeria. *Neurology Asia.*,15: 239–44
16. **Bowong S, Kurths J (2010).** Modelling Tuberculosis and Hepatitis B Co-infections. *Mathematical Modelling of Natural Phenomena.*, 5: 196-242.
17. **Lavanchy D (2004).** Hepatitis B virus epidemiology, disease burden, treatment and current and emerging prevention and control measures. *J. Viral. Hepat.*,11: 97-107.
18. **Lucifora J, Xia Y, Reisinger F, Zhang K, Stadler D, Cheng X, et al. (2014).** Specific and nonhepatotoxic degradation of nuclear hepatitis B virus cccDNA. *Science.*,14:1221-8.
19. **Gautam MP, Karki P, Rijal S, Singh R (2005).** Pott's spine and Pott's paraplegia. *J Nep Med Assoc.*,44:106–15
20. **Pandey V, Chawla K, Acharya K, Rao S, Rao S (2009).** The role of polymerase chain reaction in the management of osteoarticular tuberculosis. *Int Orthop.*,33: 801–5
21. **Griffith JF, Kumta SM, Leung PC, Cheng JC, Chow LT, Metreweli C (2002).** Imaging of musculoskeletal tuberculosis: a new look at an old disease. *Clin Orthop Relat Res.*,398: 32–9

Table 1: showing patient characteristics

	Patients with multiple level spinal tuberculosis	Patients with solitary lesion	P-value	Significance
Total number	14/76(18.4%)	62/76(81.6%)	0.017	S
Males	9/14(64.3%)	38/62(61.3%)	0.874	NS
Females	5/14(35.7%)	24/62(38.7%)	0.432	NS
Age (mean in years)	39.2±3.4	37.64±7.6	1.003	NS
HBV + ve	11/14(78.6%)	18/62(29%)	0.016	S
Elevated transaminases	13/14(92.9%)	25/62(40.3%)	0.024	S
HIV +ve	0(0%)	0(0%)	1.040	NS
Mean ESR (mm/hour)	81.3±13.5	78.6±17.5mm/hour	0.986	NS
Total leukocyte count	6.9±1.3	8.1±1.9	0.873	NS
Diabetics	4/1428.6%	14/62(22.6%)	0.431	NS

HBV: hepatitis B virus, HIV: human immune deficiency virus, S: significant – NS: Non Significant

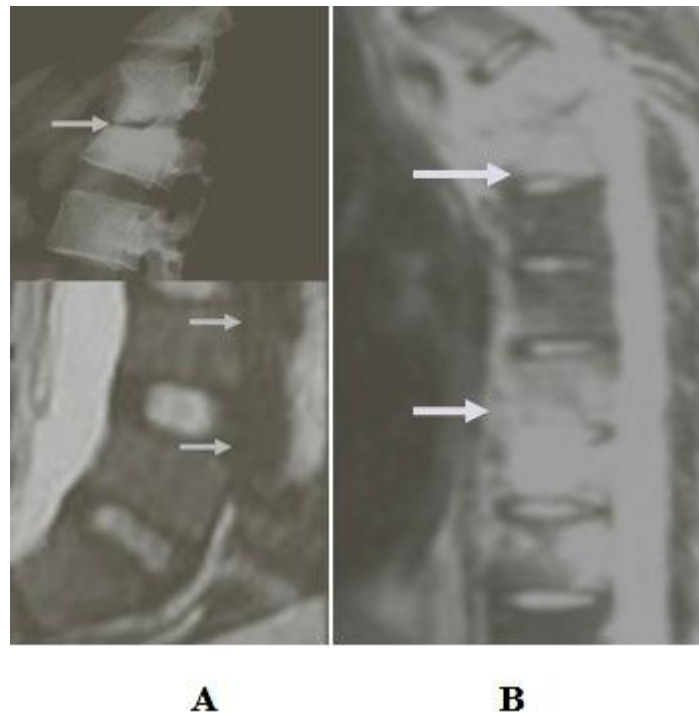


Figure 1: **A**, Plain X-rays discovered single thoracic lesion and MRI scan revealed early 2 lumbar lesions. **B**, MRI scan detected thoracic and lumbar lesions in kyphotic patient

Figure 2: methods of radiological detection

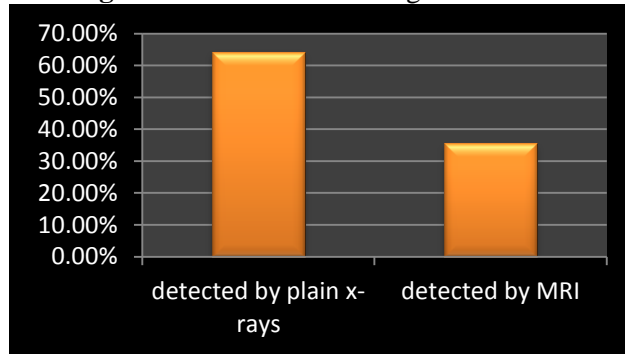


Figure 3: number of multiple lesions

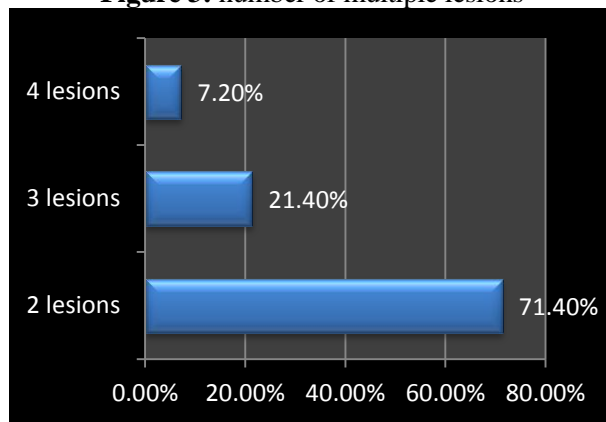


Figure 4: site of multiple lesions

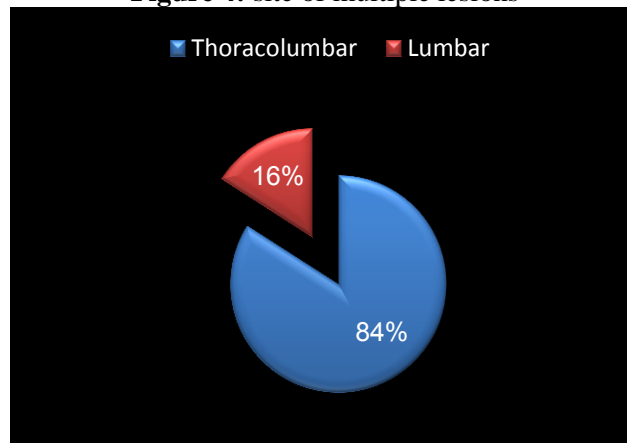


Figure 5: site of solitary lesions

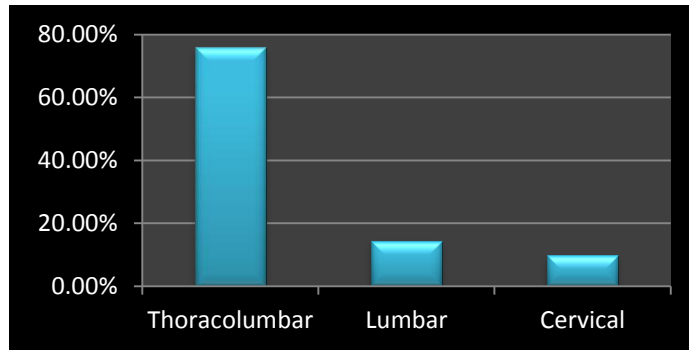


Figure 6: comparison between patients with solitary and multiple lesions regarding the associated Hepatitis B virus infection and serum transaminases

