

Immunohistochemical Studies in Mice Liver Immunized by Attenuated *Schistosoma Mansoni* Schistosomules by Gamma Radiation

Mona Mohamed Amin - Eman Naser Hafez - Elham Said Marei

Health Radiation Research Dept., National Centre for Radiation Research and Technology (NCRRT),
E.mail of corresponding author: eman_naser612@hotmail.com Tel. +201068429907 P. O. Box: 29 Nasr
City, Egypt.

ABSTRACT

Background: Schistosomiasis is an important cause of hepatic fibrosis in man. As etiological therapy alone is not enough to treat hepatic fibrosis, finding other strategies that can control the disease is important. Considering the dominant role of vaccination, research on gamma radiation-attenuated vaccine has become a new focus and has very promising value.

Aim of the work: The objective of this study was to detect the effect of vaccination with attenuating dose of gamma radiation of schistosomules in controlling immunohistochemical changes in mice model of human schistosomiasis mansoni. **Materials and methods:** Forty mice were divided into four groups (ten each). Group A served as normal control, group B was infected by subcutaneous (S. C.) injection with 100 *S. mansoni* cercariae/mouse (infected control), group C was vaccinated by (S.C.) injection with 500 schistosomulae irradiated with 20 Krad gamma-radiation (vaccine control) and group D was vaccinated by (S.C.) injection with the same dose of irradiated schistosomules and then challenged after 4 weeks by S.C. injection with 100 *S. mansoni* cercariae. Expression of α -smooth muscle actin (α SMA), desmin, collagen type-1 and transforming growth factor-beta1 (TGF- β 1) in the extracellular matrix (ECM) using immunohistochemistry were done.

Results: exhibited in infected control group B marked expression of α -SMA, desmin, collagen type-1 and TGF- β 1. These changes were moderate in vaccinated-control group C while few changes were detected in vaccinated-challenged group D.

Conclusion: It was concluded that using 20 Krad-gamma irradiated schistosomules as vaccine is effective in controlling liver pathology and reduces immunohistochemical changes.

Keywords: *Schistosoma mansoni*, Gamma-attenuation, Schistosomules, Immunohistochemistry, Liver.

INTRODUCTION

Schistosomiasis remains one of the most prevalent parasitic diseases in the world. Despite the existence of an effective antischistosome drug, the disease is spreading and national control programs do complete their tasks.⁽¹⁾ Vaccine strategies represent an essential component for the future control of schistosomiasis, as an adjunct to chemotherapy.⁽²⁾ Attenuation of infective cercariae has traditionally been achieved using a gamma source of radiation.⁽³⁾ Cercaria loses some of its potency immediately after artificial conversion to skin-stage schistosomula and was considered as the first important source of antigens in the body.⁽⁴⁾ Also most attention has been focused on molecules released from or exposed at schistosomular surface.⁽⁵⁾ So schistosomula was chosen in this study as there was a complex set of polypeptides exposed on the surface of the newly

transformed schistosomula and it was considered as an important target of protective

immunity. Following gamma irradiation, larvae of *S. mansoni* have been shown to lose their ability to migrate with normal kinetics through the host's circulation. They were retarded in the skin or lungs, where the parasites die.⁽⁶⁾ Human immune response to schistosome eggs deposited in the liver and the granulomatous inflammation they evoke are the initial factors of hepatoschistosomiasis, with a peri-parasitic extracellular matrix (ECM)-rich 'barrier' that acts to restrict cyst growth but, paradoxically, may prevent successful drug interactions with the parasite.⁽⁷⁾ This extracellular matrix (ECM) includes collagen and connective tissue cells.⁽⁸⁾

For the liver to function normally, solutes and growth factors in the blood plasma can pass through fenestrae in liver endothelial

cells where they come in contact with hepatocytes. Upon activation, the hepatic stellate cells (HSC) undergo a process of trans-differentiation from a vitamin A-storing cell to a myofibroblast phenotype.⁽⁹⁾ The myofibroblasts produce ECM that impedes the flow of solutes to the hepatocytes and, as a result of accumulating ECM products the hepatocytes lose their microvilli thereby stopping the liver functioning effectively.⁽¹⁰⁾

In response to inflammatory injury, HSCs are characterized by the expression of alpha smooth muscle actin (α -SMA), the intermediate filament desmin, the secretion of excessive collagens and the production of various pro-fibrosis cytokines such as transforming growth factor-beta (TGF- β).⁽¹¹⁻¹⁴⁾ Staining for markers such as desmin and α -SMA occurred at the edges of granulomas with HSC activation detectable after 6 weeks post-*S. japonicum* infection, coinciding with the TH₂ shift and down-modulation of granuloma size. It was reported that peak activation of HSC was observed in mice between 8-10 weeks post-infection, measured by α -SMA expression. A further study of the *S. japonicum* model again demonstrated staining for α -SMA positive cells in the fibrotic area of granulomas. Staining in this model coincided with the up-regulation of genes associated with hepatic fibrosis and HSC activation as well as chemokines associated with HSC recruitment.⁽¹⁵⁾

Among the numerous cytokines and growth factors that are involved in hepatic fibrosis, TGF- β , especially TGF- β 1. TGF- β not only maintains the progressive activation of myofibroblasts, but also activates other silent HSCs.⁽¹⁶⁻¹⁸⁾

The aim of this study was to detect the effect of vaccination with gamma radiation-attenuated schistosomules in schistosomiasis *mansoni* infected mice regarding hepatic immunohistochemical changes.

MATERIALS AND METHODS

Parasite and Animals

An Egyptian strain *S. mansoni* cercariae were purchased from the Schistosome Biological Supply Program (SBSP) at Theodor Bilharz Research Institute, Imbaba, Giza, Egypt and the vitality was confirmed by microscopy. Schistosomulae were obtained 14 days post-infection by perfusion technique

using citrated saline of Hamster's lung previously infected with 4000 cercariae.⁽¹⁹⁾

Attenuation of the Parasite:

S. mansoni schistosomules were attenuated by irradiation (NCRRT) Cairo, Egypt using indian cobalt-60 gamma chamber 4000 A irradiator. They were exposed to 20 Krad of gamma radiation at 2.5 Krad/h at the time of experimentation.⁽²⁰⁾

Experimental design

Forty male albino mice of Balb/C strain, weighing 20–25 g for each, were obtained from the Ministry of agriculture breed house. They were maintained at the animal house of the National Center for Radiation Research and Technology (NCRRT), Cairo, Egypt according to the ethics committee of the National Research Center and in accordance to the "Guide for the care and use of laboratory animals" published by the US National Institutes of laboratory animal Resources.⁽²¹⁾ The local IAUCC or ethical committee has reviewed and approved the actions and protocols detailed in the report. Mice were randomly divided into four groups, including a normal control group (group A), infected control group (group B) was infected with 100 *S. mansoni* cercariae, vaccinated control group (group C) was vaccinated with 500 schistosomulae irradiated with 20 Krad gamma-radiation and vaccinated-challenged group (group D) was vaccinated with the same vaccine and then challenged 4 weeks by S.C. injection with 100 *S. mansoni* cercariae. All animals were maintained under specific pathogen-free conditions. Sacrification of all mice was done 8 weeks post challenge.

Immunohistochemistry

Immunohistochemical staining was performed with an HRP-Polymer anti-Mouse/Rabbit IHC Kit (MAIXINBIO, China, Catalog Number: KIT-5020). The sections were dewaxed, dehydrated, washed in phosphate-buffered saline (PBS, 0.01 mol/L, pH 7.2) 3 × 5 min, heated at 100 °C in a microwave oven 6 × 2 min, incubated in 3% H₂O₂ in deionized water for 10 min to block endogenous peroxides activity, and washed 3 × 5 min with PBS. After deparaffinization, the sections were given pretreatment for antigen retrieval in the following way: For detection of α -smooth muscle actin (α -SMA) the sections were pretreated with target retrieval solution (TRS, DAKO A/S, Glostrup, Denmark) for 20 min at 97°C. For the anti-desmin antibody the

sections were first pretreated with trypsin (1mg/ml, Sigma®, Steinheim, Germany) for 15 min at 37°C and then with TRS at 97°C for 20 min. For the anti-collagen type-1 antibody the sections were pretreated with pepsin (4 mg/ml) for 2 hrs at 37°C followed by trypsin (1mg/ml) for 15 min at 37°C. For TGF-β1, the sections were pretreated with rabbit TGF-β1 antibody for 20 min at 37°C.^(22, 23)

Statistical analysis

Results were subjected to Student's *t*-test using SPSS program version 8 to determine the significance of the data. Data are expressed as mean ± standard error. Values with $P < 0.05$, $P < 0.01$ and $P < 0.001$ are significant, highly significant and very highly significant respectively.

RESULTS

1- α-SMA

Liver tissue of mice in normal control group (A) showed expression of α-SMA evaluated by 94.9 ± 12.2 (Table 1, Fig. 1). Liver tissue of mice in infected control group (B) showed strong deposition of α-SMA in portal areas and interhepatic sinusoids with high significant increase as $P < 0.001$ (Figs. 2,3,4). Compared to the control infected group, the number of cells expressing α-SMA in portal areas and interhepatic sinusoids was decreased (632.6 ± 28.3) with moderate expression of stain in vaccinated- control group (C) (Fig. 5). While, in vaccinated-challenged group (D), there was weak expression of α-SMA (337.3 ± 23.7) with high significant decrease ($P < 0.001$) (Fig. 6).

2- Desmin

Expression of desmin in cells of liver of normal control group (A) was 115.6 ± 10.9 (Table 1, Fig. 7). In mice of group (B) (infected control), there was strong deposition of desmin in portal tract and hepatic sinusoids (1081.5 ± 20.2) with high significant increase ($P < 0.001$) compared to normal control group (Figs. 8,9,10). The expression of desmin showed moderate deposition in vaccinated-control group (C) (730.7 ± 18.3) (Fig. 11). On the other hand, vaccinated-challenged group (D) showed weak expression of desmin stain (335.9 ± 15.5) (Fig 12).

3- Collagen

Immunohistochemical results showed expression of collagen in normal control group (A) (117.1 ± 17.7) (Table 1, Fig 13). On the other hand, dense deposition of collagen was recorded in infected control group (B)

(1330.2 ± 65.5) (Figs. 14,15,16) with high significant difference ($P < 0.001$). In group (C) (vaccinated - control), the positive traces were reduced compared to group (B) (847.4 ± 23.3) (Fig. 17). Vaccinated-challenged group (D) showed weak deposition of collagen (405.7 ± 18.4) (Fig. 18).

4- TGF-β1

The expression of TGF-β1 in normal control group (A) is recorded by 231.2 ± 9.8 (Table 1, Fig. 19). In infected control group (B), strong densely TGF-β1-stained cells which could be distinguished by their brownish color surrounded and infiltrated the portal tract and hepatic sinusoids (1675.1 ± 55.5) (Figs. 20, 21, 22). In vaccinated -control group (C), the intensity of positive traces was reduced compared to group (B) (705.1 ± 19.9) (Fig. 23). In vaccinated - challenged group (D) few dispersed brown traces were detected (322.0 ± 12.0) (Fig. 24).

DISCUSSION

There has been a major effort to develop immunization procedures for protecting populations at risk against schistosome infection, and a number of candidate vaccine antigens have been identified.⁽²⁴⁾ In human, the nature of the disease is largely immunological and only indirectly due to the parasitic worm itself. The pathological lesions emanate from inflammatory reactions to the large number of parasite eggs which are retained in host tissues rather than excreted with the faeces or urine to infect the snail.⁽²⁵⁾

Immunohistochemical changes were studied to detect collagen, α-SMA, desmin and TGF-β1 in connective tissue cells involved in ECM production in liver of mice infected with schistosomiasis mansoni and vaccinated with 20 Krad gamma radiation-attenuated schistosomules.

In the present study, control infected group B showed densely-stained cells with marked expression α-SMA surrounded and infiltrated in the porteal areas and hepatic sinusoides. This was in agreement with study of Baddamwar *et al.* (2004) who found expression α-SMA in cells of fibroblast morphology in portal and septal areas in infected livers and they suggested that these cells are myofibroblasts or myofibroblast-like cells that are involved in the increased production of extracellular matrix (ECM) in

infection with *S. japonicum*.⁽²²⁾ In control vaccinated group C, the intensity of positive traces was reduced compared to infected control group B however, few dispersed traces were seen in vaccinated-challenged group D.

Desmin showed minimal expression in normal liver cells (group A). It was reported that desmin is rarely expressed by hepatic stellate cells (HSC) in normal human liver.⁽²⁶⁾ The expression was severe in control infected group B, which is in agreement with previous findings of Wake and Sato⁽²⁷⁾ who found an increase in desmin expression in pig infected with *schistosoma japonicum*. Desmin was detected in smooth muscle cells in vessel walls in portal and septal areas and it could be used as a marker of portal vein destruction.⁽²²⁾ Andrade *et al.*⁽⁸⁾ stated that desmin was expressed by smooth muscle cells that disrupted by granulomatous inflammation and obstruction in chronic human hepatosplenic schistosomiasis. In present study, vaccinated-control group C the expression was moderate and vaccinated-challenged group D showed mild expression of desmin.

Collagen type 1 showed marked expression in control infected group B which was in agreement with previous studies^(28-29, 8) stated that Collagen type-1 is a major constituent of the ECM in liver fibrosis in chronic human and murine schistosomiasis mansoni. In vaccinated-control group C, the expression was moderate while vaccinated-challenged group D showed weak expression of collagen type-1

Regarding TGF- β 1, there was marked expression in control infected group B that was in accordance to Bergquist *et al.*⁽²⁴⁾ who reported an increase in TGF- β 1 in group of mice infected with *S. japonicum* cercariae to induce a schistosomal hepatic fibrosis. Also, Farah *et al.*⁽³⁰⁾ who demonstrated that repeated infection of *S. mansoni*-infected baboons primed lymphocytes to produce increased levels of TGF- β and IL-4 which are known pro-fibrogenic cytokines. Vaccinated-control group (C) showed moderate expression of TGF- β 1 while vaccinated-challenged group (D) showed few expression.

Vaccinated-control group C showed moderate expression of all α -SMA, desmin, collagen and TGF- β 1 while, vaccinated-challenged group D showed mild immunohistochemical parameters. This was in accordance with Hafez *et l.*⁽³¹⁾ who reported

that vaccination with 20 Krad gamma irradiated schistosomules revealed more immunoregulatory mechanisms in vaccinated-challenged groups than that in vaccinated-control group.

CONCLUSION

In conclusion, this study confirmed previous observations that there is an increase in expression of α -SMA, desmine, collagen type-1 and TGF- β 1 in infected group of mice. While, there was decrease in their expression in vaccinated control group which may be explained due to the immunogenic effect of the living attenuated larvae which was recognized as protein antigen. In vaccinated-challenged group, there was little expression and this can be explained by the cercarial exposures after vaccination trigger more immunoregulatory mechanisms.

ACKNOWLEDGEMENT:

The authors would like to thank the National center for radiation, research and technology for providing the gamma radiation sources and provide facilities for experiments in animal house.

REFERENCES

1. Sulbarán G, Noya O, Brito B, Ballén DE, & Cesari IM, (2013): Immunoprotection of Mice against Schistosomiasis Mansoni Using Solubilized Membrane Antigens. *PloS. Negl. Trop. Dis.*, 7(6): 2254.
2. McManus DP, & Loukas A (2008): A Current status of vaccines for schistosomiasis. *Clinical Microbiology*, (4): 225.
3. Minard P, Dean DA, Jacobson RH, Vannier WE, & Murrell KD, (1978): Immunization of mice with cobalt-60 irradiated *Schistosoma mansoni* cercariae. *Am. J. Trop. Med. Hyg.*, 27: 76.
4. Sher A, & Benno D, (1982): Decreasing immunogenicity of developing *schistosoma*- larva. *J. Parasitol. Immunol.*, 4: 101.
5. Simpson AJG & Cioli D (1987): Progress towards a defined vaccine for schistosomiasis. *Parasitol. Today*, 3: 26.
6. Mastin AJ, Bickle QD, & Wilson RA (1983): *Schistosoma mansoni*: migration and attrition of irradiated and challenge schistosomula in the mouse. *Parasitology*, 87: 87.
7. Vuitton DA, (2003): The ambiguous role of immunity in echinococcosis: protection of the host or of the parasite? *Acta Trop.*, 85: 119.
8. Andrade ZA, Peixoto E, Guerret S & Grimaud JA (1992): Hepatic connective tissue changes in hepatosplenic schistosomiasis. *Hum. Pathol.*, 23: 566.

- 9. Friedman SL, (2003):** Liver fibrosis -- from bench to bedside. *J. Hepatol.*, 38: 38.
- 10. Friedman SL, (2008):** Mechanisms of hepatic fibrogenesis. *Gastroenterology*, 134: 1655.
- 11. Bolmont C, Andujar M, Peyrol S & Grimaud JA (1991):** Desmin expression in fibroblasts of murine periovular granuloma during liver *Schistosoma mansoni* infection. *Differentiation*, 46: 89.
- 12. Brenner DA (2009):** Molecular pathogenesis of liver fibrosis. *Trans. Am. Clin. Climatol. Assoc.*, 120: 361.
- 13. Senoo H, Yoshikawa K, Morii M, Miura M, Imai K & Mezaki Y (2010):** Hepatic stellate cell (vitamin A-storing cell) and its relative- past, present and future. *Cell Biol. Int.*, 34: 1247.
- 14. Bartley PB, Ramm GA, Jones MK, Ruddell RG, Li Y, McManus DP (2006):** A contributory role for activated hepatic stellate cells in the dynamics of *Schistosoma japonicum* egg-induced fibrosis. *Int. J. Parasitol.*, 36: 993.
- 15. Burke ML, McManus DP, Ramm GA, Duke M, Li Y, Jones MK & Gobert GN (1993):** Temporal expression of chemokines dictates the hepatic inflammatory infiltrate in a murine model of schistosomiasis. *PLoS Negl. Trop. Dis.*, 4:e598.
- 16. Paiva LA, Maya-Monteiro CM, Bandeira-Melo C, Silva PM, El-Cheikh MC, Teodoro AJ, Borojevic R, Perez SA & Bozza PT (2010):** Interplay of cysteinyl leukotrienes and TGF- β in the activation of hepatic stellate cells from *Schistosoma mansoni* granulomas. *Biochim. Biophys. Acta.* 1801: 1341.
- 17. Baghy K, Iozzo RV & Kovalszky I (2012):** Decorin-TGF β axis in hepatic fibrosis and cirrhosis. *J. Histochem. Cytochem.*, 60: 262.
- 18. Dooley S & Dijke P (2012):** TGF- β in progression of liver disease. *Cell Tissue Res.*, 347: 245.
- 19. Mangold BL & Knopf PK (1978):** The effect of assay conditions on the recovery of schistosomula from the lungs of normal and resistant rats infected with *S. mansoni*. *J. Parasitol.*, 64, (50): 813.
- 20. El Gawish MAM, Moawad MAF, Mahmoud NFA (1999):** The immune response of rats inoculated with irradiated cysts of *Toxoplasma gondii*. *Egypt J. Med. Sci.*, 20: 1.
- 21. National Research Council (1996):** *National science education standards* Washington, DC: National Academy Press.
- 22. Baddamwar AA, Lee Willingham AL, Maria H & Hurst ML (2004):** A Histopathological and Immunohistochemical Study of Hepatic Fibrosis in Experimental *Schistosoma japonicum* Infection in Pigs, Master of Science Programme in Veterinary Medicine for International Students Faculty of Veterinary Medicine and Animal Science Swedish University of Agricultural Sciences (46): 1403.
- 23. Chen B, Peng J, Li Q, Yang M, Wang Y, Chen W (2013):** Exogenous bone morphogenetic protein-7 reduces hepatic fibrosis in *Schistosoma japonicum* -infected mice via transforming growth factor- β /Smad signaling. *World J. Gastroenterol.*, 19(9): 1405.
- 24. Bergquist NR, Hall BF & James SL (1994):** Schistosomiasis vaccine development translating basic research into practical results. *J. Immunol.*, 2: 131.
- 25. Yang KS, Wang XH, Yang GJ & Wu XH (2008):** An integrated approach to identify distribution of oncomelania hupensis, the intermediate host of *S. japonicum*, in a mountainous region in China. *Int. J. Parasitol.*, 38: 1007.
- 26. Schmitt-Gräff A, Kruger S, Bochar F, Gabbiani G & Denk H (1991):** Modulation of alpha smooth muscle actin and desmin expression in perisinusoidal cells of normal and diseased human livers. *Am. J. Pathol.*, 138: 1233.
- 27. Wake K and Sato T (1993):** Intralobular heterogeneity of perisinusoidal stellate cells in porcine liver. *Cell Tissue Res.*, (273): 227.
- 28. Biempica L, Dunn MA, Kamel IA, Kamel R, Hait PK, Fleischner C, Biempica SL, Wu CH & Rojkind M (1983):** Liver collagen-type characterization in human schistosomiasis. A histological, ultrastructural, and immunocytochemical correlation. *Am. J. Trop. Med. Hyg.*, 32: 316.
- 29. Grimaud JA, Boros DL, Takiya C, Mathew RC & Emonard H (1987):** Collagen isotypes, laminin, and fibronectin in granulomas of the liver and intestines of *Schistosoma mansoni*-infected mice. *Am. J. Trop. Med. Hyg.*, 37: 335.
- 30. Farah IO, Mola PW, Kariuki TM, Nyindo, M, Blanton RE & King CL (2000):** Repeated exposure induces periportal fibrosis in *Schistosoma mansoni*-infected baboons: role of TGF-beta and IL-4. *J. Immunol.*, 164: 5337.
- 31. Hafez EN, Gaffar SAM, El-Ahl SAS and Moawad MA (2009):** Assessment of vaccination with schistosomules attenuated by using different doses of γ - radiation on experimental schistosomiasis mansoni. Thesis submitted for partial fulfillment of M.D. degree in parasitology. Faculty of girls Al-Azhar university.

Table 1: Immunohistochemical changes in liver of mice of experimental groups

Groups Parameters	Group A Normal control	Group B Infected control	Group C vaccinated – unchallenged	Group D vaccinated – challenged
α-SMA	94.9±12.2	1064.9±91.7 ^a	632.6±28.3 ^{a,a₁}	337.3±23.7 ^{a,b₁}
Desmin	115.6±10.9	1081.5±20.2 ^a	730.7±18.3 ^{a,a₁}	335.9±15.5 ^{a,a₁}
Collagen	117.1±17.7	1330.2±65.5 ^a	847.4±23.3 ^{a,a₁}	405.7±18.4 ^{a,a₁}
TGF-β1	231.2±9.8	1675.1±55.5 ^a	705.1±19.9 ^{a,a₁}	322.0±12.0 ^{a,a₁}

Data are expressed as mean ± SE. Number of mice in each group is ten.

P values a < 0.001; b < 0.01; c < 0.5 and n.s non significant compared to control normal group.

P values a₁ < 0.001; b₁ < 0.01; c₁ < 0.5 and n.s.₁ non significant compared to control infected group

α- SMA

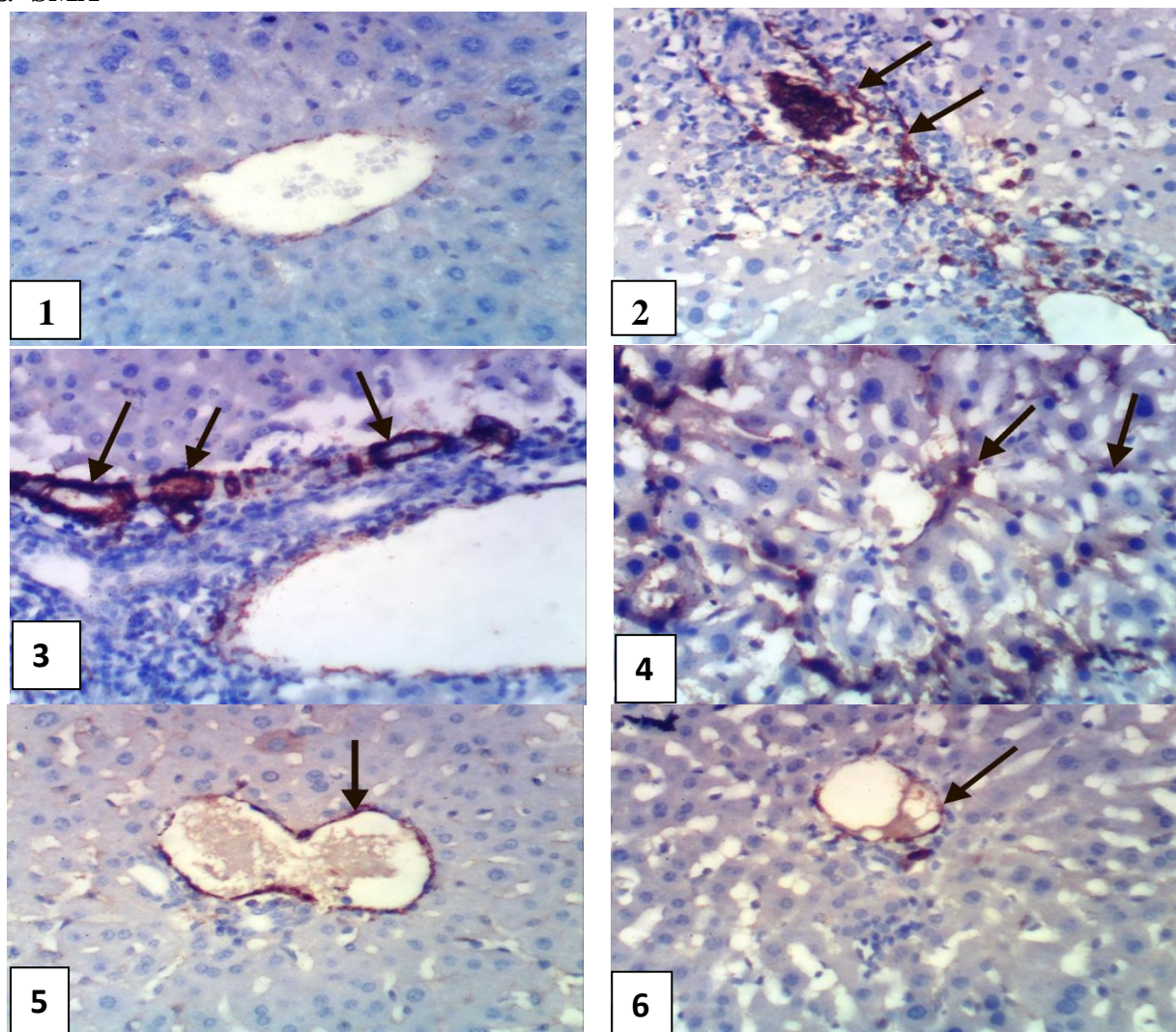


Fig. (1): Immunohistochemical staining of α -SMA in liver of mice from group A showing few expression of α -SMA (X 400).

Figs. (2,3,4): Immunohistochemical staining of α -SMA in liver of mice from group B showing strong positive expression of α -SMA(→) in portal areas and hepatic sinusoids (X 400).

Fig. (5): Immunohistochemical staining of α -SMA in liver of mice from group C showing moderate positive expression (→) (X 400).

Fig. (6): Immunohistochemical staining of α -SMA in liver of mice from group D showing weak positive expression (→) (X 400).

Desmin

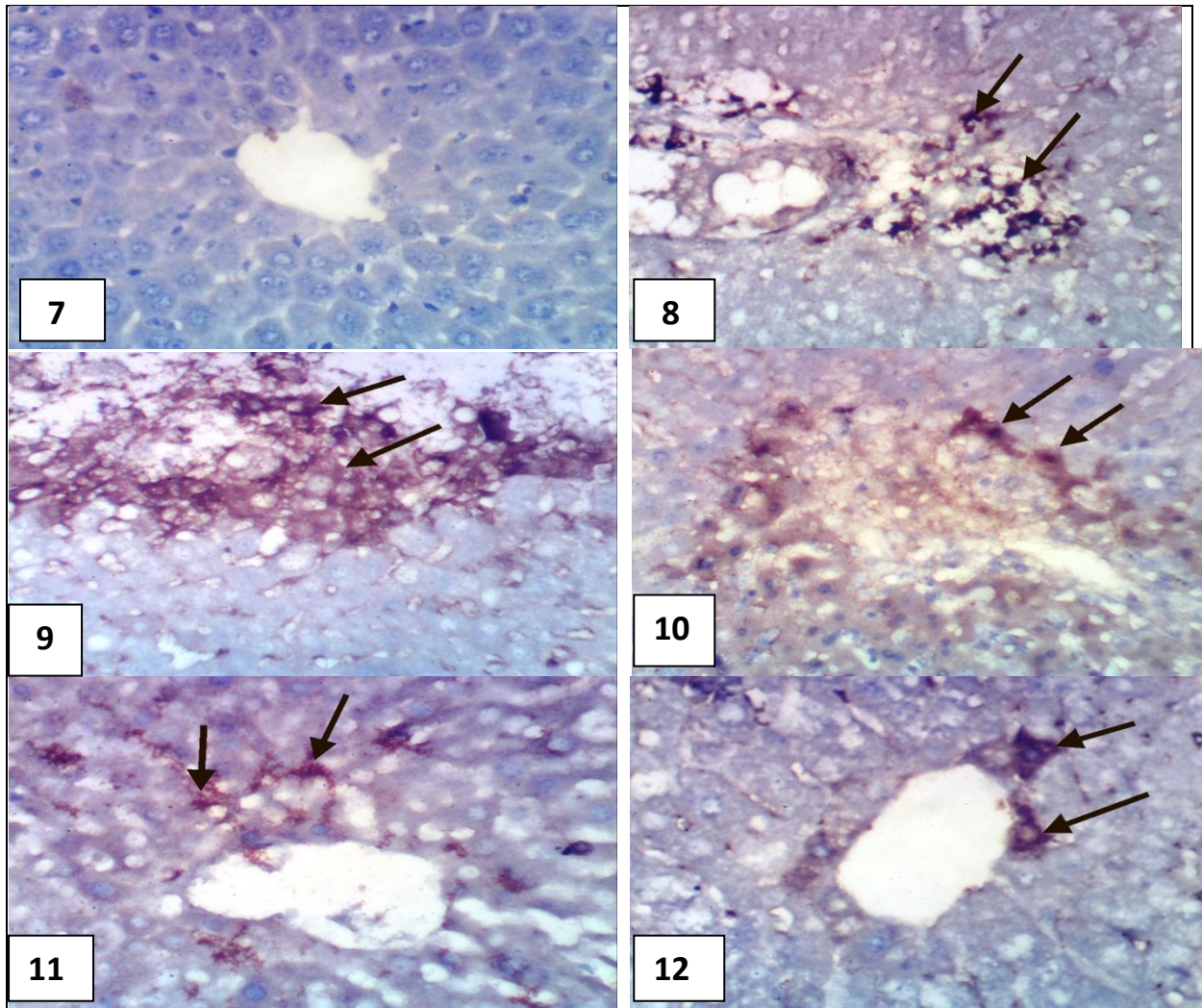


Fig. (7): Immunohistochemical staining of desmin in liver of mice from group A showing few expression of desmin (X 400).

Figs. (8, 9, 10): Immunohistochemical staining of desmin in liver of mice from group B showing strong positive expression (→) in portal areas and hepatic sinusoids (brown colour) (X 400).

Fig. (11): Immunohistochemical staining of desmin in liver of mice from group C showing moderate positive expression (→) (X 400).

Fig. (12): Immunohistochemical staining of desmin in liver of mice from group D showing weak positive expression (→) (X 400).

Collagen

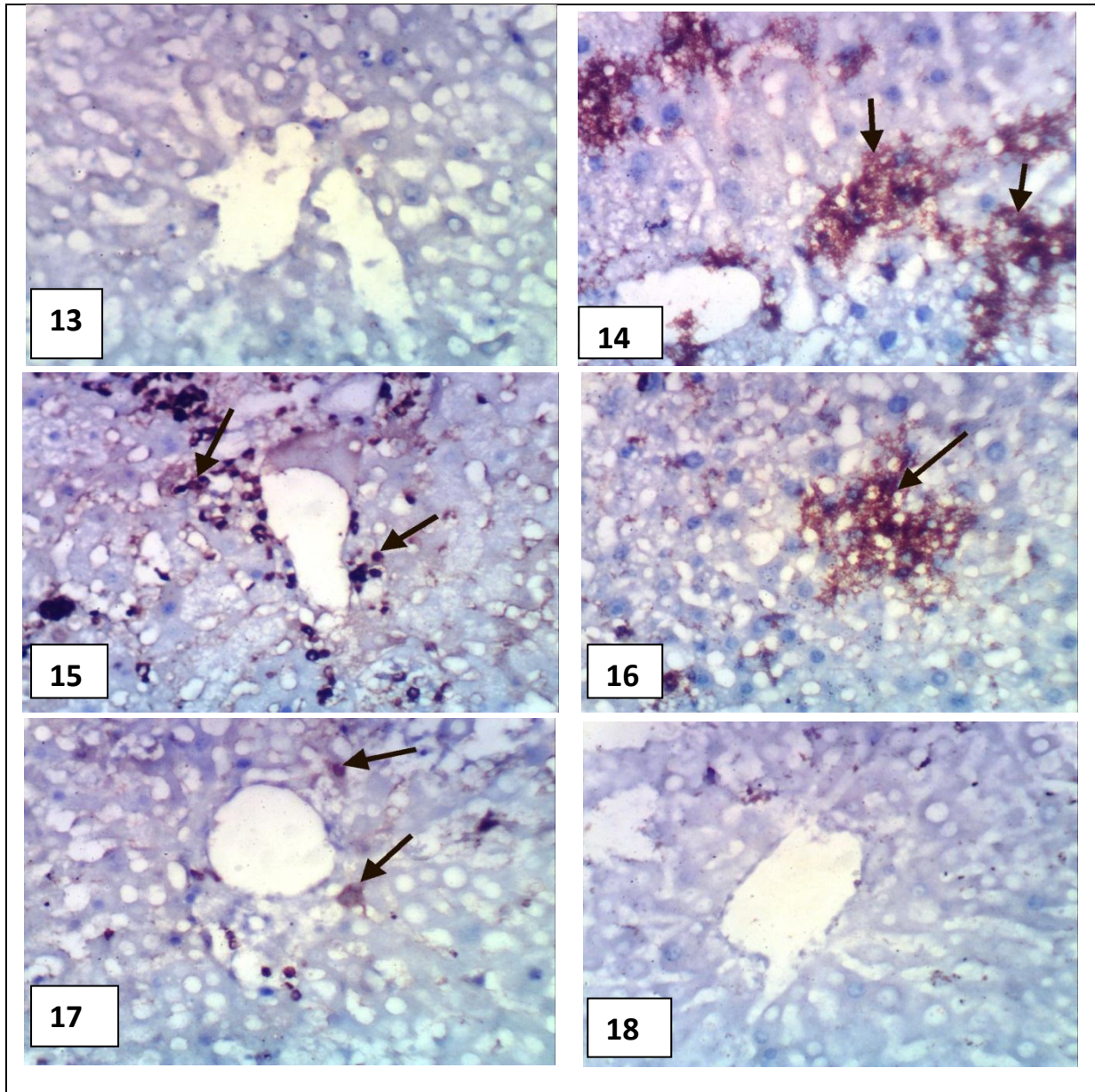


Fig. (13): Immunohistochemical staining of collagen in liver of mice from group A showing few expression of collagen (X 400).

Figs. (14,15,16): Immunohistochemical staining of collagen in liver of mice from group B showing strong positive expression of collagen (→) in portal areas and hepatic sinusoids (X 400).

Fig. (17): Immunohistochemical staining of collagen in liver of mice from group C showing concentric network (→) of collagen (X 400).

Fig. (18): Immunohistochemical staining of collagen in liver of mice from group D showing weak expression of collagen (X400).

TGF- β 1

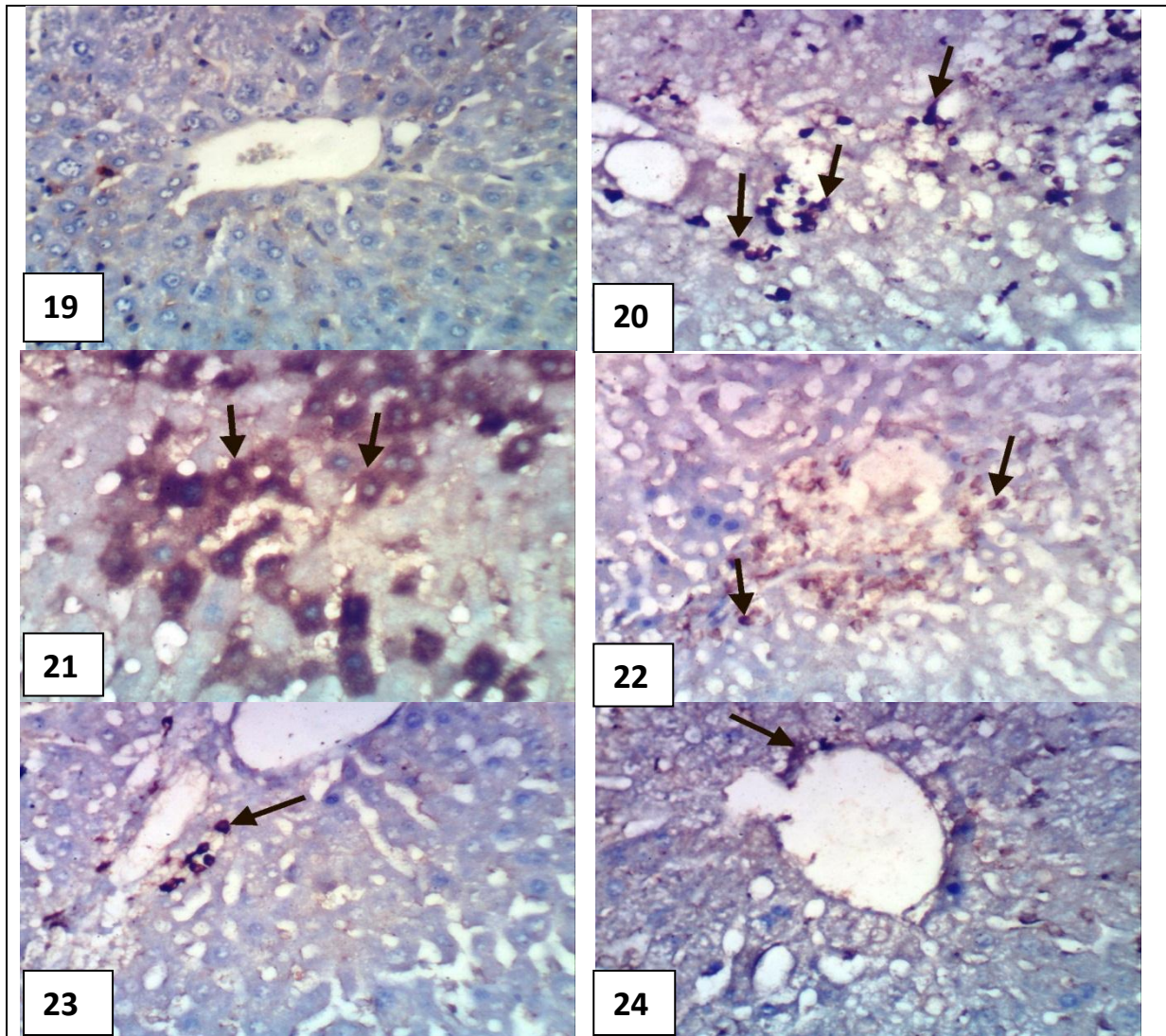


Fig. (19): Immunohistochemical staining of TGF- β 1 in liver of mice from group A showing few expression of TGF- β 1 (X 400).

Figs. (20,21,22): Immunohistochemical staining of TGF- β 1 in liver of mice from group B showing strong positive expression of TGF- β 1 (\rightarrow) in portal areas and hepatic sinusoids (X 400).

Fig. (23): Immunohistochemical staining of TGF- β 1 in liver of mice from group C showing moderate TGF- β 1 expression (\rightarrow) (X 400).

Fig. (24): Immunohistochemical staining of TGF- β 1 in liver of mice from group D showing weak expression of TGF- β 1 (\rightarrow) (X 400).