

The Effect of Clarithromycin Administration on Pregnant Albino Rats during the Cleavage Period of Gestation and on Their Embryos

Asmaa M. Kandil¹, Gabri M.S.², Maiada Moustafa², and Nehad Mohamed.²

¹Pharmacology Dep., National Organization for Drug Control and Research (NODCAR).

²Zoology and Entomology department, Faculty of Science, Helwan University

ABSTRACT

Background: Clarithromycin is a macrolide antibiotic used to treat common infections including respiratory tract, skin and *Helicobacter pylori*. This work investigates whether the administration of clarithromycin to pregnant females during the cleavage phase of gestation was associated with a risk of miscarriages and offspring morphological malformation and skeletal anomalies, histological changes and DNA fragmentation of embryos and liver of pregnant rats.

Two major groups of pregnant albino rats were used. The animals of the control group received distilled water from the 1st to 7th days of gestation. One subgroup (C1) was sacrificed on the 8th day; and the other (C2) was sacrificed on the 20th day of gestation. The treated group was drenched 45 mg/kg clarithromycin (therapeutic dose) suspension from 1st to 7th day of gestation. The first subgroup (T1) was sacrificed on the 8th day and the other (T2) was sacrificed on the 20th day of gestation.

Results: The obtained results showed a decrease in maternal body weight gain, increase in the rate of abortion, resorption and growth retardation of fetuses and some malformation in the skeletal system of the treated group. Histopathological studies of pregnant and fetal rats revealed congestion and dilatation of the central vein, fatty degeneration of the hepatocytes and severe DNA fragmentation.

Keywords: Macrolides, Clarithromycin, cleavage phase, teratology, skeletal malformation, rat and liver histopathology, germ layers, DNA fragmentation.

INTRODUCTION:

Macrolides are a group of related compounds that have a lactone ring (14 to 16 atoms) bonded to one or more deoxysugar molecules^[1]. They are generally well tolerated, and allergy to macrolides is an uncommon event (occurring in 0.4%-3% of treatments)^[1].

Clarithromycin, a new macrolide antibiotic, is effective in the management of a wide range of clinical problems, including outpatient treatment of community-acquired pneumonia, shortening the course of peptic ulcer disease associated with *Helicobacter pylori* infection and curing previously resistant respiratory infections in immunocompromised patients. It is generally well tolerated, producing fewer gastrointestinal complaints than its parent compound, erythromycin. For these reasons, it is frequently prescribed in adult and pediatric settings^[2].

Clarithromycin exerts its antibacterial action by binding to the 50S ribosomal subunit of susceptible organisms and inhibiting protein synthesis through translocation of aminoacyl transfer RNA^[3].

Clarithromycin has been extensively used for treatment of infections caused by chlamydia, mycoplasma, legionella, *Helicobacter pylori*, and *mycobacterium avium* complex.^[4]

The type of malformation induced by a teratogen is dependent not only on the nature and dosage of the agent but also on the precise developmental stage of the embryo.^[5] Animal studies have shown that clarithromycin can induce fetal loss in rabbits and monkeys when used in very low dosages and in high dosages, respectively^[6]. One observational study concerning pregnant women showed a doubling of the number of miscarriages in women exposed to clarithromycin in early pregnancy compared to a match control group^[6].

Only limited data are available concerning the effect of clarithromycin on the human fetus when used in pregnancy^[6]. The patient must then be informed of the potential risks involved in the treatment plan. This work studies the effect of a therapeutic dose of clarithromycin on pregnant rats and their

fetuses when administrated during the cleavage period of gestation.

MATERIAL AND METHODS:

I-Material:

1- **Drug Administration:** The modified release tablet of clarithromycin (Abbott Company) was the form of drug used in the present study. The drug suspension was orally administrated to the pregnant rats. The therapeutic dose in adult human is 500 mg/kg daily. The tablets were suspended in distilled water and used in a dose of 45 mg/Kg to female rats which is equivalent to therapeutic dose of human calculated according to Paget and Barnes (1964)^[7].

2- **Experimental animals and design:** Males and female (11-13 weeks old) albino rats were used in this study. Two regular estrus cycle females were selected in the pro-estrus stage and caged with a healthy and vigorous male overnight with suitable environmental condition of temperature, humidity and light. Each morning a vaginal smear was prepared according to the method of Snell (1956)^[8]. Zero day of gestation was determined by the presence of sperms in the vaginal smear^[9]. Pregnant females were divided into four groups, each consisting of (6-8 rats):

C1:- received distilled water from the 1st to 7th day and sacrificed on the 8th day of gestation (served as control group).

T1:- drenched 45mg/Kg suspension of clarithromycin from the 1st to 7th day and sacrificed on the 8th day of gestation.

C2:- received distilled water from the 1st to 7th day and sacrificed on the 20th day of gestation (served as control group).

T2:- drenched 45mg/Kg of clarithromycin suspension from the 1st to 7th day of gestation and sacrificed on the 20th day of gestation.

II- Methods:

Vaginal smear was examined at the next day of mating and the pregnant rats were isolated and the body weights were recorded. The steady increase in the mothers' body weights related to the pregnancy days, while the sudden decrease of it is a sign of abortion.

1- Signs of toxicity:

The following parameters were measured: mother's body weight, percentage

of abortion, uterine weight, number of resorption sites, number of alive and dead fetuses, placental weight, fetal growth parameters (total body weight, crown-rump length and tail lengths).

2-Morphological Examination:

The fetuses were examined for the occurrence of any malformation using the dissecting microscope.

3-Endoskeleton staining and examination:

Fetuses were skinned and carefully eviscerated to permit satisfactory penetration by the stain. Fixation was done in 95% ethyl alcohol for hardening of the specimens. Staining was done with double staining of fetal skeletons with alcian blue for cartilage and alizarin red for bone according to the method described by Peters (1977)^[10]. After staining the specimens were kept in glycerin. The skeleton was examined under the dissecting binocular microscope to study any malformation and shortening in the bones of fetuses.

4-Histological Examinations:

Maternal and fetal livers at 20th day as well as whole 8th day embryos were prepared and stained by haematoxylen and eosin and examined using light microscope (Leica).

5-Molecular biology study:

DNA fragmentation was determined by agarose gel electrophoresis, total genomic DNA was isolated from mother liver and the liver of 20th day fetuses as well as from the whole 8th day embryos according to Miller *et al.* (1988)^[11] using DNA Purification Kit (Promega, Promega Corporation, USA). Agarose gel electrophoresis of DNA was done according to the method of Sealey and Southern (1982).^[12]

6- Statistical analysis:

Results were analyzed by Prism version 5 software. Data were analyzed by the one-way analysis of variance (ANOVA) followed by Tukey-Kramer's Multiple Comparison Test. Comparison between the means of two different groups was carried out using the unpaired t- test where P<0.05 was considered significant^[13]. All the values were presented as means \pm standard deviations of the means (S.D.M.) for the tables and as mean \pm standard error of the means (S.E.M.) for the graphs.

RESULTS

I-Morphological studies:

1- Effects of Clarithromycin on Maternal rats:

1.1- Change in body weight gain:

The average gain in maternal body weight during the experimental period was recorded for the control and treated groups (Table 1 & Fig. 3).

Pregnant rats of all tested groups showed a steady increase in weight gain during the gestation period. The rate of increase in maternal body weight (weight gain) during the gestation period was less— in experimental groups than in the control.

The weight gain of pregnant rats treated with clarithromycin (45mg/Kg) from the 1st. to 7th. day of gestation and scarified on the 8th (T1) and on the 20th day(T2) were insignificantly increased at (P<0.05) compared to that of the control group.

1.2- Rate of abortion:

The percentage of abortion (completely or partially) was calculated and recorded in table (1).The numbers of abortion in all treated groups are greater-than the control groups.

The percentage of abortion in T1 (28.57%) was twice that for the control (14.2%) group. For the T2 group, the percentage of abortion was 16.66% compared to 0% for the control group.

1.3- Total uterine weight:

The total uterine weight of the treated groups drenched with clarithromycin during the early stage of gestation and sacrificed at 8th (T1) and 20th (T2) days of gestation were insignificantly different. It was higher than control in rats sacrificed on the 8th day but lower in rats sacrificed on the 20th day compared to their control (Table 1 & Fig. 4).

1.4-The placental weight and index:

In T2 (from the 1st to 7th days of gestation and scarified on the 20th day) the placental weight for the treated group significantly decreased by 29.79% than that of the control group. (Table 2 & Fig. 5)

2- Effects of clarithromycin on fetuses

2.1- Fetal mortality:

Total mortality rate included resorbed and dead fetuses at birth were recorded for control and experimental groups in table (3).

The uteri of control pregnant rats showed symmetric distribution of fetuses on both horns (Fig. 6A). Meanwhile, the uteri of clarithromycin- treated pregnant rats showed partial or total resorption (Fig 6 B&C and Table 3).

2.2- Growth retardation:

The morphological examination of the fetuses showed that clarithromycin treatment causes growth retardation represented by decrease in fetal body weight, body length and tail length (Figs. 7). The fetal body weight and tail length decreased but with no significant values from that for control group but the body length decreased significantly by 13.6%.

2.3-External anomalies:

The anomalies of fetuses are represented in table (4) and figure (1&8). Examination of fetuses showed marked hematoma manifested as dark red patches on different parts of the head, fore and hind- limbs and on the back (Fig.8). Also, these fetuses showed greyish skin (congested body) and bending tail (Fig.8). Brachydactyly was manifested by shortness of digits, fingers or toes and contraction in the fore and hind limbs in some fetuses in treated group. Paralysis in the fore limb and edema in fore and hind limbs were also observed in these fetuses (Fig. 8).

2.4. Skeletal Anomalies:

The fetuses of treated group showed fetal skeletal abnormalities including mild degree of lack of ossification of squamosal and hind limb bones. Shortness in 13th rib was also observed (Table 5, Fig. 2&9).

II-Histological results

1- Effect of Clarithromycin on maternal liver:

Examination of transverse sections of the livers of pregnant rats treated with clarithromycin during the cleavage period of pregnancy (from 1st to the 7th day) showed some histo-pathological changes as shown in fig. (10). Livers from T1 dams had many pyknotic nuclei, aggregated Kupffer cells, dilation in sinusoids, and degenerated vacuolated hepatocytes. Also, in some sections there was interstitial congestion and hydropic degeneration (Fig. 10 C&D).

Livers from T2 dams showed lymphocytic infiltration, few pyknotic nuclei,

dilation in sinusoids, and distribution of many nuclei with peripheral chromatin and degenerated vacuolated hepatocytes (Fig.10 E&F).

2- **Effect of clarithromycin on fetal histopathology:**

Examination of transverse sections of the livers of fetuses maternally treated with 45 mg/kg clarithromycin from 1st to 7th day and sacrificed on the 20th day of gestation showed pyknotic nuclei, interstitial haemorrhage and hydrobic degeneration (Fig. 11a&b).

III-Molecular Biology Study:

Effect of clarithromycin on maternal and fetal Genomic DNA:

The genomic DNA extracted from liver of treated pregnant rats and their embryos by clarithromycin is affected and showed fragmentation (Fig.12a-c).

DISCUSSION:

Clarithromycin is a semisynthetic macrolide antibiotic that is well tolerated orally and intravenously and is approved to treat infections in children.^[14]

The result of this study revealed that clarithromycin administration caused decrease in maternal body weight gain, placental weight and uterine weight during pregnancy as well as a percentage of abortion and resorption compared to the control group. Clarithromycin, a pregnancy category C drug and has a higher placental passage rate than other macrolide antibiotics. The mean trans-placental transfer of clarithromycin was 6.1%.^[15] Although the use of clarithromycin in the early pregnancy caused valuable miscarriage rate (28.57%), there were no evidence of fetal toxicity in the survival fetuses in our study.

The findings of this study strengthen the animal study on the reproductive and developmental toxicity of clarithromycin that showed an association with various congenital defects when used but in very high doses (150 mg/kg per day).^[16] **Schick et al. (1996)**^[17] studied thirty four cases of human pregnant female exposures to clarithromycin during the first and early second trimesters and recorded small percentages of abortion (13.8%).^[18] Also, there was a higher rate of spontaneous

abortions in the untreated group.^[19] An observational study showed that women treated with clarithromycin in the first trimester had a doubling of the number of miscarriages compared to a control group.^[6] Although the finding was statistically significant compared to the control group the authors noted that the number of miscarriages in the exposed group was within the expected range and they concluded that clarithromycin can be taken safely in pregnancy. The mean trans-placental transfer of clarithromycin was 6.1%,^[16] the obtained abortion may be attributed to higher drug concentration in umbilical cord or neonatal serum than in maternal serum due to the high trans-placental transfer of clarithromycin in the treated groups.

It was demonstrated that oxidative stress influences multiple physiological processes, from oocyte maturation to fertilization, embryo development and pregnancy.^[20] Also oxidative stress influences both implantation and early embryo development which decides a successful pregnancy. Also, clarithromycin inhibit ATP-binding cassette (ABC) transporter protein. ABC proteins commonly known as P-glycoprotein, encoded by the ABCB1/MDR1 gene; this was the first mammalian transporter to be associated with drug efflux and is arguably the best characterized xenobiotic transporter.^[21] Placental ABCB1/MDR1 expression is higher early in gestation compared to term possibly reflecting the greater need to protect the fetus against xenobiotics in early pregnancy which is the time of greatest teratogenicity risk.^[22, 23, 24] The level of repairing in the treated group (early embryonic period) is higher due to the longest time between the clarithromycin administration and scarification time. ABC transporters are involved in the protection of cells from the damaging effects of oxidative stress,^[25] dependently, clarithromycin increase the damaging hazards of oxidative stress in the embryos.

It is known that pregnancy, due to the mitochondria rich placenta, is a condition that favors oxidative stress.^[26] Approximately 20–30% of pregnancies are complicated, either

directly or indirectly, by placental pathologies associated with metabolic, oxidative or inflammatory stress.^[27] Also oxidative stress influences both implantation and early embryo development which decides a successful pregnancy. Increase in ROS (reactive oxygen species) is also involved in defective embryo development and retardation of embryo growth, which is attributed to induced cell-membrane damage and DNA damage.^[21] All of that may be also the reason of our results which showed abortion of the treated group and the DNA fragmentation. Previously it was confirmed that the decrease in fetal body weight is an extremely sensitive indicator for fetal toxicity.^[22] These may be explained due to the presence of clarithromycin in the fetal tissue as erythromycin is found in fetal tissues after maternal administration.^[23] Also, the embryos had numbers of external anomalies as paralysis and edema. These agree with Kallen *et al.* (2005)^[24], who stated that clarithromycin causes anal atresia, and anomalies in the limbs especially the polydactyly and syndactyly.

In the present study, the treated group with clarithromycin showed lack of ossification in some components of skeleton including the skull, fore-limbs and hind-limbs, shortness of bones of limbs. It is reported that, clarithromycin has high concentration in bone.^[24] Arai *et al.* (2007)^[28] reported that oxidative stress affected the mineralization of bone by removal of calcium and phosphorus from bone tissue also it had been reported that clarithromycin induces renal atresia and renal tubular degeneration (FDA label) decreases the Ca reabsorption in the nephron, thus resulting in hypercalciuria and low bone mineral density (BMD) and hence increased fracture risk.^[26]

Examination of transverse sections of maternal and fetuses maternally treated with clarithromycin 45mg/kg orally in all gestational period showed marked histopathological changes of the liver.

The nuclei of either treated dams or their embryos and fetuses had signs of necrotic changes as pyknotic bodies in some areas. These changes become increased in dams treated with longer period (7th day) or with

sacrificed at next day of treatment (T1) which means the improvement of the bad effect of clarithromycin appeared clearly on 20th day of gestation at group (T2) due to the long time between the end of administration and the time of scarification. From these results, it may agree with Mirodzhevet *al.*, 2007^[29], who reported hepatotoxicity in all species tested with clarithromycin (dog, rat, and monkey). In rats and monkeys, hepatotoxicity was induced at doses two times greater than human daily dose, and in dogs it was induced at doses comparable to the maximum human daily dose.

In the present study, clarithromycin causes massive appearance in kupffer cells (sinusoidal hepatic macrophage). These kinds of cells are immune cells in the liver and their aggregation is a normal immune reaction to the hepatotoxicity effect. It is known that macrolides increase the rate of neutrophil apoptosis,^[29] consequently increase in the DNA fragmentation as remarked in our results. It is also obvious that the DNA fragmentation is higher in the embryonic stages compared to the maternal DNA may be due to the high apoptotic rate during embryonic development which accompanied by DNA fragmentation. Macrolides stimulates the phagocytosis by macrophage as stated by Hodge *et al.*, (2008)^[30] and Tsai *et al.*, (2004)^[31], which cause aggregation in kupffer cells as reported in this study.

In addition to these, macrolides inhibit P-glycoprotein activity,^[32] which is an adenosine triphosphate (ATP)-dependent multidrug efflux transporter and located on the luminal surface of epithelial cells of the small intestine, bile canalicular membrane of the liver, renal proximal tubules, and endothelial cells that form the blood brain and blood-testes barriers.^[33] In the liver, P-glycoprotein is located at the canalicular membrane of hepatocytes facing the bile duct lumen. Thus, inhibition of P-glycoprotein in the liver could result in reduced biliary excretion causing hepatotoxicity.^[34]

CONCLUSION:

Collectively, clarithromycin was developmentally toxic to pregnant rats and their fetuses as evidenced by increased

abortion and resorption, intrauterine growth retardation of the fetuses, delayed ossification of bones with rib anomalies, hepatic histopathological changes in the pregnant rats and their fetuses and DNA fragmentation. Care should be taken if clarithromycin was administered during pregnancy.

REFERENCES

- [1] **Barni S, Butti D, Mori F, Pucci N, Rossi ME, Cianferoni A, Novembre E (2015):** Azithromycin Is More Allergenic Than Clarithromycin in Children With Suspected Hypersensitivity Reaction to Macrolides. *J Investig Allergol Clin Immunol.*, 25(2): 128-132
- [2] **Zuckerman JM and Kaye KM (1995):** The new macrolides. *Infect Dis Clin North Am.*, 9:731–745
- [3] **Neu HC (1992):** New macrolide antibiotics: Azithromycin and clarithromycin. *Ann Intern Med.*, 116:517-9.
- [4] **Vorbach H, Weigel G, Robibaro B, Armbruster C, Schaumann R, Hlousek M, Reiter M, Griesmacher A and Georgopoulos A (1998):** Endothelial cell compatibility of clarithromycin for intravenous use. *Clin Biochem.*, 31:653–656.
- [5] **Tuchman-Duplessis H (1977):** Drug effect on the fetus: general principles of drug induced congenital abnormalities. ADIS Press, New York pp39
- [6] **Andersen JT, Petersen M, Jimenez-Solem E, Broedbaek K, Andersen NL, Torp-Pedersen C, Keiding N, Poulsen HE (2013):** Clarithromycin in Early Pregnancy and the Risk of Miscarriage and Malformation: A Register Based Nationwide Cohort Study. *PLOS one*, 8(1):1-6
- [7] **Paget GE and Barnes JM (1964):** Evaluation of drug activities. "Pharmacometrics" 1st ed. Laurence, Acad. Press London and New York.
- [8] **Snell GD (1956):** Biology of the laboratory mouse, 5th ed. The Blakiston Company, Philadelphia.
- [9] **McClain RM and Becker BA (1975):** Teratogenicity, foetal toxicity and placental transfer of lead nitrate in rats. *Toxicol. App. Pharmacol.*, 8 (1):72-82
- [10] **Peters (1977):** Double staining of foetal skeletons for cartilage and Bone in: "Methods in prenatal toxicology ". Neu bert D, Merkerd HJ, Kwasigroch TE. George Thieme Stuttgart, 153-154.
- [11] **Miller SA, Dykes DD and Polesky HF (1988):** A simple salting out procedure for extracting DNA from human nucleated cells. *Nucleic Acids Res.*, 16(3): 1215.
- [12] **Sealey PG and Southern EM (1982):** Gel electrophoresis of DNA. In, Gel electro phoresis of nucleic acids; a practical approach (Rickwood D, Hames BD Editors), IRL Press.
- [13] **Armitage P and Berry G (1987):** Comparison of several groups. In: Blackwell Scientific Publications, Oxford, 186-213.
- [14] **Einarson A, Phillips E, Mawji F, D'Alimonte D, Schick B and Addis A (1998):** A prospective controlled multicentre study of clarithromycin in pregnancy. *Am J Perinatol.*, 15:523-5.
- [15] **Witt A, Sommer EM, Cichna M, Postlbauer K, Widhalm A, Gregor H and Reisenberger K (2003):** Placental passage of clarithromycin surpasses other macrolide antibiotics. *Am J ObstetGynecol.*, 188:816–819.
- [16] **Abbott Laboratories (2000):** Clarithromycin. Available from <http://reprotox.org>.
- [17] **Schick, B.; I-bn, M. ; Librizzi, R. and Ibnnenfeld, A.(1996):** Pregnancy outcome Following Expoure To Clarithromycin, Pregnancy health line, In part Ent of Obstetrics and Gynecology, Philadelphia, Repro. Toxi., 10: 2
- [18] **Bar-Oz B, Diav-Citrin O, Shechtman S, Tellem R, Arnon J, Francetic I, Berkovitch M and Ornoy A (2008):** Pregnancy outcome after gestational exposure to the new macrolides: A prospective multi-center observational study. *J. Euro. Obst.&Gyne. And Repro Bio .*, 141: 31–34.
- [19] **Einarson A, Phillips E , Mawji F , D'Alimonte D ,Schick B ,Addis A, Mastroiacova P, Mazzone T , D. Matsui and Koren G (1998):** A Prospective Controlled Multicentre Study of Clarithromycin in Pregnancy. *Amer J Perinato.*, 15(9): 523-525.
- [20] **Sekhoh LH, Gupta S, Kim Y, and Agarwal A (2010):** Female infertility and antioxidants. *Curr. Women Health Rev.*, 6(2):84-95.
- [21] **Ambudkar SV, Kim IW and Auna ZE (2006):** The power of the pump: mechanisms of action of p-glycoprotein (ABCB1), *J EurPharmacolSci.*, 27:392-400.
- [22] **Gil S, Saura R, Forestier F and Farinotti R (2005):** P-glycoprotein expression of the human placenta during pregnancy. *Placenta.*, 26:268-270.
- [23] **Mathias AA and Hitti JD (2005):** Unadkat, P-glycoprotein and breast cancer resistance protein expression in human placentae of various gestational ages. *Am J pysiolRegulIntegr Comp Physiol.*, 289:963-969.
- [24] **Kallen BA, Otterblad OP and Danielsson BR (2005):** Is erythromycin therapy teratogenic in humans? *ReprodToxicol.*, 20:209-14.

[25] **Aye IL and Keel JA (2013):** Placental ABC transporters, cellular toxicity and stress in pregnancy. *Chemico Bio Interact.*,203:456-466.

[26]**Ciragil P, Kurutus EB, Gul M, Kilinc M, Aral M and Guven A (2005):** The effects of oxidative stress in urinary tract infections during pregnancy. *Mediators Inflamm.*, 5:309-311.

[27] **Casanueva, E. and Viteriy, F.E. (2003):** Iron and oxidative stress in pregnancy. *J. Nutr.*, 133:1700-1708.

[28] **Arai, M.; Shibata, Y.; Pugdee, K.; Abiko, Y. and Ogata, Y. (2007):** Effects of reactive oxygen species (ROS) on antioxidant system and osteoblastic differentiation in MC3T3-E1 cells. *IUBMB Life*, 59(1):27–33.

[29] **Mirodzhev GK, Ishankulova DM, Boimatova MB and Negmatova FA (2007):** Side effects of Helicobacter pylori eradication therapy. *Klin Med (Mosk)*, 85:47–50.

[30] **Hodge S, Hodge G, Jersmann H, Matthews G, Ahern J, Holmes M, Reynolds PN (2008):** Azithromycin improves macrophage phagocytic Each value indicates the mean ± S.D.M of 6 animals. Statistical analysis was carried out by One Way

ANOVA followed by Tukey- Kramer Multiple Comparison Test. CONT =Normal Control, CLAR =clarithromycin.function and expression of mannose receptor in chronic obstructive pulmonary disease. *Am J Respir Crit Care Med.*,178(2):139-48.

[31] **Tsai WC, RodriguezML, YoungKS, DengJC, ThannickalVJ, TatedaK, HershensonMB, and StandifordTJ (2004):** Azithromycin Blocks Neutrophil Recruitment in PseudomonasEndobronchial Infection. *Am J Res Crit Care Med.*,170(12):1331-1339.

[32] **Schlossberg D (1995):** Azithromycin and clarithromycin. *Med Clin North Am.*, 79:803–15.

[33] **Mathias, A.A and J. Hitti, J.D. (2005):** Unadkat, P-glycoprotein and breast cancer resistance protein expression in human placenta of various gestational ages, *Am. J. Physiol. Regul. Integr. Comp. Physiol.*, 289: 963–969.

[34] **Ambudkar, S.V.; Kim, I.W. and Sauna Z.E. (2006):** The power of the pump: mechanisms of action of P-glycoprotein (ABCB1), *J. Eur. Pharmacol. Sci.*, 27:392–400.

Table (1): Effect of Clarithromycin on Pregnant Rats:

| Parameters Groups | No. of pregnant rats | The maternal weight gain | No. of aborted rats | No. of sacrificed rats | No. of uteri Without resorption | No. of uteri with complete resorption | Average uterine weight (gm) |
|---|----------------------|--------------------------|---------------------|------------------------|---------------------------------|---------------------------------------|-----------------------------|
| C1 (CONT (8 days)) | 7 | 16.33±5.715 | 1 (14.28) | 6 (85.7%) | 5 (71.42%) | 1 (14.28%) | 0.8935±0.3710 |
| T1 (CLAR 1 st to 7 th at 8 th day) | 7 | 13.33±2.658 | 2 (28.57) | 5 (71.42%) | 5 (71.42%) | 2 (28.57%) | 0.9505±0.2311 |
| C2 (CONT 20 days) | 6 | 65.33±12.31 | 0 | 6 (100%) | 6 (100%) | 0 | 42.46±13.03 |
| T2 (CLAR 1 st to 7 th at 20 th) | 6 | 49.83±15.47 | 1 (14.28) | 5 (83.33%) | 5 (71.42%) | 1 (16.66%) | 39.16±5.307 |

Table (2): Effect of Clarithromycin administration on placenta, fetus’s weight and placental index of the fetuses on the 20th. day of gestation:

| Parameters Groups | Mean placental weigh (gm) n= 10 | Mean fetal weight (gm) n= 10 | Mean placental index |
|-------------------|---------------------------------|------------------------------|----------------------|
| Control | 0.6155±0.1154 | 3.963±0.1434 | 0.1497±0.01050 |
| Treated | 0.4321±0.02281* | 3.789±0.1634 | 0.1161±0.003541* |

Table (3): Effect of Clarithromycin administration on Fetuses Mortality:

| Parameters Groups | No. of sacrificed dams | No. of implantation sites (average/ mother) | No. of resorbed fetuses | No. of live fetuses | No. of dead fetuses | Total mortality rate |
|--|------------------------|---|-------------------------|---------------------|---------------------|----------------------|
| G1C1 (CONT 8 days) | 6 | 46 (7.6) | 0 | 46 (100%) | 0 | 0 |
| G1T1 (CLAR (1 st to 7 th at 8 th day) | 6 | 40 (6.6) | 0 | 40 (100%) | 0 | 0 |
| G1C2 (CONT (20 days) | 6 | 45 (7.5) | 0 | 45 (100%) | 0 | 0 |
| G1T2 (CLAR (1 st to 7 th at 20 th) | 6 | 38 (7.6) | 0 | 38 (100%) | 0 | 0 |

Table (4): Effects of Clarithromycin on external anomalies in the fetuses at 20th day of gestation:

| Groups | No. of examined fetuses | hematoma | Anomalies of Limbs | | | | Anomalies in tail |
|---------|-------------------------|-------------|--------------------|-----------|-------------|----------|-------------------|
| | | | Brachydactyl | Paralysis | Contraction | Oedema | |
| Control | 45 | 0 (0%) | 0 | 0 | 0 | 0 | 0 |
| Treated | 38 | 13 (34.21%) | 2 (5.26%) | 2 (5.26%) | 5 (13.15%) | 1 (2.6%) | 2 (5.26%) |

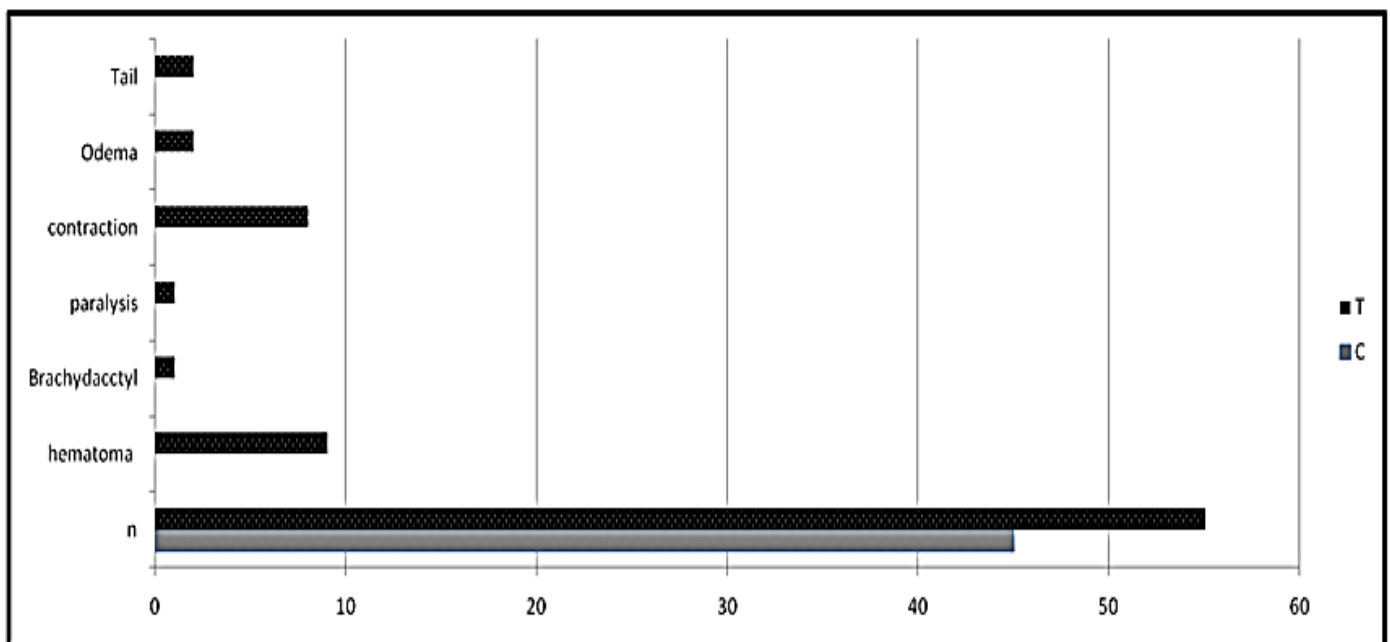


Figure (1): Histogram showing the incidence of external anomalies

Table (5): Effects of Clarithromycin on incidence of skeletal congenital malformation:

| Axial Skeleton | | | | | | |
|-----------------------|-------------------------|-----------------------------|------------------|-------------------------|---------------------|---------|
| Group | No. of examined fetuses | Skull (Mild deossification) | Vertebral column | Ribs | | Sternum |
| | | | | Shortness in rib No. 13 | Missed Ossification | |
| Control | 24 | 0 | 0 | 0 | 0 | 0 |
| Treated | 24 | 6 (25%) | 0 | 12(50%) | 0 | 0 |
| Appendicular skeleton | | | | | | |
| Group | No. of examined fetuses | Pectoral Girdle | Fore limbs | Pelvic girdle | Hind limb | |
| Control | 24 | 0 | 0 | 0 | 0 | |
| Treated | 24 | 8 (33.3%) | 8 (33.35) | 8 (33.3%) | 8 (33.3%) | |

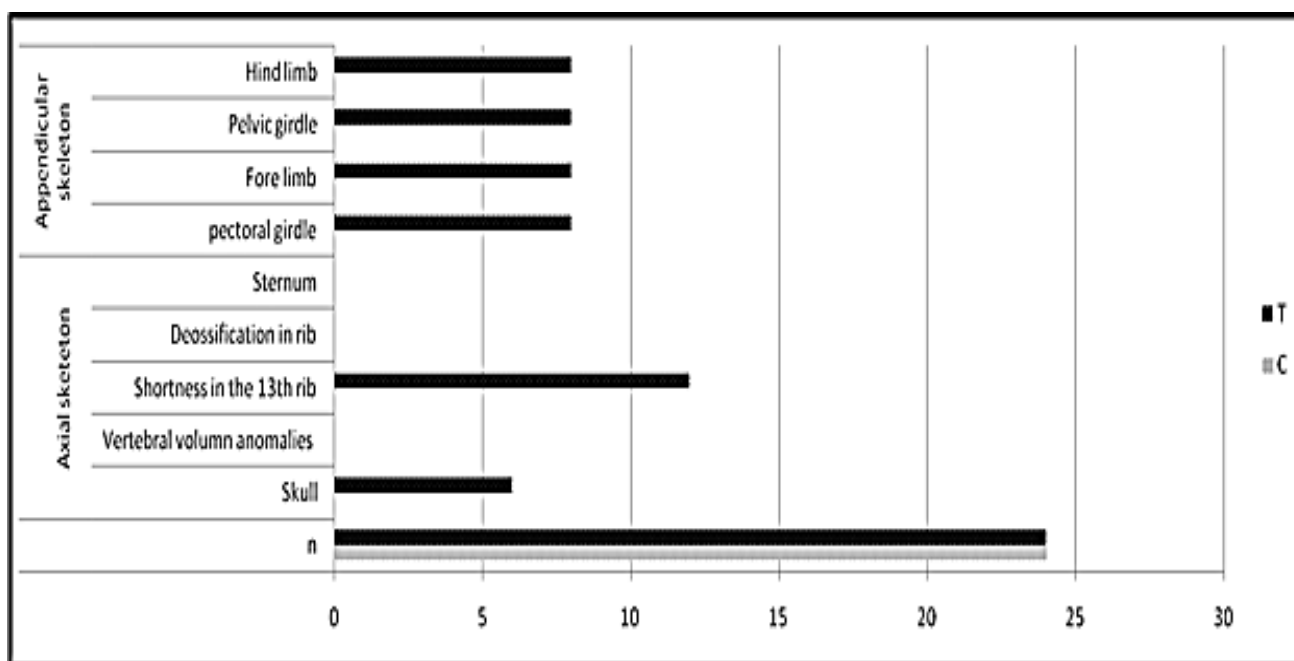


Figure (2): Histogram showing the incidence of congenital malformation of skeleton

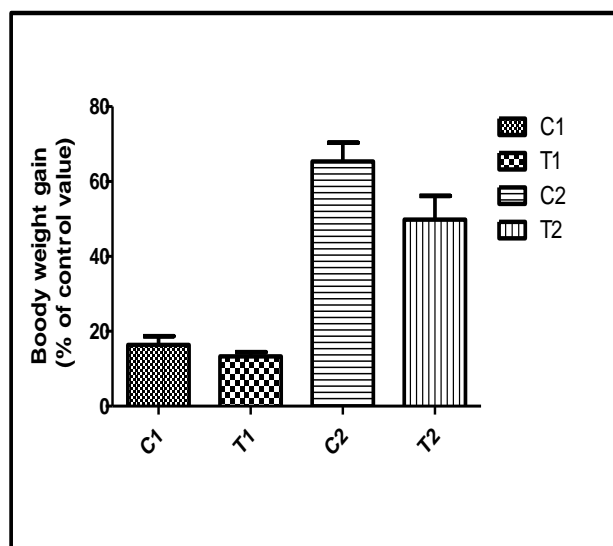


Figure (3): Effect of Clarithromycin on Body Weight Gain of Pregnant Rats: C1 (CONT 8th day), T1(CLAR from 1st to 7th and sacrificed at the 8th day of gestation, C2(CONT 20th day), T2(CLAR from 1st to7th and sacrificed at 20th day of gestation), CONT =Normal Control

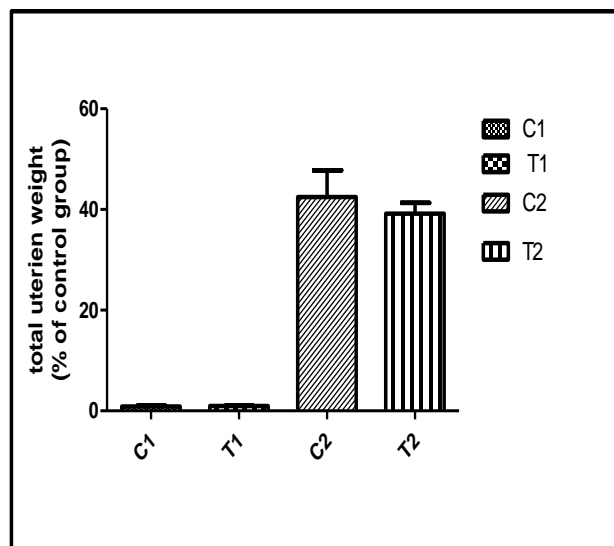


Figure (4) Effect of Clarithromycin on total uterine weight of Pregnant Rats:C1 (CONT 8th day),T1 (CLAR from 1st to 7th and sacrifices at 8th day of gestation, C2 (CONT 20th day,T2(CLAR from 1st to7th and sacrifices at 20th day of gestation,CONT =Normal Control received dist water, CLAR =clarithromycin.

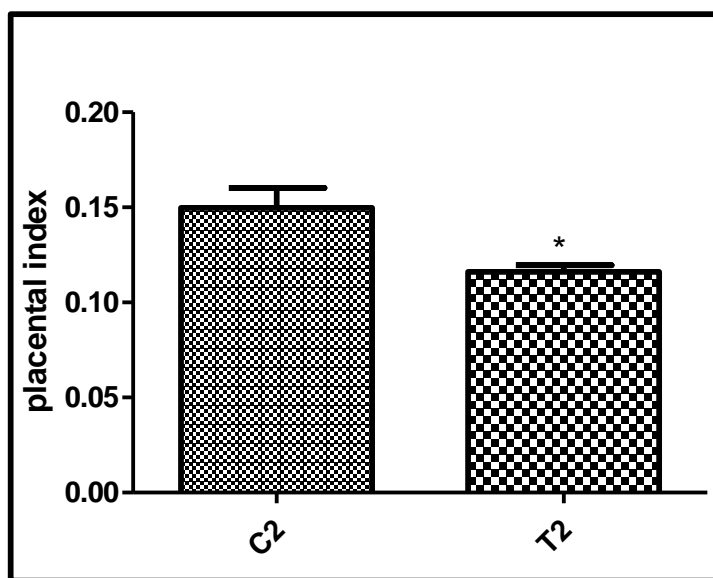


Figure (5) Effect of Clarithromycin on placental index where: C2 CONT 20th day, T2 CLAR from 1st to7th and sacrifices at 20th day of gestation, CONT =Normal Control received dist. water, CLAR =clarithromycin.

*significantly different from normal control group at P < 0.05.

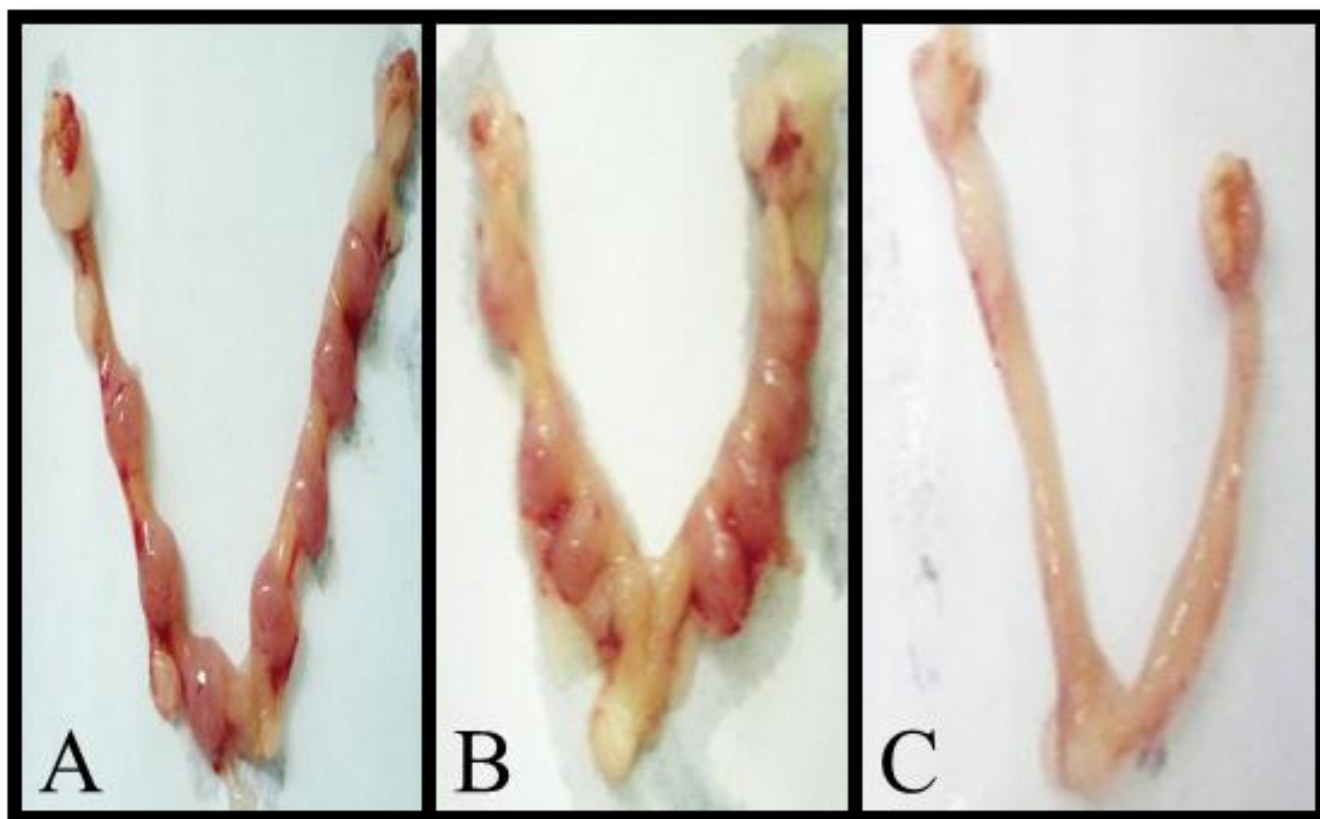


Figure (6): Photomicrographs showing Uteri of Pregnant Rats on the 8th Day of Gestation: (A) **Control group** receiving Dist.H₂O showed symmetrical distribution of fetuses on both horns. (B&C) Treated group received clarithromycin during cleavage phase and sacrificed at 8th day showed asymmetrical distribution of fetuses on both horn (B) or complete resorption of fetuses (C).

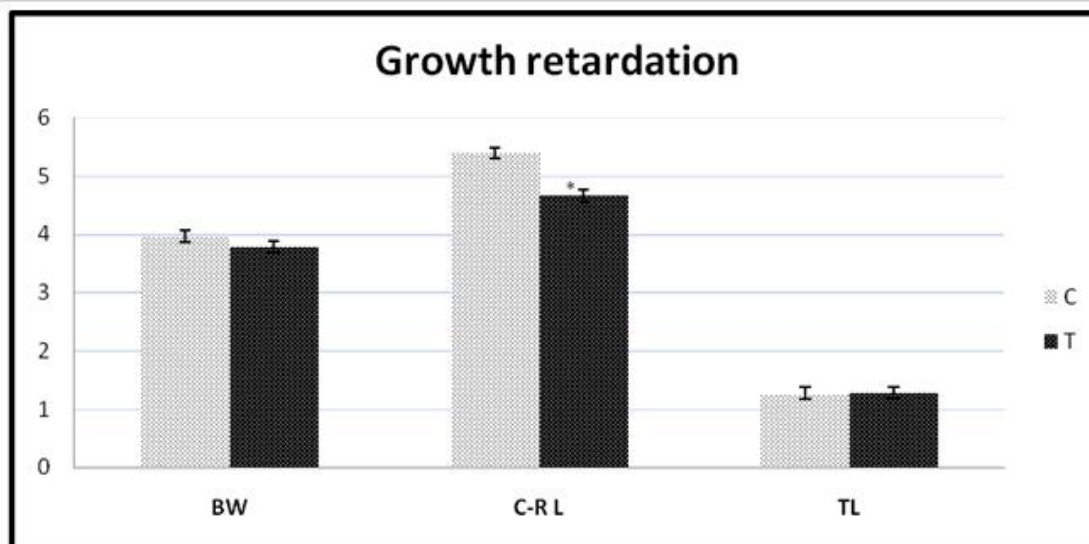


Figure (7): Histogram showing the effect of Clarithromycin on growth retardation: fetal body weight (BW), Crown-Rump length (C-RL) and tail length (TL) of the fetuses of the treated (T) and control (C) groups. *significantly different from normal control group at $P < 0.05$.

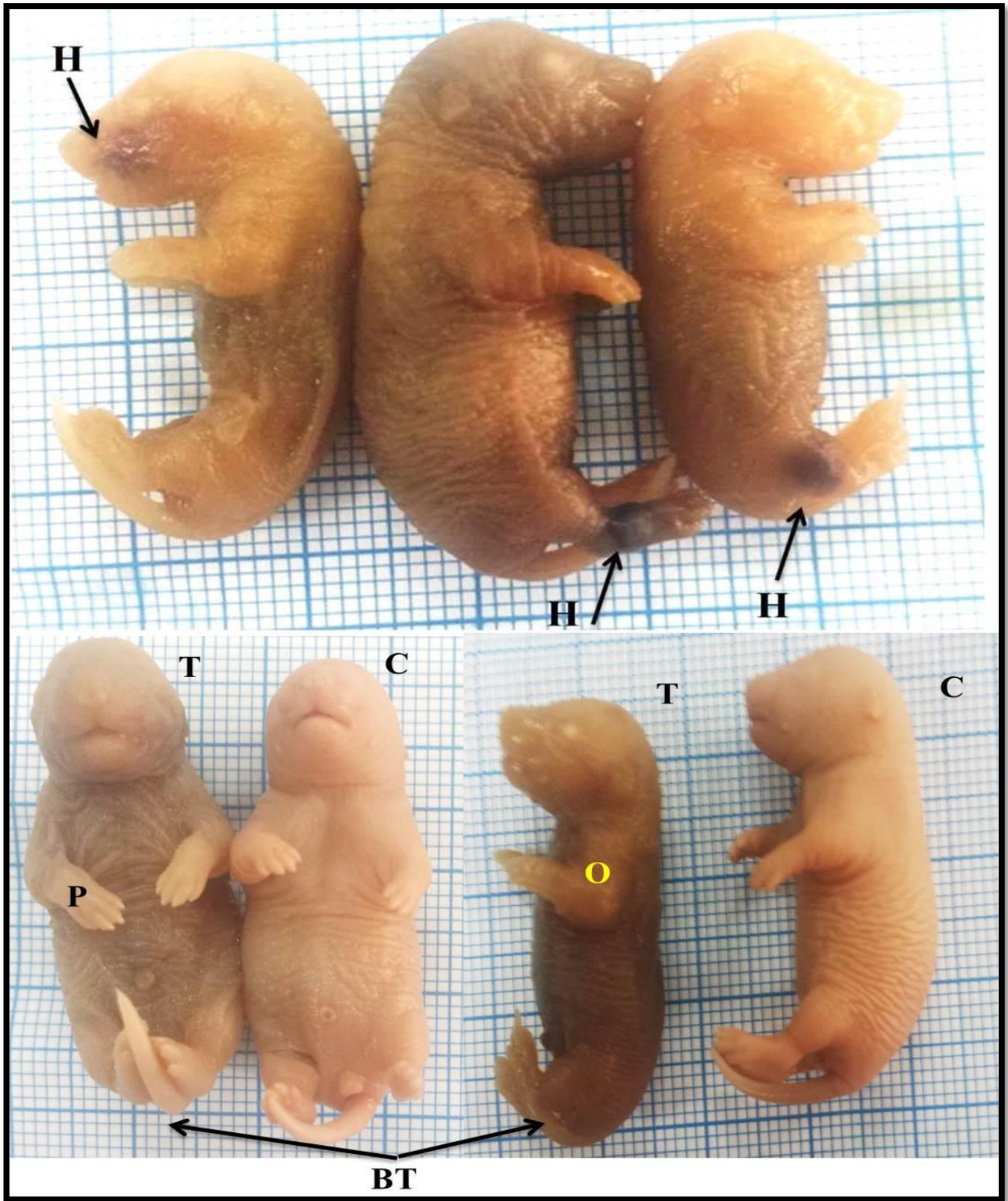


Figure (8): Photomicrographs of Full Term Fetuses maternally treated from 1st to 7th and sacrificed at the 20th Day of Gestation treated with (C) Dist. H₂O (control), showing normal structure of fetuses, (T) clarithromycin, showing paralysis [p], and bending tail [BT], oedema in the fore-limb [O] and haematoma [H]

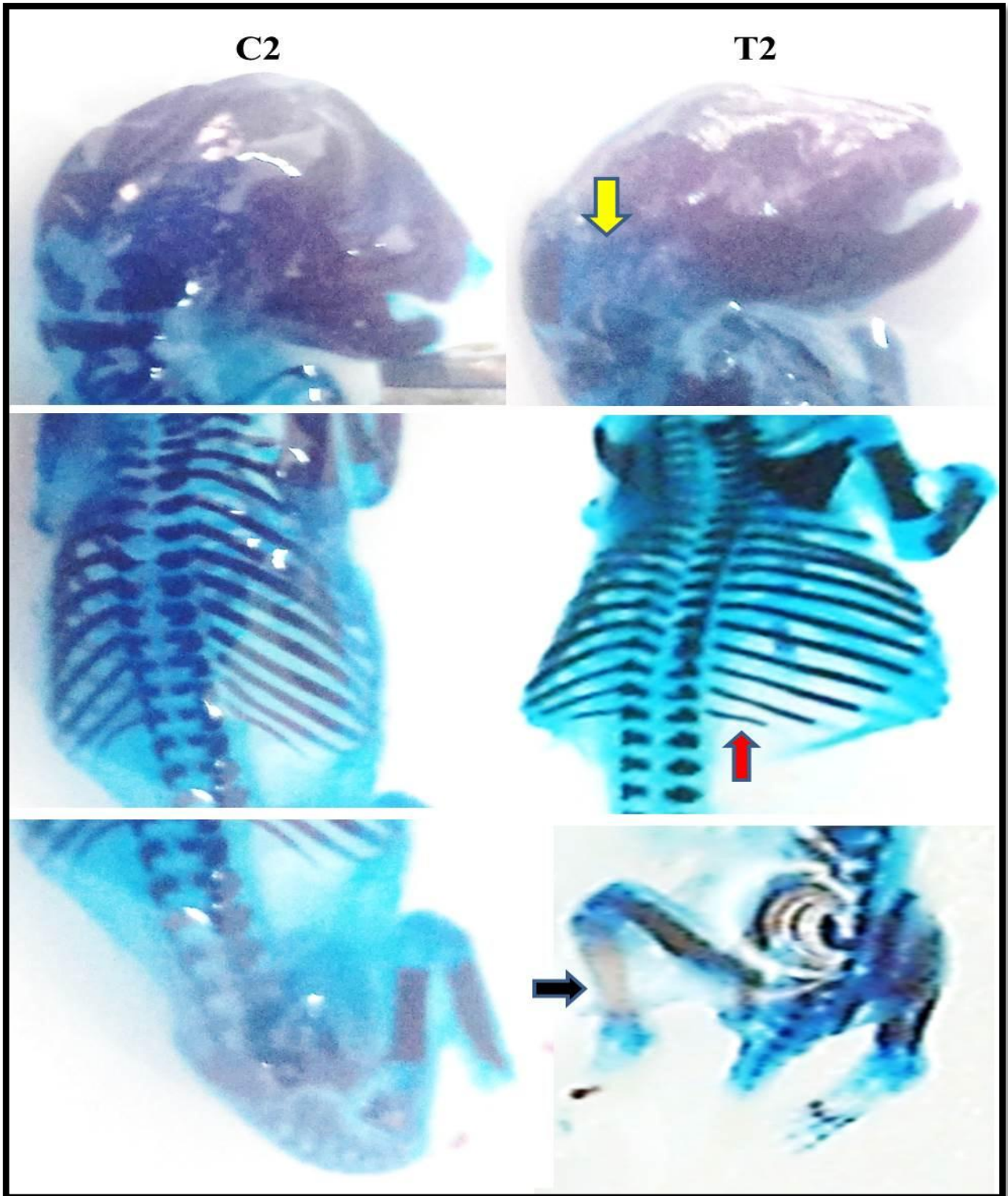


Figure (9): Photomacrographs of Skeleton of Fetuses on the 20th day of Gestation. Where C2 is control group received dist. water, T2 is treated group received clarithromycin (45mg/kg) during cleavage period showing lack of ossification of skull (yellow arrow) and hind limb (black arrow) as well as shortness in the 13th rib (red arrow).

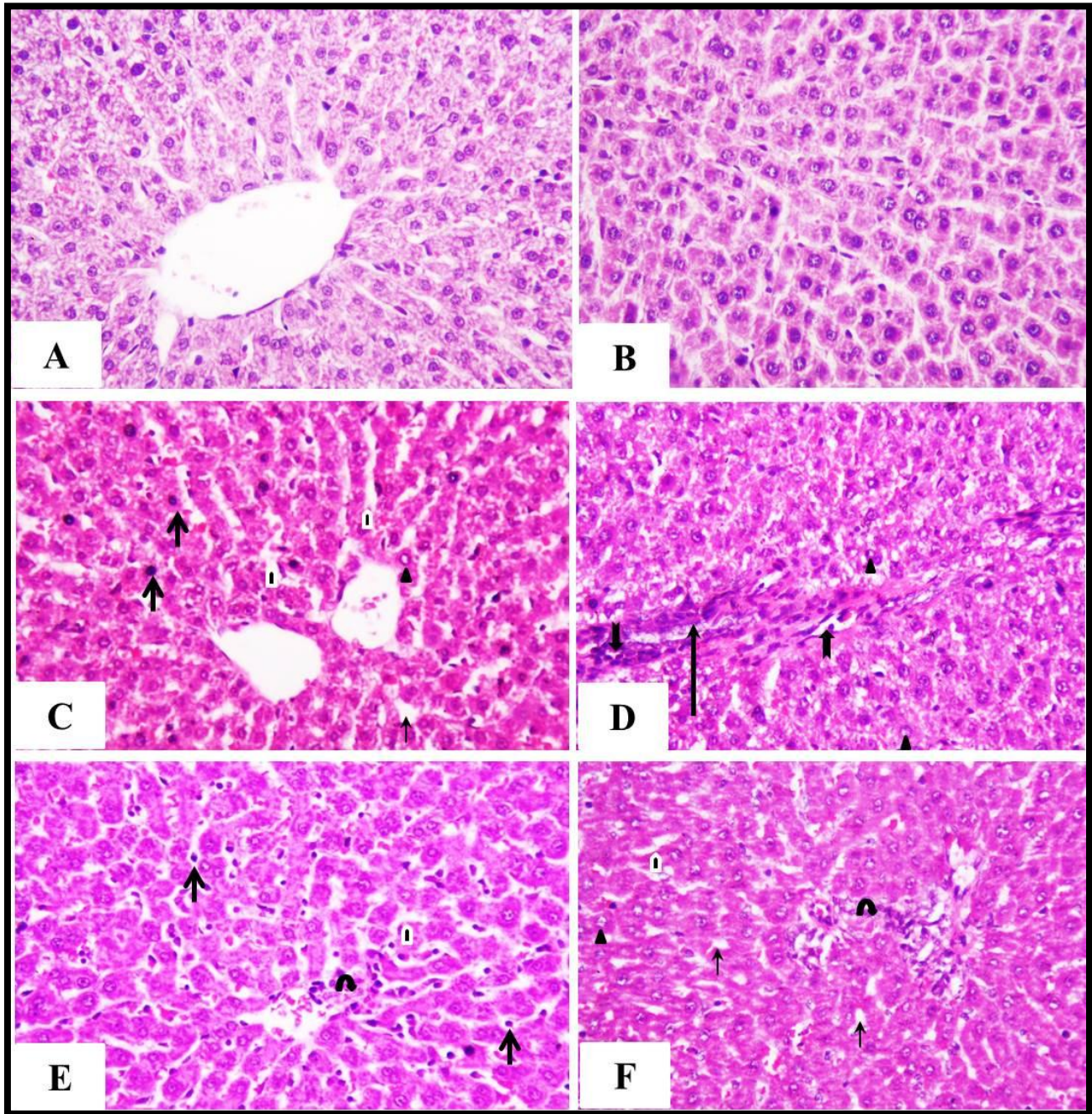


Figure (10): Photomicrograph of liver of pregnant rats showing: the control groups C1 (A) and C2 (B), received dist. H₂O have normal architecture. The treated group received clarithromycin from 1st to 7th day and scarified at 8th day of gestation T1(C&D) showing pyknotic nuclei (short arrows), necrotic area (long arrows), aggregation of Kupffer cells (thick arrows), peripheral chromatin in the nuclei of some hepatocytes (arrow head), dilation in sinusoids (black & white arrow head), and degenerated vacuolated hepatocytes (thin arrow) and interstitial congestion. The treated group received clarithromycin from 1st to 7th day and scarified at 20th day of gestation T2(E&F) showing lymphocytic infiltration (curved arrow), few pyknotic nuclei (short arrow), dilatation in sinusoids (arrow), distribution of many nuclei with peripheral chromatin (arrow) and degenerated vacuolated hepatocytes (arrow). (H&E, X.400).

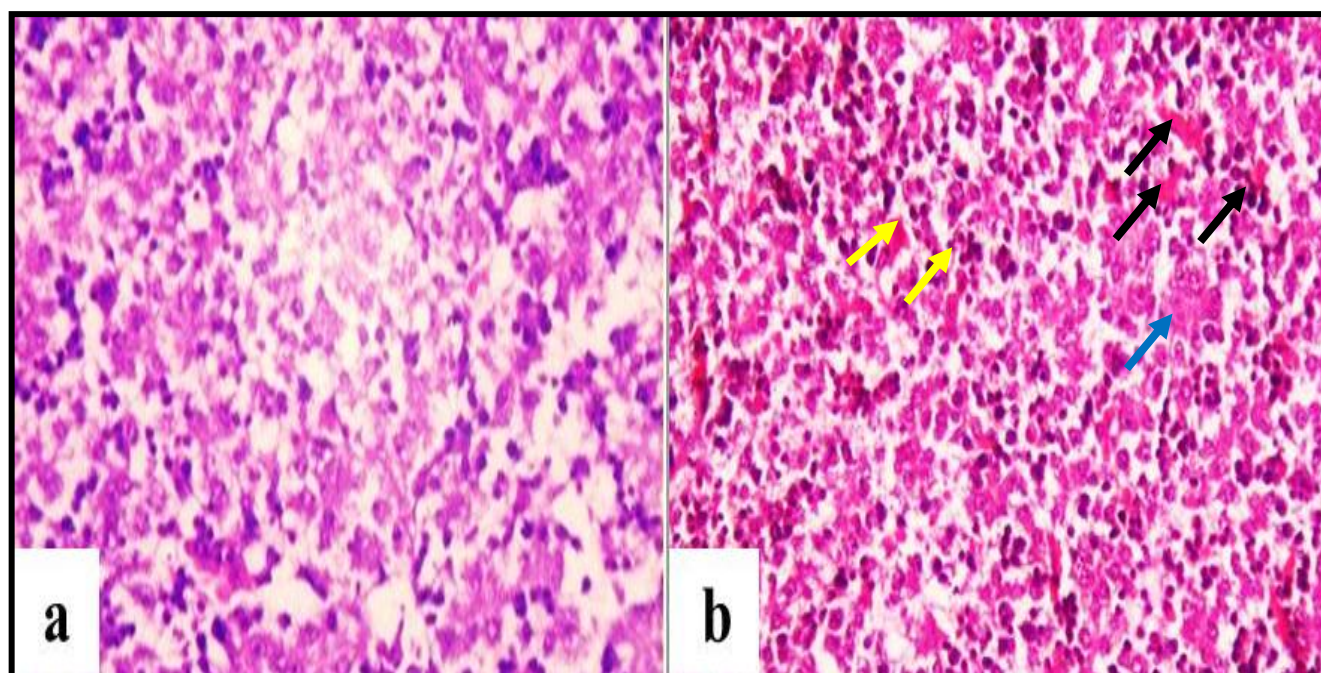


Figure (11): Photomicrograph of fetal liver at 20th day of gestation from group1: (a) Control group (maternally treated with dist. H₂O) has normal architecture; (b) Treated group (maternally drenched with clarithromycin from 1st to 7th day and sacrifices at 20th day of gestation) has interstitial hemorrhage (black arrows), hydrobic degeneration (blue arrow) and pyknotic nuclei (yellow arrows) (**H&E, X.400**).

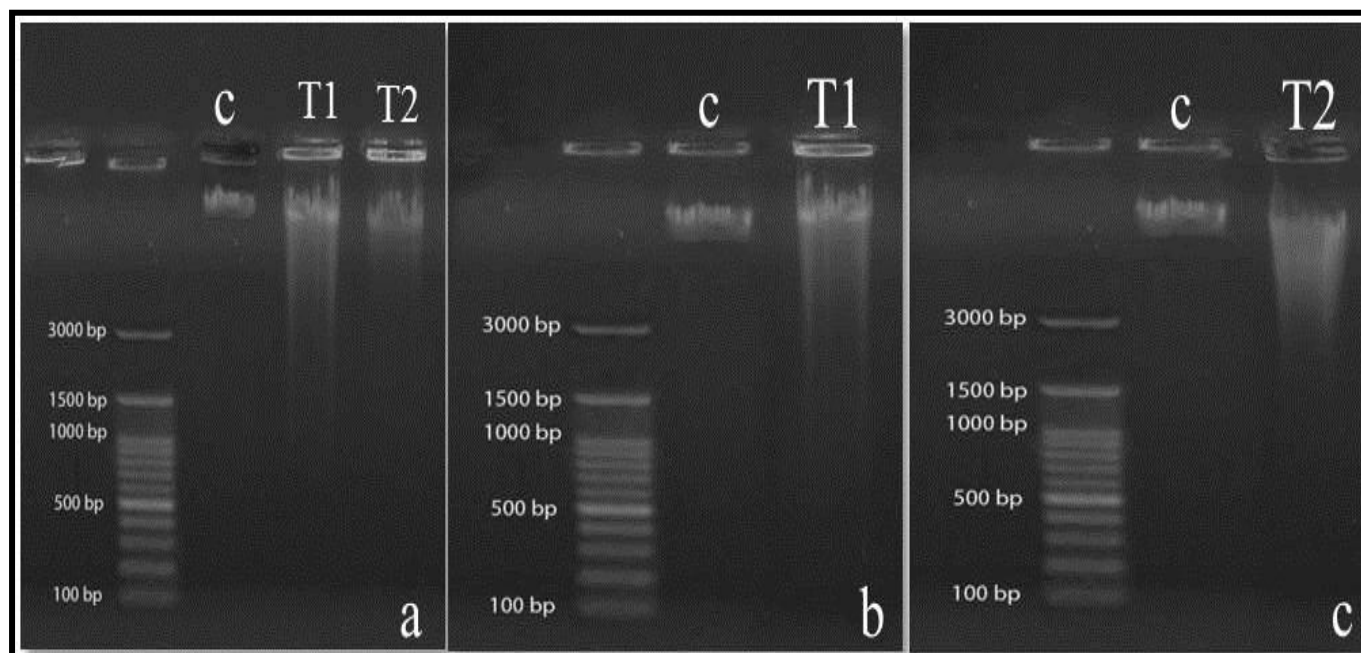


Figure (12): Agarose Gel Electrophoresis of Genomic DNA: Maternal liver Maternally treated from 1st to 7th and sacrificed at 20th day of gestation and received (C) Dist. H₂O (control) (T) clarithromycin from, showing (A) maternal fragmentation of DNA (B) fetal fragmentation of DNA.