

**Role of Doppler Ultrasound in Differentiation between Benign and Malignant Lymph Nodes**

Alaa Abdelhakim Taha Ahmed<sup>a\*</sup>, Sabah Ahmed Mohamed Fadel<sup>b</sup>, Ahmed Okasha<sup>a</sup>, Saeda Mohamed Abd Elwahab<sup>a</sup>

<sup>a</sup>Diagnostic Radiology Department, Faculty of Medicine, South Valley University, Qena 83523, Egypt

<sup>b</sup>Pathology Department, Faculty of Medicine, Assiut University, Assiut, Egypt

**Abstract:**

**Background:** A popular presenting symptom for a number of disorders is lymphadenopathy. Malignant and non-malignant lymphadenopathy differentiation has major clinical and therapeutic advantages.

**Objectives:** Assess the efficacy of doppler ultrasound in differentiating malignant and non-malignant lymphadenopathy.

**Patients and methods:** this study was done on 20 patients with clinically enlarged one or more axillary or cervical lymph nodes of both sexes and of different age groups. The lymph nodes were subjected to sonographic and Doppler studies, which were correlated with pathological diagnoses obtained by lymph node biopsy.

**Results:** At cut off point of 1.36, pulsatile index had 75% sensitivity and 85% specificity with overall diagnostic accuracy was 80% in diagnosis of malignant lymphadenopathy. At cut off point of 0.65, resistive index had 86% sensitivity and 92.3% specificity with overall diagnostic accuracy was 89% in diagnosis of malignant lymphadenopathy.

**Conclusions:** In differentiating benign from malignant lymph nodes, Color Doppler ultrasound plays an important complementary function to ultrasound. This adds to the diagnostic faith that can predict malignancy. If grey scale ultrasound results are equivocal, color doppler is also beneficial, and it increases diagnostic accuracy.

**Key words:** Doppler ultrasound, lymphadenopathy, vascular pattern, histopathology.

**DOI:** 10.21608/svuijm.2021.54120.1058

\*Correspondence: [alaahakeemtaha@gmail.com](mailto:alaahakeemtaha@gmail.com)

**Received:** 21 Decembre, 2020.

**Revised:** 18 January, 2021.

**Accepted:** 15 February, 2021.

**Cite this article as:** Alaa Abdelhakim Taha Ahmed, Sabah Ahmed Mohamed Fadel, Ahmed Okasha, Saeda Mohamed Abd Elwahab. (2022). Role of Doppler Ultrasound in Differentiation between Benign and Malignant Lymph Nodes. *SVU-International Journal of Medical Sciences*. Vol.5, Issue 2, pp: 75-82.

**Copyright:** © Ahmed et al. (2022) Immediate open access to its content on the principle that making research freely available to the public supports a greater global exchange of knowledge. Users have the right to Read, download, copy, distribute, print or share link to the full texts under a [Creative Commons BY-NC-SA 4.0 International License](https://creativecommons.org/licenses/by-nc-sa/4.0/).

## Introduction

Lymphadenopathy is a significant clinical finding associated with acute infection, granulomatous disease, autoimmune disease, and malignancy. The involvement of specific nodal groups is an indicator of pathologically affected organs and tissues, especially in the context of malignancy. (Antony et al., 2020)

Many pathological procedures require lymph nodes, so there are great therapeutic and prognostic consequences for the diagnosis of lymph node involvement. In this sense, for the identification of clinically undetectable lymph nodes, imaging modalities such as computed tomography (CT) scan, magnetic resonance imaging (MRI) and ultrasonogram play a major role. While MRI and CT scans are very useful in detecting lymph node pathology, ultrasound has always been regarded as a powerful tool for assessing the enlargement of lymph nodes, particularly through the use of high resolution probes (7.5 to 15 MHz). Although CT scanning and MRI are essential diagnostic aids, both are costly and not widely available. In addition, the patient is exposed to relatively high doses of radiation through CT scanning, and MRI is costly, time-consuming and not ideal for every patient. (Venkatesh et al., 2013)

Cancer can appear in the lymph node as the primary site or can spread there from another primary site. For carcinomas that disseminate through the lymphatic system, they commonly spread to the regional node before spreading to the next tier of nodes. These immediate regional nodes are called the sentinel lymph nodes. Biopsy or dissection of the sentinel lymph node can help to determine if cancer has metastasized, this information can assist with staging cancer and direct mode of therapy (Tui et al., 2020)

Blood flow details and nodal morphology are given by Color Doppler ultrasonography. The use of higher-frequency transducers increases the ability of superficial structures to detect low-velocity signals. Since vessels in inflamed lymph nodes are dilated, tumor cells may be compressed by vessels in malignant lymphadenopathy, and thus the vascular resistance in inflamed lymph node

vessels may decrease due to vasodilatation, and due to tumor cell compression, vascular resistance of lymph nodes involved in malignancy may increase. (Mohamed et al., 2018)

## Patients and Methods

This Study was conducted on 20 patients with clinically enlarged one or more axillary or cervical lymph nodes of both sexes and of different age groups from general surgery and oncology outpatient clinics between June 2019 and May 2020.

### Data Collection

- A- Family history of malignancy.
- B- History of chemo- and/or radiotherapy.
- C- History of infections.
- D- Suspected neck or cervical swelling.

### Ethical Consideration

All patients were included in the study after taking a written consent after full explanation of the purpose, nature and risks of all procedures used according to the ethical committee of Qena University hospital.

### Physical Examination

- A- General examination: Measurement of patients' weight and height for BMI calculation and BP with detailed relevant systemic examination.
- B- Lymph node examination: clinical examination of cervical and axillary LNs, examination of drainage areas and morphological aspects like shape, consistency, mobility etc.

**Investigations:** CBC, TLC, Tumour markers, ESR, CRP, LDH, CT, MRI, U/S and tru-cut biopsy.

### Doppler U/S and grey scale examination

It was done with 11-L probe (GE Logiq P6 premium-ultrasound system) with the frequency of 4.5–12 MHz, by the radiologist who was unaware of the pathologic findings. The suspected nodes in each patient were subjected to measurement of:

**Ahmed et al (2022)**

- Color doppler examination of vascular pattern.
- Resistive Index (RI).
- Pulsatile Index (PI).
- Peak systolic Velocity (PSV).
- End Diastolic Velocity (EDV).

**Statistical Analysis**

Data was collected and analyzed using SPSS (Statistical Package for the Social Science, version 20, IBM, and Armonk, New York). Continuous data was expressed in form of mean  $\pm$  SD or median (range) while nominal data was expressed in form of frequency (percentage). Diagnostic accuracy of different ultrasound findings and parameters of color Doppler in diagnosis the nature of lymphadenopathy was assessed by receiver operating characteristics curve. Level of confidence was kept at 95% and hence, *P* value was considered significant if  $< 0.05$ .

**Results****A- Demographic data of enrolled patients (n= 20): (data are shown in Table (1)).**

Mean age of enrolled patients was  $43.34 \pm 10.45$  years with range between 22 and 56 years. Out of the studied patients; 16 (80%) patients were females and 4 (20%) patients were males.

The site of suspected node(s) among cases was axillary in 15 patients representing 75% of total while it was cervical in 5 patients which represent 25% of total patients.

**Table 1. Demographic data of enrolled patients**

Variables	N= 20
Age	
• Mean	$43.34 \pm 10.45$
• Range	22-56
Sex	
• Male	4 (20%)
• Female	16 (80%)

Body mass index (kg/m <sup>2</sup> )	$25.78 \pm 3.56$
Site of suspected node(s)	
• Axillary	15 (75%)
• Cervical	5 (25%)

Data expressed as mean (SD), frequency (percentage)

**B- General characteristics of lymphadenopathy among enrolled patients (n= 20): (data are shown in Table (2)).**

Mean size of examined nodes was  $17.03 \pm 36.87$  mm. It was found that 92.31% of benign nodes were oval in shape and 7.69% were round while 71.43% of malignant nodes were round in shape and 28.57% were oval. Regarding hilum, 92.31% of benign nodes had preserved hilum and 7.69% had lost hilum while 71.43% of malignant nodes had lost hilum while 14.29% had preserved hilum and 14.29% had attenuated hilum.

**Table 2. General characteristics of lymphadenopathy among enrolled patients**

Lymph node characters			Number (total=20, benign=13, malignant=7)
Size (mm)			$17.03 \pm 36.87$
Shape	Oval	Benign	12 (85.71%)
		Malignant	2 (14.26%)
	Round	Benign	1 (16.66%)
		Malignant	5 (83.33%)
Hilum	Preserved	Benign	12 (92.31%)
		Malignant	1 (7.69%)
	Lost	Benign	1 (14.28%)
		Malignant	12 (85.71%)
	Attenuated	Benign	0%
		Malignant	1 (14.29%)

Data expressed as mean (SD), frequency (percentage)

**C- Accuracy of ultrasound parameters in diagnosis nature of lymphadenopathy: (data are shown in Table (3))**

It was noticed that lost hilum had 83.33% sensitivity and 77% specificity with overall

diagnostic accuracy was 65% in diagnosis of malignant lymphadenopathy.

**E- Accuracy of color Doppler parameters in diagnosis of malignant lymphadenopathy: (data are shown in Table (5) and Figure (1))**

**Table 3. Accuracy of ultrasound parameters in diagnosis of malignant lymphadenopathy**

At cut off point of 2.8, end diastolic velocity had 71.4% sensitivity and 61.5% specificity with overall diagnostic accuracy was 75% in diagnosis of malignant lymphadenopathy.

	Lost hilum
Sensitivity	83.33%
Specificity	77%
Positive predictive value	50%
Negative predictive value	71.4%
Accuracy	65%
Cut off point	---
Area under curve	0.55

At cut off point of 14, peak systolic velocity had 83.33% sensitivity and 92.3% specificity with overall diagnostic accuracy was 75% in diagnosis of malignant lymphadenopathy.

At cut off point of 1.36, pulsatile index had 75% sensitivity and 85% specificity with overall diagnostic accuracy was 80% in diagnosis of malignant lymphadenopathy.

**D- Doppler findings among enrolled patients: (data are shown in Table (4))**

At cut off point of 0.65, resistive index had 86% sensitivity and 92.3% specificity with overall diagnostic accuracy was 89% in diagnosis of malignant lymphadenopathy.

The majority of benign cases (85.71%) had central hilar vascular pattern and 16.66% had peripheral and central pattern. The majority of malignant cases (83.33%) had peripheral and central vascular pattern while 14.26% had central hilar vascular pattern. The flow type in most benign cases (92.31%) was low-resistant flow while 14.28% had high resistant flow. In malignant cases, 85.71% had high resistant flow and only 7.69% had low resistant flow.

**Table 5. Accuracy of color Doppler parameters in diagnosis of malignant lymphadenopathy.**

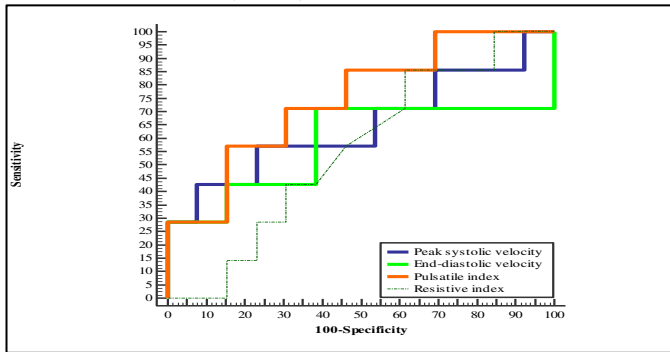
**Table 4. Doppler findings among enrolled patients:**

	EDV	PSV	PI	RI
Sensitivity	71.4%	83.33%	75%	86%
Specificity	61.5%	92.3%	85%	92.3%
Positive predictive value	50%	75%	71%	43%
Negative predictive value	80%	75%	85%	83%
Accuracy	75%	75%	80%	89%
Cut off point	2.8	14	1.36	0.65
Area under curve	0.58	0.65	0.75	0.56

Variables		N= 20	
Vascular Pattern	Central hilar	Benign	12 (85.71%)
		Malignant	2 (14.26%)
	Peripheral and central	Benign	1(16.66%)
		Malignant	5(83.33%)
Flow type	Low-resistant	Benign	12 (92.31%)
		Malignant	1 (7.69%)
	High-resistant	Benign	1 (14.28%)
		Malignant	6 (85.71%)

**EDV: end diastolic velocity; PSV: peak systolic velocity; PI: pulsatile index; RI: resistive index.**

Data expressed as mean (SD), frequency (percentage)



**Fig.1. Accuracy of color Doppler parameters in diagnosis of malignant lymphadenopathy.**

***F- Cross- tabulation between final diagnoses based on histopathological and duplex findings among enrolled patients: (data are shown in Table (6))***

Based on histopathological diagnosis; malignant lesion present in 7 (35%) patients while 13 (65%) patients had benign lesion. Diagnosis based on duplex findings was matched with histopathological diagnosis in all cases with exception in two cases;

- One case was diagnosed as malignant lesion (false positive) by duplex but histopathological diagnosis revealed benign features (tuberculous lymphadenitis)
- Another case was diagnosed as benign lesion (false negative) by duplex but histopathological diagnosis revealed malignant features (metastatic lymphadenopathy)

**Table 6. Cross- tabulation between histopathological and duplex diagnosis**

Variables	Histopathological Diagnosis		Total
	Malignant lesion	Benign lesion	
Duplex examination			
-Malignant lesion	6	1	7
-Benign lesion	1	12	13
Total	7	13	20

Data expressed as frequency

**Discussion**

In our study nodal size varied among examined nodes with mean value of  $17.03 \pm 36.87$  mm and could not be used as a strong tool to dissociate benign from malignant nodes.

In our study, nodal shape was a valuable parameter, It was found that 92.31% of benign nodes were oval in shape and 7.69% were round while 71.43% of malignant nodes were round in shape and 28.57% were oval. This was matched with study of (Venkatesh et al., 2013) which stated that in differentiating malignant and metastatic nodes from benign, nodal shape is an important parameter; 42 (72.41 percent) of malignant nodes were round in their analysis, and 57 (83.82 percent) of nonmalignant nodes were oval in shape.

In a study research made on cervical lymphadenopathy by B-mode, color doppler and power doppler were performed and they found in all 18 malignant cases, in which (n=14) 77.78 percent were round in shape and (n=4) 22.23 percent were oval in shape.(Jayesh et al., 2017)

In our study, 92.31% of benign nodes had preserved hilum and 7.69% had lost hilum while 71.43% of malignant nodes had lost hilum while 14.29% had preserved hilum and 14.29% had attenuated hilum. It was noticed that lost hilum had 43% sensitivity and 77% specificity with overall diagnostic accuracy was 65% in diagnosis of malignant lymphadenopathy.

As a part of a study of cervical lymphadenopathy, hilum was present in 55 of the 80 nodes, while in 25 of the lymph nodes it was missing. Of those 55 hilum-present nodes, 54 nodes have been histopathologically proven to be benign nodes and 1 node to be malignant. It was noted that the presence of echogenic hilum can be considered an indication of its benign existence inside an enlarged lymph node. Of the 25 absent hilum nodes, 20 were histopathologically confirmed to be malignant, while 5 were proven to be benign nodes.(Deepankaret al., 2016)

In our study at cut off point of 0.65, resistive index had 86% sensitivity and 39% specificity with overall diagnostic accuracy was

55% while at cut off point of 1.36, pulsatile index had 75% sensitivity and 85% specificity with overall diagnostic accuracy was 80% in diagnosis of malignant lymphadenopathy.

There was a study stated that the vascular resistance (RI) of the intranodal vessels can be estimated using spectral doppler ultrasonography. However the role of vascular resistance remains controversial and inconsistent in distinguishing malignant and benign nodes. The RI of metastatic nodes compared with reactive nodes has been documented to be higher. However other studies indicate that, relative to benign lymph nodes, metastatic nodes may have lower or comparable vascular resistance levels. In their analysis, at a cutoff point of 0.7, the resistivity index (RI) revealed that all lymph nodes with a RI value greater than 0.7 were malignant (either primary or metastatic), but not all lymph nodes with a RI value less than 0.7 were benign: 57% of RI lymph nodes less than 0.7 (16 of 28) were benign and 43% (12 of 28) were primary node affective. Their research also showed that RI's sensitivity and specificity were 50 and 100 percent respectively for detecting malignant lymph nodes. (Mohamed et al., 2018)

In another study, a sensitivity of 86 percent and 80 percent, and a specificity of 70 percent and 86 percent, respectively, the parameters for optimal cut-off values for RI and PI were suggested as 0.7 and 1.4. It is suggested that RI values tend to be lower or equivalent to malignant nodes for benign nodes, although there is typically higher RI for later nodes. This hypothesis of increased RI is that the normal part of a node is replaced with tumor cell growth, resulting in blood vessel compression, increased vascular resistance and increased RI. (Chammas et al., 2016)

In this study the majority of benign cases (85.71%) had central hilar vascular pattern and 16.66% had peripheral and central pattern. The majority of malignant cases (83.33%) had peripheral and central vascular pattern while 14.26% had central hilar vascular pattern. The flow type in most benign cases (92.31%) was low-resistant flow while 14.28% had high resistant flow. In malignant cases, 85.71% had high resistant flow and only 7.69% had low resistant flow.

Lymph nodes that are regular and receptive seem to exhibit hilar vascularity or appear to be avascular. Metastatic lymph nodes, however, typically have peripheral or mixed vascularity (hilar + peripheral). Lymphomatous nodes tend to have mixed vascularity, unlike metastatic nodes, and isolated peripheral vascularity is rare. The evaluation of nodal vascular pattern by Power Doppler ultrasonography was reported to have high sensitivity (83-89 percent) and specificity (87-100 percent) for differentiating metastatic and reactive nodes. Sensitivity and precision are 67 per cent and 100 per cent respectively in separating lymphomatous and reactive nodes. (Yinga et al., 2013)

In a study for predicting malignancy, they obtained a positive predictive value of 80 percent using the peripheral or mixed vascularity criterion. 24 out of 30 malignant lymph nodes displayed mixed or peripheral vascularity in their study, with 3 lymph nodes displaying central vascularity and 3 lymph nodes showing a lack of vascularity. (Kanika et al., 2016)

### Limitations of the study

One of the limitations of our study is low patient sample size. However, we included only cases with histopathological confirmatory diagnosis. Another disadvantage of this approach is that Doppler ultrasound and color cannot be tested for deep lymph nodes. The failure to detect micro metastases in non-large lymph nodes is a modality-specific limitation of ultrasound.

### Case Presentations

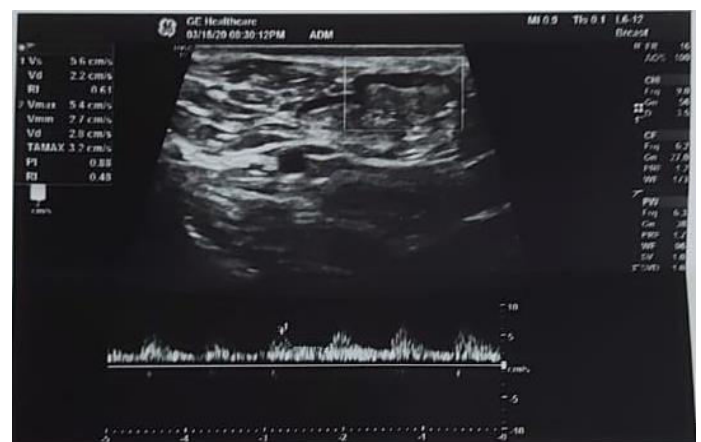

Fig. 2. Greyscale ultrasound of 40 year old female patient showing well-defined hypoechoic

Ahmed et al (2022)

axillary LN with preserved hilum and normal cortical thickness. RI=0.4, PI=0.88. Follow up was suggestive of reactive lymph node.

hilum and mixed (central and peripheral) high resistant vascular pattern. Histopathology revealed malignant featuring metastatic LN from CLL.

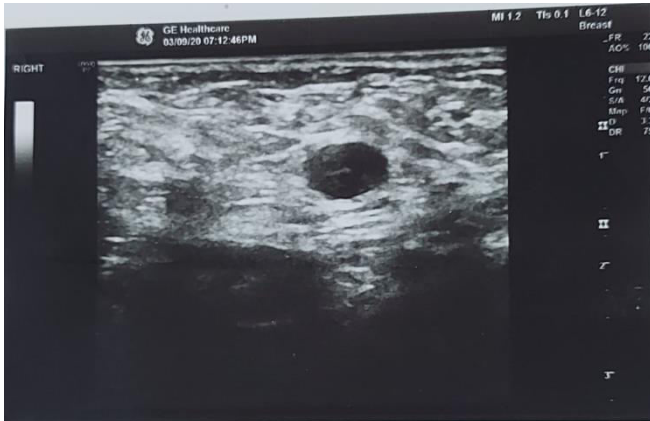

Fig. 3. Greyscale ultrasound of 42 year old female patient shows hypoechoic axillary lymph node which is round in shape with lost hilum. Histopathology revealed metastatic LN from invasive ductal carcinoma of the breast.

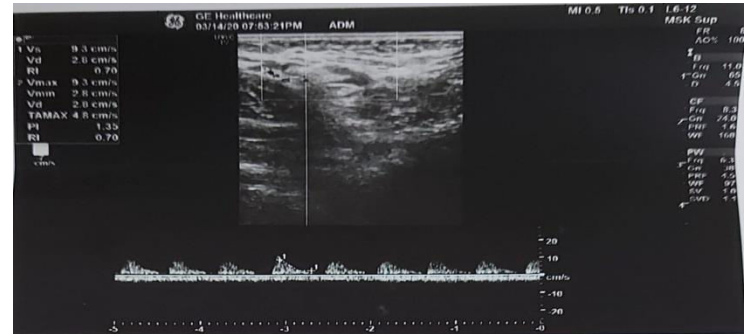


Fig. 6. Doppler ultrasound of 35 year old female patient complaining of mastalgia shows well-defined hypoechoic axillary lymph node with preserved hilum, resistive index of 0.70 and pulsatility index of 1.35. Follow up was suggestive of reactive lymph node.

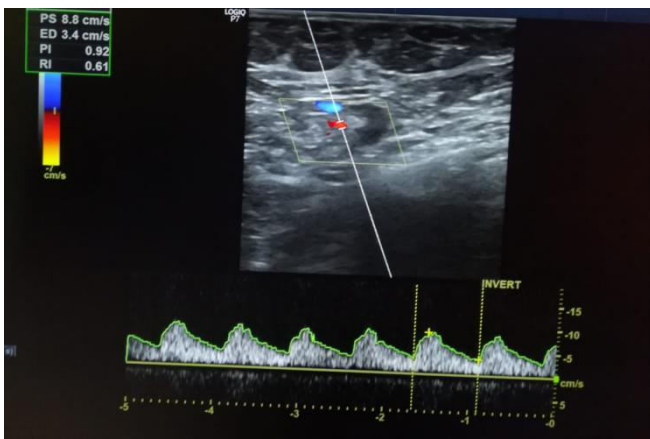


Fig. 4. Colour ultrasound of 30 year old female patient with breast fibroadenosis. It shows well-defined hypoechoic axillary LN with central hilar vascular pattern. Follow up was suggestive of reactive lymph node.

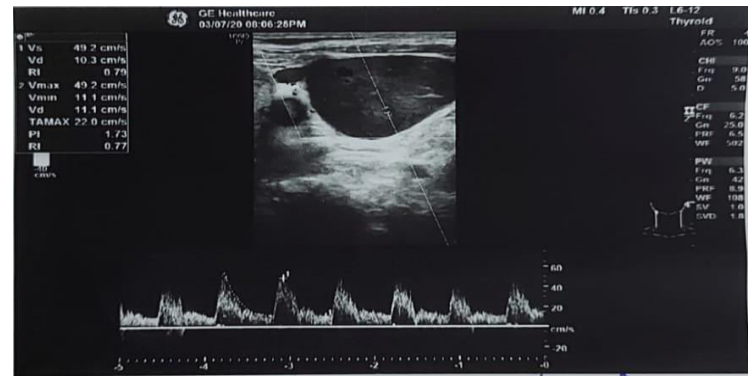


Fig. 7. Doppler ultrasound of 50 year old female patient shows well-defined hypoechoic cervical LN with lost hilum, PI=1.7 and RI=0.77. Histopathology revealed B-cell non-Hodgkin lymphoma.

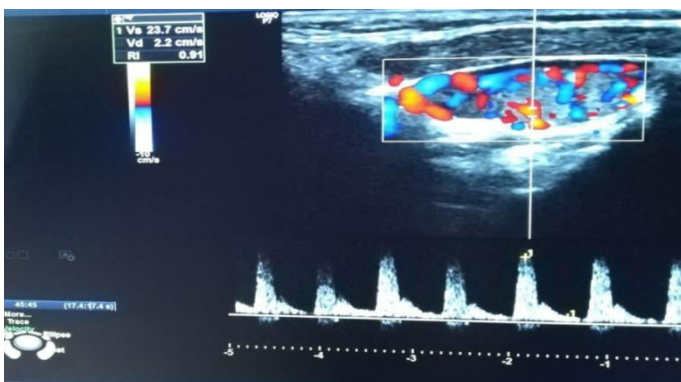


Fig. 5. Colour ultrasound of 50 year old female patient shows hypoechoic cervical LN with lost

**Conclusion**

In differentiating benign from malignant lymph nodes, Color Doppler ultrasound plays an important complementary role to ultrasound. This adds to the diagnostic faith that can predict malignancy. If grey scale ultrasound results are equivocal, color doppler is also beneficial, and it increases diagnostic accuracy. Color Doppler ultrasound, however will neither substitute histopathology nor remove the need for biopsy in order to distinguish between benign and malignant lymph nodes.

- **Bui T, Bordoni B. (2020).** Anatomy, abdomen and pelvis, inguinal lymph node, StatPearls Publishing. PMID: 32491571.
- **Chammas M, Macedo T, Lo V. (2016).** Predicting malignant neck lymphadenopathy using color duplex sonography based on multivariate analysis, J Clin Ultrasound, 44(9):587-594. doi: 10.1002/jcu.22380.
- **Deepankar M, Sapna P, Shalu R.(2016).** Diagnostic efficacy of color doppler ultrasound in evaluation of cervical lymphadenopathy, Dent Res J (Isfahan), 13(3):217-224. doi: 10.4103/17353327.182180.
- **Jayesh S, Sanjay M, Foram D. (2017).** Benign versus malignant cervical lymphadenopathy on ultrasound and doppler-a case series, Sch. J. App. Med. Sci, 5(11D):4611-4621. doi: 10.21276/sjams.2017.5.11.59.
- **Kanika G, Tushar C, Bhuvaneshwari V. (2016).** Role of color doppler ultrasound in predicting malignancy in cervical lymph nodes, International Journal of Anatomy. Radiology and Surgery, 5(4):15-20. doi: 10.7860/IJARS/2016/23816:2209.
- **Koroulakis A, Jamal Z, Agarwal M. (2020).**Anatomy, head and neck, lymph nodes, StatPearls Publishing. PMID: 30020689.
- **Mohamed S, Sameh M, Reham M. (2018).** Role of color doppler ultrasonography in differentiating benign and malignant cervical lymphadenopathy, Menofia Medical J, 31(3):1030-1035.
- **Raghavendra M, Anuradha P, Yadavalli G. (2013).**Efficacy of colour doppler ultrasound in diagnosis of cervical lymphadenopathy, J. Maxillofac. Oral Surg, 12(2):123–129. doi:10.1007/s12663-012-0395-1.
- **Venkatesh J, Ravi D, Rama S.(2013).** The efficacy of colour doppler ultrasound in differentiating malignant and nonmalignant head and neck lymph node enlargement. International Journal of Dental Science and