

# Post-operative Clinical and Radiological Assessment after Submucosal Resection of Inferior Turbinate and Partial Inferior Turbinectomy

Tarek Mohamed M. Mansour<sup>1</sup> MD, Mahmoud M. El Bahrawy<sup>2</sup> MD, Mohamed M. El-Barody<sup>3</sup> MD & Ahmed Okasha MD

**\* Corresponding Author:**

Tarek Mohamed M. Mansour

[drtarekrad@gmail.com](mailto:drtarekrad@gmail.com)

**Received** for publication November 1, 2020; **Accepted** February 21, 2020; **Published online** February 21, 2020.

**Copyright** 2021 The Authors published by Al-Azhar University, Faculty of Medicine, Cairo, Egypt. All rights reserved. This an open-access article distributed under the legal terms, where it is permissible to download and share the work provided it is properly cited. The work cannot be changed in any way or used commercially.

**doi:** [10.21608/aimj.2021.47460.1342](https://doi.org/10.21608/aimj.2021.47460.1342)

<sup>1</sup>Radio-diagnosis department, Faculty of Medicine, Al-Azhar University, Assuit, Egypt

<sup>2</sup>ENT department, Faculty of Medicine, Al-Azhar University, Assuit, Egypt

<sup>3</sup>Radio-diagnosis department, South Egypt cancer institute, Assuit University, Assuit, Egypt.

<sup>4</sup>Radio-diagnosis department, Faculty of Medicine, south valley University, Qena, Egypt.

## ABSTRACT

**Background:** Hypertrophied inferior turbinates, commonly caused by allergic rhinitis, cause nasal obstruction.

**Aim of this study:** This study aimed to evaluate nasal patency following submucosal resection of the inferior turbinate as a mucosa and bone-preserving method for reducing the size of the hypertrophied inferior turbinate, in comparison with the traditional method (partial inferior turbinectomy).

**Patient and methods:** This study was performed on patients with moderate to severe turbinate hypertrophy, selected from our ear, nose, and throat outpatient clinic, during March 2018 to March 2020. Patients were divided into GROUP I (n = 40; 25 males and 15 females), subjected to microdebridement submucosal turbinoplasty, and GROUP II (n = 40; 22 males and 18 females), subjected to traditional partial inferior turbinectomy.

**Result:** There was a statistically significant decrease in mean nasal obstruction scores and a significant increase in nasal cavity space distance at three levels of the inferior turbinate after 6 months (P < 0.05). Rhinorrhea and sneezing decreased significantly in both groups after 6 months (P < 0.05), but there was no significant difference between the groups in terms. There was significantly more post-operative bleeding, Crustations, and atrophic rhinitis in the GROUP II than in GROUP I in patients subjected to the traditional partial turbinectomy.

**Conclusion:** These results highlight the superiority of microdebridement to traditional turbinectomy for the management of chronic nasal obstruction, as it demonstrated the highest efficacy and least complications.

**Keywords:** Nasal obstruction; Submucosal microdebridement; Turbinectomy

**Disclosure:** The authors have no financial interest to declare in relation to the content of this article. The Article Processing Charge was paid for by the authors.

**Authorship:** All authors have a substantial contribution to the article.

## INTRODUCTION

The inferior turbinates are the main regulators of nasal airflow and play an important role in normal respiratory function. Their mucosa maintains a normal nasal defense, and humidifies, warms, and filters inspired air.<sup>1</sup>

Hypertrophied inferior turbinates, commonly caused by allergic rhinitis, cause nasal obstruction.

Turbinate surgery aims to improve nasal-breathing ability for recipients while preserving the physiological function of the nasal passages and mucosa, with minimal discomfort or adverse effects.

The ideal turbinate surgery would reduce the inferior turbinate volume while preserving the nasal mucosa.<sup>2</sup>

We compared nasal patency after submucosal resection of the inferior turbinate and after traditional turbinectomy.

## Patient and methods

### Ethics approval

The present study was approved by the medical research ethics committee at the University hospital and was performed following the Code of Ethics of the 1964 Declaration of Helsinki and its 2013 revision. Informed consent was obtained from parents or authorized legal guardians of all children who participated in the study.

### Study design and patient selection

This retrospective study included patients with chronic nasal obstruction and rhinitis, with enlarged inferior turbinates without any other causes of nasal obstruction, who were selected from our ear, nose, and throat outpatient clinic, during March 2018 to March 2020. We graded inferior turbinates from I (mild) to III (severe). Grade I was defined as mild enlargement with no obvious obstruction, while Grade III involved complete occlusion of the nasal cavity; turbinates that were intermediate between these grades were classified as Grade II (moderate). Grades II and III were included in this study. The patients were divided randomly into GROUP I (n = 40; 25 males and 15 females) subjected to microdebridement submucosal turbinoplasty and GROUP II (n = 40; 22 males and 18 females) subjected to traditional partial inferior turbinectomy.

### Study procedures

All patients were evaluated clinically, endoscopically and radiologically prior to surgery and 6 months after surgery. Patients were requested to avoid the use of oral or topical steroids, antihistamines, and vasoconstrictors prior to each examination to avoid confounding effects. The symptoms and signs of the patients under search are evaluated by clinically, and by evaluation tests VAS (Visual Analogue Score) and by sinuscope examination to assess the outcome of operation in both groups. The clinical parameters assessed were nasal obstruction, presence of a nasal or postnasal discharge, and sneezing. Post-procedural complications that were evaluated were intra-operative or post-operative bleeding, crustations, atrophic rhinitis, adhesions, and empty nose syndrome.

In GROUP I, the microdebrider submucosal turbinoplasty procedure was performed under general anesthesia and under endoscopic guidance. GROUP II underwent traditional partial turbinectomy under general anesthesia, using a 4-mm 0-degree sinuscope.

Airway patency was assessed objectively using a rigid 4-mm 0- or 30-degree sinuscope, and by measuring the nasal cavity at the level of the inferior turbinate assessed by VAS score, showing the distance between the inferior turbinate and the nasal septum in millimeters, on pre- and post-operative computed tomography (CT) scans. Multi-detector CT high-resolution coronal plane 5-mm-thick images were obtained all patients preoperatively and as well as 6 month postoperatively. The CT scans were

acquired using a 16-channel scanner (Genesis-zeus; GE Medical Systems, Chicago, IL) with axial and coronal scans. A tube voltage of 120 kilovolt peak (kVp) was used for 200–230 mA seconds; slice thickness was 5 mm, field-of-view was 512 × 512 mm. The window width and level of CT were controlled to allow visualization of mucosal and ostial lesions.

Measurements were made at the anterior, middle, and posterior thirds of the inferior turbinate in coronal sections. For standardization, anterior measurement was performed on the first image in which the entire inferior turbinate bone could be identified (level 1). The middle measurement was performed on the section in which the uncinate process and maxillary sinus ostium could be visualized (level 2). The posterior measurement was performed on the last image in which the entire inferior turbinate, at maximal size, could be identified (level 3). All images were magnified to facilitate accurate measurement. The thicknesses, in millimeters, of the medial mucosa, bone, and lateral mucosa, and the distance between the nasal septum and medial mucosa of the inferior turbinate were measured separately at the anterior, middle, and posterior portions of the inferior turbinate, on a plane perpendicular to the mucosal surface in the inferior turbinate, with the aid of a cursor on the CT scanner screen. Three lines were traced below the three levels of the inferior turbinate, and the distance was calculated in millimeters in both preoperative and postoperative scans, for comparison within and between groups (Fig. 1). Specifically, the distance between the nasal septum and medial mucosa of the inferior turbinate was measured at the anterior, middle, and posterior level, and the cross-sectional distance of the whole inferior turbinate, including the medial mucosal layer, lateral mucosal layer, and the bony part of inferior turbinate, were measured in millimeters on pre- and post-operative CT scans and compared in both groups.

### Statistical analysis

Quantitative data are presented as mean and standard deviation. Other than nasal obstruction, rhinorrhea, and sneezing scores, which had a non-normal distribution, all data showed a normal distribution. For normally distributed data, one-way ANOVA (analysis of variance) was used to compare between the two groups. Tukey's post-hoc test was used for pair-wise comparisons of mean values when the ANOVA produced significant results. Paired *t*-tests were used to study the changes by time within each group. For non-normally distributed data, the Kruskal–Wallis test was used to compare between the two groups. The Mann–Whitney U test was used for pair-wise comparisons between the groups when the Kruskal–Wallis test was significant. Wilcoxon's signed-rank test was used to study the changes in non-normally distributed parameters by time within each group.

## RESULTS

The baseline characteristics of the two groups are compared in Table 1. There was no statistically significant difference between groups in terms of age or sex distributions.

There was no statistically significant difference between the two groups in terms of any symptoms; however, there was a statistically significant decrease in mean nasal obstruction scores after 6 months in both groups which Tables (2, 3).

Traditional surgical turbinectomy was associated with a statistically significantly higher prevalence of bleeding, crustation, empty nose syndrome, atrophic

rhinitis, and synechia than microdebridement, which showed small areas of crustations over a few sites of iatrogenic mucosal tears, and which healed rapidly within a few weeks Table (4).

There was a statistically significant difference between GROUPS I and II at anterior level 1, which showed a more significant increase in nasal cavity space distance at the three levels, decrease in medial mucosal thickness, and decrease in the cross-sectional distance at the three levels Figure (2) after 6 months Tables (5–7). At levels 2 and 3, there was a greater increase in nasal cavity space distance and a decrease in mucosal thickness in GROUP II than in GROUP I Figure (3).

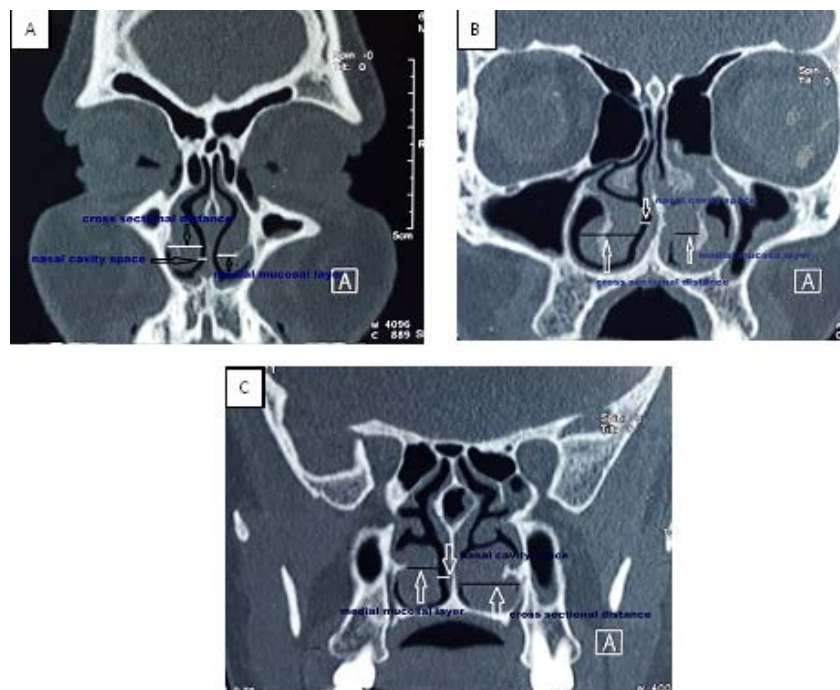


Figure 1: Preoperative inferior turbinate bone-window parasinaxial sinus coronal computed tomography showing lines for measuring nasal cavity, medial mucosal layer, and cross-sectional inferior turbinate distances. (A) Level 1. (B) Level 2: maxillary sinus ostium/uncinate process. (C) Level 3: largest posterior inferior turbinate-end.

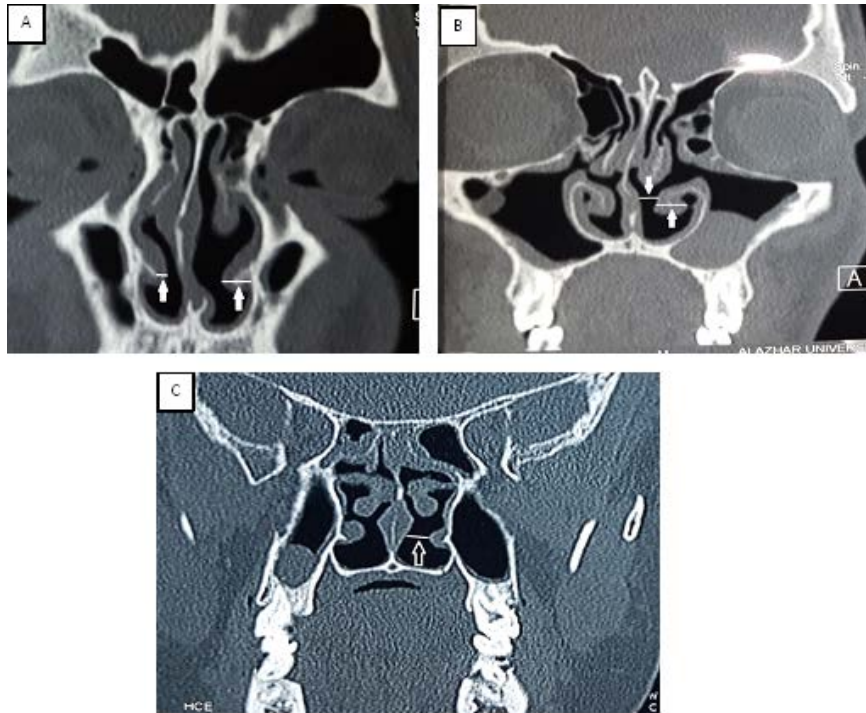


Figure 2: Nose and paranasal sinus coronal computed tomography images obtained 6-months post-microdebrider surgery. (A) Level 1: decreased medial mucosal layer (right arrow) and cross-sectional distance (left arrow). (B) Levels 2 and (C) 3: increased nasal cavity (upper arrow) and (B) decreased cross-sectional distances (lower arrow).

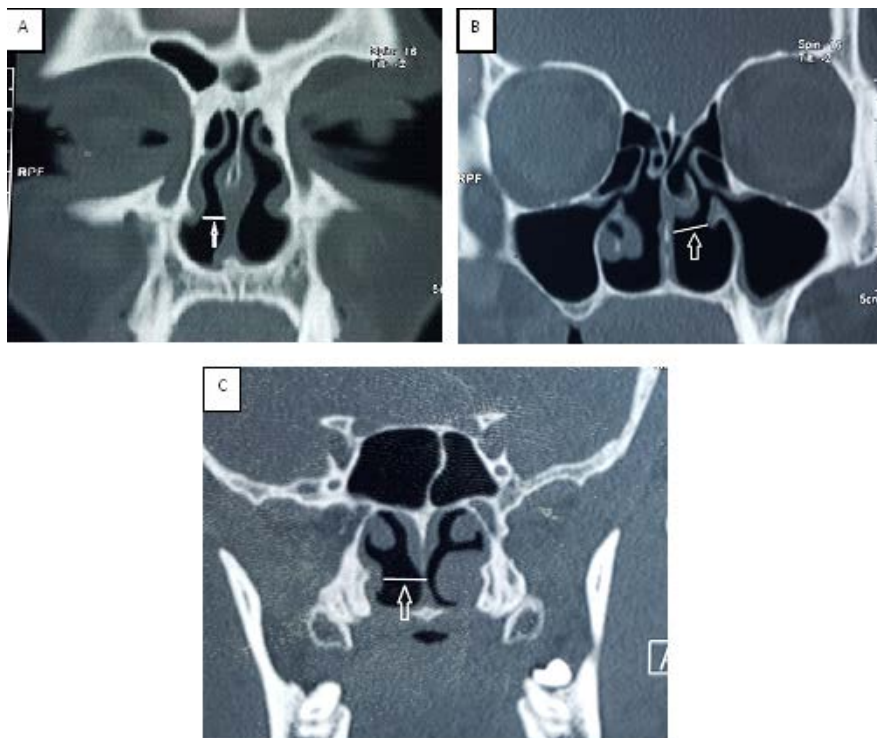


Figure 3: Nose and paranasal sinus coronal computed tomography images obtained 6 months after traditional surgery of the inferior turbinate. (A) Level 1: increased nasal cavity distance (arrow). (B) Levels 2 and (C) 3: increased nasal cavity space (arrows).

Demographic data	Submucosal Microdebrider (n = 40)	Conventional surgical (n = 40)	P-value
Age (Mean $\pm$ SD)	25.7 $\pm$ 7.2	26.5 $\pm$ 7.8	0.555
Gender (freq., %)			0.498
Male	25 (62.5 %)	22 (55%)	
Female	15 (37.5%)	18 (45%)	

Significant at  $P \leq 0.05$

Table 1: Mean, standard deviation (SD), frequency, percentage values and results of one-way ANOVA test and Chi-square test for comparison between ages and gender distributions in the two groups.

The procedure	Preoperative	6 months postoperative	P-value
Microdebrider (frequency, %)	40 (100)	4(10)	<0.0001*
Traditional (frequency, %)	40(100)	2(5)	<0.0001*

\*: Significant at  $P \leq 0.05$

Table 2: frequency and comparison of proportions of chi-square test for the changes by time in mean nasal obstruction scores of each group.

The procedure	Submucosal Microdebrider (n = 40)	traditional surgical (n = 40)	P-value
Period			
Preoperative - 6months postoperative	90 $\pm$ 2.2 <sup>a</sup>	95 $\pm$ 3.1 <sup>a</sup>	<0.001*

\*: Significant at  $P \leq 0.05$ , Different letters are statistically significantly different according to Tukey's test

Table 3: Mean, standard deviation (SD) values and results of one-way ANOVA test and Tukey's test for comparison between percentage of decrease in nasal obstruction scores in the two groups.

Complications	Submucosal Microdebrider (n = 40)	traditional surgical (n = 40)	P-value
Bleeding (Frequency, %)	0 (0%)	6 (15%)	0.0114*
Empty nose synd. (frequency, %)	0 (0%)	4 (10%)	0.0414*
Synaechia, (frequency, %)	0 (0%)	2 (5%)	0.1547
Atrophic rhinitis (frequency, %)	0(0%)	4(10%)	0.0414*

\*: Significant at  $P \leq 0.05$

Table 4: Frequency, percentage values and results of Chi-square test for comparison between complications in the two groups.

Procedure Level	Microdeprider (n=40)	Traditional (n=40)	p-value
Level 1 (mean ± SD)	Pre. 1.8± 0.8	Pre. 1.6 ± 0.6	0.0209
	Post. 3.8 ± 0.9	Post. 2.5 ± 0.6	0.0001*
Level 2 (mean ± SD)	Pre. 1.3 ± 0.9	Pre. 1.1 ±0.9	0.3234
	Post. 3.1 ± 1.1	Post.12.1 ± 2	0.0001*
Level 3 (mean ± SD)	Pre. 0.9 ±0 .7	Pre. 1.1 ± 0.9	0.2707
	Post. 2.8 ± 0.8	Post. 13.4 ± 3	0.0001*

\*: Significant at  $P \leq 0.05$  . Level 1; at the anterior end of inferior turbinate at maximum size, Level 2 ; at the maxillary sinus ostium, Level 3 ; at the posterior end of inferior turbinate at maximum size.

Table 5: Mean, standard deviation (SD) values and results of Chi-square test and T-test for comparison between nasal cavity distance space scores in millimeters in preoperative and 6 months postoperative CT scans at the three levels of inferior turbinate in both groups.

Procedure Level	Microdeprider (n=40)	traditional (n=40)	P- value
Level 1 (mean ± SD)	Pre. 6.1 ± 1.3	Pre. 6.6 ± 1.3	0.0894
	Post. 3.9 ± 0.9	Post. 5.8 ± 1.2	0.0001*
Level 2 (mean ± SD)	Pre. 6.1 ± 1.2	Pre. 6.4 ±1.4	0.3067
	Post. 5 ± 1.1	Post.1.5 ± 1	0.0001*
Level 3 (mean ± SD)	Pre. 6.2 ± 1.2	Pre. 6.5 ± 1.4	0.3067
	Post. 4.6 ± 0.9	Post. 0.9 ± 0.8	0.0001*

\*: Significant at  $P \leq 0.05$  . Level 1; at the anterior end of inferior turbinate at maximum size, Level 2 ; at the maxillary sinus ostium, Level 3 ; at the posterior end of inferior turbinate at maximum size.

Table 6: Mean, standard deviation (SD) values and results of Chi-square test and T-test for comparison between medial mucosal thickness scores in millimeters in preoperative and 6 months postoperative CT scans at the three levels in both groups.

Procedure Level	Microdeprider (n=40)	Traditional (n=40)	P-value
Level 1 (mean ± SD)	Pre. 11±2.3	Pre. 11.6 ± 2.2	0.2368
	Post. 8.7±2.1	Post. 6.5 ± 2	0.0001*
Level 2 (mean ± SD)	Pre. 11.1±2.3	Pre. 11.7±2.2	0.2368
	Post. 8.3±1.9	Post. 6.3±2.1	0.0001*
Level 3 (mean ± SD)	Pre. 11.9±1.6	Pre.12.1± 1.8	0.6009
	Post. 9 ± 1.3	Post. 6.7 ± 1.7	0.0001*

\*: Significant at  $P \leq 0.05$  . Level 1; at the anterior end of inferior turbinate at maximum size, Level 2 ; at the maxillary sinus ostium, Level 3 ; at the posterior end of inferior turbinate at maximum size.

Table 7: Mean, standard deviation (SD) values and results of Chi-square test and T-test for comparison between cross sectional distance scores in millimeters in preoperative and 6 months postoperative CT scans at the three levels in both groups.

## DISCUSSION

Inferior turbinectomy is an accepted treatment for nasal obstruction and considerably improves the nasal airway.<sup>3</sup> Pizzi and colleagues has reported that, among all available surgical procedures, submucosal resection provided the greatest relief of nasal obstruction due to hypertrophy of the inferior turbinates.<sup>4</sup> However, this technique produces some damage to the mucosa of the inferior turbinate and requires good surgical skills. Thus, in this study, we compared the outcomes after traditional turbinectomy and microdebridement submucosal turbinoplasty and found evidence of the superiority of microdebridement, as it demonstrated the highest efficacy and least complications in the management of chronic nasal obstruction.

We compared three main factors: changes in the subjective complaints of the patients, including nasal obstruction, rhinorrhea, and sneezing, by visual analogue scale score; complications occurring intra- or post-operatively, determined by nasal endoscopic examination, and objective nasal findings based on endoscopy and CT evaluations.

In both groups, nasal obstruction had mostly disappeared by 6-months post-operatively or were significantly decreased ( $P < 0.05$ ), but there is significant difference are present if compared to each other.

Rhinorrhea and sneezing had significantly decreased in both groups after 6 months ( $P < 0.05$ ). However, there was no significant difference in terms of rhinorrhea or sneezing between the two groups after 6 months ( $P > 0.05$ ). This was in agreement with Tabajara et al.<sup>5</sup> who reported that, in a microdebrider group, nasal obstruction, rhinorrhea, and sneezing significantly improved by 6 months to 3 years postoperatively, as compared to their preoperative levels. Additionally, Chan and colleagues,<sup>6</sup> in their short-term study, also found that both microdebridement and conventional surgical turbinectomy were effective for relieving nasal obstruction, rhinorrhea, and sneezing in patients with hypertrophy of the inferior turbinates. In our study a significant improvement ( $P < 0.05$ ) in pre-existing nasal obstruction, rhinorrhea, and sneezing was noted between 1 month and 3 months after surgery in both groups.

Moreover, Chen et al.<sup>7</sup> also reported the efficacy of microdebridement for submucosal resection when they evaluated the long-term (3-year) outcomes of endoscopic microdebridement without fracture, as compared with endoscopic submucous tissue resection alone for hypertrophic turbinates in 145 patients with perennial allergic rhinitis. Both groups showed similar improvement in the visual analogue scale scores at 1 year, which were sustained to 3 years post-operatively.

In terms of complications, the present study showed a significant difference in bleeding between the two groups postoperatively ( $P < 0.05$ ). In GROUP I, no bleeding occurred in any patients, while six patients suffered bleeding after conventional surgical

turbinectomy (15% of GROUP II showed bleeding during the operation or few days after the operation, which stopped after 2 days of nasal packing). There was also a significant difference in nasal crustation and atrophic rhinitis between the two groups ( $P < 0.05$ ): 0% in GROUP I and 10% in GROUP II. Chen and colleagues partially agreed with this study's findings, because they reported a significant increase in crustations ( $P < 0.05$ ) over the inferior turbinate, from 0% in the microdebridement group to  $2.50 \pm 0.51\%$  in the conventional surgical group, which was markedly lower than in our study; nevertheless, the direction of change was similar between the studies.

Inferior turbinate hypertrophy can be confirmed objectively by rhinomanometry. This investigation is performed with and without decongestion and total resistance is calculated. Resistance above 0.3 Pa/ml/s is usually considered symptomatic.<sup>8</sup> CT is indicated for the evaluation of nasal obstruction when a cause cannot be identified on physical examination by endoscopy, or when evaluating tumors or polyps. CT is not indicated in the workup of inferior turbinate hypertrophy alone. However, if a CT scan of the nose and paranasal sinuses has been obtained for other reasons, it may provide useful information, such as assessment of bony versus mucosal hypertrophy.<sup>9</sup>

El-Anwar et al.<sup>10</sup> provided normal CT parameters that we used as reference in our study; the results of post-operative CT scans were near the normal parameters of the normal inferior turbinate reported in that study. In addition, our study demonstrated that the nasal cavity distance (airway space) was wider than the normal parameters previously reported.

In our study, the results regarding patency after microdebridement and partial turbinectomy showed increased airflow and nasal respiratory function, and the lowest risk of long-term complications, in the microdebridement group. There was a significant decrease in the thickness of the medial mucosa of the inferior turbinate and decreased mean dimensions of the inferior turbinate. We showed a statistically significant decrease between GROUP I and GROUP II, with a significant greater decrease in medial mucosal thickness at levels 2 and 3 after 6 months; however, microdebridement showed a more significant decrease in medial mucosal thickness at level 1. Moreover, we showed a statistically difference between the microdebridement group and traditional turbinectomy group, with a significantly greater increase in nasal cavity space distance at all three levels after 6 months.

Cingi et al.<sup>11</sup> agreed with the findings of this study in terms of efficacy when they compared the short-term effects (up to 3 months post-operatively) of microdebridement with those of radiofrequency treatment in a study of 268 patients. They found that both the microdebridement and radiofrequency group had statistically significant improvement in nasal obstruction symptoms after 1 month; however, only the microdebridement showed persistent and statistically significant improvement at 3 months. Therefore, Cingi et al.'s study showed that microdebridement-assisted turbinoplasty was more

effective than the radiofrequency-assisted technique for the relief of nasal obstructive symptoms.<sup>11</sup>

Romano et al.<sup>12</sup> concluded that microdebridement-assisted inferior turbinoplasty and partial inferior turbinectomy are both very effective surgical techniques for resolving hypertrophy of the inferior turbinates and the related problems of nasal obstruction. However, compared to partial inferior turbinectomy, the microdebridement-assisted inferior turbinoplasty ensures greater preservation of the nasal mucosa, preventing nasal bleeding, which agreed with the results of our study.

The study had some limitations, including a limited sample size and short-term follow-up. Longer-term studies with larger sample sizes are needed to confirm the good results obtained with microdebridement in this study.

### CONCLUSION

In conclusion, we recommend the use of microdebridement as a standard method for inferior turbinate surgery, due to its advantages over the traditional method in terms of efficacy in improving nasal obstruction and reducing the complications that follow the traditional method.

### REFERENCES

- Grymer LF, Ilium P, Hilberg O. Septoplasty and compensatory inferior turbinate hypertrophy: A randomized study evaluated by acoustic rhinometry. *J. Laryngol. Otol.* 2008;107:413-417.
- Chen YL, Tan CT, Huang HM long-term efficacy of microdebrider-assisted inferior turbinoplasty with lateralization for hypertrophic inferior turbinates in patients with perennial allergic rhinitis, *Laryngoscope.* 2008;118:1270-1274.
- Samad I, Stevens HE, Maloney A. The efficacy of nasal septal surgery. *J. Otolaryngol.* 2004;21:88-91.
- Pizzi S, Bernardi SCF, Mantovani W. Clinicopathological evaluation of ciliary dyskinesia: diagnostic role of electron microscopy. *Ultrastruct. Pathol.* 2008;27:243-252.
- Tabajara CC, Roithmann R. Turbinectomy parcial tradicional × five-minutes turbinectomy: resultados preliminares. *Braz. J. Otolaryngol.* 2011;77 Suppl. 46.
- Chan R, Astor FC, Younis RT. Embryology and Anatomy of the Nose and Paranasal Sinuses. Pediatric Sinusitis and Sinus Surgery. *Taylor & Francis.* 2006.
- Chen YL, Tan CT and Huang HM. Long term efficacy of microdebrider-assisted inferior turbinoplasty with lateralization for hypertrophic inferior turbinates in patients with perennial allergic rhinitis, *Laryngoscope.* 2008: 118:1270-1274.
- Sozansky J, Houser SM. The physiological mechanism for sensing nasal airflow: a literature review. *Int. Forum Allergy Rhinol.* 2014;4:834-838.
- Uzun L, Savranlar A, Beder LB, Ugur MB, Cinar F, Ozdemir H, et al. Enlargement of the bone component in different parts of compensatorily hypertrophied inferior turbinate. *Am. J. Rhinol.* 2004;18:405-410.
- El-Anwar MW, Hamed AA, Abdulmonaem G, Elnashar I, Elfiki IM. Computed tomography measurement of inferior turbinate in asymptomatic adult. *Int. Arch. Otorhinolaryngol.* 2017;21:366-370 .
- Cingi C, Ure B, Cakli H, Ozudogru E. Microdebrider-assisted versus radiofrequency-assisted inferior turbinoplasty: a prospective study with objective and subjective outcome measures. *Acta Otorhinolaryngol. Ital.* 2010;30:138-143.
- Romano A, Orabona GD, Salzano G, Abbate V, Iaconetta G, Califano L. Comparative study between partial inferior turbinectomy and microdebrider-assisted inferior turbinoplasty. *Craniofac. Surg.* 2015;26:e235-e238.