

Is Sutureless and Glueless Limbal Conjunctival Autograft for Primary Pterygium Surgery Efficient and Safe?

Hoda Saeed Mohamed Hassan Arab

Ophthalmology Department, Faculty of Medicine for Girls, Al-Azhar University

ABSTRACT

Aim of the study: evaluate the safety and efficacy of sutureless glue free limbal conjunctival autograft for the management of primary pterygium surgery.

Material and method: This prospective, interventional randomized, non-comparative study was held at AlZahraa University Hospital between May, 2013 and June, 2015. It included 20 eyes of 17 patients, 12 males (70.6%), and 5 females (29.4%). Their mean age \pm SD was 52.50 ± 18.31 years (Range: 30-75 years). They were presented to the outpatient clinic of Al Zahraa University Hospital with primary pterygium. Inclusion criteria included primary pterygium, non atrophic, with healthy conjunctiva. Exclusion criteria included atrophic pterygium, pseudopterygium, ocular surface pathology, infection, previous limbal surgery or double head pterygium. Surgeries were done under local anesthesia. Simple pterygium excision was done leaving a bare sclera. The size of bare sclera was measured. A conjunctival graft 2 mm larger in width and length than the recipient bed was created from the superior temporal quadrant and was extended to the limbus to include limbal stem cells. The graft was gently moved to the recipient bed with the epithelial side up and keeping the limbal edge toward the limbus. Hemostasis was allowed to occur spontaneously without use of cautery to provide autologous fibrin to glue the conjunctival autograft naturally in position without tension. All patients were followed up after 48 hours, weekly for one month then monthly for 12 months. **Results:** Pterygia were located nasally in all cases. Pterygia were presented right eye in 10 (50%) and left eye 10 (50%). Mean graft size \pm SD was 5.5 ± 1.5 millimeter (Range: 5-7 mm). Mean duration of graft fixation \pm SD was 10 ± 2.82 minutes (Range: 10-12 minutes). Mean operative time \pm SD was 25 ± 1.41 minutes (Range: 24-26 minutes) with good cosmetic outcome in all cases. There was minimal postoperative pain and discomfort, without graft dislocation or dehiscence and without recurrence of pterygia during the follow up period.

Conclusion: Sutureless and glueless conjunctival limbal autograft following primary pterygium excision is safe, easy, effective and economic technique in primary pterygium surgery.

Keywords: Pterygium, Fibrin glue, Limbal autograft, graft retraction, conjunctival edema.

INTRODUCTION

Pterygium (derived from pterygion, ancient Greek for wing) is a common ocular disease seen mostly in tropical and subtropical areas. It is an abnormal overgrowth of fibrovascular tissue arising from the subconjunctiva toward the cornea, almost always in the palpebral fissure and thought to be caused by increased light exposure, dust, dryness, heat and wind.^[1] Although it can be easily excised, it has a high rate of recurrence ranging between 24% and 89%.^[2] With the popularity of conjunctival autograft and use of antimetabolites such as mitomycin C and 5-Fluorouracil the incidence of recurrence has been greatly reduced up to 12%.^[3-5] The role of carbon dioxide and excimer lasers in pterygium surgery remains uncertain. Additionally, the relative benefits and risks are debatable of physiochemical methods to prevent recurrence. For example possible complications of mitomycin C and beta-irradiation include aseptic necrosis of the sclera and cornea, cataract, persistent epithelial defects and visual loss.^[6] Therefore, a simple surgical procedure that can

reduce the recurrence rate to an acceptable level with minimal complications and without the use of potentially toxic drugs or radiotherapy would be ideal for the management of pterygium. Some reports favor the use of fibrin glue above sutures.^[7-8] The use of fibrin glue has been reported to improve comfort, decrease surgical time, reduce complications and recurrence rates.^[9-10] Suture-related complications include infection, prolonged operating time, postoperative discomfort, suture abscesses, buttonholes, and pyogenic granuloma which usually require a second surgery for removal^[11]. Plasma-derived fibrin glue has the potential risk of disease transmission and anaphylaxis in susceptible individuals.^[12,13]

Sutureless grafting has been used successfully in gingival grafts and represents a similar mucosal membrane tissue environment to the conjunctiva of the eye.^[14]

In this study, we evaluate the safety and efficacy of sutureless glue free

limbal conjunctival autograft for the management of primary pterygium surgery.

PATIENTS AND METHODS

This prospective, interventional randomized non-comparative study was done at Al Zahraa University Hospital between May, 2013 and June, 2015. It included 20 eyes of 17 patients, 12 males (70.6%) and 5 females (29.4%). Their mean age \pm SD was 52.50 ± 18.31 years (Range: 30-75 years). They attended the outpatient clinics of Al Zahraa University Hospital and were presented with primary pterygium. Patients complain included red eye, tearing, rapid growth of the pterygium over the cornea, dropped vision as well as cosmetic concerns.

Inclusion criteria included primary pterygium, non atrophic, with healthy conjunctiva. Exclusion criteria were recurrent pterygium, atrophic pterygium, pseudopterygium, ocular surface pathology, infection, previous limbal surgery or double head pterygium.

An informed written consent was signed by the patient in all cases. All patients were subjected to a comprehensive ophthalmologic examination including visual acuity, refraction, slit lamp biomicroscopy, measurement of intraocular pressure, extraocular muscle movements and dilated funduscopy. Anterior segment photography was performed for documentation of pterygium size and morphology.

The goals of pterygium surgery were to remove the pterygium, restore the conjunctival anatomy, leave the cornea as smooth and clear as possible, and prevent recurrence.

Simple pterygium excision was performed under peribulbar anesthesia using 2% Lidocaine. After an eyelid speculum was inserted, local anesthesia was used to balloon the pterygium separating it from the sclera. Excision consisted of detachment of the pterygium head using a crescent knife and dissection of the body from the overlying conjunctiva in a smooth clear plane as possible using blunt and sharp dissection. Subsequently, the subconjunctival pterygium tissue and the thickened segment of conjunctiva and adjacent Tenon's capsule were excised leaving bare sclera. Then the size of bare sclera was measured with calipers and was documented in millimeters.

For harvesting the conjunctival autograft, the globe was rotated downward with a limbal traction suture. The superior temporal quadrant of bulbar conjunctiva was injected with 1 cc of 2% Lidocaine to facilitate separation of the conjunctiva from Tenon's capsule, then a marker was used to mark the four corners of the

conjunctival limbal graft that was created 2 mm larger in width and length than the recipient bed. A small opening was created and a careful blunt dissection with Westcott scissors was performed until the entire graft was free from Tenon's reaching the limbus to include limbal stem cells that act as a barrier to the conjunctival cells migrating onto the corneal surface. Subsequently, the edges of the graft were cut by Vannas scissors. Forceps was used to gently slide the graft to the recipient bed with the epithelial side up and keeping the limbal edge toward the limbus.

Hemostasis was allowed to occur spontaneously without use of cautery to provide autologous fibrin to glue the conjunctival autograft naturally in position without tension, and the scleral bed was viewed through the transparent conjunctiva to ensure that residual bleeding did not lift the graft. Small central hemorrhages were lampooned with direct compression. The graft was held in position for 10 min by application of gentle pressure over the graft with fine non-toothed forceps. The stabilization of the graft was tested with a Merocel spear centrally and on each free edge to ensure firm adherence to the sclera. The eye was bandaged for 48 hours. Postoperatively, a pressure eye patch was applied. Analgesia in the form of 50 mg diclofenac tablets was prescribed two times daily for 5 days. Postoperative medications included Tobramycin and dexamethasone eye ointment, three times daily for 1 week with gradual tapering over 3 weeks and liberal use of topical lubricating eye drops (0.5% Carboxymethyl cellulose sodium) four times daily for 4 weeks. Patients were instructed to avoid rubbing their eyes for 24 hours and avoid dust, heat, as well as direct sun exposure. Patients were also advised to wear sun glasses for 7 days.

All patients were followed up after 48 hours, weekly for one month then monthly for 12 months. The main postoperative outcomes included the recurrence (which was defined as fibrovascular proliferation invading the cornea more than 1.5 mm at the site of previously excised pterygium), graft dehiscence and graft retraction. The secondary outcomes included the duration of surgery, postoperative pain, foreign body eye sensation, photophobia, hyperemia, chemosis, and complications as, persistent epithelial defect, dellen, inclusion cyst, pyogenic granuloma, conjunctival edema, corneo-scleral necrosis, infective scleritis, keratitis and endophthalmitis.

STATISTICAL ANALYSIS

Data were collected, coded, revised and entered to the Statistical Package for Social Science (IBM SPSS) version 20. The data were presented as number and percentages for the qualitative data, mean, standard deviations and ranges for the quantitative data with parametric distribution and median with inter quartile range (IQR) for the quantitative data with non parametric distribution. Spearman correlation coefficients were used to assess the significant relation between two quantitative parameters in the same group .

The confidence interval was set to 95% and the margin of error accepted was set to 5%. So, the p-value was considered significant as the following:

P > 0.05: Non significant (NS)

P < 0.05: Significant (S)

P < 0.01: Highly significant (HS).

RESULTS

All pterygia were located nasally in all cases. Mean patient age \pm SD was 52.50 \pm 18.31 years (Range: 30-75 years). They were 12 males(70.6%) and 5females (29.4%). Pterygia were presented in the right eye in 11 cases (55%) and in the left eye in 9 cases (45%). Mean horizontal graft size \pm SD was 6.4 \pm 1.1mm(Range: 5-8 mm), while mean vertical graft size \pm SD was 5.8 \pm 0.8mm (Range: 4-7 mm). Mean duration of graft fixation \pm SD was 11.5 \pm 1.82 minutes. (Range: 9-14 minutes). Mean operative time \pm SD was 26.3 \pm 1.41 minutes(Range: 24-28 minutes). There was good cosmetic outcome in all cases, with minimal postoperative pain and discomfort. Mean follow up period \pm SD was 9.2 \pm 1.6 months (Range: 7-12 months). No graft dislocation, dehiscence or recurrences of pterygia were reported during the follow up period (Table 1).

Conjunctival edema occurred in one eye (5%). It resolved gradually within the first post-operative week. Faint corneal nebula occurred at the site of excised pterygia in one eye (5%) and graft retraction in 2 eyes(10%). No Conjunctival cyst ordellen were reported. There were no anesthetic complications, graft necrosis, symblepharon, scleral necrosis or thinning, excessive bleeding, globe perforation or injury to the medial rectus muscle (Table2).

DISCUSSION

Surgical techniques for the management of pterygium vary, but high recurrence rates after successful excision remain a challenge. The aim of pterygium surgery is to excise the pterygium and prevent its recurrence^[15]. However, there are very few clinical guidelines for optimal treatment that

lower recurrence and complication rates. The variety of techniques, range from the bare scleraprocedure to more complex approaches, such as amniotic membrane transplantation and lamellar keratoplasty, including conjunctival autograft, and limbal conjunctival transplant, conjunctival flap, conjunctival rotation autograft surgery, cultivated conjunctival transplant (ex-vivo expanded conjunctival epithelial sheet) and the use of fibrin glue. Adjunctive therapies include Beta irradiation, 5-Fluorouracil, Daunorubicin, and Mitomycin C (MMC).^[15-19]

Bare sclera excision (BSE) has an unacceptably high recurrence rate (40–60%) and has become obsolete. BSE with perioperative MMC^[20-22] preoperative subconjunctival injection, intraoperative application and postoperative drops had yielded better outcomes, but the risk of complications has made these procedures less favorable. BSE with beta irradiation has resulted in encouraging outcomes (13% recurrence); however it has some reported complications.^{(20-23).}

Pterygium excision with limbal conjunctival autograft, has been reported to be more effective with low recurrence rate but it may compromise the corneal stem cell population. Additionally, adjunctive use of amniotic membrane graft results in low recurrence rate but it is costly.^[24,25]

Fibrin glue has been used as an alternative to sutures for securing the conjunctival grafts. One study has reported recurrence rate of 5.3% for glue versus 13.5% for sutures and suggested that immediate adherence of the graft and lack of postoperative inflammation may inhibit fibroblast ingrowth and reduce the recurrence. The main issue in using commercial fibrin glue, despite viral inactivation techniques, is the transmission of infectious agents such as parvovirus B19 (HPV B19). Furthermore, anaphylactic reaction has been reported after the use of (TISSEEL) fibrin sealant which was due to bovine protein aprotinin. Foroutan *et al.*^[23] prepared autologous fibrin glue, though that it is much safer but not yet used widely because of the duration it takes to procure the fibrin and lack of laboratory facilities at all centers. They reported that fibrinogen compounds may be susceptible to inactivation by iodine preparations used for conjunctival disinfection before pterygium surgery.^[23]

In our study we used the technique of sutureless and glue free conjunctival limbal autograft, in primary pterygium surgery without recurrence (0%) during follow up period of one year. Massaouti *et al.*^[26] stated that the concept of surgical success in pterygium surgery can be defined as the provision

of a white cosmetic conjunctiva, with no persistent symptoms and a low recurrence rate (less than 10%). The recurrence rate in our study agrees with the Massautiset *al.*'s criteria. The recurrence rate is also similar to Malik *et al.*^[27] who reported recurrence rate of 2.5% using a similar procedure of sutureless and glue free graft, with a follow up period of 30 months.

Graft dehiscence is a recognized complication of techniques using glue. Froutanet *al.*^[23] reported 13.33% rate of graft dehiscence using autologous fibrin and attributed this to a low concentration of thrombin and fibrinogen in autologous glue compared to a commercial preparation. In our study no graft dehiscence occurred. We attributed this to the strict patient instructions to use a protective shell and not to rub the eye in the first post-operative week, and to the meticulous dissections of thin donor limbal conjunctival autograft free of Tenon's capsule.

Graft retraction was reported by Tan^[10] who advocated sub-conjunctival fibrosis and recommended meticulous dissection of sub-epithelial graft tissue. Foroutanet *al.*^[23] reported 20% graft retraction. In our study graft retraction was reported in 2 eyes out of 20 (10%). We think that all graft retraction in our study was due to conjunctival chemosis and edema. They showed complete resolution within 24 hours using a combination of Tobramycin and Dexamethasone eye drops 4 times daily. Wit *et al.*^[25] reported no graft displacement and postulated that sutureless and glue free graft resulted in even tension across the whole graft interface

The mean operative time \pm SD was 26.3 \pm 1.41 minutes (Range: 24-28 minutes), and the mean graft fixation time \pm SD was 11.5 \pm 1.82 minutes (Range: 9-14 minutes). These durations are comparable but longer than other studies^[23,28,29] using fibrin glue who reported average operative time of 16 min (Range: 14-16) and 20 min (Range: 20-29) in suture-less and glue free conjunctival autograft.

Our results confirmed significantly lower post-operative signs and symptoms including irritation, pain, foreign body sensation, photophobia, hyperemia and chemosis at all follow up visits. None of our patients developed serious complications such as scleral necrosis, sclera thinning, graft necrosis, symblepharon, excessive bleeding, medial rectus muscle injury, or globe perforation.

CONCLUSION

Sutureless and glueless conjunctival limbal autograft following primary pterygium excision is

safe, easy, effective and economic technique in primary pterygium surgery.

REFERENCE

1. **Rosenthal JW (1953).** "Chronology of pterygium therapy". *Am J Ophthalmol.* ,36:1601-1606.
2. **Gupta VP (1997).** "Conjunctival transplantation for pterygium". *DJO.* ,5:5-12.
3. **Singh G, Wilson NR, Foster CS (1988).** "Mitomycin eye drops as treatment for pterygium". *Ophthalmology*,95:813-821.
4. **Tarr KH, Constable IJ (1980).** "Late complications of pterygium treatment". *Br J Ophthalmol.* ,64:496-505.
5. **Gans LA (1996).** "Focal points: clinical modules for ophthalmologists". American Academy of Ophthalmology, San Francisco: Surgical treatment of pterygium; p. 2. Vol 14.
6. **Ayala M (2008).** "Results of pterygium surgery using a biologic adhesive". *Cornea*,27:663-667.
7. **Kim HH, Mun HL, Park YJ, Lee KW, Shin JP (2008).** "Conjunctival limbal autograft using a fibrin adhesive in pterygium surgery". *Korean J Ophthalmol.*,22:147-154.
8. **Koranyi G, Seregard S, Kopp ED (2004).** "Cut and paste: a no suture, small incision approach to pterygium surgery". *Br J Ophthalmol.* ,88:911-914.
9. **Koranyi G, Seregard S, Kopp ED (2005).** "The cut-and-paste method for primary pterygium surgery: long-term follow-up". *Acta Ophthalmologica Scandinavica*,83:298-301.
10. **Tan D (1999).** "Conjunctival grafting for ocular surface disease". *Curr Opin Ophthalmol.*,10:277-281.
11. **Dorfman HS, Kennedy JE, Bird WC (1982).** "Longitudinal evaluation of free autogenous gingival grafts. A four year report". *J Periodontol.* ,53:349-352.
12. **Suresh KP (2011).** "An overview of randomization techniques: an unbiased assessment of outcome in clinical research". *J Hum Reprod Sci.*,4(1):8-11.
13. **Mackenzie FD, Hirst LK, Kynaston B (2003).** "Recurrence rate and complications of 5-Fluorouracil as chemoadjuvant for primary pterygium surgery: preliminary report". *Cornea* ,22:522-526.
14. **Akarsu C, Taner P, Ergin A (2003).** "5-Fluorouracil as chemoadjuvant for primary pterygium surgery: preliminary report". *Cornea* ,22:522-526.
15. **Dadeya S, Kamlesh S, Khurana C (2003).** "Intraoperative daunorubicin versus conjunctival autograft in primary pterygium surgery". *Cornea* ,22:763-770.
16. **Chapman-Smith JS (1992).** "Pterygium treatment with triethylenethiophosphoramide". *Aust N Z J Ophthalmol.* ,20:129-131.
17. **Cheng HC, Tseng SH, Kao PL, Chen FK (2001).** "Low-dose intraoperative mitomycin -C as chemoadjuvant for pterygium excision". *Cornea* ,20:24-29.

18. *Donaldson KE, Alfonso EC(2003)*. "Recent advances in pterygium excision". *ContempOphthalmol.* ,2:1–8.

19. *HirstLW(2003)*. "The treatment of pterygium". *SurvOphthalmol.* ,48:145–180.

20. *Nishimura Y, Nakai A, YoshimasuT(2000)*. "Long-term results of fractionated strontium-90 radiation therapy for pterygia". *Int J RadiatOncolBiolPhys.* ,46:137–141.

21. *Wong AK, Rao SK, Leung AT, Poon AS, Lam DS(2000)*. "Inferior limbal-conjunctivalautograft transplantation for recurrent pterygium". *Indian J Ophthalmol.* ,48:21–24.

22. *Ma DH, See LC, Liao SB, Tsai RJ(2000)*. "Amniotic membrane graft for primary pterygium: comparison with conjunctivalautograft and topical mytomycin C treatment". *Br J Ophthalmol.* ,84:973–97.

23. *Foroutan A, Beigzadeh F, Ghaempanah MJ, Eshghi P, Amirizadeh N, Sianati H(2011)*. "Efficacy of autologous fibrin glue for primary pterygium surgery with conjunctivalautograft". *Iranian J Ophthalmol.* ,23:39–47.

24. *Oswald AM, Joly LM, Gury C, Disdet M, Leduc V, KannyG(2003)*. "Fatal intraoperative anaphylaxis related to aprotinin after local application of fibrin glue". *Anesthesiology* ,99:762–763.

25. *Wit D, Athanasiadis I, Sharma A, Moore J(2010)*. "Sutureless and glue free conjunctivalautograft in pterygium surgery: a case series". *Eye*,24:1474–1477.

26. *Massaoutis P, Khemka S, AyliffeW(2006)*. "Clinical outcome study of a modified surgical technique for pterygium excision". *Can J Ophthalmol.*,41:704–708.

27. *Malik KP, Goel R, Gupta SK, Kamal S, Malik VK, Singh S(2012)*. "Efficacy of sutureless and glue free limbalconjunctivalautograft for primary pterygium surgery". *Nepal J Ophthalmol.*,4(8):230–235.

28. *Uy HS, Reyes JM, Flores JD, Lim-Bon-SiongR(2005)*. "Comparison of fibrin glue and sutures for attaching conjunctivalautografts after pterygium excision". *Ophthalmology*,112:667–671.

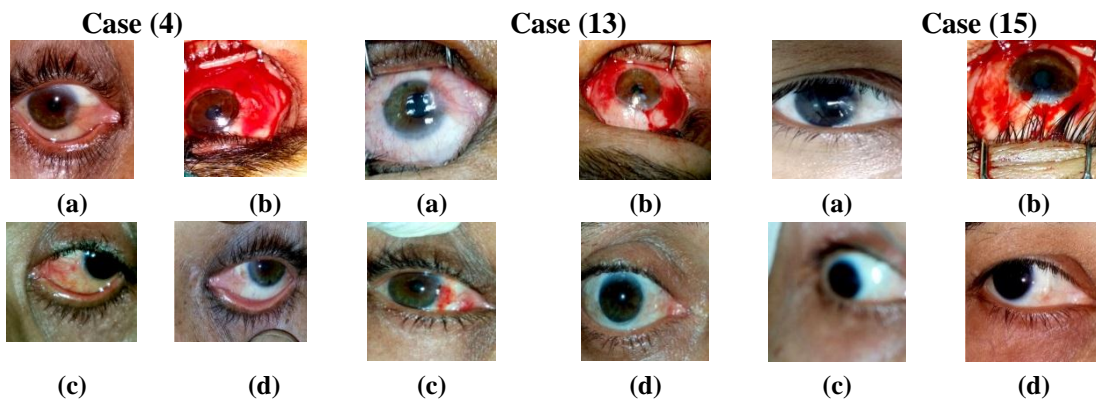
29. *Srinivasan S, Slomovic AR(2007)*. "Eye rubbing causing conjunctival graft dehiscence following pterygium surgery with fibrin glue". *Eye*,21:865–867.

Table (1): Pre-operative data, operative and post-operative outcomes

	No.	%
No. of eyes	20	100%
Gender		
• Male	12	70.6%
• Female	5	29.4%
Age		
• Mean ± SD	52.50 ± 18.31 years	
• Range	30-75 years	
Mean follow up ± SD – Range	9.2 + 1.6 months (Range: 7-12 months)	
Operative time		
• Mean ±SD	25.00 ± 1.41 minutes	
• Range	24-26 minutes	
Graft size		
• Mean ±SD	Horizontal: 6.4±1.1 mm Vertical: 5.8±0.8 mm	
• Range	Horizontal: 5-8 mm Vertical 4-7 mm	
Location		
• Nasal primary pterygia	20	100%
Cosmetic outcome		
• Good	20	100%
Duration of graft fixation		
• Mean ±SD	11.5±1.82 minutes	
• Range	9-14 minutes	
OD/	11	55%
OS	9	45%

Table (2): Post operative complications

	No.	%
Complications		
• Postoperative pain	0	0%
• Graft dislocation	0	0%
• Graft retraction	2	10%
• Recurrence	0	0%
• Conjunctival edema	1	5%
• Faint corneal nebula	1	5%
• Conjunctival granuloma	0	0%
• Graft necrosis	0	0%
• Scleral necrosis	0	0%
• Scleral thinning	0	0%



(a) Preoperative nasal pterygium
 (b) Intraoperative conjunctival graft adhesion
 (c) One week postoperative
 (d) Two weeks postoperative

(a) Preoperative nasal pterygium
 (b) Intraoperative conjunctival graft adhesion
 (c) One week postoperative
 (d) Ten months postoperative

(a) Preoperative nasal pterygium
 (b) Intraoperative conjunctival graft adhesion
 (c) Three months postoperative
 (d) Six months postoperative