

## EFFECT OF STATINS ON THE PERIODONTAL LIGAMENT OF INDUCED DIABETIC RATS

Yasser Abd-Elraouf Mohamed<sup>1</sup>, Rasha Mohamed Taha<sup>2</sup>, Laila Sadek Ghali<sup>3</sup>

DOI: 10.21608/dsu.2021.21285.1024

Manuscript ID: DSU-2002-1024 (R5)

### KEYWORDS

Diabetes, Periodontal ligament, Statins, Streptozotocin.

### ABSTRACT

**Introduction:** Considering the Diabetes mellitus (DM) as one of the oldest conditions characterized in humans, it has been recognized since antiquity and considered as a major health problem at present. There is a need for efficient treatment. **Aim:** The aim of the present investigation was to find out whether statins can alleviate the well documented side effects of Streptozotocin induced diabetes mellitus on the periodontal ligament of adult male Albino rats. **Material and Methods:** Sixty adult male albino rats with body weight ranging from 180-200gr were used in this investigation. They were divided into the following groups. Group 1: consisted of 20 animals and served as controls. Group 2: consisted of 20 animals, they were subjected to a single intraperitoneal injection of streptozotocin in a dose 60 mg/kg body weight of for induction of diabetes mellitus. Group 3: consisted of 20 animals. They were subjected to induction of diabetes mellitus in the same way as group 2 animals. One week later, the animals were treated with simvastatin in a daily intraperitoneal dose of 5mg/kg body weight. At the end of the experiment the animals were sacrificed by cervical dislocation, their Jaws were dissected out then processed for the histological and transmission electron microscopic examinations. **Results:** The present work showed that the treatment of diabetic rats with statins resulted in amelioration of the degenerative effect of diabetes on the periodontal ligament when compared with. Changes of diabetes in group 2 and regenerative changes of statins in group 3 compared to the control group 1. **Conclusion:** Diabetic albino rats treated with statins revealed partial improvements, mostly in the arrangement of the fibers of periodontal ligament.

### INTRODUCTION

Diabetes Mellitus (DM) is a genuine condition influencing all age bunches worldwide and is related with testing difficulties. The effect of diabetes is felt in created nations and Egyptian prevalence of diabetes is 6% <sup>(1)</sup>.

Diabetes mellitus is a metabolic disease portrayed by the nearness of hyperglycemia because of a decrease in insulin emission, activity or both which if not appropriately controlled can prompt long haul spin-off of harm, brokenness and disappointment of different organs. The administration of diabetes with no symptoms is as yet a test to the medicinal framework. Dysglycemia is a subjective term used to

- E-mail address:  
Yasser\_biology\_dr@dent.svu.edu.eg
- 1. Assistant lecturer in Oral Biology Department, Faculty of Dentistry,
- 2. Assistant Professor of Oral Biology, Faculty of Dentistry, Suez Canal University, Ismailia, Egypt,
- 3. Professor of Oral Biology, Faculty of Oral and Dental Medicine, Cairo University.

portray blood glucose (BG) that is strange without characterizing a limit because of vulnerability about ideal BG ranges and the present understanding that even somewhat raised BG levels can cause significant problems<sup>(2)</sup>.

The fundamental types of diabetes mellitus incorporate type 1 and type 2. Type 1 diabetes or adolescent onset diabetes, in the past named Insulin Dependent Diabetes Mellitus (IDDM) might be either because of immune system or idiopathic causes<sup>(3)</sup>.

Type 1 diabetes is basically because of an immune system decimation of the pancreatic  $\beta$  cells through T-cell interceded fiery reaction (insulates) and in addition a humeral ( $\beta$  cell) response<sup>(4)</sup>.

This immune system type 1 diabetes is portrayed by the nonattendance of insulin discharge and is more prevailing in youngsters and teenagers. Notwithstanding the significance of hereditary inclination in type 1 diabetes, a few natural elements have been involved in the etiology of the disease<sup>(5)</sup>.

Late onset of type 1 diabetes may prompt debilitated bone development because of the nonappearance of the anabolic impacts of both insulin and amylin which is more muddled in long-standing cases by the activity of vascular complications<sup>(6)</sup>.

Statins are the medical treatment of choice for reducing high cholesterol levels. They inhibit 3-hydroxy-3-methyl-glutaryl (HMG)-CoA reeducates the rate limiting step in cholesterol synthesis, which leads to up regulation of hepatic low-density lipoprotein (LDL) receptors and reduction in circulating LDL and very low-density lipoprotein (VLDL) levels<sup>(7)</sup>.

As of late, the extent of statins treatment has extended with the rise of confirmation proposing

that because of pleiotropic impacts of statins that are not specifically connected with their direction of cholesterol levels, they may end up being advantageous for treating various diseases<sup>(8)</sup>.

Stains no flagging and cell destiny choices, importantly statins likewise affect vascular and resistant capacities by means of adjusted no flagging prompting enhanced vascular capacity, hindrance of leukocyte chemo taxis, and down regulation of leukocyte bond and movement at the vascular wall<sup>(9)</sup>.

Full-thickness wounds in streptozotocin-initiated diabetic rats treated with topical atorvastatin have fundamentally speedier injury mending rates in correlation with control groups<sup>(10)</sup>. It was found that the mean histopathologic and angiogenesis scores were fundamentally unique at day 14 amongst statin and control bunches. Rates of wound mending were observed to be essentially higher in the streptozotocin-initiated diabetic rats treated topically with atorvastatin contrasted and those treated with a blend of lanolin–vaseline and the untreated group<sup>(11)</sup>.

In the present work, it was worth shedding light on the possible modulatory effect of statins on the periodontal ligament of induced diabetic rats.

## MATERIAL AND METHODS

Sixty adult male albino rats with body weight ranging from 160-180 grams were used in this investigation. They were divided into the following groups: -

**Group 1:** Consisted of 20 animals and served as controls.

**Group 2:** Consisted of 20 animals, they were subjected to a single intraperitoneal injection of streptozotocin in a dose of 60mg/kg. body weight for induction of diabetes mellitus<sup>(12)</sup>.

**Group 3:** Consisted of 20 animals, they were subjected to induction of diabetes mellitus in the same way as in group 2.1 animals. One week later, the animals were treated with simvastatin in a daily intraperitoneal dose of 5mg/kg body weight <sup>(13)</sup>.

At the end of the experiment which lasted for 2 months, the animals of different groups were euthanized by cervical dislocation, their jaws were dissected out. Those of the right side were fixed in 10% neutral buffered formalin, decalcified in 10% EDTA solution for two months. The specimens were then washed properly under running water, dehydrated by transferring through ascending grades of alcohol, then transferred to xylene to clear the specimens from alcohol. The specimens were infiltrated with paraffin wax and embedded in the center of the paraffin wax blocks. The embedded specimens were sectioned 6 microns thick. The sections were mounted on clean glass slides and stained with:

- Hematoxylin and eosin stain for histological examination and detection of any structural changes in the arrangement of fibers.

#### - Preparation of specimens for T.E.M:

Small specimens of average size one cubic mm. were immediately cut from the periodontal ligament and alveolar bone of the decalcified jaws of the left side in the region of the molar areas and prepared for transmission electron microscope (TEM) examination as follows:

Specimens were rapidly fixed in 3% phosphate buffered glutaraldehyde (PH 7.2) for 1-2 hours (primary fixation), then washed in 3 changes of phosphate buffer (PH 7.2) 15 minutes each. Specimens were post fixed in 1% buffered Osmium tetroxide at 4°C for 1-2 hours and then washed thoroughly in the buffer.

Specimens were then dehydrated in ascending grades of ethanol.

Final dehydration and clearing were carried out in propylene oxide for 30 minutes.

Embedding was then carried out in oven-dried gelatin capsules using fresh epoxy resin and left to polymerize in an oven at 60°C for 24-36 hours. Semi thin sections (1-2 microns thick) were cut and stained with Toulidine blue for 45 seconds to be examined with light microscope for orientation and localization of the site to be examined by the electron microscope.

Ultrathin sections (0.06 microns) were cut using ultramicrotome and glass knives and then mounted on copper grids.

Staining was carried out with saturated uranyl acetate in 50% ethanol for 30 minutes, then washed for several times in distilled water followed by staining with lead citrate for 5 minutes.

Finally, examination was carried out using the T.E.M (JEOL 1000) in the cancer institute, Cairo University.

## RESULTS

### a. Hematoxylin and Eosin results:

**Group 1 (control group):** The periodontal ligament of the control rats was composed of cells, fibers, blood vessels & nerves. The collagen fibers which are the main components of the PDL. The gingival group of fibers attached to the cervical part of the cementum and extended to the free and attached gingiva, where they fuse with the fibrous tissue of the gingiva. The interdental or trans-septal group of fibers extending from the cementum of one tooth to the cementum of adjacent tooth crossing above the crest of the alveolar bone **Figure (1A, 1B).**

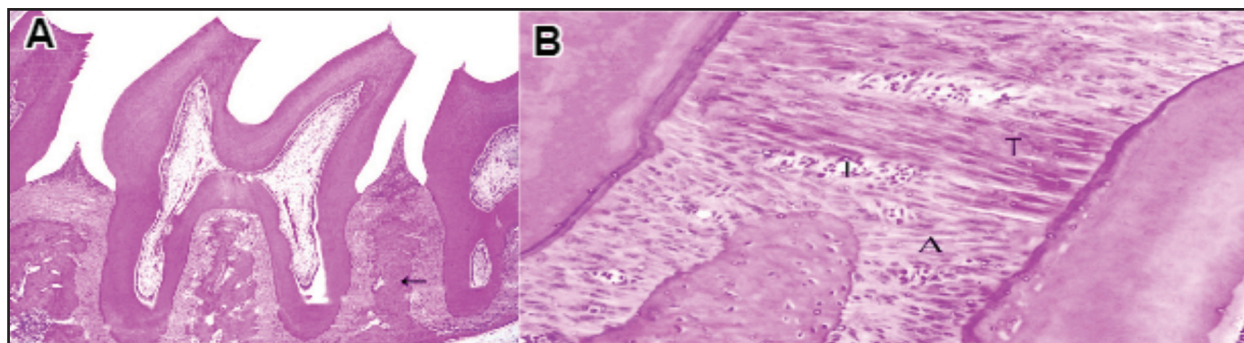


Fig. (1) **A.** A photomicrograph of the mandible of a control animal showing teeth with their investing structures which include the periodontal ligament and alveolar bone (arrow). **B.** normal transseptal (T) and alveolar crest group of fibers(A) with interstitial spaces between the bundles of fibers(I), notice the surfaces of bone and cementum are smooth with normal fiber attachment (H&E.orig.mag.A,100 B,400).

**Group2 (Diabetic Group):** Periodontal ligament of rats subjected to a single intraperitoneal injection of streptozotocin in a dose of 60mg. /kg body weight for induction of diabetes mellitus showed degenerative changes in the periodontal ligament in the form of disorientation, detachments and dissociation of the principle fibers, in addition to lots of Howship's lacuna and osteoclasts on the surface of the bone and widening of the marrow cavities **Figure (2A, 2B).**

### Group 3 (treated with simvastatin)

Periodontal ligaments of rats of Group 3 that were subjected to induction of diabetes mellitus in

the same way as in group 2 animals and treated with simvastatin, showed partial improvements, mostly in the arrangement and association of the fibers of PDL. Compared to diabetic group, the fibers mostly regained their arrangement and association together in bundles, as dissociation of fibers and disorientation were at minimum in this group of animals. Dilatation of the blood vessels was still observed, however in lesser degree compared to diabetic animals. A lot of empty Howship's lacunae were observed on the bone side, while on the root side cementum showed new cementoid tissue formation. There was minimal apical migration of the attachment epithelium **Figure (3A, 3B).**

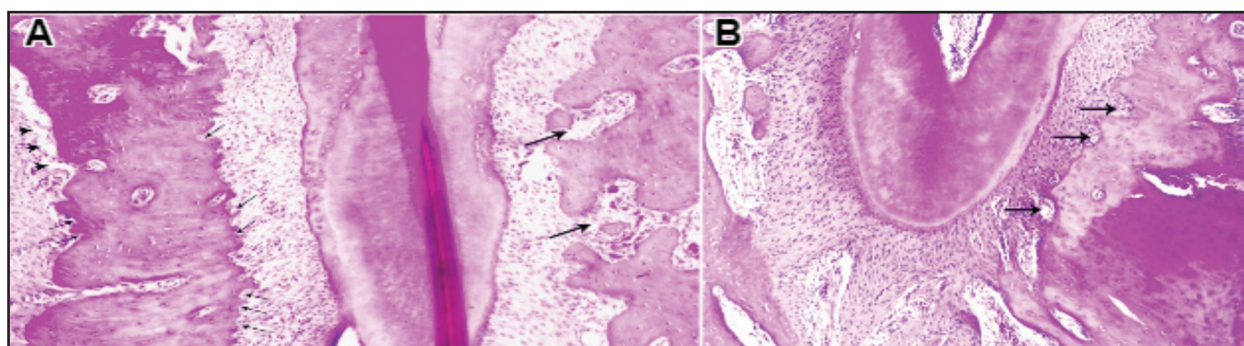


Fig. (2) **A.** A photomicrograph of PDL of diabetic animal in the area of oblique fibers showing marked dissociation of fibers with focal areas of detachment of fibers from the alveolar bone (arrows heads), a lot of Howship's lacunae (thin arrow) and widening of Zuckercandel & Hirschfeld canals (thick arrows), **B.** dissociation of fibers with presence of multiple Howship's lacuna (arrows), osteoclastic activity and infiltration of inflammatory cells (H&E.Orig.Mag.200).



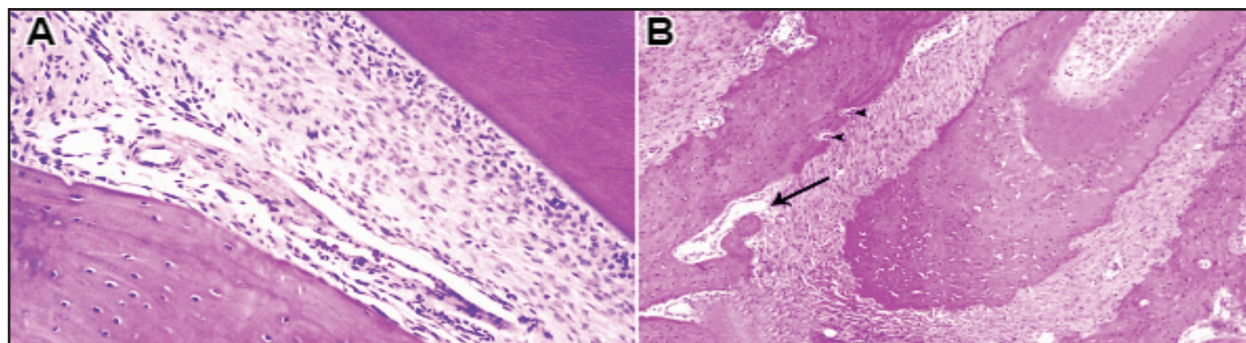


Fig. (3) **A.** A photo of PDL of a diabetic animal treated with simvastatin showing oblique fibers with partial regeneration, **B.** partial regeneration of oblique and apical fibers with minimum Howship's lacunae and osteoclasts on the bone side (arrow heads) and widening of Zuckercandel & Hirschfeld canals (arrow), (H& E., Orig. Mag. A 400, B 200).

#### b. Transmission Electron Microscopic Results:

##### *Group 1 (control group):*

The electron microscopic examination of the PDL of this group revealed the normal ultrastructure of the collagen bundles that were either cut longitudinally or transversely extending between the bone and cementum. According to the direction of section, the fibroblasts were either spindle, stellate or rounded in shape the fibroblasts were presented with large rounded or oval nuclei **Figure (4A, 4B).**

##### *Group2. (Diabetic Group):*

Electron microscopic examination of the PDL of this group ensured the histopathological findings where there were marked destruction and marked reduction in density of the collagen fibers leaving a lot of debris. The fibroblast cells showed definite signs of degeneration as they were markedly shrunken with pyknotic nuclei, degenerated organelles, vacuolated cytoplasm and fatty infiltration **Figure (5A, 5B).**

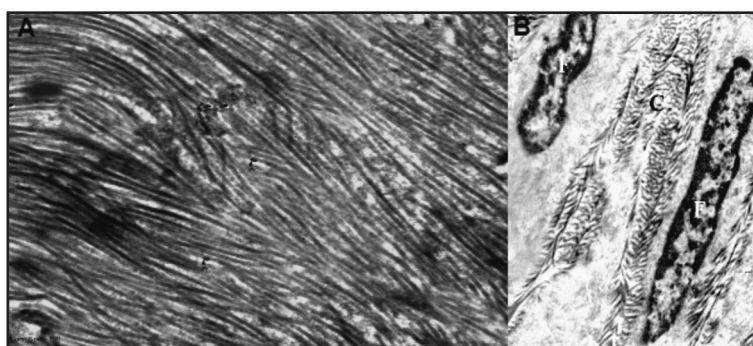


Fig. (4) **A.** An electron micrograph of the periodontal ligament of a control animal in the mid root area showing obliquely arranged collagen fibers, **B.** normal ultrastructure of the fibroblast (F) and collagen fiber bundles (C) that were cut longitudinally (Uranyl acetate & lead citrate A. x 5000, B. x 3000).

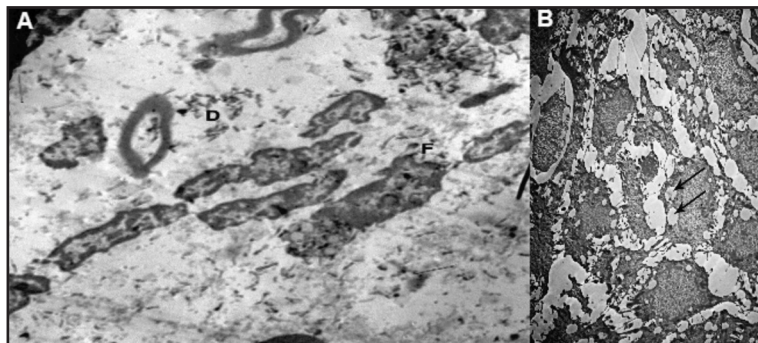


Fig. (5) **A.** An electron micrograph of the periodontal ligament of diabetic rats showing shrunken fibroblasts (F) among degenerated collagen fibers (D), **B.** degenerated fibroblasts, degenerated lymphocytes and fibroblast with a lot of cytoplasmic vacuolization (arrows) (uranyl acetate & lead citrate x 1000).

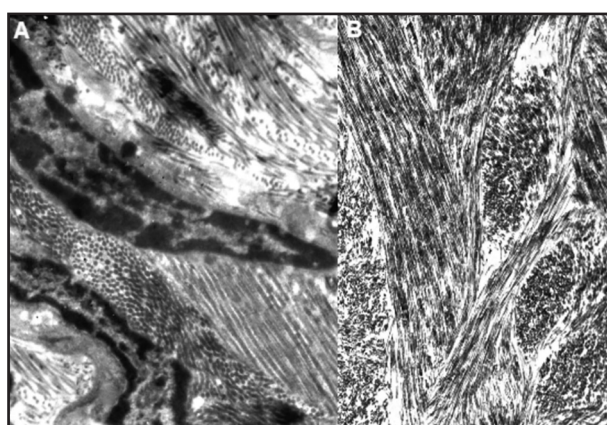


Fig. (6) **A.** A photomicrograph of PDL of simvastatin treated animal showing regenerative changes in the collagen fibers and fibroblasts, **B.** moderate regenerative changes in the fibroblasts and collagen fibers (Uranyl acetate & lead citrate x 5000).

### Group 3.1 (treated with simvastatin):

The electron microscopic examination of the PDL of this group showed regenerative changes in the fibrous and cellular elements **Figure (6A, 6B)**.

## DISCUSSION

In the present work, the periodontal ligament and was the tissue of choice for studying the link between oral and systematic health.

Streptozotocin (STZ) was the drug of choice in this study to induce diabetes as it had low mortality rate and high tolerance by the experimental animals than alloxan. Also, it can be given easily by different

routes and its diabetogenic action was rapid and permanent as it is known to destroy the beta cells of islets of Langerhans<sup>(15)</sup>.

It was reported that SMV at low concentration exhibits a positive effect on the proliferation and differentiation of human periodontal ligament (PDL) cells into osteoblasts by stimulating vascular endothelial growth factor (VEGF) released in a dose-dependent manner<sup>(16)</sup>.

By examining sections of group 3 that were treated with simvastatin, revealed partial improvements, mostly in the arrangement and association of the fibers of PDL. Compared to diabetic group, the fibers mostly regained their arrangement and association together in bundles, as dissociation of fibers and disorientation were at minimum in this group of animals.

It was reported that a great decrease in gingival index probing depth at sites treated with locally delivered SMV as compared to scaling and root planning (SRP) plus placebo in human subjects with chronic periodontitis<sup>(17)</sup>.

The same results were obtained by other researchers as they proved that SMV when applied systemically to rats (30mg/kg for 11 days) versus oral saline, SMV improved induced periodontal disease by demonstrating anti-inflammatory antioxidant activity as well as improving alveolar bone loss within all studied parameters<sup>(18)</sup>.

Another reason for the anti-inflammatory effect of statins could be due to the beneficial effects of statins which is mediated through the lowered LDL cholesterol levels, which has been suggested to have anti-inflammatory properties. It was found that hyperlipidemic patients are more prone to periodontal disease and statins have positive impact on periodontal health. SMV has been shown to inhibit the ability of macrophages to oxidize low-density lipoproteins (LDL) <sup>(19)</sup>.

Numerous studies have showed the protective effect of statins on periodontal infections. It was reported that patients on statin medication exhibited fewer signs of periodontal injury than subjects without statin regimen and showed the association of statin use with reduced tooth loss rate in chronic periodontitis patients. These findings indicate that statins might have beneficial effect not only in cardiovascular disease but also in periodontal disease <sup>(20)</sup>.

Diabetic patients are one of the gatherings that advantages most from statin treatment with respect to cardiovascular hazard. There is no persuading proof showing that statin treatment in diabetics may add to declining glycaemic control. Generally, the cardiovascular defensive advantages of statins exceed the worries related with danger of diabetes mellitus <sup>(21)</sup>.

There is confirmation to recommend that a few statins are conceivably diabetogenic, and the hazard has all the earmarks of being dosage related <sup>(22)</sup>. However, diabetic patients are one of the gatherings that advantages most from statin treatment with respect to cardiovascular hazard. There is no persuading proof showing that statin treatment in diabetics may add to declining glycaemic control. Generally, the cardiovascular defensive advantages of statins exceed the worries related with danger of diabetes mellitus <sup>(21)</sup>.

## CONCLUSION

Streptozotocin induced diabetes caused various histological and ultrastructural degenerative effects on the periodontal ligament. Diabetic albino rats treated with statins revealed that partial improvements, mostly in the arrangement and association of the fibers of PDL.

## REFERENCES

1. El Banna S, Fouad A. Prevalence of Pre-hypertension and Hypertension in a sample of Egyptian Adults and its Relation to Obesity. *Aust J Basic Appl Sci* 2012;6:481-489.
2. Inzucchi SE, Bergenstal RM, Buse JB. Management of hyperglycaemia in type 2 diabetes: a patient-centered approach. Position statement of the American Diabetes Association (ADA) and the European Association for the Study of Diabetes (EASD). *Diabetologia* 2012;55:1577-1596.
3. Molbak AG, Christau B, Marner B, Borch Johnsen K, Nerup J. Incidence of insulin dependent diabetes mellitus in age groups over 30 years in Denmark. *Diabet Med* 1994;11:650-655.
4. Devendra D, Liu E, Eisenbarth GS. Type 1 diabetes: recent developments. *Bmj* 2004;328:750-754.
5. Canivell S, Gomis R. Diagnosis and classification of autoimmune diabetes mellitus. *Autoimmun Rev* 2014; 13:403-407.
6. Hofbauer LC, Brueck CC, Singh SK, Dobnig H. Osteoporosis in patients with diabetes mellitus. *J Bone Miner Res* 2007;22:1317-1328.
7. Mills EJ, Wu P, Chong G. Efficacy and safety of statin treatment for cardiovascular disease: a network meta-analysis of 170 255 patients from 76 randomized trials. *Qjm* 2010;hcq165.
8. Kavalipati N, Shah J, Ramakrishan A, Vasawala H. Pleiotropic effects of statins. *Indi J Endocrinol Metab* 2015;19:554.
9. Kubatka P, Kruzliak P, Rotrekl V, Jelinkova S, Mladosevicova B. Statins in oncological research: from experimental studies to clinical practice. *Crit Rev Oncol Hematol* 2014;92:296-311.

10. Toker S, Gulcan E, Caycı MK, Olgun EG, Erbilien E, Ozay Y. Topical atorvastatin in the treatment of diabetic wounds. *Am J Med Sci* 2009;338:201-204.
11. Mahajan VK. Psoriasis treatment: Unconventional and non-standard modalities in the era of biologics. *World J Dermatol.* 2016;5:17-51.
12. Fahim MA, Hasan MY, Alshuaib WB. Cadmium modulates diabetes-induced alterations in murine neuromuscular junction. *Endocr Res* 2000; 26: 205-217.
13. Bitto A, Minutoli A, Altavilla D, Polito F, Fiumara T, Marini H and Galeano M. Simvastatin enhances VEGF production and ameliorates impaired wound healing in experimental diabetes. *pharmacol. Res* 2008;57:159-169.
14. El Banna S, Fouad A. Prevalence of Pre-hypertension and Hypertension in a sample of Egyptian Adults and its Relation to Obesity. *Aust J Basic Appl Sci* 2012;6:481-489.
15. Anderson LC. Salivary gland structure and function in experimental diabetes. *Biomed Rev* 1998; 9: 107-119.
16. Caterina F and Giorgia B. The use of subgingivally delivered simvastatin in the treatment of chronic periodontitis. *J Clin Period* 2014; 45: 275 – 310.
17. Pradeep AR, Thorat MS. Clinical effect of subgingivally delivered simvastatin in the treatment of patients with chronic periodontitis: A randomized clinical trial. *J period* 2010; 81:214-222.
18. Roberta D, Adriana MA, Otacilio B, Reinaldo B, Mariana V, Ronaldo A, Gerly A. Protective mechanism of simvastatin in experimental periodontal disease. *J period* 2013; 8:1145-1157.
19. Bonetti P, Lerman L, Napoli C, Lerman A. Statin effects beyond lipid lowering—are they clinically relevant?. *Europ Heart J* 2013; 24: 225 – 248.
20. Snophia S, Satya N, Jayakumar P, Uma S, Pramod V. Evaluation of anti-inflammatory effect of statins in chronic periodontitis. *Indian J Pharmacol* 2013; 45: 391–394.
21. Castro MR, Simon G, Cha SS, Yawn BP, Melton III LJ, Caraballo PJ. Statin use, diabetes incidence and overall mortality in normoglycemic and impaired fasting glucose patients. *J Gen Intern Med* 2016; 31:502-508.
22. Navarese EP, Buffon A, Andreotti F. Meta-analysis of impact of different types and doses of statins on new-onset diabetes mellitus. *Am J Cardiol* 2013;111:1123-1130.