

EFFECT OF DIFFERENT LOCATOR HEIGHTS ON PERI-IMPLANT BONE CHANGES IN MANDIBULAR IMPLANT RETAINED OVERDENTURE

Helmy Hassan Abd El Hafiz¹, Moataz Mostafa Bahgat Elmahdy²,
Sayed Mohamed Mohamed Elmasry³, Hala Mohamed Abd Alhameed⁴

DOI: 10.21608/dsu.2021.45417.1049

Manuscript ID: DSU-2010-1049 (R1)

KEYWORDS

Bone density,
Implants, Marginal bone,
Locator height.

- E-mail address:
dr_helmy_hassan@yahoo.com.
- 1. Postgraduate Student in Department of Prosthodontics, Faculty of Dentistry, Suez Canal University, Egypt
- 2. Professor of Prosthodontics, Faculty of Dentistry, Suez Canal University, Egypt
- 3. Professor of Prosthodontics, Faculty of Dentistry, Suez Canal University, Egypt
- 4. Assistant professor of Prosthodontics, Faculty of Dentistry, Suez Canal University, Egypt .

ABSTRACT

Introduction: The implant supported overdentures offered better chewing and masticatory functions. Locator attachment has more advantages than other attachment types. **Aim:** The aim of the study was to compare radio-graphically the effect of implant locator's height on peri-implant bone height and density in mandibular over-denture. **Patients and method:** Twelve completely edentulous male patients had received conventional complete maxillary dentures and mandibular overdenture that retained by two implants that were inserted in the canine region by the help of CAD/CAM based surgical guides. The patients were divided randomly into two groups. Group I: the patients were received locator abutment with 1mm in height. Group II: the patients were received locator abutment with 3mm in height, a series of cone beam radiographs were taken at 0, 6, 12 and 18 months starting from the first day of lower over denture installation, peri-implant bone changes regarding height and density were estimated. **Results:** It was found that the mean marginal bone loss measurements were relatively higher for group I than group II with non-statistical significant difference. The average difference in bone density measurements around the implants for both groups showing initial increase followed by marked decrease through the follow up periods. **Conclusion:** locator height has an effect on peri-implant bone height, bone density.

INTRODUCTION

The necessity of improving denture retention and stability is directly proportional with severely resorbed mandibles. The implant supported over dentures offered a treatment alternative; it provides better chewing, masticatory performance, less complaints and higher satisfaction when compared with conventional complete denture treatment. Many attachments have been used to retain implant supported over dentures including bars, magnets, studs and telescopes^(1,2).

The locator attachment has been widely and successfully used to support over dentures, this attachment is self-aligning, has dual retention and is available in different colors with different retention values; in addition, repair and replacement are quick and straight forward⁽³⁾.

The literature supports the use of Cone Beam Computerized Tomography (CBCT) in dental implant treatment planning particularly

in regards to linear measurements, three-dimensional evaluation of alveolar ridge topography, proximity to vital anatomical structures, and fabrication of surgical guides ⁽⁴⁾.

From this point the present study aimed to estimate radio graphically the changes in height and density for the supporting bone around dental implant whenever using implant locators of different length to retain implant supported mandibular overdentures .

PATIENTS AND METHODS

Patient's Inclusion and exclusion criteria

Twelve male patients, ranged between 50-65 years old had completely edentulous maxillary and mandibular ridges. All patients were selected with skeletal Angles class I maxillary-mandibular relation, with available inter arch space suitable for over-denture prosthetic treatment and Patients were free from any temporomandibular joint disorders. All patients were free from any systemic diseases, as insulin controlled diabetes, renal or liver disease, chemotherapy osteoporosis and impaired psychological condition were excluded.

The patients who were smoking, with history of poor oral hygiene, bad habits e.g. severe clenching, bruxism, alcohol or drug abuse were excluded.

The selected patients were informed with the nature of the research work through the detailed consent.

Preoperative radiographic examination: to evaluate bone of the edentulous mandibular ridge and to detect any pathological lesion and available bone for implant placement. At the start of the study all patients were received conventional complete dentures.

Construction of CAD/CAM base surgical guide:

Duplication of lower denture for each patient was done using silicon putty consistency in a duplicating flask. Radiopaque acrylic resin is prepared by mixing auto polymerizing acrylic resin with barium sulfate at a ratio of 3:1.

A preoperative Cone Beam Computerized Tomography (CBCT) scan was taken for the patient's maxillary and mandibular arches with the scan appliance and interocclusal bite index in their position in the patient's mouth with CBCT machine. Optical scanning of the cast was done instead of second CBCT producing a stereolithography (STL) file which can be easily merged into the planning software, then the models with the radiographic template were scanned again using the same optical scanner. The STL of the second scan can be used in planning and more importantly in fabricating a more accurate fitting surgical guide ^(5,6).

Both scans were imported to the blue sky plane 3 software and were used together with the preoperative CBCT to plan the optimal implant position. Two Implants were placed in sufficient bone locations guided by the radiolucent channels in the scan appliance at place of canine area. The two implants were planned parallel to each other. The final virtual surgical guide was then exported as STL file and then was processed from poly-amide material with special software at the rapid prototyping unit of the "Central Metallurgical Research and Developing Institute " (CMRDI) unit. Metallic sleeves were then fitted into the planned holes of the fabricated stent ^(7,8).

Flapless surgical steps: the surgical guide was firmly fixed to the underlying mucosa and bone by bite index and three fixation screws in a tripod position. After removal of the silicone bite, the fitness and adaptability of the surgical stent were checked.

The surgery was performed with simple guide surgical kit (Dentis co ,Seol, South Korea) using three successive drills (pilot, 2.2 and 2.8) but final drill without surgical stent. The implant was then carried by its fixture mount and inserted manually in the prepared osteotomy site, further tightening using a ratchet was continued until reaching the required depth.

Locator pickup

After 3 months confirming implant Osseointegration, insertion of locator attachments with different heights (Dentis co ,Seol, South Korea) by direct pick up technique for the lower complete denture done for all patients sharing in this study, then the patients divided into two equal groups according to the height of the locator attachment:

Group 1: the patients of this group were received locator abutment with 1mm in height.

Group II: the patients were received locator abutment with 3mm in height.

Radiographic Evaluation:

A series of cone beam radiographs were taken at 0, 6, 12 and 18 months starting from the first day of lower over denture locator installation. Using the on demand 3D project viewer a vertical and horizontal lines were drawn as follow taken as a reference for measurement mesial and distal bone for each the implant to calibrate the alveolar bone height in the subsequent radiographs before measurements, fig (1) This calibration ensured the standardization of all radiographic images along the follow-up period. The alveolar bone on mesial and distal sides of the implant for each group was calculated as follow:-

1. **Average bone height** = (mesial bone height + distal bone height) for concerned implant / 2

Average bone height = (R+L)/ 2

The mean changes in the alveolar bone height throughout the follow up periods indicate the crystal bone loss around the implants.

These results were calculated, tabulated and statistically analyzed.

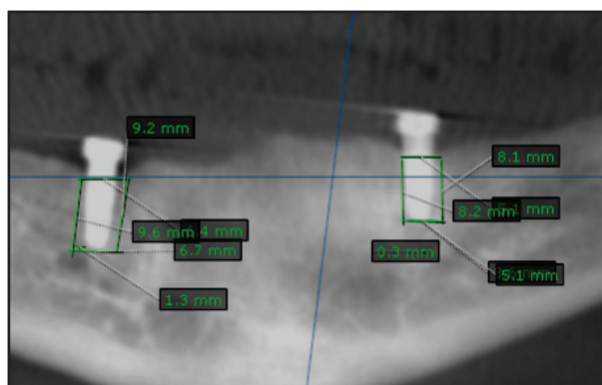


Fig. (1) Measurement of bone height changes in mesial and distal sides

2- Peri-implant bone density changes

Densitometric analysis was performed around dental implants on CBCT image in both groups by picking up implant in the software just wider and longer in diameter than actual implant and measuring bone density around implant by densitometric analysis in the on demand 3D project viewer software at 4 time intervals. Fig(2,3)

Statistical analysis

The obtained data at different observation periods were collected, tabulated and statistically analyzed using independent t-test) as means, \pm standard deviation (SD), P-value which is considered significant at $P \leq 0.05$ level and highly significant at ≤ 0.01 level.

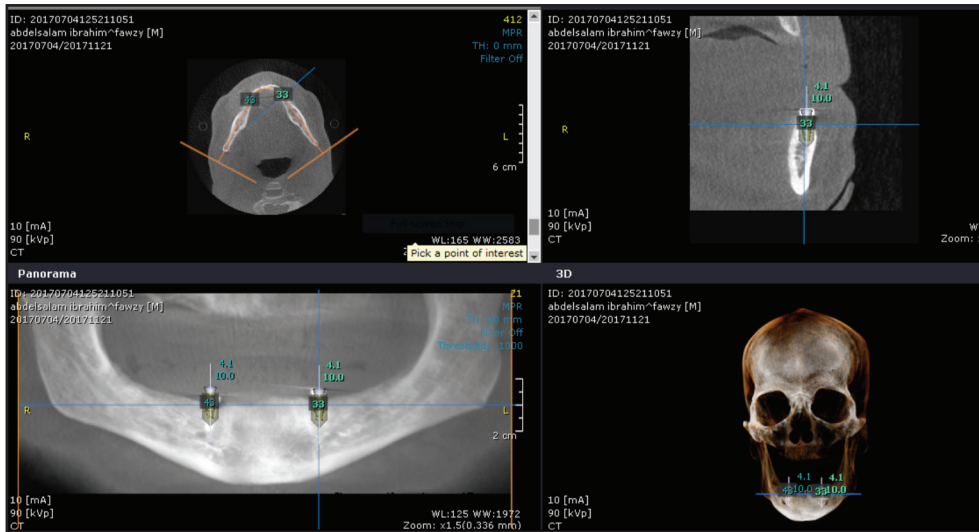


Fig. (2) Implant pick up for bone density measurements.

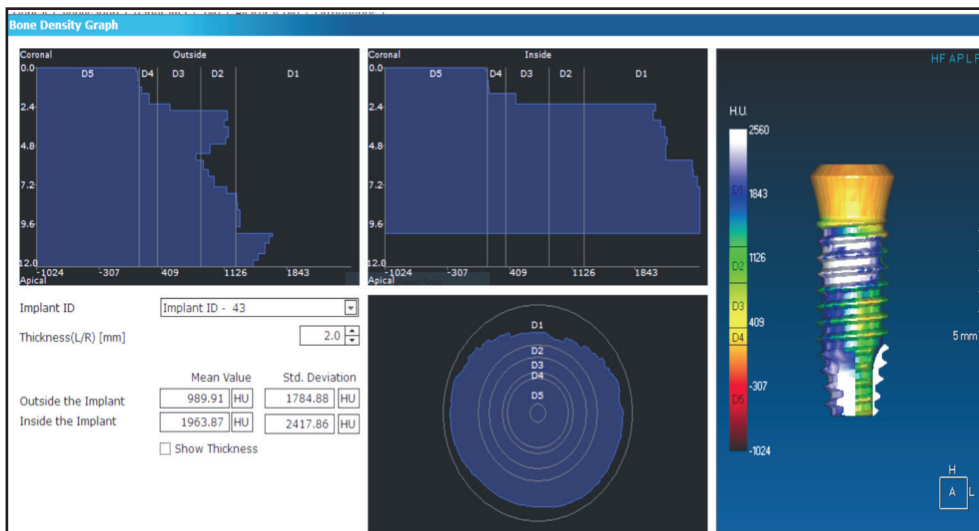


Fig. (2) Bone density measurements through on demand software.

Eta-square (η^2) estimates are used for overall comparison among studied groups, while **Cohen's d** estimates represent the effect size estimates between any two groups (repeated measurements).

For any PQAS item, effect size estimate (η^2 or d) close to 0.80 suggest a *large effect*, η^2 or d close to 0.50 suggest a *medium effect*, and η^2 or d of values ≤ 0.20 suggest a *small effect*. Moreover, effect size estimates (η^2 or d) greater than one suggests a *very large effect*.

RESULTS

Differences in marginal bone loss between the two groups at observation periods: As shown from table 1 comparing marginal bone loss between the two test groups, it was found that the mean marginal bone loss measurements were relatively higher for group I than group II with non-statistical significant difference at ($p > 0.05$) throughout all follow up periods, the Cohen's effect size estimates

that the marginal bone loss were higher in **G I** than **G II** at all follow up periods positive sign, except for 6-12 months negative sign, on average.

Differences in bone density around the implant between the two groups at observation periods:

From **Table 2** showing the average difference in bone density measurements around the implants for both groups showing initial increase in bone density measurements for both groups at the first

observation period followed by marked decrease in the measurements at the remaining observation periods especially in **G I** with non-statistical significant differences ($P > 0.05$) between the two groups along all follow up periods. Effect size estimate that the reduction is higher in **G I** than **G II**, this means that the effect sizes at all observations periods were positive except for 0-6 effect size were negative due to initial increase in average bone density which is higher in **GII** than **GI**.

Table (1) Means of marginal bone loss between the two groups at each observation period:

| Group \ Interval | Estimates | 0-6 month | 6-12 month | 12-18 month | 0-18 month |
|-------------------------------|-----------|-------------------------|-------------------------|------------------------|-----------------------|
| Marginal bone loss (Group I) | Mean± SD | 0.483± 0.117 | 0.047± 0.041 | 0.055± 0.040 | 0.585 ± 0.094 |
| | SE | 0.048 | 0.017 | 0.016 | 0.038 |
| Marginal bone loss (Group II) | Mean± SD | 0.443± 0.105 | 0.062± 0.039 | 0.030± 0.044 | 0.535 ± 0.108 |
| | SE | 0.043 | 0.016 | 0.018 | 0.044 |
| Independent t test (t) | | 0.623 ^{NS} | -0.649 ^{NS} | 1.028 ^{NS} | 0.855 ^{NS} |
| P value | | 0.547 | 0.531 | 0.328 | 0.413 |
| Effect size (d) estimate | | 0.360 | -0.375 | 0.593 | 0.493 |
| Effect size | | Small to medium (~ 0.5) | Small to medium (~ 0.5) | Medium (close to 0.50) | Medium (close to 0.5) |

Table (2) Means of Bone density between the two groups at each observation period:

| Group \ Interval | Estimates | 0-6 month | 6-12 month | 12-18 month | 0-18 month |
|--------------------------|-----------|----------------------|----------------------|----------------------|--------------------------|
| Bone density (Group I) | Mean± SD | -37.50± 32.12 | 42.83± 33.89 | 30.50± 14.84 | 35.83± 61.07 |
| | SE | 9.440 | 13.84 | 6.059 | 24.93 |
| Bone density (Group II) | Mean± SD | -42.33± 17.95 | 7.0± 38.38 | 24.83± 32.34 | -10.50± 68.47 |
| | SE | 7.328 | 15.66 | 13.20 | 27.95 |
| Independent t test (t) | | -0.404 ^{NS} | -1.714 ^{NS} | -0.390 ^{NS} | -1.237 ^{NS} |
| P value | | 0.694 | 0.117 | 0.705 | 0.244 |
| Effect size (d) estimate | | -0.233 | +0.990 | 0.225 | 0.714 |
| Effect size | | Small (~ 0.20) | Large (> 0.80) | Small (~ 0.20) | Medium to large (~ 0.80) |

NS = Non-significant ($P > 0.05$)

DISCUSSION

This study was conducted to evaluate the effect of implant locator of different heights on supporting structures in mandibular over-denture radio-graphically. The design of an overdenture attachment system should provide optimum force distribution around supporting implants to allow bone loading within physiological limits, transmit the occlusal forces in the direction of the long axes of the implant keeping the overdenture from dislodging from the patients mouth to be able to enjoy a normal, comfortable chewing function ⁽⁹⁾.

Bone density, bone height measurements were the radiographic monitored parameters used in this study, as they considered important evaluation in determining the prognosis of any prosthetic therapy as well as bone density measurements are an important parameter giving idea about the bone-load tolerance and the approximate level of tissue loading, to detect the effect of stresses transmitted by each attachment type and the subsequent bone resorption around implants ⁽¹⁰⁾.

CBCT was used to measure bone height because it is more precise than any other radiographic technique in measuring residual alveolar bone and peri-implants bone level changes, it allows three dimensional evaluation of the mandible providing very detailed images, with high contrast and resolution without overlapping ⁽¹¹⁾.

The period of 6 months could be sufficient for a measurable bone loss around implants, also the whole period of 18 months could be valuable to evaluate the acceptable bone loss around the implants ⁽¹²⁾.

The clinical results of this study revealed that the patients showed increase in marginal bone loss around the implant mesially and distally in both

groups which is more accentuated in the first 6 months after loading, which could be due to the trauma associated with surgical procedure, bone removal during drilling, detachment of the marginal periosteum, high bone remodeling rate during the stage of Osseo integration and future changes was happened after the implant subjected to functional loading of implant retained over denture. This is in agreement with the findings, that impair remodeling during the first 6 months after installation (the healing phase) can be a causative factor for initial bone loss to implants during the first year of function loading ⁽¹³⁾.

There was no statistically significant difference between GI, GII effects on the peri-implants bone resorption, this could be explained by the fact that, locator attachments of both height has dual retention and limited lateral movements of Locator male and female attachment parts due to pivoting action may be responsible for transferring less moment loads to the implants thus, difference in bone loss was not significant between the two levels of attachments ⁽¹⁴⁾.

Increased bone resorption in group I than group II can be explained by the two crown height considerations with implant retained overdentures. The first crown height space is the crown height of the attachment system to the crest of the bone, while the second crown height space is considered to be the distance from the top of the attachment to the occlusal plane. In the current study, the first crown height space was modeled in GI 1mm above gingiva and 3mm in GII, whereas the second crown height space was decreased 1 mm in GI and 3 mm in GII, respectively (i.e. second crown height is shorter by 2mm in GII than GI), this thereby increase magnitude of prosthetic force, thus increasing the lever arm, and it was concluded that the higher the

crown height distance, the more the forces applied to the implants. Increasing the crown height of an implant-supported prosthesis increases the risk of excessive occlusal overload because of an increased lever arm ⁽¹⁵⁾.

In this study initial increase in bone density measurements for both groups at the first observation period followed by marked decrease in the measurements at the remaining observation periods especially in **GI** with no significant differences which was attributed to several factors such as The alveolar bone surrounding the implant undergoes certain changes in the course of functional loading, which is known as bone remodeling, in which the bone responds positively to the applied loads by building additional support through the arrangement of its trabecular pattern and heavy lamina dura ⁽¹⁶⁾, but the following decrease due to increase effect of lateral forces in GI than GII (second crown height space) .This result proved that the density of alveolar bone controlled by the mechanical environment of strain, which is clearly observed in the reduction of bone density after tooth loss where the region is not loaded properly⁽¹⁷⁾

CONCLUSION

Within the limitations of this study, the following conclusions were drawn:

Increase locator heights decrease the lever arm with subsequent decreasing in the amount of the applied force. This intern has its great role in reduction of the amount of alveolar bone loss and bone density around implant supported overdenture.

Certain recommendations about the attachment height in terms of their effects on peri-implant bone cannot be drawn by two-heights only for further researches of other heights.

REFERENCES

1. Misch C E. Introduction in Dental implant prosthodontics: Part I . 2nd. Ed. El sevier Mosby Inc.2015:262-285.
2. Preoteasa E, Imre M , Lerner H . Narrow diameter and mini dental implant overdentures. Emerging trends in oral health sciences and dentistry. Editor: Mandeep S. V. 2015;11:241-264.
3. McCord J F. Risk mangement in clinical practice. Part 6a. Identifying and avoiding medico-legal risks in complete denture prosthetics. Br. Dent. J. 2010; 209: 273-276.
4. Neeria M, Rahul K T .Overdenture locator attachment for atrophic mandible.Clin Dent. 2013;4:509-511.
5. Cordaro L,Di-Torresanto V M , Petricivic N. Single unit attachments improve peri-implant soft tissue conditions in mandibular overdentures supported by four implants. Clin. Oral Implants Res. 2013; 24:536-542.
6. Mackie A, Lyons K, Thomson W M, Payne A G T. Mandibular two-implant overdentures: Three-year prosthodontic maintenance using the locator attachment system. Int J Prosthodont. 2011; 24: 328-331.
7. Kattadiyil M T, Parciak E , Puri S , Scherer M D. CAD/CAM guided surgery in implant dentistry: a brief review. Alpha Omega 2014; 107: 26–31
8. Mora M A, Chenin, D L , Arce, R M. Software tools and surgical guides in dental-implant-guided surgery. Dent clin N Am. 2014;58 :597–626.
9. Guedat C, Nagy U, Schimmel M. Clinical Performance of Locator attachment: A retrospective study with 1-8 years of follow- up .Clin Exp Dent Res.2018;4:132-145.
10. Machtei E, Oved-Peleg E, Peled M . Comparison of clinical, radiographic and immunological parameters of teeth and different dental implant platforms. Clin Oral Implants Research.2006;17: 658–665.
11. Orentlicher G , Horowitz A, Abbou M . Computer-guided implant surgery: indications and guidelines for implant use. Commend Contin Educ Dent. 2012; 23: 720-732.
12. Galindo-Moreno P , Nilsson P, King P ,Becktor J, Speroni S. Clinical and radiographic evaluation of early loaded narrow diameter implants-1- year follow- up. Clin Oral Implants Res. 2012; 23: 609-616.

13. Kleis W K, Kammerer P W, Hartmann S, Al-Nawas B, Wagner W. A comparison of three different attachment systems for mandibular two-implant overdentures: one-year report. *Clin implant dent relat res.*2010; 12:209–218.
14. Ma S , Tawse-Smith A , Thomson W M , Payne A G T. Marginal bone loss with mandibular two-implant overdentures using different loading protocols and attachment systems: 10 year outcomes. *Int. J. Prosthodont.* 2010; 4: 321-332.
15. Gallucci G O, Morton D , Weber H P. Loading protocols for dental implants in edentulous patients. *Int J Oral Maxillofac Implants.* 2009;24:132-146.
16. Yang S, Shin S, Kye S. Relationship between implant stability measured by resonance frequency analysis (RFA) and bone loss during early healing period. *Oral Surg Oral Med Oral Pathol Oral Radiol Endod.* 2008;105: 9-12.
17. Giro G, Goncalves D, Sakakura C E. Influence of estrogen deficiency and its treatment with alendronate and estrogen on bone density around osseointegrated implants: Radiographic study in female rats. *Oral Surg Oral Med Oral Pathol Oral Radiol Endod.* 2008; 105: 162-167.