

Image-Guided Insertion of Portacath Compared to Anatomical Landmark Blind Technique

MANAL I. GOMAA, M.D.¹; ASHRAF M.H. EL-SHERIF, M.D.²; ASHRAF H. IBRAHIM, M.D.³; AMIRA D. DARWISH, M.D.⁴; REDA H. TABASHY, M.D.⁵ and AHMED ADEL MOHSEN, M.D.⁶

*The Department of Diagnostic and Interventional Radiology, National Liver Institute, Menoufiya University*¹,
*The Department of Diagnostic Radiology, Faculty of Medicine, Minya University*², *The Departments of Surgical Oncology*³,
*Medical Oncology*⁴ *and Diagnostic & Interventional Radiology*⁵, *National Cancer Institute, Cairo University and*
*The Department of Diagnostic and Interventional Radiology, Faculty of Medicine, Aswan University*⁶, Egypt

Abstract

Background: Insertion of subcutaneous portacath is important in some cancer cases for whom chemotherapy is indicated. It is done either through image guided technique in Interventional Department or through blind technique in the Surgical Department.

Aim of Study: We aimed in our study to evaluate the complications and advantages of the two methods used for portacath insertion (image-guided insertion and anatomical landmark blind technique) and compare both to detect the better one should be used for the patients.

Patients and Methods: 110 adult cancer patients referred from the Medical Oncology Department outpatient clinics for subcutaneous port catheter insertion in the period from January 2019 to January 2020. 55 patients underwent image-guided insertion technique, while the other 55 patients underwent the anatomical landmark blind technique. Data were collected and analyzed. We compared the feasibility, advantages and complications of each technique.

Results: The results showed obvious decreased complications in image guided port catheter insertion compared to anatomical landmark blind technique in adult cancer patients indicated for chemotherapy.

Conclusion: Image guided portacath insertion is more safe than anatomical landmark blind insertion.

Key Words: *Blind insertion – Chemotherapy – Image guidance – Portacath.*

Introduction

OVER the last decades, many changes have occurred in oncology with new chemotherapy combinations and more complex application schemes becoming available. Central venous catheters and implantable venous port systems have become

widely used and have facilitated the problem of vascular access [1].

Central venous catheters are indispensable in current medical practice. They are used in infusion therapy purposes & hemodynamic monitoring. Any venous catheter whose tip lies in one of the great venous vessels is termed a central venous catheter, regardless of the insertion site [2].

Previously, chemoport insertions were done predominantly by surgeons who perform venous cutdown or use anatomic landmarks for entry site [3].

Image guided placement of lines and ports by interventional radiologist has increased dramatically over last decade and has advantage of precise positioning of the catheter tip and have less chance of complications [4].

The interventional radiologists use ultrasound guidance with the Seldinger technique for access site and fluoroscopy to check catheter placement.

Image-guided percutaneous chemoport insertion shows good success rates comparable to that done by surgeons. Its easier, safer, with less complications and little cost compared to surgical placement [3].

Although, the complications associated with portacath are rare, but may be severe and life-threatening. During implantation of the device, hemorrhage and pneumothorax may occur. Long-term complications include thrombosis of the central venous system, infection of the implanted material, extravasation of chemotherapeutic agents,

Correspondence to: Dr. Manal I. Gooma, [E-Mail: mibraheim3333@gmail.com](mailto:mibraheim3333@gmail.com)

rupture or dislocation of the catheter, and heparin-induced delayed hypersensitivity [5].

So we aimed in our study to evaluate the complications and advantages of image-guided insertion of portacath with the anatomical landmark blind technique.

Patients and Methods

A cross-sectional study was performed on 110 patients referred from the Medical Oncology Department outpatient clinics for subcutaneous portacath insertion.

Ethics: All study procedures were conducted in accordance with declaration of helsinki and were approved by the Ethical Committee.

Verbal consents were obtained from the patients.

Patients:

- Their ages range between 37 and 61 years old, with mean 47.5 years. All patients were females.
- The study was conducted from January 2019 to January 2020 at the National Cancer Institute.
- Fifty-five patients were referred to the Interventional Radiology Unit, and the other 55 patients were referred to the Surgical Oncology Department. The portacath insertion in all patients was indicated for chemotherapy treatment.

Inclusion criteria:

- Clear chest wall (free of infection).
- Normal complete blood picture.
- Average coagulation profile.
- Patent central venous system (Internal Jugular Vein (IJV), Subclavian Vein (SCV) and Superior Vena Cava (SVC)).

- No history of deep venous thrombosis or pulmonary embolism.

Exclusion criteria:

- Infection, fever, or chest wall scar.
- Anemia.
- Bad coagulation profile.
- Central venous system thrombosis (IJV, SCV or SVC).
- Positive history of deep venous thrombosis or pulmonary embolism.

All patients underwent the following:

- Good history taking.
- Chest examination and X-ray (if indicated).
- Complete blood picture.
- Coagulation profile.

Image-guided port catheter insertion:

- Patients' demographic data (age, sex, and diagnosis) were recorded.
- An experienced interventional radiologist performed all procedures in the well-sterilized angiography room.
- The patient was positioned in a neutral supine position on an operating table with head turned toward the left side.
- Under full operating aseptic conditions, the skin was prepared with 2% chlorhexidine in 70% isopropyl alcohol.
- The equipments used in portacath insertion are shown in Fig. (1A). Including Portacath set Fig. (1B).
- Local infiltration anesthesia.

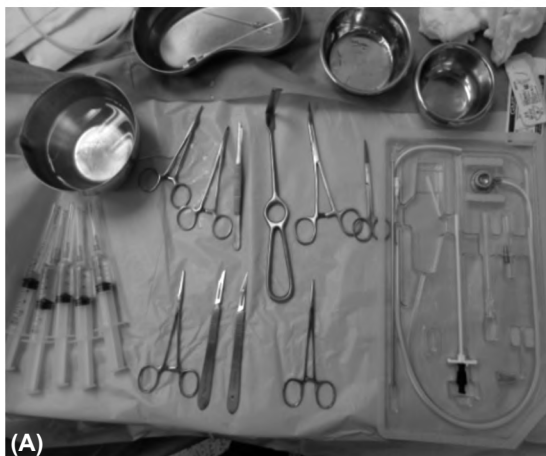


Fig. (1): (A) Equipments of the port insertion. (B) Port catheter set.

- Some patients were offered (intravenous) IV midazolam/fentanyl sedation to remove anxiety. Doppler evaluation to detect anatomical and pathological conditions influencing the choice of the vein, site, and any other potential difficulties before the procedure.
- Venous access detected under ultrasound guidance, puncture of the IJV. Vein puncture was ensured by free aspiration of a non-pulsatile blood Fig. (2).
- The guide wire was introduced through the introduction needle under the fluoroscopy, ensure the proper site of the guide wire is in the venous system.
- The introduction needle was withdrawn over the guide wire then the peel way sheath was introduced over the guide wire under fluoroscopic guidance to avoid venous transfixion.
- Port pocket creation: Mostly anterior to the second rib or in the second intercostal space.
- Subcutaneous catheter tunneling from the port pocket to the venous entry site.
- Estimation of the port catheter length to make the catheter tip position at the junction area between superior vena cava and the right atrium.

- Port catheter insertion, the port was stitched to the underlying fascia by non-absorbable stitches. Instillation of the pocket by antibiotic was done before closing the skin incision. Suturing of the neck and chest wall incision. Heparinization of the catheter was done. Then, dressing of the port and venous entry site.
- All steps of image-guided portacath insertion are seen in Fig. (3).

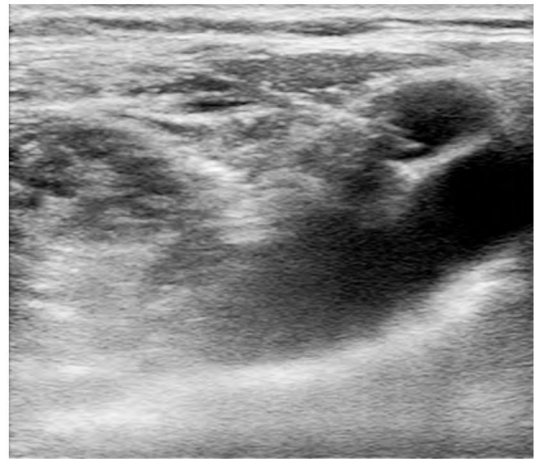

Fig. (2): Ultrasound guidance of the needle introduction to venous access, transverse view.

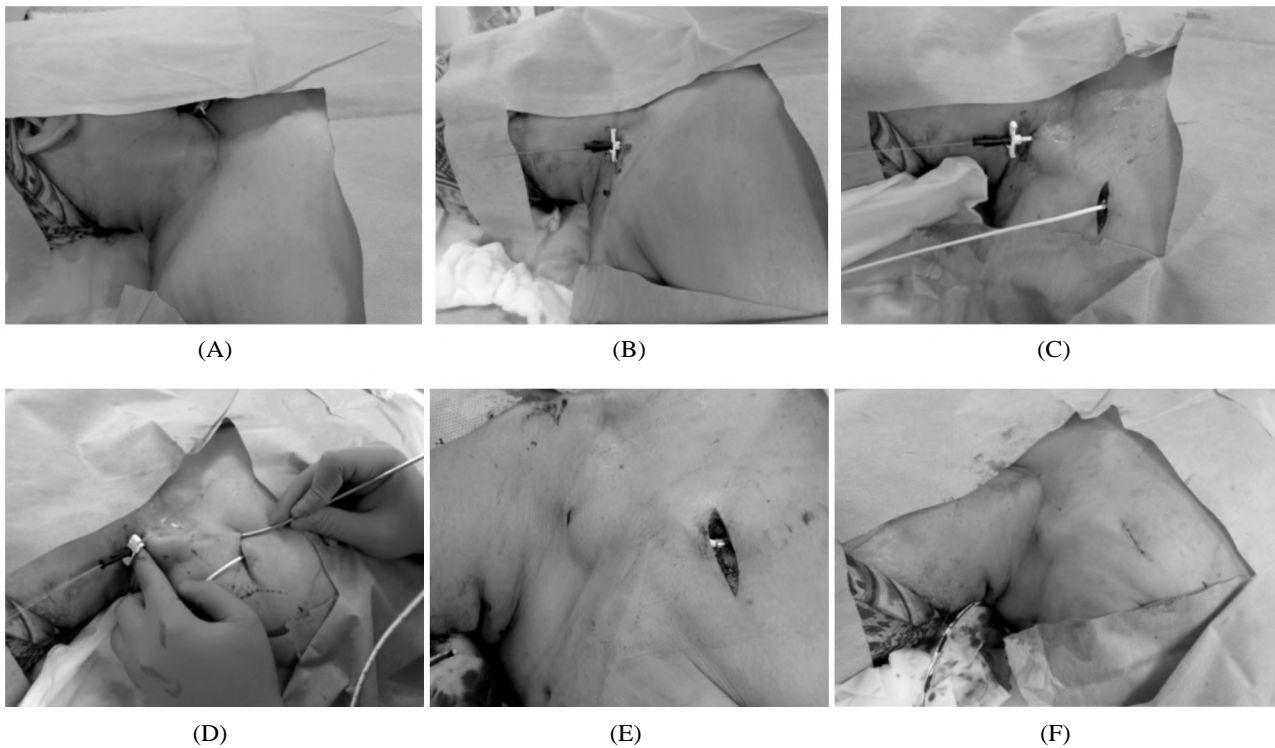


Fig. (3): (A) Skin preparation of the patient. (B) Introduction of the guide wire through the needle and peel way sheath over the guide wire after withdrawal of the introduction needle. (C) Transverse incision for the port and port implantation in its pocket. (D) Tunneling of the catheter in the subcutaneous tissue to protrude at the venous access site. (E) Port catheter insertion and removal of the peel way sheath. (F) Suturing of the neck and chest wall incision.

- *Immediate post -procedure evaluation:*

- All patients were followed-up by color Doppler ultrasound within 48 hours after the procedure.
- Chest radiography with the patient standing was routinely performed after the procedure and repeated the day after to assess the catheter position and to exclude presence of pneumothorax.

- *Follow-up:*

- The patients were followed-up for two weeks after the procedure for the evaluation of the port patency, catheter insertion related complications.
- After the close follow-up period of two weeks, port assessment was performed on request of the Medical Oncologist.

Surgical port catheter insertion:

- Localized skin sterilization.

- *Venous access:*

- The IJV is located between the clavicular heads of sternomastoid muscle. It was accessed the apex of the triangle the muscle heads make with the clavicle.

- The IJV was accessed by a saline-filled syringe with 18G needle to permit passage of a guide wire through it.

- The needle was directed at an angle of 45° to the skin surface, between the 2 heads of the sternomastoid muscle and pointing toward the ipsilateral nipple.

- Aspiration of blood with ease confirmed correct placement.

- Guide-wire was passed through the needle and the tip was positioned in the uppermost inferior vena cava.

- Fluoroscopy used to confirm the position of the guide wire tip.

- The needle withdrawn and the dilator sheath was introduced under fluoroscopy guidance.

- The dilator sheath was removed and the peel way sheath was introduced into the right atrium. The guide wire and trochar of the dilator sheath were removed.

- Port pocket creation.

- A 5cm incision was made at the midpoint of an imaginary line between the nipple and humeral head. An artery clip ensures dilatation for about 3-4cm into the incision, where the line cuff will rest.

- Local anesthesia was injected generously along the planned tunnel track, up to the neck puncture site.

- The tunneler was directed from the chest wall incision to complete the tunneling up to the neck puncture. The catheter tip was pulled from the chest wall incision into the neck puncture.

- Port catheter insertion.

Records of complications:

- Early complications such as: Malposition, hematoma, pneumothorax, bleeding, arterial injury, and venous injury.

- Late complications such as: Thrombotic complications (native venous or port-catheter thrombosis) and infections (tunnel/pocket infections or catheter-associated bloodstream infections).

- Pinch off syndrome.

Statistical analysis:

We assessed medical records, radiographs, operative findings, mean and standard deviation for numerical data and percentage (or numbers) for non-numerical data. Study the relationship between demographic data, original pathology and incidence of portacathe complications with its onset (early or late). Data was analyzed using SPSS program, version 19 from IBM company.

Results

The current study was prospective randomized study included 110 patients (108 females, 2 males) with age ranged from 30 to 65 years (median age was 47.5 years) (Table 1). All patients were referred from the Medical Oncology Department outpatient clinics for subcutaneous port catheter insertion in the period from January 2019 to January 2020.

Table (1): Age and sex distribution of 110 patients.

Group	Age	Sex		Total	%
		Male	Female		
• Image-guided insertion	30-65	0	55	55	50
• Anatomical landmark insertion	30-65	0	55	55	50

Group A included 55 patients who were referred to the Interventional Radiology Unit for image-guided port catheter insertion. Group B included the other 55 patients who were referred to the Surgical Oncology Department for anatomical landmark insertion. Analysis of the early and late complications in both methods was done & tabulated.

The Portacath insertion in all patients was indicated for chemotherapy treatment. The primary cancer was breast cancer in 107 patients (97.2%), cancer colon in 2 patients (1.8%) and non-Hodgkin lymphoma in one patient (0.9%).

The port catheter was inserted in the right internal jugular/subclavian vein for 95 patients (85.45%) and in the left internal/subclavian vein for 15 patients (13.63%) (Table 2).

Table (2): Distribution of the site of port insertion.

Group	Rt. side	Lt. side
Image-guided insertion	55 (55%)	0
Anatomical landmark insertion	40 (35.45%)	15 (13.63%)

The technical success rate success rate of the image-guided group A was compared with 21.81 % in the in the anatomical landmark group B. The high technical success rate of the image-guided insertion is attributed to the easy venous access by the ultrasound guidance and the well-controlled technique under fluoroscopic guidance (Table 3).

Table (3): Technical success rate difference between the two groups of port insertion.

Group	Image guided insertion	Anatomical landmark insertion
Success rate	52 patients (94.5%)	12 patients (21.81%)

The incidence of complications was 5.4% in the image-guided group A, which can be considered lower than that of the anatomical landmark group B 78.18% (Tables 4,5), Fig. (4) was a chart which clarify the nuber of complicated pateints in both groups of portacath insertion.

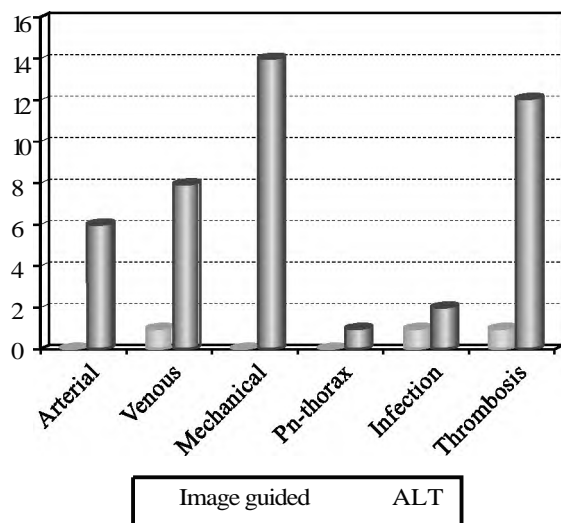


Fig. (4): Chart of complications in both groups of port insertion.

Table (4): Complications distribution among image-guided port insertion group with their prevalence.

Complications	No. of patients	Percentage
<i>Early complications:</i>		
Arterial injury	0	0
Venous injury	1	1.8
Mechanical	0	0
Pneumothorax/hemothorax	0	0
<i>Late complications:</i>		
Infection	1	1.8
Thrombosis	1	1.8
Total	3	5.4

Table (5): Complication distribution among anatomical landmark port insertion group with their prevalence.

Complications	No. of patients	Percentage
<i>Early complications:</i>		
Arterial injury	6	10.9
Venous injury	8	14.54
Mechanical	14	25.45
Pneumothorax/hemothorax	1	1.8
<i>Late complications:</i>		
Infection	2	10.9
Thrombosis	12	14.54
Total	43	78

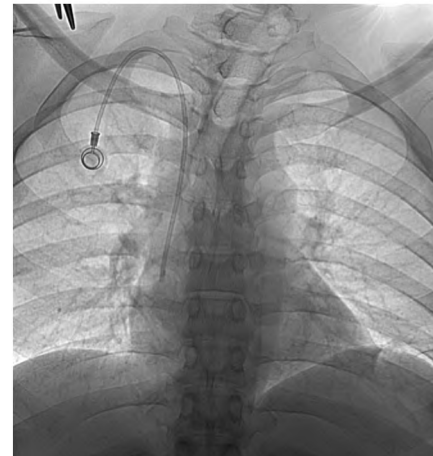

Fig. (5): Case (1) 40-years old male patient has cancer colon. Port cath insertion indicated for chemotherapy. The Port cath inserted by image guidance. The port is placed in the 2nd intercostal space with optimum angulation of the catheter and catheter tip position just at the right atrium.

According to the previous results, there is very low incidence of early and late complications (3 out of 55 patients, 5.45%) in image-guided port catheter insertion group A. So, revealing how important is the combined ultrasound and fluoroscopy techniques needed for portacath insertion.

The anatomical landmark technique group B shows high rate of early and late complications (43 out of 55 patients, 78.18%).

From (Table 6) we noted that, the mean of complications in group A was 0.5 while the mean of complications in group B was 7.1. The relative risk of complications of the two groups, which was the probability of having a complication in, a ratio between anatomical landmark group B to the image-guided group A is (14.3).

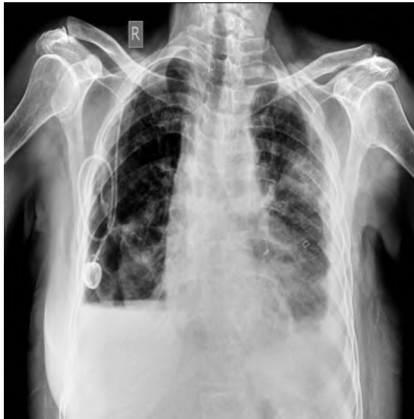

Fig. (6): Case (2) 57-years old female patient has breast cancer. Port cath insertion indicated for chemotherapy. The Port cath inserted by the anatomical landmark method. At the end of the procedure, there is right hemo-pneumothorax associated with partial right lung collapse. The port itself is seen lower down and the catheter is folded in the right lateral chest wall not entering.

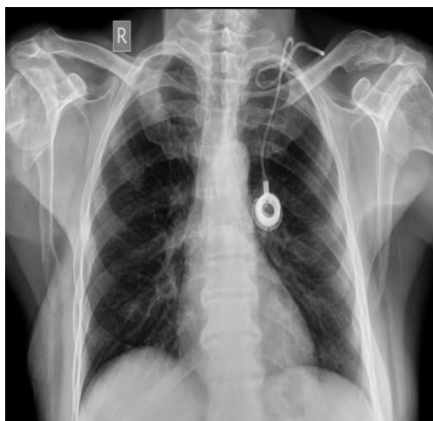

Fig. (7): Case (3) 54-years old female patient has breast cancer. Port cath insertion indicated for chemotherapy. The Port cath inserted by the anatomical landmark method. At the end of the procedure, the port itself is seen in more medial position in the chest wall and the catheter is folded in the left lower neck. After the first chemotherapy session, there was marked subcutaneous inflammation. And fluoroscopic image with contrast injection in the port revealed that the catheter tip is extravascular.

Table (6): Mean, SD, and SEM of the complications in the two groups of port insertion.

	Mean	SD*	SEM*
Image-guided insertion	0.5	0.54772	0.224
Anatomical landmark insertion	7.1	5.23132	2.136
Relative risk	14.3		

*SD : Standard Deviation.

SEM: Standard Error of the Mean.

Discussion

Placement of Central venous catheter (CVC) is the most common interventional procedures performed on the seriously ill patients. In oncology, it used for infusion therapy purposes & hemodynamic monitoring. Avoiding complications from CVC, placement is a subject of particular concern and interest in the ongoing era of quality and safety culture [6].

Several complications associated with such implantation include venous thrombosis, infection, catheter fracture, extravasations, and intravascular dislodgements. The incidence of complications is higher after cannulation of the Subclavian Vein (SCV) than after the Internal Jugular Vein (IJV) [7].

Ultrasound is increasingly used to guide venous access procedures because it has been shown to increase accuracy, safety, and patient comfort [8].

Placement of port catheters by guidance of ultrasound was expressed in 1990s for the first time, which caused entrance of needle into the vessel with high accuracy. It decreases the number of needling and decreases the complications. Different injections into any vein increase the risk for thrombus formation secondary to endothelial tissue damage during the procedure [9].

Due to lack of enough study comparing the complications rate of portacath implantation in two methods, [10] decided to assess the complications rate in two mentioned methods in a descriptive-comparative study in a three-year period (2006-2009), in order to have a strong base to suggest using ultrasound in Port-A-Cath implantation (as a reliable vascular access device) in oncologic patients.

In the current study, a comparison was made between two techniques of central venous port catheters placement, image-guided technique by combined (ultrasound and fluoroscopy) and anatomical landmark technique without guidance of radiology. The study is not just about technique feasibility, but also to show how different protocols (radiology and surgery) can affect management of such an important mean of diagnostic/therapeutic central catheters in recommended patients.

Rate of complications related to portacath is different from 5%-19% according to the method of portacath implantation [11].

Like our study, many studies found that the complications in image-guided portacath insertion

technique is less than the surgical blind one. For example Hemmati et al., Gebauer et al., Karakitsos et al., and Koroglu et al., [7,10,12,13].

In the study of Hemmati et al., portacath placement complications rate in both anatomic landmark and ultrasound guidance methods in breast cancer was more than other types of cancer (90% and 100%, respectively). After portacath placement, 2 catheters were non-functional just after placement (3.2%) in anatomical landmark method group; while all portacath placed in ultrasound-guided group were functional. Rate of success in anatomic landmark group was lower than second group, but this difference was not significant [61 (96.8%) vs. 41 (100%), ($p < 0.518$)].

Ten patients (15.9%) in the landmark group and 1 patient (2.4%) in US-guided group were complicated. The most common complication in both groups was pain [6 (9.5%) and 1 (2.4%), respectively]. The difference between complications rate in anatomic landmarks method and US-guided method was statistically significant ($p < 0.04$). No statistically significant difference was detected in types of complications between two groups. In patients whose port catheter was placed in left or right subclavian veins by anatomic landmark method, no complication was detected. Complication rate of port catheter placement in left and right jugular veins in anatomic landmarks group was 25% and 15.2%, respectively. In US-guided group, complication was only seen in patients whose portacath was inserted in left jugular vein. There was no significant difference in two groups in duration of port placement ($p < 0.345$), age ($p < 0.444$), site of port placement ($p < 0.244$) or type of malignancy ($p < 0.18$).

In a study by Gebauer et al., among 299 port catheters inserted with US-guidance, 298 cases of them were placed in jugular vein and 1 case was placed in subclavian vein. The rate of cannulation success was reported 99%. No main complication was occurred in these patients. Rate of infection, thrombus and migration were 0.15, 0.07 and 0.04 per 1000 catheter, respectively. In general, there were 23 complications (0.33 per 1000 catheter-days). Therefore, results of the study indicated that using US-guided method is effective in increasing the success rate and decreasing complications.

Cannulation of central vein by ultrasound guidance has many advantages in comparison to the anatomic landmark, as Tercan et al., study [14]. Many researchers explained that sonographic imaging just before the catheterization of central vein

makes selection of a proper vein possible for example Yip and Funaki study [15].

However, other studies found that there no significant difference in rate of complications between the two techniques, like Froehlich et al., [16] which was done on CVC children and the its results indicated no significant difference in success rate of cannulation with anatomic landmark (88.2%) in comparison with US-guided (90.8%), so US guidance did not improve success rates. However, they concluded that US guidance decreased the time to placement, increased the use of internal jugular catheter placement and decreased artery punctures, which all considered advantages for use of US guidance insertion.

Also Balls et al., [17] study which did not observe improved success with the use of ultrasound for CVC cannulation on the first attempt, but they observed reduced number of total punctures per attempt.

To achieve the “zero complication” option of CVC insertion, however, a change in CVC placement policy will be necessary. US guidance techniques have become the gold standard for catheterization of IJV. Compared to the classical landmark technique, the ultrasound (US) guided infra-clavicular cannulation permits puncturing more laterally, reducing not only pneumothorax, but also costoclavicular pinch-off complication [18]. An ideal alternative, can be the US supra-clavicular approach with a supraclavicular catheter tunnelization, which offers a good view of the needle and the vein, without any US shadow of the clavicle, and avoids catheter pinch [19].

Conclusion:

Central venous port catheters have become widely used and have facilitated the problem of vascular access. They are used for many purposes such as infusion therapy and hemodynamic monitoring. Since they are easy to be implanted under local anesthesia, they significantly improve the quality of life for oncologic patients with difficult intravenous access.

The current study results showed obvious increase incidence of technical complications directly with the anatomical landmark group without any guidance, while technical complications using image guidance were nearly nil revealing the significance of image-guided insertion of catheters safely which in turn help to remove suffering from those malignancy patients. Therefore, the study concluded that the ultrasound is increasingly used

to guide venous access procedures because of increasing accuracy, safety and patient comfort without any general anesthesia or surgical procedures.

Acknowledgements:

We acknowledge firstly, the patients whose accept using their data and clinical staff in surgical and Radiological Departments whose help in collection of the data.

References

- 1- J. PURKAYASTHA, D.A. TALUKDAR and D.H. KANIA: Chemo-port insertion without image guidance: Experience of a regional cancer centre of North-East India. *European Journal of Surgical Oncology*, 45 (8): 87-8, 2019.
- 2- T. SEO, M.G. SONG and J.S. KIM: Long-term clinical outcomes of the single-incision technique for implantation of implantable venous access ports via the axillary vein. *The Journal of Vascular Access*, 18 (4): 345-51, 2017.
- 3- YAACOB Y., NGUYEN D.V., MOHAMED Z., RALIB A. R., ZAKARIA R. and MUDA S.: Image-guided chemoport insertion by interventional radiologists: A single-center experience on periprocedural complications. *Indian J. Radiol. Imaging*, 23 (2): 121-5, 2013.
- 4- KUMER S. and SHRMA P.: Image Guided Central Venous Line and Port Insertion. *International Journal of Radiology & Radiation Therapy*, 4 (4), 2017.
- 5- SEOK J.P., KIM Y.J., CHO H.M., RYU H.Y., HWANG W.J. and SUNG T.Y.: A retrospective clinical study: Complications of totally implanted central venous access ports. *Korean J. Thorac. Cardiovasc. Surg.*, 47 (1): 26-31, 2014.
- 6- AL-JAHDALI H., KLAUS L. IRION, K.L. CAROLYN ALLEN, C. DANIEL MARAFIGA De GODOY D.M. and ALI NAWAZ KHAN A.N.: "Review Article: Imaging Review of Procedural and Periprocedural Complications of Central Venous Lines, Percutaneous Intrathoracic Drains, and Nasogastric Tubes." *Pulmonary Medicine*, Volume, Article ID 842138, 18 pages, 2012.
- 7- HEMMATI H., DELSHAD M.S.E. and BARZEGAR M. R.: Jandaghi AB., Najafi B., Asgary MR., Es-Haghi A.) "Ultrasound Guided Port-A-Cath Implantation." *Surgical Science*, (5): 159-63, 2014.
- 8- M. MICCINI, D. CASSINI, M. GREGORI, S. GAZZANELLI, S. CASSIBBA and D. BIACCHI: Ultrasound-guided placement of central venous port systems via the right internal jugular vein: Are chest X-ray and/or fluoroscopy needed to confirm the correct placement of the device?" *World Journal of Surgery*, 40 (10): 2353-8, 2016.
- 9- M. MICCINI, D. CASSINI, M. GREGORI, S. GAZZANELLI, S. CASSIBBA and D. BIACCHI: Ultrasound-guided placement of central venous port systems via the right internal jugular vein: Are chest X-ray and/or fluoroscopy needed to confirm the correct placement of the device?" *World Journal of Surgery*, 40 (10): 2353-8, 2016.
- 10- GEBAUER B., EL-SHEIK M., VOGT M. and WAGNER H.: Combined Ultrasound and Fluoroscopy Guided Port Catheter Implantation-High Success and Low Complication Rate." *European Journal of Radiology*, Vol. (69): 517-22, 2009.
- 11- KUSMINSKY R.E.: Complications of Central Venous Catheterization." *Journal of the American College of Surgeons*, 204: 681-96, 2007.
- 12- KARAKITSOS D.: Real-Time Ultrasound-Guided Catheterization of the Internal Jugular Vein: A Prospective-Comparison with the Landmark Technique in Critical Care Patients." *Critical Care*, 10 (6), 2006.
- 13- KOROGLU M.: "Percutaneous Placement of Central Venous Catheters: Comparing the Anatomical Landmark-Method with the Radiologically Guided Technique for Central Venous Catheterization through the Internal Jugular Vein in Emergent Hemodialysis Patients". *Acta Radiologica*, 47: 43-7, 2006.
- 14- TERCAN F., OZKAN U. and OGUZKURT L.: "US-Guided Placement of Central Vein Catheters in Patients with Disorders of Hemostasis." *European Journal of Radiology*, Vol. (65): 253-6, 2008.
- 15- YIP D. and FUNAKI B.: Subcutaneous Chest Ports via the Internal Jugular Vein. *Acta Radiologica*, Vol. 43: 371- 5, 2002.
- 16- FROEHLICH C.D, MARK R., ROSENBERG E.S., LI R., PEI-LING J.R., KIRK A.E. and STOCKWELL J.A.: Ultrasound-Guided Central Venous Catheter Placement Decreases Complications and Decreases Placement Attempts Compared with the Landmark Technique in Patients in a Pediatric Intensive Care Unit." *Pediatric Critical Care*, Vol. 37: 1090-6, 2009.
- 17- BALLS A., LOVECCHIO F., KROEGER A., STAPCZYNSKI J.S., MULROW M. and DRACHMAN D.: Ultrasound Guidance for Central Venous Catheter Placement: Results from the Central Line Emergency Access Registry Database." *American Journal of Emergency Medicine*, 28: 561-7, 2009.
- 18- M. MICCINI, D. CASSINI, M. GREGORI, S. GAZZANELLI, S. CASSIBBA and D. BIACCHI: Ultrasound-guided placement of central venous port systems via the right internal jugular vein: Are chest X-ray and/or fluoroscopy needed to confirm the correct placement of the device?" *World Journal of Surgery*, 40 (10): 2353-8, 2016.
- 19- H. MATSUSHIMA, T. ADACHI and T. IWATA: Analysis of the outcomes in central venous access port implantation performed by residents via the internal jugular vein and subclavian vein. *Journal of Surgical Education*, Vol. 74,

إدخال قسطرة بورتا باستخدام التوجيه التصويري مقارنة بإدخالها بالتقنية التشريحية

المقدمة: يعتبر إدخال قسطرة بورتا تحت الجلد من الأشياء المهمة لمرضى السرطان الذين يتلقون العلاج الكيميائي، وتتم هذه العملية أما في وحدة الأشعة التداخلية بالإستعانة بأدوات التصوير الطبى، أو فى قسم الجراحة عمياناً باستخدام العلامات التشريحية.

الهدف من الدراسة: هو مقارنة مميزات ومضاعفات الطريقتين المستخدمتين فى إدخال قسطرة بورتا.

المرضى وطرق البحث: تم إجراء الدراسة على ١١٠ مريض من مرضى السرطان الذين يتلقون العلاج الكيميائي محولين من العيادات الخارجية لتركييب قسطرة بورتا فى الفترة من يناير ٢٠١٩ وحتى يناير ٢٠٢٠. تم إستخدام طريقة الإستعانة بأدوات التصوير الطبى فى وحدة الأشعة التداخلية مع ٥٥ مريض، فى حين خضع ال ٥٥ مريض الباقين بقسم الجراحة. تم جمع البيانات الخاصة بحدوث مضاعفات فى الطريقتين وذلك أثناء المتابعة الخاصة بالمرضى، وتم تحليلها إحصائياً.

النتائج: مضاعفات تركيب قسطرة بورتا بالإستعانة بأدوات التصوير الطبى فى وحدة الأشعة التداخلية، أقل بكثير من تلك التى تمت بقسم الجراحة باستخدام طريقة العلامات التشريحية.

الخلاصة: الإستعانة بالتصوير الطبى أثناء تركيب قسطرة بورتا أفضل بكثير من إستخدام الطريقة التشريحية.