

Microneedling With and Without Vitamin C versus Fractional CO₂ LASER in Treating Abdominal Striae Distensae Alba: A Comparative Clinical and Histopathological Study

AMIRA S. ABDELSAMIEA, M.Sc.*; NERMEEN S. ABDEL FATTAH, M.D.*; OLA H. NADA, M.D.** and CHRISTINE K.T. GABRIAL, M.D.*

The Departments of Dermatology, Venereology & Andrology and Pathology**, Faculty of Medicine, Ain Shams University*

Abstract

Background: Striae distensae, a common skin condition, represent linear dermal scars accompanied by epidermal atrophy.

Aim of Study: The aim of this prospective self controlled comparative study is to evaluate and compare between microneedling only, microneedling with topical vitamin C 15% application and fractional CO₂ LASER in treatment of abdominal striae distensae alba.

Patients and Methods: This prospective self-controlled comparative study included 30 patients with abdominal striae distensae alba (five patients skipped the study). Sampling method equation and program: MedCalc® version 12.3.0.0 (Ostend, Belgium) was used for calculation of sample size, statistical calculator based on 95% confidence interval and power of the study was 80% with a error 5%. Type of sampling was simple random sampling.

All patients were from the Dermatology Outpatient Clinic, Ain-Shams University Hospitals in the period from December 2016 till July 2017.

This study was approved by the Research Ethical Committee of Faculty of Medicine Ain Shams University. All patients signed an informing written consent with full information about the description of the procedure of treatment, possible side effects and photo documentation.

Results: Microneedling in combination with vitamin C is an effective, safe and low-cost therapy treatment modality for abdominal striae distensae alba. Addition of topical vitamin C increases the treatment outcome. It is easy to perform with no observable side effects or serious complications and results in great patient satisfaction with high induction of both collagen and elastin and increase in epidermal thickness and rete ridges.

Although fractional CO₂ LASER has been proven to play a role in collagen and elastin induction but the presence of complications as post inflammatory hyperpigmentation leads to decrease in patient satisfaction.

Key Words: *Microneedling – Vitamin C fractional CO₂ laser – Abdominal striae distensae alba.*

Correspondence to: Dr. Amira S. Abdelsamiea, [E-Mail: dr.amirasamy@hotmail.com](mailto:dr.amirasamy@hotmail.com)

Introduction

STRIAE distensae affect skin that is subjected to continuous and progressive stretching, increased stress is placed on the connective tissue due to increased size of the various parts of the body [1].

Striae distensae are a reflection of "breaks" in the connective tissue. Skin distention may lead to excessive mast cell degranulation with subsequent damage of collagen and elastin [2]. Prolonged use of oral or topical corticosteroids or Cushing syndrome (increased cortical activity) leads to the development of striae [3].

Microneedling and fractional CO₂ LASER showed promising results in treatment of striae distensae alba [4].

Microneedling is being used in dermatology for mainly two purposes, firstly, collagen induction therapy for scars, stretch marks and antiaging effect and secondly, for deep transdermal delivery of active substances through epidermal barrier (stratum corneum) [5].

In the dermis, vitamin C is required for the formation of hydroxyprolyl residues to form stable triple-helical collagen molecules and hydroxylysyl residues operating in crosslinks synthesis [6].

Vitamin C is also known to stabilize the collagen messenger RNAs (m-RNA) and increase procollagen synthesis [7].

The fractional CO₂ LASER is one of the most widely used LASERS in the dermatology field. It emits light at a wavelength of 10,600nm that is absorbed strongly by water (the primary chromophore for carbon dioxide LASER that is abundant

in skin) [8]. Approximately 90% of carbon dioxide LASER energy is absorbed in the initial 20-30µm of skin, yet traditional continuous wave LASERS leave behind a thick zone of thermal damage measuring 0.2-1mm in thickness [9]. As with other resurfacing modalities (e.g., chemical peeling, dermabrasion), completely removing the epidermis and part of the dermis results in wound remodeling with subsequent new collagen and elastin fiber formation that translates into healthier, firmer and tighter skin [10].

Aim of the work:

The aim of this study is to evaluate and compare between microneedling only, microneedling with topical vitamin C 15% application and fractional CO₂ LASER in treatment of abdominal striae distensae alba.

Patients and Methods

This prospective self-controlled comparative study included 30 patients with abdominal striae distensae alba (five patients skipped the study). Sampling method equation and program: MedCalc® version 12.3.0.0 (Ostend, Belgium) [11] was used for calculation of sample size, statistical calculator based on 95% confidence interval and power of the study was 80% with a error 5%. Type of sampling was simple random sampling.

All patients were from the Dermatology Out-patient Clinic, Ain-Shams University Hospitals in the period from December 2016 till July 2017.

This study was approved by the Research Ethical Committee of Faculty of Medicine Ain Shams University. All patients signed an informing written consent with full information about the description of the procedure of treatment, possible side effects and photo documentation.

Inclusion criteria: Age of the patients ranging from 18-45 years old, both males and females and skin types III-IV and striae distensae alba on abdomen (bilateral and more or less symmetrical).

Exclusion criteria according to Napolini et al., [4]. Premalignant or malignant skin diseases, collagen or elastic disorders e.g. (lupus, rheumatoid arthritis, scleroderma, temporal arteritis, Ehlers-Danlos syndrome and Marfan's syndrome), blood clotting disorders and patients on any anticoagulant therapy to avoid bleeding, diabetes mellitus or immunosuppression therapy to avoid delayed healing, keloids or hypertrophic scars, active skin infection, chronic skin disease like lichen and psoriasis to avoid koebner phenomenon, history

of oral retinoid intake within a year before the start of the study, oral or systemic steroids intake within a year before the start of the study to exclude striae rubra, striae rubra, previous treatment to striae with any kind of LASER, radiofrequency, dermabrasion or chemical peeling within a year before the start of the study, pregnant and lactating females, history of bariatric surgery (histologic evaluation of post-bariatric surgery skin samples showed a poorly organized collagen structure and elastin degradation) [12] and patients on diet.

All patients were subjected to the following:

1- Full history taking:

- The personal history including name, age, marital status, address, occupation, telephone number, pregnancy status, lactation and special habits of medical importance.
- Past medical history for the presence of any chronic illness, previous surgeries and drug history.
- Detailed history for the striae alba condition including first onset and duration. All previous treatments for striae alba were recorded.

2- Detailed consent about the steps of the procedure, the expected effects and possible complications.

3- General and dermatological examination: Careful general and dermatological examination was performed. Any signs of any associated systemic diseases or other skin conditions were recorded.

4- *Local examinations:* Local abdominal examination was done to confirm the diagnosis and ensure the type of the striae (alba).

5- *Evaluation of the severity of striae distensae:* Evaluation of the severity of striae distensae was done using the Davey score with a simplification, the severity of abdominal striae distensae was divided into three categories: Mild=0-5 striae, moderate=6-10 striae and severe > or =11 striae per abdomen [13] Fig. (1).

6- *Photographic documentation:* Standard digital photographs were taken from 3 views of the abdomen (right, front and left) for each patient when they first presented, before each treatment session as well as one month after the last session. Photographs were taken using Panasonic, lumix, 16.1 megapixels digital camera, Japan.

7- *Histological assessment:* Skin biopsies were taken from ten patients, 4mm punch biopsy was taken from the striae to be treated after local injection with Debocaine® (Lidocaine HCl 2%, manufactured by: Sigma-Tec pharmaceutical Industry).

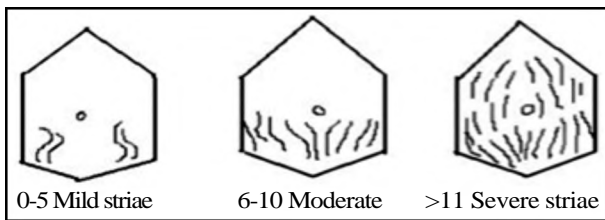


Fig. (1): Buchanan chart used to assess stretch mark scores.

The first biopsy was taken before treatment from one side randomly assigned and the other three biopsies were taken from the three sides one month after the treatment sessions. Skin biopsies were collected in 10% formalin solution, (100ml of formaldehyde and 900ml of distilled water). Fixation time: 12-24 hours then processed into paraffin blocks and sections.

8- Procedure:

Eutectic Mixture of Local Anesthesia (EMLA) cream (APP Pharmaceuticals, Fresenius Kabi, San Francisco, USA) was applied to the abdomen for approximately 45-60 minutes before the procedure. The affected areas of the abdomen were divided into three parts: Right, left and middle. The right part of the abdomen (Area A) was treated by microneedling only with 1.5mm depth [14]. Microneedling treatment was performed by derma pen (Bomtech Electronics, Seoul, Korea). The middle part (Area B) of the abdomen was treated with microneedling (derma pen) with 1.5mm depth in combination with topical vitamin C 15% serum application ordered by Elbadr Pharma Company (Cairo, Egypt). The left part of the abdomen (Area C) was treated with 10,600nm fractional CO₂ LASER (Bison Medical Fire-xel LASER, Seoul, Korea), using 40mJ energy per pulse, 8mm X 8mm scanning area and single path [15]. All patients received monthly treatment for three sessions. All sessions were done at LASER Unit, Dermatology Department, Ain-Shams University Hospitals.

1- *Subjective evaluation:* According to the score of Yang and Lee:

A- Clinical improvement was evaluated by the average score of two blinded dermatologists assessment of patients by comparing photographs before and after treatment.

The criteria for evaluations using a quartile grading scale were as follows:

- 0 = No improvement.
- 1 = Mild (percent improvement < or =25%).
- 2 = Moderate (percent improvement=26~50%).
- 3 = Good (percent improvement=51~75%).
- 4 = Excellent (percent improvement > or =76%).

B- In addition, a patient satisfaction score was rated using the following scale:

- 0 = Not satisfied.
- 1 = Slightly satisfied.
- 2 = Satisfied.
- 3 = Very satisfied.
- 4 = Extremely satisfied.

2- *Objective assessment (histopathological evaluation):*

Sections were stained with:

Hematoxylin and Eosin stain were used to compare the epidermal thickness and rete ridges before and after treatment. Scale bar microscopic measurement was used to measure the epidermal thickness and rete ridges in gm before and after treatment.

Masson trichrome stain was used to compare the quantity of collagen fibers before and after treatment.

Orcein stain was used to compare the quantity of elastic fibers before and after treatment.

After biopsy staining, images were acquired with a light microscope (Olympus(R) BX 40 CX21i-LED "Binocular Version" Biological Microscope, UK).

Image analysis was done using "Tissue Quant" software (version 1.0) [16]. The principle of the tissue quant was based on measuring the area occupied by the target structure taken up specific colour and its shades in the image, in the current study it was blue for collagen and brown for elastic fibers. The total area occupied by the structures to be analysed were represented by number of pixels are converted to percentage [17].

3- *Assessment of side effects:*

A- *Pair:* Patients were examined immediately after the treatment session to evaluate post procedural pain, each patient is asked to rate his pain intensity as a number from 0 to 10 [18] which was rated using numerical rating scale.

It is a (0 to 10) point scale which correlates to:

- No pain at zero.
- Mild pain from 1-4.
- Moderate pain from 5-7.
- Severe pain from 8-10.

B- *Other complications:* Patients were also asked and examined for other complications like edema, infection and hyperpigmentation.

Statistical analysis:

Recorded data were analyzed using the statistical package for social sciences, version 20.0 (SPSS Inc., Chicago, Illinois, USA). Quantitative data were expressed as mean \pm Standard Deviation (SD). Qualitative data were expressed as frequency and percentage.

Results

The results of the present study are demonstrated in the following Tables and Figs.:

1- **Demographic data:** The present study included 30 patients with abdominal striae alba (five patients skipped the study). Nineteen cases were females (76%) and six cases were males (24%). The age of patients ranged from 19 to 45 years old (mean=29.84 years \pm 6.14 SD) Table (1), they were recruited from the Dermatology Out-patient Clinic of Ain Shams University Hospitals from December 2016 to July 2017.

Table (1): Demographic data of the patients (n=25).

Demographic data	Total (n=25)
Sex:	
Male	6 (24%)
Female	19 (76%)
Age (years):	
Range	19-45
Mean \pm SD	29.84 \pm 6.

Table (2): Distribution of cases according to the duration of striae distensae alba (years) (n=25).

Duration (years)	Total (n=25)
<5 years	8 (32%)
5 ~ 10 years	12 (48%)
>10 years	5 (20%)
Range	3-18
Mean \pm SD	7.16 \pm 4.46
Median (IQR)	5 (4.5)

This table shows that the number of cases with duration of striae distensae alba <5 years=8 cases (32%), from 5 ~ 10 years=12 cases (48%) and >10 years=5 cases (20%). The range of duration of striae distensae alba from 3 to 18 years (mean=7.16 years \pm 4.46 SD) (Median=5 and IQR=4.5) Table (2).

Table (3): Causes of striae distensae alba (n=25).

Causes	Total (n=25)	%
Systemic corticosteroids	2	8.0
Obesity	15	60.0
Pregnancy	8	32.0
Total	25	100.0

The most common cause of striae distensae alba among the patients of our study was obesity reaching 15 cases (60%). Striae distensae due to pregnancy represented 8 cases (32%) and striae distensae due to systemic corticosteroids represented 2 cases (8%) Table (3).

Table (4): Severity of striae distensae alba according to Davey score (n=25).

Davey score	Total (n=25)	%
Mild	2	8
Moderate	8	32
Severe	15	60
Total	25	100

The number of cases with severe striae distensae alba were 15 cases (60%), moderate cases were 8 cases (32%) and mild cases were 2 cases (8%) according to Davey score Table (4).

2- Subjective evaluation of treatment outcome:

Table (5): Comparison between the three treatment groups according to the clinical evaluation by the score of two blinded dermatologists.

Clinical evaluation	Fractional CO ₂ LASER		Microneedling with vitamin C		Microneedling		Chi-square test	
	(n=25)	%	(n=25)	%	(n=25)	%	χ^2	p-value
0	13	52	10	40	8	32	12.038	0.149
1	10	40	13	52	11	44		
2	0	0	0	0	4	16		
3	0	0	0	0	1	4		
4	2	8	2	8	1	4		
Total	25	100	25	100	25	100		

This table shows no statistically significant difference between the three treatment groups according to the clinical evaluation by the score of two

blinded dermatologists, p-value=0.149 (Table 5).

Table (6): Comparison between the three treatment groups according to the clinical evaluation by the score of patient satisfaction.

Clinical evaluation	Fractional CO2 LASER		Microneedling		Microneedling with vitamin C		Chi-square test	
	(n=25)	%	(n=25)	%	(n=25)	%	χ^2	p-value
0	12	48	9	36	7	28	8.539	0.383
1	11	44	12	48	10	40		
2	0	0	1	4	3	12		
3	0	0	1	4	3	12		
4	2	8	2	8	2	8		
Total	25	100	25	100	25	100		

This table shows no statistically significant difference between the three treatment groups according to the clinical evaluation by the score of patient satisfaction, p -value=0.383 (Table 6).

2- *Objective evaluation (histopathological evaluation)*: Histopathological examination of the skin biopsies obtained before treatment demonstrated

thin atrophic epidermis and flat dermo-epidermal junction. The dermis showed increased inter-fibrillary space and random deposition of collagen fibers. At the end of the follow-up period, treated patients showed an increase in the thickness of the epidermis with an increase in collagen and elastin fibers in the dermis and decreased inter-fibrillary spaces.

Table (7): Comparison between the epidermal thickness before and after treatment.

Treatment groups	Range (μ m)	Mean \pm SD	Paired Sample t -test			
			Mean difference	Change %	t -test	p -value
Pre-treatment	64.41-68.75	66.62 \pm 1.52				
Fractional CO2 LASER	72.72-79.81	75.60 \pm 2.61	8.98	13.5%	23.679	<0.001 **
Microneedling	67.13-73.42	70.37 \pm 2.08	3.75	5.6%	18.692	<0.001 **
Microneedling with vitamin C	75.64-85.43	80.16 \pm 3.49	13.54	20.3%	21.243	<0.001 **

In the side treated with fractional CO2 LASER, the mean epidermal thickness increased from 66.62 \pm 1.52 μ m before treatment to 75.60 \pm 2.61 μ m after treatment. In the side treated with microneedling, it increased to 70.37 \pm 2.08 μ m and in the side

with microneedling with vitamin C, it increased to 80.16 \pm 3.49 μ m.

There was a highly statistically significant improvement in the epidermal thickness in all sides (p =<0.001**) Table (7).

Table (8): Comparison between the mean percentage of collagen content before and after treatment.

Treatment groups	Range (%)	Mean \pm SD	Paired Sample t -test			
			Mean diff.	Change %	t -test	p -value
Pre-treatment	35.25-50.24	41.49 \pm 5.34				
Fractional CO2 LASER	41.29-58.56	48.54 \pm 6.04	7.05	17.0%	6.922	<0.001 **
Microneedling	38.47-55.37	46.30 \pm 5.76	4.81	11.6%	23.510	<0.001 **
Microneedling with vitamin C	45.78-60.48	51.47 \pm 5.36	9.98	24.1%	94.886	<0.001 **

In the side treated with fractional CO2 LASER the mean percentage of collagen content changed from 41.49 \pm 5.34% to 48.54 \pm 6.04%. In the side treated with microneedling only, it changed to 46.30 \pm 5.76% and in the side treated with

needling with vitamin C, it changed to 51.47 \pm 5.36%.

There was a highly statistically significant improvement in the mean percentage of collagen content in all sides (p =<0.001**) Table (8).

Table (9): Comparison between the mean percentage of elastin content before and after treatment.

Treatment groups	Range (%)	Mean ± SD	Paired Sample <i>t</i> -test			
			Mean difference	Change %	<i>t</i> -test	<i>p</i> -value
Pre-treatment	7.29-12.69	9.92±1.98				
Fractional CO ₂ LASER	15.3-20.87	17.91±2.07	7.99	80.5%	99.599	<0.001**
Microneedling	12.11-17.71	14.88±2.12	4.96	50.0%	57.326	<0.001**
Microneedling with vitamin C	17.42-22.82	19.89±1.94	9.97	100.5%	82.020	<0.001**

In the side treated with fractional CO₂ LASER the mean percentage of elastin content increased from 9.92±1.98% to 17.91±2.07%. In the side treated with microneedling only, it increased to 14.88±2.12% and in the side treated with micro-needling with vitamin C, it increased to 19.89±1.94%.

There was a highly statistically significant improvement in the mean percentage of elastin content in all sides ($p < 0.001^{**}$) Table (9).

3- Assessment of side effects: • Pain:

Most of the patients of our study (96%) experienced mild pain after treatment with microneedling or microneedling with vitamin C application, but in areas treated with fractional CO₂ LASER 13 patients (52%) experienced mild pain, 11 patients (44%) experienced moderate pain and one patient experienced severe pain (4%) Table (10).

Table (10): Comparison between the three treatment groups according to the pain score.

Pain score	Fractional CO ₂ LASER		Microneedling		Microneedling with vitamin C		Chi-square test	
	(n=25)	%	(n=25)	%	(n=25)	%	χ^2	<i>p</i> -value
Mild	13	52	24	96	24	96	21.352	<0.001**
Moderate	11	44	1	4	1	4		
Severe	1	4	0	0	0	0		
Total	25	100	25	100	25	100		

This table shows statistically significant difference between treatment by fractional CO₂ LASER and treatment by microneedling or microneedling with vitamin C according to the pain score, treat

ment with fractional CO₂ LASER showed higher pain intensity than treatment by microneedling or microneedling with vitamin C, p -value=0.002 * Table (10).

Table (11): Comparison between the three treatment groups according to the occurrence of Post Inflammatory Hyperpigmentation (PIH).

PIH	Fractional CO ₂ LASER		Microneedling		Microneedling with vitamin C		Chi-square test	
	(n=25)	%	(n=25)	%	(n=25)	%	χ^2	<i>p</i> -value
Negative	20	80	25	100	25	100	10.714	0.005**
Positive	5	20	0	0	0	0		
Total	25	100	25	100	25	100		

This table shows statistically significant difference between treatment by fractional CO₂ LASER and treatment by microneedling or microneedling with vitamin C according to the occurrence of Post Inflammatory Hyperpigmentation (PIH), p -value 0.049*. Hyperpigmentation was reported by the two blinded dermatologist in 5 cases (20%) in areas treated with fractional CO₂ LASER and no

cases of hyperpigmentation were reported after treatment by microneedling or microneedling with vitamin C Table (11).

No reported cases of Hypopigmentation, infection, allergy or any other side effects after treatment with fractional CO₂ LASER, microneedling or microneedling with vitamin C.

Fig. (2): Case (1)

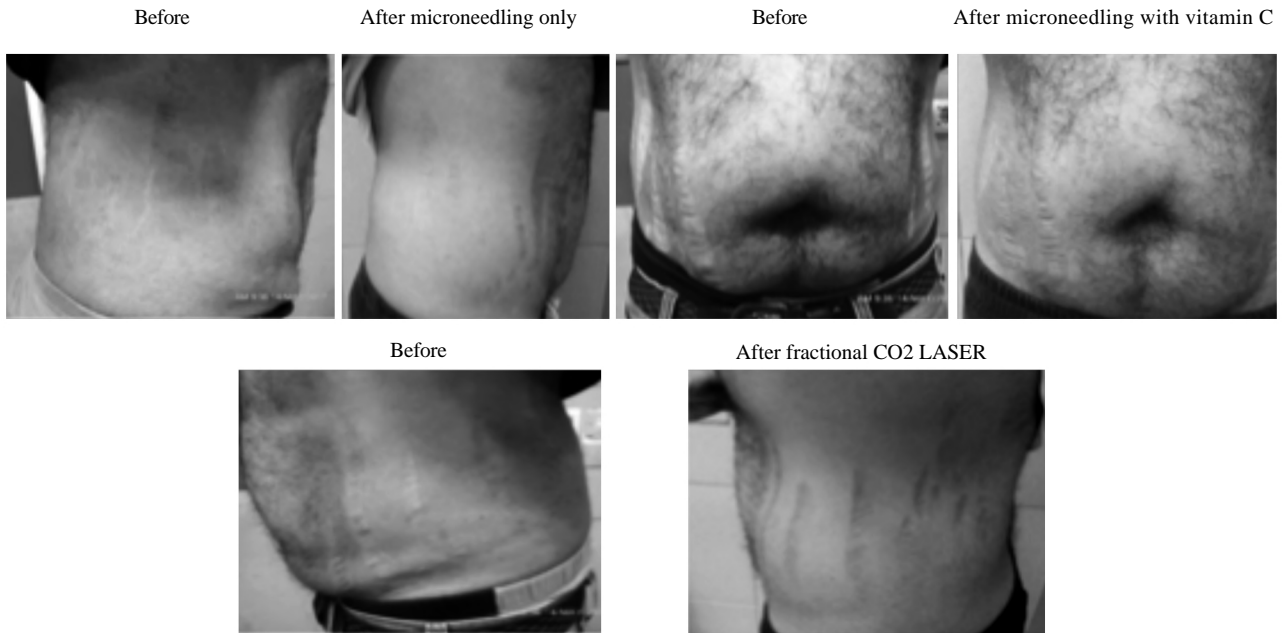


Fig. (2): Case 1: 35 years old male patient complained of (severe) striae distensae alba after systemic corticosteroid administration.

Fig. (3): Histopathology of Case (1) (Collagen).

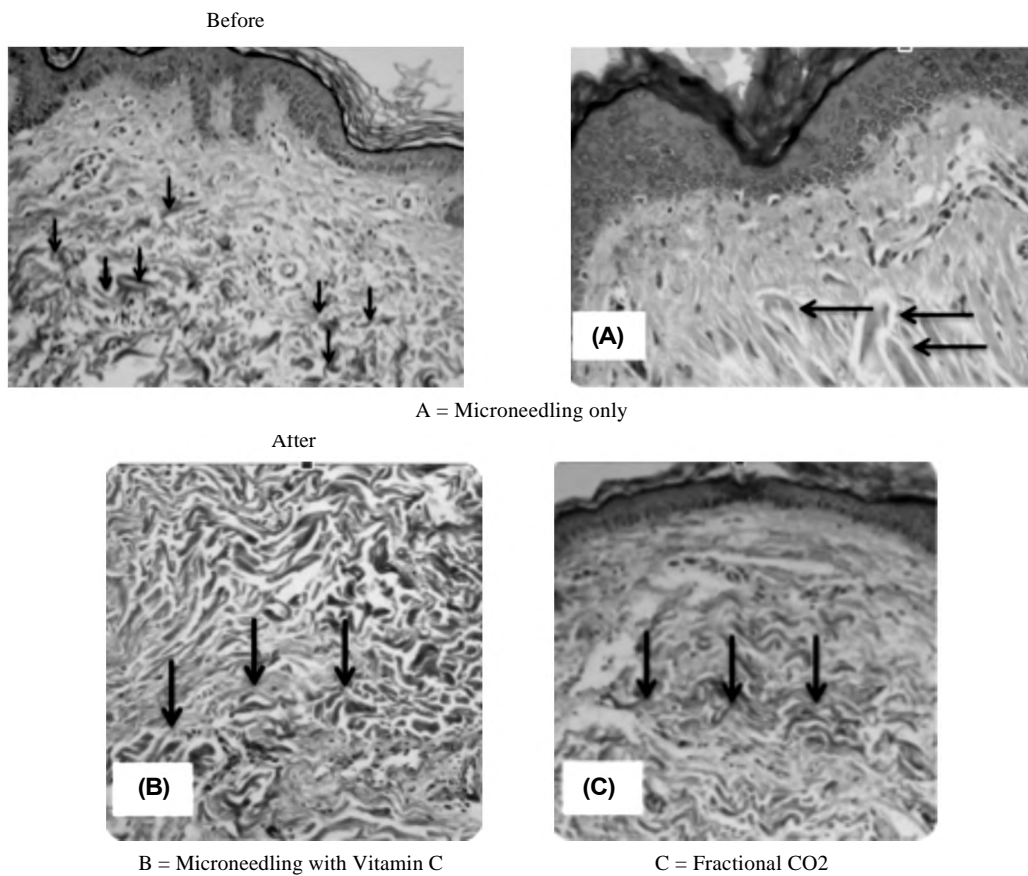


Fig. (3): Case 1: Striae alba before treatment showing randomly distributed collagen with increased inter-fibrillary spaces, biopsies after the treatment modalities showed an increase in the number and density of collagen fibers, decreased inter-fibrillary spaces and there was good linear orientation of the fibers parallel to the dermo-epidermal junction in all sides.

Fig. (4): Histopathology of Case (1) (Elastin).

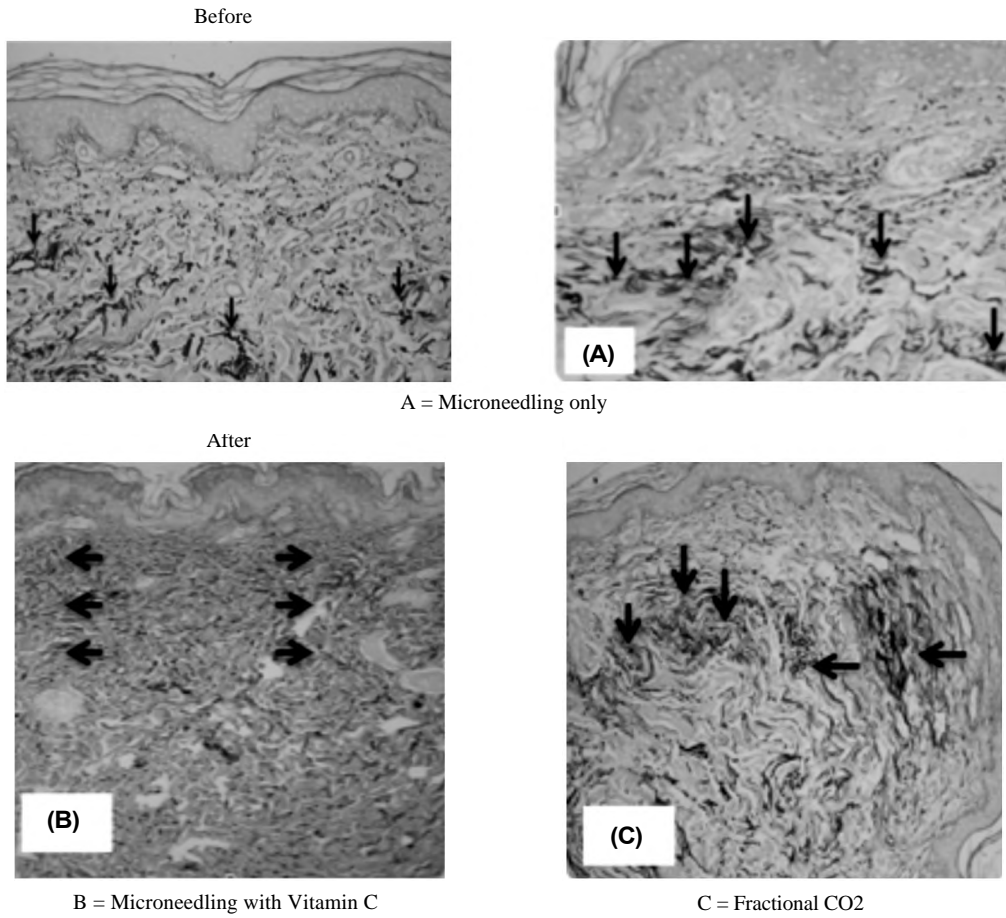


Fig. (4): Case 1: The elastin fibers on the papillary dermis are significantly reduced in striae, biopsies after the treatment modalities showing an increase in the number and density of elastic fibers.

Fig. (5): Case (2)

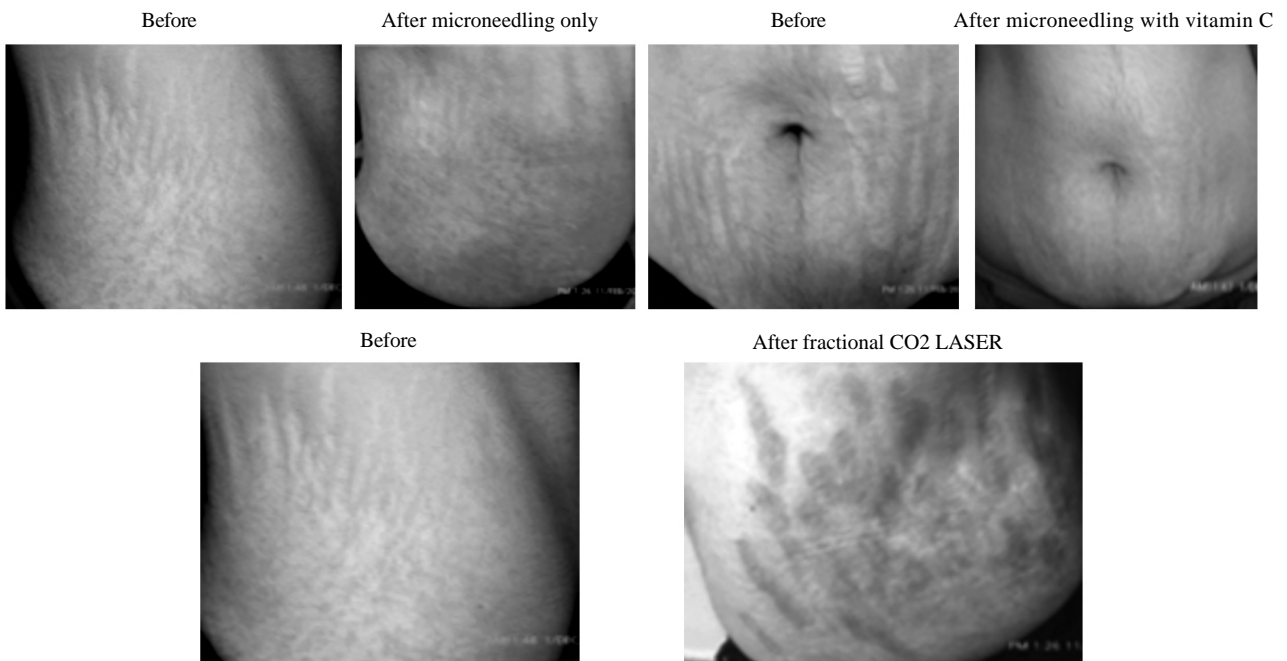


Fig. (5): Case 2: 42 years old female patient complained of (severe) striae distensae alba after pregnancy. We reported PIH after treatment with fractional CO₂ LASER.

Discussion

The aim of this prospective self controlled comparative study is to evaluate and compare between microneedling only, microneedling with topical vitamin C 15% application and fractional CO₂ LASER in treatment of abdominal striae distensae alba.

The present study included 30 patients with abdominal striae alba (five patients skipped the study). Nineteen cases were females (76%) and six cases were males (24%). The age of patients ranged from 19 to 45 years old (mean=29.84 years \pm 6.14 SD).

The most common cause of striae distensae alba among the patients of our study was obesity reaching 15 cases (60%), pregnancy represented 8 cases (32%) and striae distensae due to systemic corticosteroids represented 2 cases (8%). The number of cases with severe striae distensae alba were 15 cases (60%), moderate cases were 8 cases (32%) and mild cases were 2 cases (8%).

The role of fractional CO₂ LASER in treatment of striae distensae alba has been discussed before by Lee et al., when twentyseven women with striae distensae were treated in a single session with fractional CO₂ LASER. Clinical improvement was assessed by comparing pre and post-treatment clinical photographs and participant satisfaction rates, evaluators used a quartile grading scale from 0=no change to excellent=75-100% improvement, the evaluation of clinical results 3 months after treatment showed that two of the 27 participants (7.4%) had grade 4 (excellent) improvements, 14 (51.9%) had grade 3 (marked) improvements, nine (33.3%) had grade 2 (moderate) improvements and two (7.4%) had grade 1 (mild) improvement. Surveys evaluating overall participant satisfaction administered after treatment with fractional CO₂ LASER completed showed that six of the 27 participants (22.2%) were very satisfied, 14 (51.9%) were satisfied, five (18.1%) were slightly satisfied and two (7.4%) were unsatisfied [19].

The evaluation of clinical results of our study one month after three monthly sessions of fractional CO₂ LASER treatment showed that only two patients (8%) out of 25 patients had excellent improvement, ten patients (40%) had mild improvement and thirteen patients (52%) had no improvement. Patient satisfaction score after the treatment showed twelve patients (48%) were not satisfied by the result, eleven patients (44%) were slightly satisfied and only two patients (8%) were extremely satisfied by the results [19].

Our study showed statistically significant (p -value ≤ 0.001) increase in the mean percentage of dermal collagen by 17% to be (48.54 \pm 6.04) % and elastin by 80.5% to be (17.91 \pm 2.07) % in all cases (100%) treated by fractional CO₂ LASER. There was also increase in the mean epidermal thickness by 13.5% to be (75.60 \pm 2.61) μ m and rete ridges by 26.4% to be (76.93 \pm 20.43) μ m which is in agreement with another study done by Yang and Lee on 24 Korean female volunteers with abdominal atrophic striae alba who were treated with fractional CO₂ LASER for a total of three treatments, 4 weeks apart. The results revealed that the ablative fractional CO₂ LASER produced statistically significant improvement in overall clinical appearance, skin elasticity over baseline measurements, increase of epidermal thickness and the amount of collagen and elastic fibers were also increased compared to the pre-treatment state. Yang and lee reported that the treatment was generally well tolerated. There was no significant long lasting adverse effect except transient mild erythema [15] but in our study we reported five cases (20%) of persistent post inflammatory hyperpigmentation.

In the current study, we were also able to show the effectiveness and safety of microneedle therapy in the treatment of striae distensae with two cases (8%) showed excellent clinical improvement and extreme patient satisfaction, thirteen patients (52%) showed mild improvement but ten patients (40%) showed no improvement, nine patients (36%) were not satisfied, twelve patients (48%) were slightly satisfied, one patient (4%) was satisfied and one patient (4%) was very satisfied, which is in agreement with a study performed by Park et al., on sixteen Korean volunteers with striae distensae alba, patients received three treatments using a disk microneedle therapy system at 4 weeks intervals. Clinical response to treatment was assessed by comparing preand post-treatment clinical photographs and patient satisfaction scores, marked to excellent improvement was noted in seven (43.8%) patients, with minimal to moderate improvement in the remaining nine patients. Patient satisfaction scores showed that six (37.5%) patients were highly satisfied, eight (50.0%) were satisfied and two (12.5%) were unsatisfied. There were no significant side effects except mild pain, erythema and spotty bleeding [14].

Skin biopsies of Park et al., showed increase in the amount of collagen, number of fibroblasts and epidermal thickness at the end of treatment sessions which is in agreement with our study that showed statistically significant (p -value < 0.001)

increase in the mean percentage of collagen by (11.6) % to be (46.30±5.76) %, elastin by (50) % to be (14.88±2.12) %, increase in the thickness of rete ridges by (16.6) % to be (70.95±20.72) μ m and increase in the epidermal thickness by 5.6% to be (70.37±2.08) μ m in all cases (100%) treated by microneedling.

In our study we spotted the light on vitamin C as an adjuvant in collagen induction with microneedling [20]. We reported high increase in the mean of collagen percentage by 24.1% to be (51.47 ± 5.36) %, elastin percentage by 100.5% to be (19.89±1.94) %, increase in epidermal thickness by 20.3% (80.16± 3.49) μ m and rete ridges by 33.2% to be (81.05±20.70) μ m which is in agreement with a study done by Casabona and Marchese to assess the effectiveness of microneedling with topical vitamin C for improving the appearance of red and white stretch marks. Skin biopsies revealed an increase in the quantity and quality of dermal collagen and elastin fibers [21].

Comparing the three treatment modalities with each others, there was no statistically significant difference between the three treatment options according to the score of the two blinded dermatologists (p -value=0.149) or the score of patient satisfaction (p -value=0.383) but there was highly statistically significant difference according to the histopathological evaluation (p -value <0.001 *), the highest rate of collagen and elastin induction was induced by microneedling with vitamin C followed by fractional CO₂ LASER then microneedling only, but complications were reported only in areas treated with fractional CO₂ LASER (20%), we refer this to the parameters used which is in agreement with a study done by Soliman et al., and Sobhi et al., to evaluate the efficacy of fractional CO₂ as a treatment of striae distensae, postinflammatory hyperpigmentation was evident with fractional CO₂ [22,23], treatment with fractional CO₂ LASER showed higher pain intensity than treatment by microneedling or microneedling with vitamin C, pain score was higher in fractional CO₂ LASER than microneedling only or microneedling with vitamin C, most of the patients of our study (96%) experienced mild pain after treatment with microneedling or microneedling with vitamin C application, but in areas treated with fractional CO₂ LASER 13 patients (52%) experienced mild pain, 11 patients (44%) experienced moderate pain and one patient experienced severe pain (4%), in addition to microneedling is a useful low-cost therapy for striae alba than fractional CO₂ which is in agreement with a study done by Napolini et

al., to compare between fractional LASER and microneedling for treating striae distensae [4].

Conclusion:

We conclude that microneedling in combination with vitamin C is an effective treatment modality for abdominal striae distensae alba. Addition of topical vitamin C increases the treatment outcome. It is easy to perform with no observable side effects or serious complications and results in great patient satisfaction with high induction of both collagen and elastin and increase in epidermal thickness and rete ridges, although fractional CO₂ LASER has been proven to play a role in collagen and elastin induction but the presence of complications as postinflammatory hyperpigmentation leads to decrease in patient satisfaction.

References

- 1- FORBAT E. and AL-NIAIMI F.: Treatment of striae distensae: An evidence-based approach. *J. Cosmet. Laser Ther.*, 16: 1-9, 2018.
- 2- SALTER S.A. and KIMBALL A.B.: Striae gravidarum. *Clin. Dermatol.*, 24: 97-100, 2006.
- 3- SCHOEPE S., SCHÄCKE H., MAY E. and ASADULLAH K.: Glucocorticoid therapy-induced skin atrophy. *Exp. Dermatol.*, 15 (6): 406-20, 2006.
- 4- NASPOLINI A.P., BOZA J.C., Da SILVA V.D. and CE-STARI T.F.: Efficacy of Microneedling Versus Fractional Non-ablative Laser to Treat Striae Alba: A Randomized Study. *Am. J. Clin. Dermatol.*, 20 (2): 277-87, 2019.
- 5- DENET A.R., VANBEVER R. and PRÉAT V.: Skin electroporation for transdermal and topical delivery. *Adv. Drug Deliv. Rev.*, 56: 659-74, 2004.
- 6- HUMBERT P., MESSIKH R. and TRY C.: The action of vitamin C for treating wrinkles and protecting skin from photodamage. *Eur. J. Dermatol.*, 5: 36-40, 2010.
- 7- BERISIO R., VITAGLIANO L., MAZZARELLA L. and ZAGARI A.: Crystal structure of the collagen triple helix model. *Protein Sci.*, 11: 262-70, 2002.
- 8- RIGGS K., KELLER M. and HUMPHREYS T.R.: Ablative laser resurfacing: High-energy pulsed carbon dioxide and erbium: Yttrium-aluminum-garnet. *Clin. Dermatol.*, 25: 462-73, 2007.
- 9- CHAN N.P., HO S.G. and YEUNG C.K.: Fractional ablative carbon dioxide LASER resurfacing for skin rejuvenation and acne scars in Asians. *Lasers Surg. Med.*, 42: 615-23, 2010.
- 10- KARSAI S., CZARNECKA A., JUNGER M. and RAULIN C.: Ablative fractional lasers (CO₂ and Er:YAG): A randomized controlled double-blind split-face trial of the treatment of peri-orbital rhytides. *Lasers Surg. Med.*, 42: 160-7, 2010.
- 11- SCHOONJANS F., ZALATA A., DEPUYDT C.E. and COMHAIRE F.H.: MedCalc: A new computer program for medical statistics. *Comput Methods Programs Biomed.*

- 12- LIGHT D., DAVID M.D. and GEORGIA M.: Effect of Weight Loss after Bariatric Surgery on Skin and the Extracellular Matrix. *Plast. Reconstr. Surg.*, 125: 343-51, 2010.
- 13- BUCHANAN K., FLETCHER H.M. and REID M.: Prevention of striae gravidarum with cocoa butter cream. *Int. J. Gynaecol. Obstet.*, 108: 65-8, 2010.
- 14- PARK K.Y., KIM H.K. and KIM S.E.: Treatment of striae distensae using needling therapy: A pilot study. *Dermatol. Surg.*, 38: 1823-8, 2012.
- 15- YANG Y.J. and LEE G.Y.: Treatment of Striae Distensae with Nonablative Fractional Laser versus Ablative CO2 Fractional Laser: A Randomized Controlled Trial. *Ann. Dermatol.*, 23: 481-9, 2011.
- 16- PRASAD K., CHAKRAVARTHY M. and PRABHU G.: Applications of 'Tissue Quant'-a colour intensity quantification tool for medical research. *Comput Methods Programs Biomed.* 106 (1): 27-36, 2012.
- 17- NAVEEN K., PRAMOD K., KEERTHANA P., SATHEE-SHA N.B., RANJINI K. and RAGHUVVEER C.V.: Histomorphometric Analysis of Dermal Collagen and Elastic Fibres in Skin Tissues Taken Perpendicular to Each Other. *From Head and Neck Region. Plast. Surg. Int.*, 4 (8): 171-6, 2014.
- 18- MOHAMMAD I.R., AL ZAMIL L. and TRENGGANU I.: Pain assessment immediately after venipuncture in adulthood. *Life Sci. J.*, 10: 1901-8, 2013.
- 19- LEE S.E., KIM J.H., LEE S.J., LEE J.E., KANG J.M. and KIM Y.K.: Treatment of striae distensae using an ablative 10,600-nm carbon dioxide fractional LASER: A retrospective review of 27 participants. *Dermatol. Surg.*, 36: 1683-90, 2010.
- 20- GUPTA B., KUMAR B., SHARMA A., SORI D., SHARMA R. and MEHTA S.: Nutraceuticals for Antiaging, Nutraceuticals in Veterinary Medicine, 383-92, 2019.
- 21- CASABONA G. and MARCHESE P.: Calcium Hydroxylapatite Combined with Microneedling and Ascorbic Acid is Effective for Treating Stretch Marks: *Plast. Reconstr. Surg. Glob. Open*, 5 (9), 2017.
- 22- SOLIMAN M., MOHSEN SOLIMAN M., EL-TAWDY A. and SHORBAGY H.S.: Efficacy of fractional carbon dioxide laser versus microneedling in the treatment of striae distensae. *J. Cosmet. Laser Ther.*, 21 (5): 270-7 2019.

دراسة عملية وتحليلية للأنسجة لمقارنة الإبر المجهرية فقط أو بمصاحبة فيتامين ج مقابل ليزر ثاني أكسيد الكربون في علاج الخطوط التمديدية البيضاء في البطن

تعد علامات التمدد حالة شائعة للغاية ومشكلة تجميلية صعبة وتشكل عبئاً نفسياً كبيراً على المرضى. تم تطبيق طرق العلاج المختلفة مع معدل رضا منخفض.

هذه الدراسة مصممة للمقارنة الإكلينيكية والتحليلية للأنسجة بين الإبر المجهرية والإبر المجهرية بمصاحبة فيتامين ج الموضعي وليزر ثاني أكسيد الكربون التجزئي في علاج الخطوط التمديدية البيضاء.

تم قيد خمس وعشرين حالة في هذه الرسالة من نوع البشرة الثالث والرابع ويتراوح أعمارهم بين ١٩ إلى ٤٥ عاماً بمتوسط حسابي ٢٩.٨٤ عاماً ومدة الإصابة تتراوح بين ٣ إلى ١٨ عاماً بمتوسط حسابي ٧.١٦ عاماً.

تم تقسيم المنطقة المصابة من البطن إلى ثلاثة أجزاء: أيمن ووسط وأيسر الجزء الأيمن (منطقة أ) تم علاجه بالإبر المجهرية فقط والجزء الأوسط (منطقة ب) تم علاجه بالإبر المجهرية مع فيتامين ج الموضعي والجزء الأيسر (منطقة ج) تم علاجه بليزر ثاني أكسيد الكربون التجزئي.

تم إجراء الجلسات العلاجية بصورة شهرية لمدة ثلاث جلسات وتم عمل التقييم الإكلينيكي بواسطة إثنين من أخصائيين الجلدية عن طريق مقارنة الصور الفوتوغرافية قبل وبعد العلاج وتم الإستعانة بمستوى رضا الحالات عن العلاج للتقييم.

تم ملاحظة وجود زيادة في التصبغات في خمس حالات في المناطق التي تم علاجها بليزر ثاني أكسيد الكربون التجزئي.

تم أخذ العينات من الجلد بسمك ٤ملى متر من مكان عشوائي مصاب بالخطوط التمديدية قبل بدء جلسات العلاج وتم أخذ عينة من كل منطقة علاج بعد آخر جلسة علاج بشهر.

تم التقييم بواسطة تحليل الأنسجة وكان هناك زيادة ذات دلالة إحصائية في تحفيز الكولاجين والإيلاستين وزيادة سمك البشرة والتلال الشبكية في الثالث مناطق المعالجة.