

## The Effect of Stress Using Long-Term Continuous Light Exposure on Liver Cells in Male and Female Wistar Rats

MOHAMED Y. BERIKA, M.D., Ph.D.

The Department of Rehabilitation Science, College of Applied Medical Sciences, King Saud University, KSA  
and The Department of Anatomy, Faculty of Medicine, Mansoura University, Mansoura, Egypt

### Abstract

**Background:** Many modern lifestyles are unhealthy and can negatively affect our health. Many studies showed that the stress caused pronounced action on the structure of various body systems. The liver is one of the body organs that can be heavily affected by stress. The liver can withstand stress for longer periods and shows signs of damage very late although the structural changes can be detected very early.

**Aim of Study:** Is to examine the acute and chronic effect of acute and chronic stress of long-term continuous light exposure on the structure of the liver tissues.

**Material and Methods:** 48 male and female Wistar rats (250-300g) were enrolled in 6 groups (n=8/group). Group (a); Normal male control group with normal light/dark exposure. Group (b); Normal female control group with normal light/dark exposure. Group (c); Continuous room light for 3 weeks male group as an acute stress model in which normally fed male rats exposed to continuous room light exposure for 3 weeks. Group (d); Continuous room light for 3 weeks female group as an acute stress model in which normally fed female rats exposed to continuous room light exposure for 3 weeks. Group (e); Continuous room light for 3 months male group as a chronic stress model in which normally fed male rats exposed to continuous light exposure for 3 months. Group (f); Continuous room light for 3 months female group as a chronic stress model in which normally fed female rats exposed to continuous light exposure for 3 months.

**Results:** Sections of liver tissues of the groups who lived under acute stress showed generally, preserved hepatic architecture. The hepatocytes showed marked ballooning (vacuolar degeneration). The sinusoids and central veins showed congestion. Sections of liver tissues of the groups who lived under chronic stress conditions showed in general, preserved hepatic architecture. The hepatocytes showed ballooning (vacuolar degeneration), focal spotty necrosis, together with some binucleated cells. The sinusoids & central vein showed congestion.

**Conclusion:** This study used 48 Wistar mice as a model to assess the effect of stress on liver tissues. Continuous room light exposure was used as acute stress for 3 weeks and as chronic stress for 3 months. This stressful stimulus and its

deleterious effect on the liver may be supported by the theory of sympathetic nervous system overactivity. The examined liver tissues in this study showed congestive and degenerative changes both in acute and chronic stressed animals. Changing modern lifestyles to one that respects the natural chronobiology is important for our wellbeing.

**Key Words:** Continuous light stress – Liver – Rat.

### Introduction

**STUDIED** biological rhythms lately led to many cellular, molecular, and neurobiological discoveries which resulted in the expansion of the knowledge base of the impact of chronobiology on health. The high sensitivity of chronobiology to the light/dark cycle changes was reported [1]. It was found that the stimulation of retinohypothalamic tract neurons by light may affect the central circadian clock in the hypothalamus [2]. Disturbance of light/dark cycle disturbs the normal chronobiologic rhythms of the metabolic system causing various disorders from disturbed insulin sensitivity and development of type II diabetes to cardiovascular and liver disease [3]. The modern communities are exposed to light at night which increases vulnerability to metabolic disorders. Disturbed sleep rhythms as happens in workers having night-shifts raise the possibility of exposure to biological disorders [4]. Not enough data is present regarding the effect of Continuous Light (CL) exposure as a model of stress on liver histology. Different studies demonstrated the effect of long-term CL exposure in rats on metabolic activities. These studies noted a decrease in body weight [5], body mass increase [6]. Others showed no change in body weight [7]. The effect of exposure to CL or dim light on food intake is also controversial [8]. The light/dark cycle can affect the liver energy expenditure and consequent effects by the release of hormones and autonomic signals [9].

**Correspondence to:** Dr. Mohamed Y. Berika, [E-Mail: mberika@ksu.edu.sa](mailto:mberika@ksu.edu.sa)

It is well known that females are more liable to suffer more stress than males because they have a different stress response. Females have a different hormonal system that results in more emotional reactions and become more exhausted emotionally. Investigations are still in the early stages to discover different gender responses to stress in humans; however, one of the key players in that is estrogen [10].

### Material and Methods

#### Animals and procedures:

48 male and female Wistar rats (250-300g) were enrolled in 6 groups (n=8/group) each group contains 4 males and 4 females.

*Group (a):* Normal male control group with normal light/dark exposure.

*Group (b):* Normal female control group with normal light/dark exposure.

*Group (c):* Continuous room light for 3 weeks male group as an acute stress model which normally fed male rats exposed to continuous light exposure for 3 weeks.

*Group (d):* Continuous room light for 3 weeks female group as an acute stress model in which normally fed female rats exposed to continuous light exposure for 3 weeks.

*Group (e):* Continuous light for 3 months male group as a chronic stress model in which normally fed male rats exposed to continuous light exposure for 3 months.

*Group (f):* Continuous light for 3 months female group as a chronic stress model in which normally fed female rats exposed to continuous light exposure for 3 months.

#### Tissue samples preparation:

Immediately after killing of the animals by euthanasia, tissue samples from the liver were fixed in 10% neutral formalin solution for pathology examination. Then pathology samples were preserved in 70% ethanol and dehydrated with ascending grades of ethanol. Then, it was cleared with xylene and embedded in paraffin wax to get paraffin blocks. Paraffin blocks were cut to obtain serial sections of 59m, then, they were put on the top of glass slides and stained with hematoxylin and eosin (H & E) stain. Then were examined under a light microscope equipped with a high-resolution digital camera (X10, and X20).

This study was carried out in The Faculty of Medicine, Mansoura University, Egypt during 2018-2019

### Results

This study included 24 male and 24 female rats with body weight ranged from 250 to 300 grams and aged from 2.5 to 3 months. Two groups (one male and one female) lived under normal light/dark cycles. Two groups (one male and one female) lived in acute stress by exposure to continuous room light for 3 weeks. Two groups (one male and one female) lived in chronic stress by exposure to continuous light for 3 months.

Examination of H & E sections of liver tissues of control groups who lived under normal light/dark cycles showed preserved hepatic architecture Fig. (1A,B).

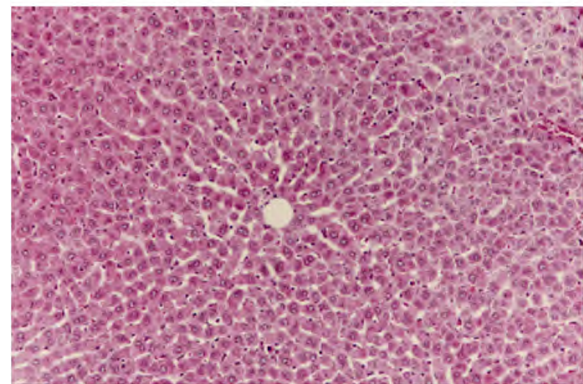


Fig. (1A): H & E section of liver tissues of female control rat who lived under normal light/dark cycles showing preserved hepatic architecture (X20).

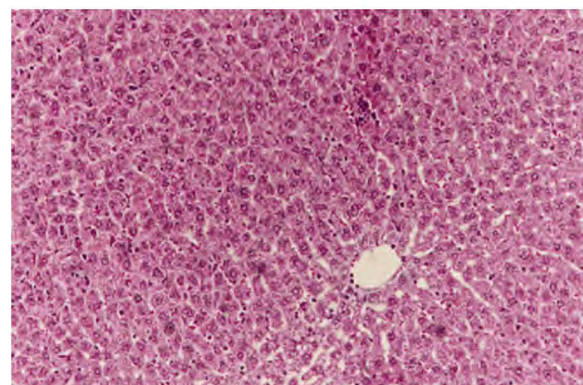


Fig. (1B): H & E section of liver tissues of male control rat who lived under normal light/dark cycles showing preserved hepatic architecture (X20).

Examination of H & E sections of liver tissues of the groups who lived under acute stress showed generally, preserved hepatic architecture. The hepatocytes showed marked ballooning (vacuolar degeneration). The sinusoids and central veins showed congestion. The portal tracts appeared within normal. No evidence of dysplasia or malignancy were noticed in the sections examined Fig. (2A,B,C).



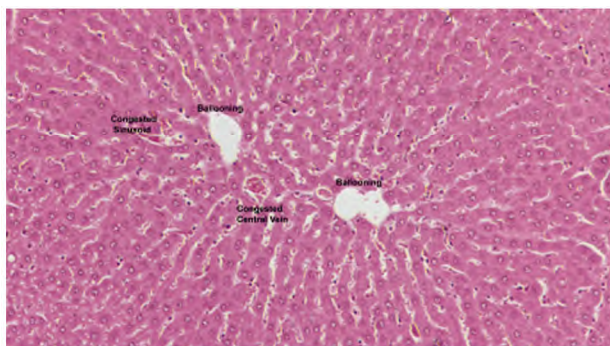


Fig. (2A): H & E section of liver tissues of an acutely stressed female rat showing preserved hepatic architecture, marked ballooning (vacuolar degeneration), the sinusoids and central veins showed congestion. ( X20).

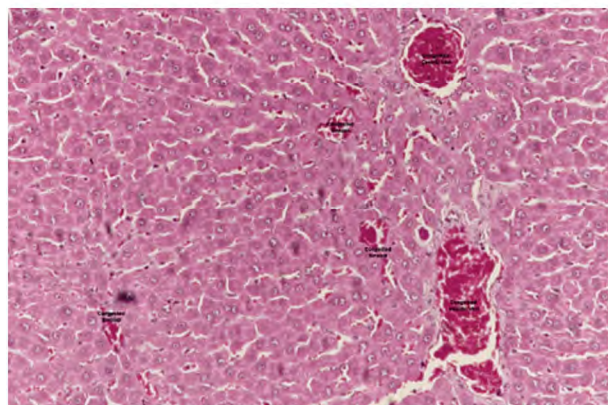


Fig. (2B): H & E section of liver tissues of an acutely stressed male rat showing preserved hepatic architecture, the sinusoids and central veins showed congestion. ( X20).

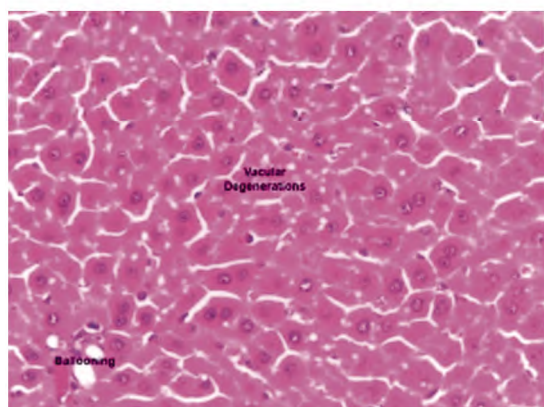


Fig. (2C): H & E section of liver tissues of an acutely stressed male rat showing preserved hepatic architecture, marked ballooning, and vacuolar degenerations ( X20).

Examination of H & E sections of liver tissues of the groups who lived under chronic stress conditions showed in general, preserved hepatic architecture. The hepatocytes showed ballooning (vacuolar degeneration), apoptosis, focal spotty necrosis, together with some binucleated cells. The

sinusoids & central vein showed congestion. The portal tracts appeared within normal. No evidence of dysplasia or malignancy was seen in the sections examined Fig. (3A,B).

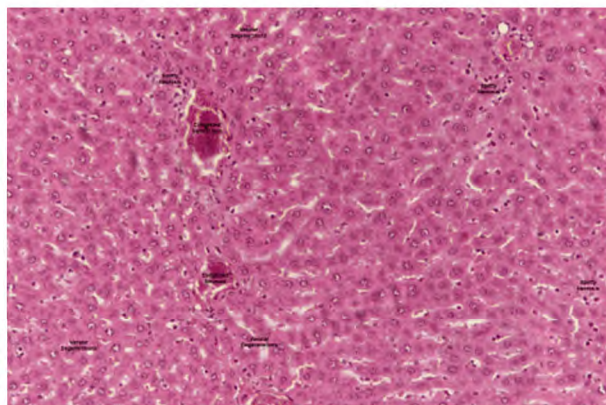


Fig. (3A): H & E section of liver tissues of a chronically stressed female rat showing preserved hepatic architecture. The hepatocytes showed focal spotty necrosis, vacuolar degenerations, and congested veins.

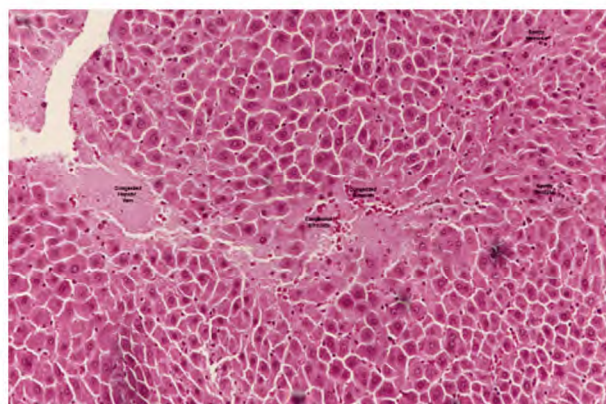


Fig. (3B): H & E section of liver tissues of a chronically stressed male rat showing preserved hepatic architecture. The hepatocytes showed focal spotty necrosis, vacuolar degenerations, and congested veins.

No obvious differences were noticed between examined male and female liver sections of all rats exposed to both acute and chronic stress.

### Discussion

This study used 48 Wistar mice as a surrogate for the assessment of the effect of stress on liver tissues. In this experiment, continuous room light exposure was used as acute stress for 3 weeks and as chronic stress for 3 months. All mice were anesthetized then their livers were removed and the mice were killed by euthanasia. Slides were prepared from the excised livers and stained by H & E and examined by light microscopy.

Alterations of the light/dark cycle can affect the norepinephrine quantities in tissues that receive sympathetic nerve supply. These alterations target the ventrolateral medulla and the superior cervical sympathetic ganglion causing hormonal release that results in sympathetic hyperactivity [11].

Fonken et al., 2014, reported that exposure of mice to light at night prevented weight gain by the animals [12]. Contrary to mice, continuous light may affect humans differently by increasing the tendency to weight gain and obesity due to disturbed food habits and increased intake such as night eaters [13] and late sleepers [14] who are examples. Further human studies showed that continuous bright light exposure day and night was insignificant on total energy expenditure [15]. The risk of developing type 2 diabetes and obesity in humans and experimental animals is linked with Melatonin disturbances by continuous light. It inhibits nocturnal melatonin release [16].

The continuous light is considered as a stressful stimulus and its deleterious effect on the liver may be supported by the theory of sympathetic nervous system overactivity. The examined liver tissues in this study showed congestive and degenerative changes both in acute and chronic stressed animals. It was noticed that those changes looked like pathological changes in stress models in experimental animals using chronic epinephrine injection for 4 weeks [17]. A stress model of foot shock for 3 weeks showed the same hepatic degenerative changes [18].

In contrary to other studies [19], this study showed no obvious differences between examined male and female liver sections of all rats exposed to both acute and chronic stress.

The histopathological changes in the liver parenchyma gave the impression of the picture of non-alcoholic fatty liver disease. Insulin resistance theory may be worked and caused the hepatic degenerative changes.

A limitation of this study was a short stress period as more stress time may show a clearer and evident advanced wide-spread steatosis. Besides, insulin resistance needs to be studied and investigated with this stress model.

In conclusion, the deleterious effects of the continuous light as a stress model on the liver parenchyma resembles some aspects of our recent modern lifestyles. Stress causes damage to our liver. Changing an unhealthy lifestyle into a healthy one that respects the well-studied effects of dis-

turbed chronobiology on our health is essential for a more healthy and prosperous life.

*Disclosure:* The author reports no conflicts of interest in this work.

## References

- 1- DAUCHY R.T., DAUCHY E.M., TIRRELL R.P., HILL C. R., DAVIDSON L.K., GREENE M.W., TIRRELL P.C., WU J., SAUER L.A. and BLASK D.E.: Dark-Phase light contamination disrupts circadian rhythms in plasma measures of endocrine physiology and metabolism in rats. *Comparative Medicine*, 60: 348-56, 2010.
- 2- BERSON D.M., DUNN F.A. and TAKAO M.: Phototransduction by retinal ganglion cells that set the circadian clock. *Science*, 1070-3, 2002.
- 3- FONKEN L.K., WORKMAN J.L., WALTON J.C., WEIL Z. M., MORRIS J.S., HAIM A., et al.: Light at night increases body mass by shifting the time of food intake. *Proc. Natl. Acad. Sci., USA*, 107 (43): 18664-423 18669, 2010.
- 4- BORNIGER J.C., WEIL Z.M., ZHANG N. and NELSON R. J.: Dim light at night does not disrupt timing or quality of sleep in mice. *Chronobiol Int.*, 30 (8): 1016-23. DOI: 10.3109/07420528.2013.803196, 2013.
- 5- KANG X.Z., JIA L.N., ZHANG X., LI Y.M., CHEN Y., SHEN X.Y. and WU, Y.C.: Long-Term Continuous Light Exposure Affects Body Weight and Blood Glucose Associated with Inflammation in Female Rats. *Journal of Biosciences and Medicines*, 4: 11-24, 2016.
- 6- BÁEZ-RUIZ A., GUERRERO-VARGAS N.N., CÁZAREZ-MÁRQUEZ F., SABATH E., DEL CARMEN BASUALDO M., SALGADO-DELGADO R., ESCOBAR C. and BUIJS R.M.: Food in synchrony with melatonin and corticosterone relieves constant light disturbed metabolism. *J. Endocrinol.*, 235: 167-78, 2017.
- 7- MUSTONEN A.M., NIEMINEN P. and HYVÄRINEN H.: Effects of continuous light and melatonin treatment on energy metabolism of the rat. *J. Endocrinol. Investig.*, 25: 716-23, 2002.
- 8- RUMANOVA V., S., OKULIAROVA M. and ZEMAN M.: Differential Effects of Constant Light and Dim Light at Night on the Circadian Control of Metabolism and Behavior. *Int. J. Mol. Sci.*, 21: 5478, 2020.
- 9- FUKUDA Y. and MORITA T.: Effects of the light-dark cycle on diurnal rhythms of diet-induced thermogenesis in humans, *Chronobiology International*, 34: 10, 1465-72, 2017.
- 10- GARZA K. and JOVANOVIĆ T.: Impact of Gender on Child and Adolescent PTSD. *Current Psychiatry Response*, Sep. 30, 19 (11): 87, 2017.
- 11- JING J.N., WU Z.T., LI M.L., WANG Y.K., TAN X. and WANG W.Z.: Constant Light Exerted detrimental Cardiovascular Effects Through Sympathetic Hyperactivity in Normal and Heart Failure Rats. *Front. Neurosci.*, 14: 248, 2020.
- 12- FONKEN L.K. and NELSON R.J.: The Effects of Light at Night on Circadian Clocks and Metabolism. *Endocrine Reviews*, 35: 648-70, 2014.

- 13- BENCA R., DUNCAN M.J., FRANK E., MCCLUNG C., NELSON R.J. and VICENTIC A.: Biological rhythms, higher brain function, and behavior: Gaps, opportunities, and challenges. *Brain Res. Rev.*, 62 (1): 57-70, 2009.
- 14- FUNG T.T., HU F.B., YU J., CHU N.F., SPIEGELMAN D., TOFLER G.H., et al.: Leisure-Time Physical Activity, Television Watching, and Plasma Biomarkers of Obesity and Cardiovascular Disease Risk. *American Journal of Epidemiology*, 152 (12): 1171-8, 2000.
- 15- MELANSON E.L., RITCHIE H.K., DEAR T.B., CATE-NACCI V., SHEA K., CONNICK E., et al.: Daytime bright light exposure, metabolism, and individual differences in wake and sleep energy expenditure during circadian entrainment and misalignment. *Neurobiology of sleep and circadian rhythms*, 4: 49-56, 2018.
- 16- BRAINARD G.C., ROLLAG M.D. and HANIFIN J.P.: Photic regulation of melatonin in humans: Ocular and 397 neural signal transduction. *J. Biol. Rhythms.*, 12 (6): 537-46, 1997.
- 17- KUMAR R., KUMAR S., ALI M., KUMAR A., NATH A., LAWRENCE K., et al.: Impact of Stress on Histology and Biochemical Parameters of Liver and Kidney of Mice. *Innovative Journal of Medical and Health Science*, 2 (4): 63-6, 2012.
- 18- PRAKASH BABU B., HEMALATHA B. and HENRY T.: Effect of stress induced by exposure to short and long term foot shock on liver, spleen and kidney in aged mice. *Journal of the Anatomical Society of India*, 67 (2): 148-52, 2018.
- 19- THOMÀS-MOYÀ E., GÓMEZ-PÉREZ Y., FIOLE M., GIANOTTI M., LLADÓ I. and PROENZA A.: Gender related differences in paraoxonase 1 response to high-fat diet-induced oxidative stress. *Obesity*, Oct., 16 (10): 2232-8, 2008.

## تأثير التوترب باستخدام التعرض للضوء المستمر على خلايا الكبد في ذكور وإناث فئران ويستار

خلفية البحث: عديد من أنماط الحياة الحديثة غير صحية ويمكن أن تؤثر سلباً على صحتنا. أظهرت العديد من الدراسات أن الإجهاد تسبب في إحداث تأثير واضح على بنية أجهزة الجسم المختلفة. الكبد هو أحد أعضاء الجسم التي يمكن أن تتأثر بشدة بالتوتر. يمكن للكبد أن يتحمل الإجهاد لفترات أطول وتظهر عليه علامات التلف في وقت متأخر جداً على الرغم من أنه يمكن إكتشاف التغيرات الهيكلية في وقت مبكر جداً.

الهدف من الدراسة: فحص التأثير الحاد والمزمن للضغوط الحادة والمزمنة بالتعرض المستمر للضوء على بنية أنسجة الكبد.

المواد والأساليب: استخدمت هذه الدراسة ٤٨ من ذكور وإناث جرذان ويستار (٢٥٠-٣٠٠ جم) في ٦ مجموعات ثمانية في كل مجموعة.

المجموعة الأولى عبارة عن ذكور تتعرض طبيعياً للضوء/الظلام. المجموعة الثانية عبارة عن إناث تتعرض للضوء الطبيعي/الظلام. المجموعة الثالثة ذكور تتعرض لضوء مستمر لمدة ٣ أسابيع كنموذج ضغط حاد. المجموعة الرابعة إناث تتعرض للضوء المستمر لمدة ٣ أسابيع كنموذج ضغط حاد. المجموعة الخامسة ذكور تتعرض لضوء مستمر لمدة ٣ أشهر كنموذج ضغط مزمن. المجموعة السادسة إناث تتعرض لضوء مستمر لمدة ثلاثة أشهر كنموذج ضغط مزمن.

النتائج: أظهرت نتائج فحص أنسجة الكبد للمجموعات التي عاشت تحت ضغط حاد بشكل عام، بنية كبدية محفوظة وأظهرت خلايا الكبد تضخماً ملحوظاً (تحلل فجوى) وأظهرت الجيوب الوريدية والأوردة المركزية إحتقاناً. وأظهرت أنسجة الكبد للمجموعات التي عاشت تحت ظروف إجهاد مزمنة بشكل عام بنية كبدية محفوظة وأظهرت الخلايا الكبدية تضخماً (تحلل فجوى)، ونخر متقطع بؤرى، مع بعض الخلايا ثنائية النوى. كما أظهر الجيوب الوريدية والوريد المركزي إحتقاناً ملحوظاً.

الخلاصة: استخدمت هذه الدراسة ٤٨ فأراً من نوع Wistar كنموذج لتقييم تأثير الإجهاد والضغط على أنسجة الكبد. تم استخدام التعرض المستمر للضوء كضغط حاد لمدة ٣ أسابيع وإجهاد مزمن لمدة ٣ أشهر. وأظهرت الدراسة التأثير المجهد وتأثيره الضار على الكبد من خلال نظرية فرط نشاط الجهاز العصبي الودي. أظهرت أنسجة الكبد التي تم فحصها في هذه الدراسة تغيرات إحتقانية وتكسية في كل الحيوانات المجهدة سواءً في الإجهاد الحاد أو المزمن.

يعد تغيير أنماط الحياة الحديثة إلى أسلوب يحترم التسلسل الزمني الطبيعي أمراً مهماً لرفاهيتنا.