

Dural Fenestrations versus Duraplasty in Traumatic Acute Subdural Hematoma

MOHAMED G. ABDEL TAWAB, M.D.

The Department of Neurosurgery, Faculty of Medicine, Fayoum University, Egypt

Abstract

Background: Patients with Acute Subdural Hematomas (ASDHs) have higher mortality and lower functional recovery rates compared with those of other head-injured patients. The optimal surgical management of traumatic (ASDHs) is controversial.

Aim of Study: Is to compare results of (ASDHs) managed with: Group (A) dural fenestrations (multiple fenestrations of the dura in a meshlike fashion and removing clots through the small dural openings that are left open, short operative time, minimal manipulations of the brain. Group (B) duraplasty (by pericranium or fascia lata graft and close dura after evacuation of hematoma long operative time, more manipulations of the brain.

Patients and Methods: A retrospective review of 81 patients with traumatic ASDH were operated at the Departments of Neurosurgery at Cairo and Fayoum Universities during the period from 2012-2015. These patients are divided into two groups: Group (A) 55 patients operated with dural fenestrations, (50 males and 5 females) median age 41 years old. On admission there were 32 patients with Glasgow Coma Scale (GCS) scores of 3 to 5, 21 patients with GCS scores of 6 to 8, and 2 patients with GCS scores of 9 to 12. Operative time average 120 minutes. Group (B) 26 patients operated with duraplasty, (22 males and 4 females) median age 44 years old. On admission there were 19 patients with Glasgow Coma Scale (GCS) scores of 3 to 5, 6 patients with GCS scores of 6 to 8, and one patient with GCS scores of 9 to 12. Operative time average 180 minutes. Early surgical evacuation, decompression craniotomy, intensive care management to monitor intracranial pressure and follow-up Computed Tomography (CT) of the brain are done for all patients.

Results: Group (A): 20 patient died in the hospital, 16 survived with unfavorable outcome, and 19 survived with favorable outcome. Group (B): 15 patient died in the hospital, 6 survived with unfavorable outcome, and 5 survived with favorable outcome.

Conclusions: The present analysis of the data reveals that dural fenestrations show good prognosis in decompressive craniectomy regarding short operative time, minimal brain manipulations compared to duraplasty, which appear in a

Correspondence to: Dr. Mohamed G. Abdel Tawab, The Department of Neurosurgery, Faculty of Medicine, Fayoum University, Egypt

significant low morbidity, good survival with unfavorable outcome and good survival with favorable outcome.

Key Words: Acute subdural hematoma (ASDH) – Dural fenestrations – Duraplasty – Glasgow coma scale.

Introduction

ACUTE Subdural Hematoma (ASDH) can be found in one third of patients with severe Traumatic Brain Injury (TBI). ASDHs arise from tearing of bridging veins or arterial rupture [1]. It might also be associated with rupture of dural sinuses or superior cortical arteries. The mortality rate of traumatic ASDHs is estimated as high as 60% [2].

ASDHs are usually noticed in younger ages compared to spontaneous category but the incidence of ASDHs rises with simple head trauma in the elderly patients [3].

Current literature includes well-established surgical guidelines for decompression of ASDH: A thickness greater than 10mm and/or midline shift greater than 5mm on CT scan in subdural hematoma patients should be surgically evacuated regardless of patient's Glasgow Coma Scale score [4].

Decompressive craniectomy entails removal of skull bone flap and evacuation of ASDH to allow for possible expansion of acute brain swelling [5].

In the present study, we aim to compare the efficacy and prognosis of two modalities of dural expansion to gain extraspaces for the associated increased intracranial pressure.

Patients and Methods

Between 2012 and 2015, 81 patients with ASDH (proved by CT) of both genders and age groups from 2nd to the 7th decades were retrospectively analysed at the Departments of Neurosurgery at Cairo and Fayoum Universities in Egypt.

Age, sex, mode of trauma, thickness of hematoma, concomitant pathologies, and GCS score on admission and after discharge were carefully investigated.

All patients were received at emergency room within 6 hours following trauma. Immediate resuscitation followed non-contrast CT brain with bone window. All patients were subjected to thorough history taking from companions and were clinically examined. Complete laboratory work-up was routinely carried out. CT brain was done for all cases.

We included all patients with isolated head trauma. We excluded patients associated with systemic injury that might affect prognosis of traumatic subdural hematoma. Patients with spontaneous (non-traumatic) ASDH on anticoagulants were excluded from the study.

Patients were classified into two groups. Group (A): 55 patients operated upon with dural fenestrations and Group (B); 26 patients operated with duraplasty.

Surgical technique:

Operations were routinely performed under general anaesthesia in all cases. CT brain was used for diagnosis and post-operative assessment. Group (A) operated with dural fenestrations in a mesh like fashion after decompressive craniectomy (frontotemporoparietal). A no. 15 scalpel is used to apply multiple linear dural incisions multiple fen-

estrations of the dura in a meshlike fashion of about 5-8mm long, in horizontal lines, parallel to vessels and 2-2.5cms apart from each other. Blood clots are evacuated through the small dural openings with a 6F nelaton catheter and normal saline washing. Active cortical bleeding usually stops with continuous saline washes but it is mandatory to locate the site of bleeding for proper hemostasis through widening of one dural incision. Decompressive craniectomy with evacuation of the hematoma and widening of the dura participated in a significant decrease of intracranial pressure Fig. (1A).

Group (B): After decompressive craniectomy, dura opened circum-ferentially, hematoma evacuated through saline washing, proper hemostasis was achieved and dura was widened by a pericranium or fascia lata graft that was stitched to the dura Fig. (1B).

Bone flaps were implanted in the abdominal fat for about 3 months for re-implantation.

Post-operatively all patients were monitored carefully in the Surgical Intensive Care Unit, serial CT scans were performed to assess complete evacuation of the hematoma, improvement of midline shift and adequacy of extraspaces for the oedematous brain. Outcome was assessed by monitoring of GCS score post-operatively, at time of discharge and one month later.

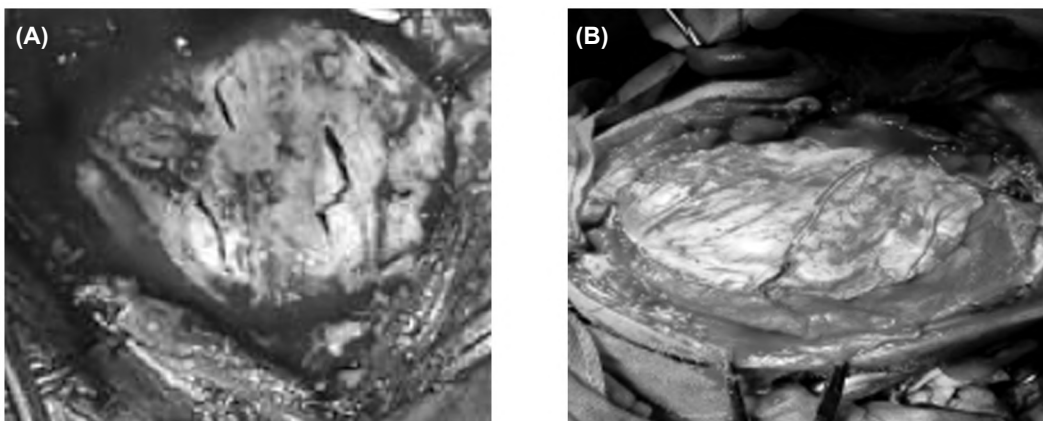


Fig. (1): Different surgical techniques, (A) Dural fenestration, (B) Duraplasty.

Statistical analysis:

Data were gathered and coded to make manipulation of data easier and were double entered into Microsoft Access and data analysis was performed using Statistical Package of Social Science (SPSS) software version 18 in windows 7. Qualitative data were analysed in a simple descriptive way in the form of numbers and percentages, and quantitative

parametric data were analysed by arithmetic means as central tendency measurement, standard deviations as measure of dispersion.

Sampling:

The sample size was carefully calculated according to Epi Info 2000. The sample size was chosen using a particular formula based on the

prevalence of disease at a confidence interval of 95% and precision of (2%). The sample increased by 10% to avoid problems related to non-responses and missing data. The power of study was 80%.

Ethical approval:

The study was approved by the scientific Research Ethical Committee at our University Hospital after ensuring the ethical standards and scientific merit of research involving our patients and was matched with the 1964 Helsinki Declaration and its later amendments.

Consenting:

Written consents were obtained from the patients and/or their family relatives after discussing with them; the details of surgery, the probable outcome, the complications, and the possibility of recurrence and re-operation.

Results

On comparing the demographic characteristics of the patients in both study groups, in group (A), the age ranged between 18 to 64 years and the mean age was 41 years old. Group (B) had patients with age ranged between 21 to 67 years and the mean age was 44 years old.

In group (A), 39 patient (70%) was below 40 years old while 11 patients (20%) were between 40-60 years old, 5 patients of them (10%) were over 60 years old. In group (B), 17 patients (65%) were below 40 years old while 7 patients (26.9%) were between 40-60 years old, 2 patients of them (7.7%) were above 60 years old. Most patients (>65%) were in the age group of <40 years from both study groups. Males constitute more than 84% of both study groups (Table 1).

There was no statistically significant difference with *p*-value >0.05 between study groups regarding age and sex distribution which indicated proper matching between the groups.

Table (1): Demographic characters in different study groups.

	Group A (n=55)	Group A (n=26)
<40 years	39 (70%)	17 (65%)
Between 40-60 years	11 (20%)	7 (26.9%)
>60 years	5 (10%)	2 (7.7%)

Regarding the mode of trauma, we found that the motor vehicle accident was the most common aetiology (>60%) in both study groups. We experienced additional pathologies in all patients in both study groups. The most common of which

were traumatic Subarachnoid Hemorrhage (SAH) and cerebral contusions (Table 2). There was no statistically significant difference with *p*-value >0.05 between study groups regarding the mode of trauma and the presense of additional pathologies.

Table (2): Mode of trauma and additional pathologies in different study groups.

	Group A (n=55)	Group A (n=26)
<i>Mode of trauma:</i>		
Motor vehicle accident	35 (63.6%)	17 (65.4%)
Fall from height	13 (23.6%)	6 (23.1%)
Isolated head trauma	7 (12.7%)	3 (11.5%)
<i>Additional pathologies:</i>		
SAH	21 (38.2%)	11 (42.3%)
Contusions	16 (29.1%)	7 (26.9%)
Fracture	11 (20%)	5 (19.2%)
Depression fracture	4 (7.3%)	2 (7.7%)
Extradural hematoma	3 (5.4%)	1 (3.8%)

In group (A) on admission there were 32 patients (58.2%) with GCS scores of 3-5, 21 patients (38.2%) with GCS scores of 6-8, and two patients (3.6%) with GCS scores of 9-12. In group (B) on admission there were 19 patients (73.1%) with GCS scores of 3-5, 6 patients (23.1%) with GCS scores of 6-8, and one patient (3.8%) with GCS scores of 9-12 (Table 3).

Table (3): GCS data in different study groups.

	Group A (n=55)	Group A (n=26)
(GCS) 3 to 5	32 (58.2%)	19 (73.1%)
GCS 6 to 8	21 (38.2%)	6 (23.1%)
GCS 9 to 12	2 (3.6%)	1 (3.8%)

All patients reached to our Emergency Department within 6 hours of the time of injury. Unilateral frontotemporoparietal decompressive craniectomy was performed in all patients from both study groups. The mean thickness of hematoma was 18.2 ±6mm.

On comparing the length of the operative procedure, we found that in group A average operative time was 120 minutes while in group (B) average operative time was 180 minutes which proved to be statistically significant with *p*-value <0.05.

While comparing the outcome between both groups we found that in group (A): 20 patient (36.4%) died in the hospital, 16 (29.1%) survived with unfavorable outcome, and 19 (34.5%) survived with favorable outcome. This proved effective when compared to group (B) where 15 patient (57.7%) died in the hospital, 6 (23.1%) survived

with unfavorable outcome, and 5 (19.2%) survived with favorable outcome (Table 4). These results proved to be statistically significant with p -value <0.05 .

Table (4): Outcome data in different study groups.

	Group A (n=55)	Group A (n=26)
Died	20 (36.4 %)	15 (57.7 %)
Unfavourable outcome	16 (29.1 %)	6 (23.1 %)
Favourable outcome	19 (34.5 %)	5 (19.2 %)

Post-operative complications as wound infection, seizures, hydrocephalus (in most of the surviving patients in both groups), hygromas were related to primary trauma, rather than, the decompression procedures. These were managed carefully without causing any mortalities.

Discussion

Despite the developments in neurosurgery, ASDH remains a clinical entity with increased morbidity and mortality. Optimum clinical outcome requires urgent intervention [6,7]. It presents in approximately 30% of patients with severe head trauma [8].

Various surgical modality such as burr-hole evacuation, craniotomy, and DC are used for evacuation of ASDH. On the brain trauma foundation guidelines published in 2006, they recommended that ASDH with thickness greater than 10mm, or midline shifting greater than 5mm on CT scan should be treated surgically [9]. The aim of craniectomy was to provide sufficient space for brain relaxation and to prevent herniation.

Primary brain damage consisting of contusions and brain swelling accounts for the high mortality of ASDH. It is caused mainly by secondary brain insult in addition to parenchymal damage even when treated with early surgical evacuation [10].

According to experience and preference of the surgeons in our departments, 2 different surgical procedures were performed on 81 patients during the period from 2012 to 2015 in our departments.

Hyder et al., demonstrated that traumatic ASDH has an important role on the mortality under the age of 45 [11]. Ryan et al., reported that 63% of traumatic ASDH patients were males and the mean age of the study population was 58 years [12]. This matches our study as we have more than 84% male and mean age of 41 and 44 years in both groups respectively.

Sawauchi et al., [10]. Reported a poor outcome of ASDH associated with brain swelling even when they were treated with early surgical evacuation. The mortality rate of such patients was over 75%. In our study we have near results to that in the duraplasty group about 57.7% but we have got better results in the dural fenestration group with mortality of 36.4%, a favourable outcome of 34.5% and overall survival of 63.6% [10].

Seelig et al., reported better outcomes when patients operated early after accident with a mortality rate of 30% when operated within one hour following trauma and 90% mortality rate when operated after 4 hours of trauma [13]. In our study, although all patients received within 6 hours of trauma, we found a lower mortality (36.4%) within the dural fenestration group.

We found another advantage of the dural fenestration group with average operative time 120 minutes compared to average 180 minutes in the duraplasty group which makes the surgical technique easy and safe with minimal brain manipulations.

Associated secondary insults like brain contusions, brain oedema and subarachnoid haemorrhages were treated conservatively, all patients were followed-up for one month post-operatively.

Conclusion:

Acute Subdural Hematoma (ASDH) is a disease with increased morbidity and mortality despite the advances in neurosurgery and urgent intervention is obviously necessary for a perfect clinical outcome. Decompressive craniotomy with dural fenestrations show good prognosis as regards time saving and minimal brain manipulations compared to duraplasty, with a good and significant low morbidity, good survival with unfavorable outcome and good survival with favorable outcome.

References

- 1- YANAKA K., KAMEZAKI T., YAMADA T., TAKANO S., MEGURO K. and NOSE T.: Acute subdural hematoma-prediction of outcome with a linear discriminant function. *Neurol. Med. Chir. (Tokyo)*, 33: 552-8, 1993.
- 2- BUSL K.M. and PRABHAKARAN S.: Predictors of mortality in non traumatic subdural hematoma. *J. Neurosurg.*, 119 (5): 1296-301, 2013.
- 3- EL-FIKI M.: Acute traumatic subdural hematoma outcome in patients older than 65 years. *World Neurosurg.*, 78 (3-4): 228-30, 2012.
- 4- BULLOCK M.R., CHESNUT R., GHAJAR J., et al.: Surgical management of traumatic brain injury author group. *Surgical management of acute subdural hematomas. Neurosurgery*, 58 (3 Suppl): S16-S24, 2006.

- 5- CHATURVEDI J., BOTTA R., PRABHURAJ A.R., SHUKLA D., BHAT D.I. and DEVI B.I.: Complications of cranioplasty after decompressive craniectomy for traumatic brain injury. Br. J. Neurosurg., 17: 1-5, 2015.
- 6- GODLEWSKI B., PAWELCZYK A., PAWELCZYK T., CERANOWICZ K., WOJDYN M. and RADEK M.: Retrospective analysis of operative treatment of a series of 100 patients with subdural hematoma. Neurol. Med. Chir. (Tokyo), 53 (1): 26-33, 2013.
- 7- YILDIRIM H., OZTURK T. and ESEN M.: Akut subdural hematomun spontan rezolüsyon ve redüştürbüsyonu: BT ve MR bulguları. Firat. Tıp. Dergisi., 16 (3): 137-40, 2011 (In Turkish).
- 8- YANAKA K., KAMEZAKI T., YAMADA T., TAKANO S., MEGURO K. and NOSE T.: Acute subdural hematoma-prediction of outcome with a linear discriminant function. Neurol. Med. Chir. (Tokyo), 33: 552-8, 1993.
- 9- BULLOCK M.R., CHESNUT R., GHAJAR J., GORDON D., HARTL R., NEWELL D.W., et al.: Surgical management of acute subdural hematomas. Neurosurgery, 58 (3 Suppl): S16-S24; discussion Si-Siv, 2006.
- 10- SAWAUCHI S. and ABE T.: The effect of haematoma, brain injury and secondary insult on brain swelling in traumatic acute subdural haemorrhage. Acta Neurochirurgica, 150 (6): 531-6, 2008.
- 11- HYDER A.A., WUNDERLICH C.A., PUVANACHANDRA P., GURURAJ G. and KOBUSINGYE O.C.: The impact of traumatic brain injuries: A global perspective. Neuro. Rehabilitation, 22: 341-53, 2007.
- 12- RYAN C.G., THOMPSON R.E., TEMKIN N.R., CRANE P. K., ELLENBOGEN R.G. and ELMORE J.G.: Acute traumatic subdural hematoma: Current mortality and functional outcomes in adult patients at a Level I trauma center. J. Trauma Acute Care Surg., 73 (5): 1348-54, 2012.
- 13- SEELIG J.M., BECKER D.P., MILLER J.D., GREENBERG R.P., WARD J.D. and CHOI S.C.: Traumatic acute subdural hematoma: Major mortality reduction in comatose patients treated within four hours. New England Journal of Medicine, 304 (25): 1511-8, 1981.

نوفذة غشاء الأم الجافية مقابل رتقها في حالات إصابات نزيف تحت الأم الجافية الحاد للمخ

نزيف تحت الأم الجافية الحاد هو من أخطر أنواع النزيف التي تصيب المخ. يحمل هذا النوع من النزيف خطورة كبيرة على حياة المريض كما يحمل تهديداً لكفاءة الحالة الوظيفية للمرضى الآخرين بعد التعافي بالمقارنة بكثير من حالات نزيف المخ الأخرى الناتجة عن إصابات تصادم. توجد طرق كثيرة للجراحة مع وجود اختلاف على أفضل طريقة للعلاج. لقد خلصت هذه الدراسة إلى أن نوفذة الأم الجافية Fenestrations Dural تعطى نتائج أفضل من رتقها Duraplasty مع توسيع الجمجمة وتفريغ النزيف من حيث أنها تختصر وقت الجراحة وتقلل من حدوث أى إصابات أخرى قد تحدث للمخ بسبب طول مدة الجراحة وذا إنعكس على النتائج التي أظهرت إنخفاض ملحوظ في عدد الوفيات وتحسن في جودة الحالة الوظيفية للمرضى الآخرين.