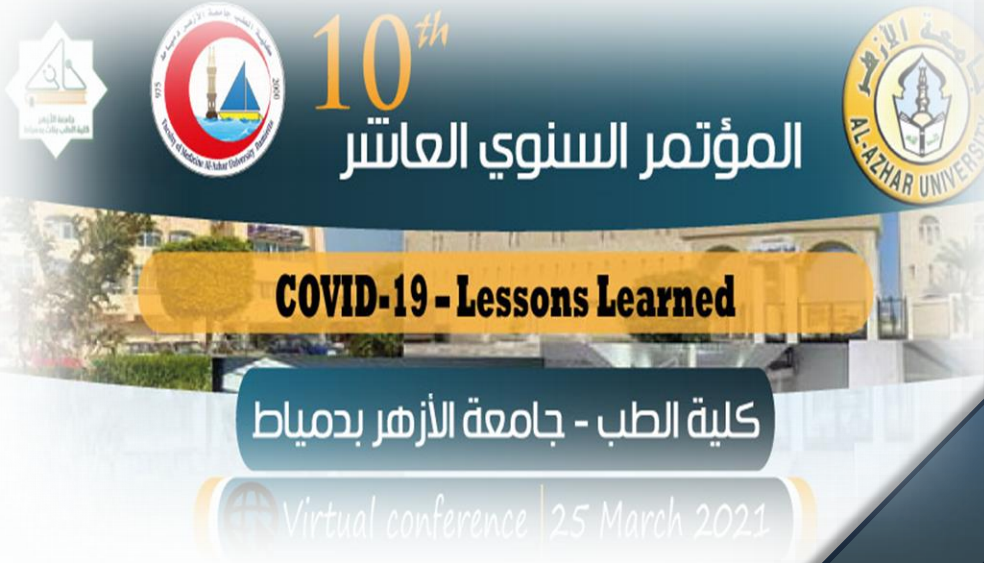

# IJMA



## INTERNATIONAL JOURNAL OF MEDICAL ARTS

*Volume 3, Issue 2 [Spring (April-June) 2021]*



<http://ijma.journals.ekb.eg/>

Print ISSN: 2636-4174

Online ISSN: 2682-3780

## About IJMA [last updated March, 1<sup>st</sup>, 2021]

- ✓ International Journal of Medical Arts is the Official Journal of the Damietta Faculty of Medicine, Al-Azhar University, Egypt
- ✓ It is an International, Open Access, Double-blind, Peer-reviewed Journal
- ✓ Published four times a year
- ✓ The First Issue was published in July 2019
- ✓ Published under the following license: Creative Commons Attribution-ShareAlike 4.0 International Public License (CC BY-SA 4.0). It had updated from the Creative Commons license [CC BY] in volume 2, Issue 4, October 2020 About IJMA
- ✓ The Egyptian Knowledge Bank hosts the web site of IJMA
- ✓ The Egyptian Knowledge Bank supports IJMA
- ✓ IJMA follows the regulations of the International Committee of Medical Journal Editors
- ✓ IJMA is indexed in the "Directory of Open Access Journals" [Indexed on 15 January 2021].
- ✓ IJMA is a member of the International Society of Managing and Technical Editors
- ✓ Listed in "Index Copernicus", "Publons", "Academic resource index [ResearchBib]", "Electronics journal library", "Eurasian Scientific Journal Index", and "Citefactor"
- ✓ IJMA introduced to the search engine [BASE] through DOAJ

Click image to reach the page



Egyptian Knowledge Bank

DOAJ



INDEX COPERNICUS  
INTERNATIONAL



ESJI Eurasian Scientific Journal Index  
www.ESJIndex.org





Available online at Journal Website  
<https://ijma.journals.ekb.eg/>  
Main subject [Orthopedic Surgery]\*



## Original Article

# Clinical Outcomes of Plate Fixation Compared with Non-operative Treatment of Displaced Mid-shaft Clavicular Fractures in Adults

Mahmoud Mohamed Sherif <sup>[1]</sup>; Osman Abdellah Mohamed <sup>[2]</sup>; Mohamed Abdalah Hassan <sup>[2]</sup>

Department of Orthopedic Surgery, Al-mahalla General Hospital, Ministry of Health, Egypt <sup>[1]</sup>  
Department of Orthopedic Surgery, Damietta Faculty of Medicine, Al-Azhar University, Egypt <sup>[2]</sup>

Corresponding author: Mahmoud Mohamed Sherif  
Email: [mahmoudsherif5398@gmail.com](mailto:mahmoudsherif5398@gmail.com)

Submission date: December 20, 2020; Revision date: March 07, 2021; Acceptance date: March 10, 2021

DOI: [10.21608/ijma.2021.54224.1227](https://doi.org/10.21608/ijma.2021.54224.1227)



DOAJ

## ABSTRACT

**Background:** Clavicle fractures are representing 2.6% of total body fractures. The common fracture is the midshaft fracture of the clavicle. The outcomes of non-operative treatment are not preferred nowadays, so the trend to surgical treatment of these fractures has grown.

**The aim of the work:** The current study aimed to compare the outcomes of conservative and operative treatment of displaced midshaft clavicular fractures with plate fixation to clarify the merits and possible disadvantages of each method.

**Patients and Methods:** Twenty patients as a convenient sample were included. These patients were subdivided into two groups, group I for conservative treatment and group II for operative treatment with plate fixation. All patients will be subjected to complete history taking, clinical, general & local examination, a standard anteroposterior view of the clavicle was done and follow up average 6 months.

**Results:** At the end of follow up period, according to Constant Shoulder Score (CSS), 11 patients had excellent results (CSS: < 11), 4 patients had good results (CSS: 11-20), 3 patients had fair results (CSS: 21-30), 2 patients had poor results (CSS: >30). Pain VAS was significantly higher in group I compared with group II. There is a significant difference found between the groups as regard (outcome, pain VAS, the strength of abduction and the extent of internal rotation) P value < 0.05. There is no significant difference found between the groups as regard (socio-demographic data, comorbidities, fracture characteristics, fractures classification, degree of forward flexion, degree of lateral elevation and extent of lateral rotation) P value > 0.05.

**Conclusion:** Operative treatment with plate fixation is better than conservative treatment in management of pain, high union rate, good functional outcomes and greater patients satisfactory after displaced mid shaft clavicular fractures.

**Keywords:** Clavicle; Displaced; Midshaft Fracture; Conservative; Plate Fixation

This is an open-access article registered under the Creative Commons, ShareAlike 4.0 International license [CC BY-SA 4.0] [<https://creativecommons.org/licenses/by-sa/4.0/legalcode>].

**Citation:** Sherif MM, Mohamed OA, Hassan MA. Clinical Outcomes of Plate Fixation Compared with Non-operative Treatment of Displaced Mid-shaft Clavicular Fractures in Adults. IJMA 2021; 3[2]: 1351-1358. DOI: [10.21608/ijma.2021.54224.1227](https://doi.org/10.21608/ijma.2021.54224.1227)

\* Main subject and any subcategories have been classified according to the research topic.

## INTRODUCTION

Clavicular fractures constitute about 4% of all fractures. They are commonly encountered as fractures of the midshaft about 76% of all clavicle fractures in one large series [1].

In the elderly, clavicular fractures are primarily occurring in females, caused by a low-energy mechanism of injury such as a fall from a standing height. In the young, fractures of the clavicle are found predominantly in males and are secondary to a high energy direct trauma sustained in sports, a motor car crash [1,2].

The clavicle has peculiar anatomic features, it is S-shaped with a wide medial end convex forward and a thin lateral end concave forward, both medial and lateral ends are flattened. Middle third fractures account for 80% of all clavicle fractures. Fracture clavicle according to Allman classification is divided into three groups. Group I, fracture of middle third (80%) which is sub classified into two types either incomplete or complete displacement. Group II, fracture of the distal third (15%). Group III, fracture of the proximal third (5%) [3].

There has been a trend in the past few years to increase operative treatment. As this injury usually affects young, active patients, the objective of the treatment is to obtain early union and subsequently a rapid return to prior function. Favorable results with surgical treatment for middle-third clavicle fractures have been reported [4].

## AIM OF THE WORK

This study aimed to compare clinical outcomes of conservative and operative treatment with plate fixation of displaced mid shaft clavicular fracture.

## PATIENTS AND METHODS

This prospective study was carried out on 20 adult patients, who have displaced midshaft clavicular fracture. These patients were divided into: group I, for conservative treatment by standard sling immobilization for six weeks, and group II for operative treatment with plate fixation. This was achieved at the Orthopedic Department [Al-Azhar University Hospital,

Damietta] and Al-mahalla General Hospital, from December 2019 to September 2020.

**Inclusion criteria** were adult patients age more than 18 years old; displaced midshaft clavicular fractures (simple or wedge comminuted (Type 2 B1) and isolated or comminuted segmental (Type 2B2) according to Robinson's classification; no medical contraindications to general anesthesia, and displaced fractures. On the other side, the **exclusion criteria** were fractures involving the proximal or distal third of the clavicle; pathological fractures; associated neurovascular injury, or open fracture.

## Surgical technique of plate fixation [Figure 1]:

Surgery was completed under general anesthesia; the patient was placed in semi-setting position with a small pad behind the shoulder. The entire shoulder girdle, including the sternum was prepared and draped so that the upper extremity can be used to mobilize the lateral fragment to help in reduction [5].

The proximal and distal parts of the clavicle are marked on the skin and an incision is made over the fracture site. An oblique incision is made along the upper surface of the clavicle. The skin and subcutaneous tissues were incised and reflected upward permitting identification of the underlying myofascia, protecting any obvious cutaneous nerve branches and reflected upward. This layer, showing the deltopectoral muscle attachment was raised as contiguous flaps and was preserved so that a two-layers are closed and were achieved over the plate [6].

Next, the fracture site was identified by full exposure of the proximal and distal fragments. The fracture ends were reduced with reduction forceps, and the clavicle was realigned. Butterfly fragment was fixed by inter-fragmentary screws either separately or passed through the plate [7].

With the fracture reduced, the fracture was temporarily fixed with 2.0 mm Kirschner wire applied perpendicular to the fracture line. The plate was applied to the clavicle and was secured to the medial and lateral fragments with bone reduction forceps; the plate was bent to follow the contour of the clavicle. A drill-and-tap preparation sized to the screw was then used to fix the plate to the clavicle. A minimum of three

screws were placed on either side of the fracture such that purchase was achieved through all six cortices of bone [8].

is irrigated with normal saline. Then the standard closure is performed for myofascia and subcutaneous tissue and then the skin is closed by non-absorbable sutures [8]. The arm is placed in a sling after surgery [8].

Once all of the screws have been inserted, the field

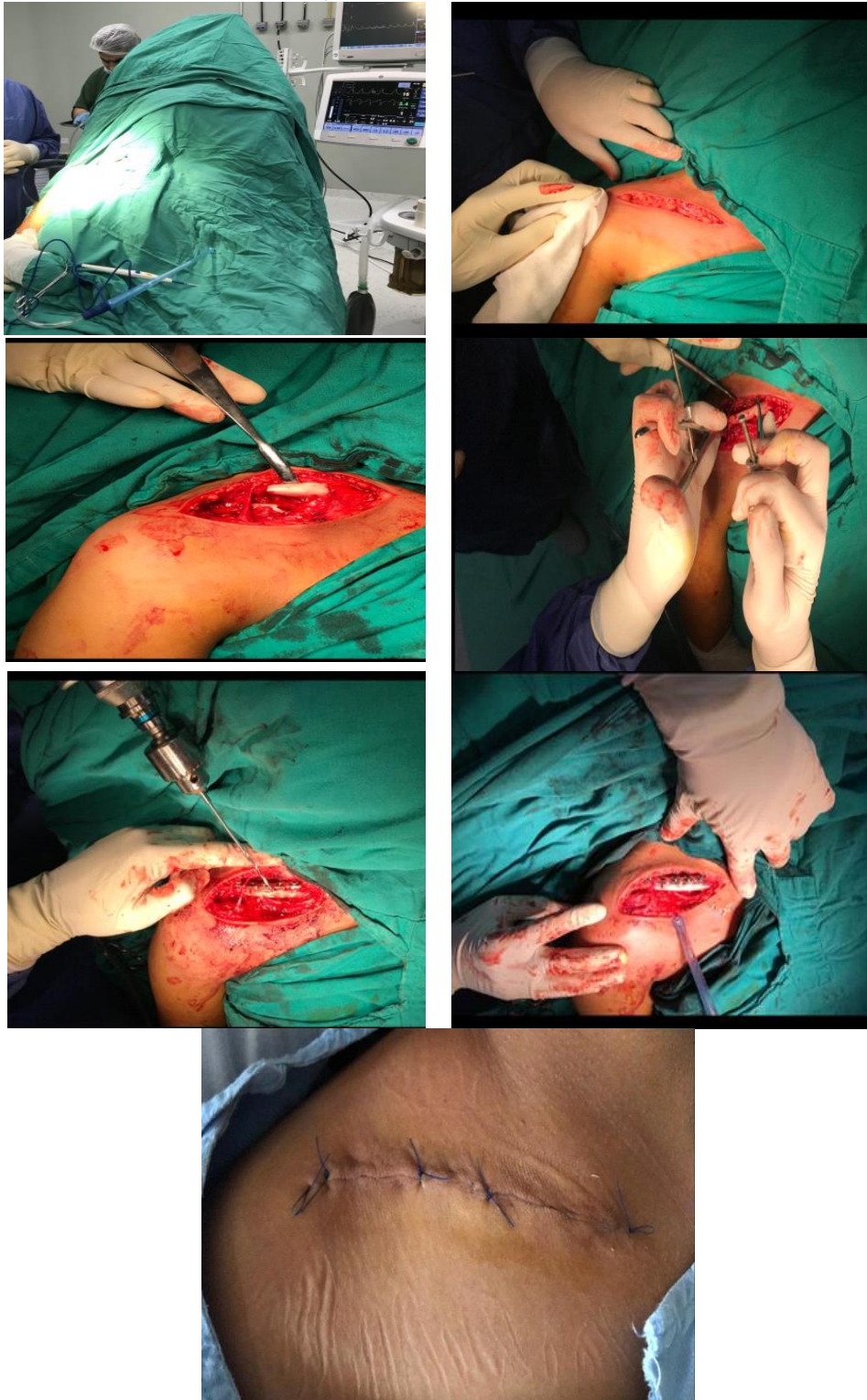

Figure (1): Steps of surgical technique

### Postoperative management and rehabilitation:

The postoperative x-ray included not only the fracture site and internal fixation [to verify fracture alignment and hardware placement], and the lung to make sure that no injury has occurred during surgery. When comfortable, the patient was discharged from the hospital and wound care continued until the removal of the sutures at the 2<sup>nd</sup> week post-operative visit [9].

Early postoperative isometric exercises for the rotator cuff were initiated; but isometric strengthening of the trapezius and deltoid muscles was delayed until their suture junction was healed securely (3 to 4 weeks). Range of motion after surgery was not permitted past 45° of flexion in the plane of the scapula until there were clinical signs of the union, usually at 4 to 6 weeks [10].

When clinical or radiographic union was present, the patient had the choice to start a full range of motion, particularly forward elevation (using an overhead pulley) and external rotation (using a cane or stick). Hyperextension-internal rotation can also be added. Resistive exercises of the deltoid, cuff, trapezius, and scapular muscles were introduced gradually to the rehabilitation program. When radiographic union was present, full active use of the arm was permitted. The patient was not permitted to return to full, strenuous work or athletic activities until there was a nearly full range of shoulder motion, and the strength had returned to the near normal [11].

### Methods of patient assessment:

The functional outcome was assessed using the Constant Shoulder Score (CSS) [12] adopted by the European Society for Shoulder and Elbow Surgery (ESSES). This scoring system consists of four variables that were used to assess each shoulder separately. The subjective variables are pain and ADL (sleep, work, recreation / sport) which give a total of 35 points. The objective variables were the range of motion and the strength which give a total of 65 points.

### Grading of the Constant Shoulder Score:

A difference between normal and abnormal side more than 30 was considered "poor", from 21-30 was considered "fair", from 11-20 was considered "good"

and less than 11 was considered "excellent" Constant Shoulder Score [12].

### Statistical Analysis

All data were collected, tabulated and statistically analyzed by SPSS (Statistical package for the social sciences) 22.0 for windows (SPSS Inc., Chicago, IL, USA). Data were tested for normal distribution using the Shapiro Wilk test. Qualitative data were represented as frequencies and relative percentages. Chi square ( $\chi^2$ ) and Fisher exact tests were used to calculate the difference between qualitative variables as indicated. Quantitative data were expressed as mean  $\pm$  SD (Standard deviation) for parametric and median and range for non-parametric data. Independent "t" and Mann Whitney tests were used to calculate differences between quantitative variables in two groups for parametric and non-parametric variables respectively. All statistical comparisons were two tailed with significance level  $\leq 0.05$ .

### RESULTS

All of the 20 patients included in this study had a follow up average of at least 6 months. Objective assessment of the final condition was done for all patients.

Socio-Demographic characteristics between the two groups showed that, the mean age of patients in group I was  $34.17 \pm 7.35$  years; eight patients (80%) were males; the mean body mass index [BMI] was  $25.74 \text{ kg/m}^2$ . In group II, the mean age was  $37.50 \pm 9.45$  years, 7 patients (70%) were males and the mean BMI was  $26.12 \text{ kg/m}^2$  [Table 1].

Regarding fracture characteristics, in group I, 70% had fractures on the right side. Fracture due to direct fall on the shoulder was reported in 60 % and direct trauma in 40 %. In group II, 60% had fractures on the right side. Fractures due to direct fall on the shoulder were found in 70 %, direct trauma in 20% and fall on the outstretched hand in 10% (Table 2).

CSS for the group I revealed that, there were two patients (20.0%) who were poor, 2 patients (20%) were fair, 2 patients (20%) were good and 4 patients (40%) were excellent. In group II, there was one patient that was fair, two patients (20%) were good and 7 patients

(70%) were excellent. The VAS was significantly higher in group I compared to group II (Table 3).

The strength of abduction: in group I: four patients (40%) had a strength of abduction > 10 kg, two patients (20%) had a strength of abduction equals 10 kg, two patients (20%) had a strength of abduction of 5-9 kg and two patients (20%) had a strength of abduction of <5 kg. In group II, 7 patients (70%) had a strength of abduction > 10 kg, two patients (20%) with a strength of abduction equals 10 kg and one patient (10%) with a strength of abduction of 5- 9 kg (Table 4). The extent of internal rotation: In group I, 60% can achieve internal rotation with the thumb reaching the dorsal T12 vertebra, 20% can achieve internal rotation with the thumb reaching the waist (L3 vertebra) and 10% can

achieve internal rotation with the thumb reaching buttock. In group II, 70% can achieve internal rotation with the thumb reaching the interscapular region, 10% can achieve internal rotation with the thumb reaching the dorsal T12 vertebra, and 10% can achieve internal rotation with the thumb reaching the waist (L3 vertebra) (Table 5).

Finally, there was a significant difference regarding pain, a strength of abduction and extent of internal rotation. However, no significant difference was detected regarding comorbidities, characteristics of the fracture, type of fracture, the degree of forward flexion, degree of lateral elevation and extent of lateral rotation or demographic data.

**Table [1]: Socio-Demographic characteristics between the studied groups**

Socio-Demographic characteristics		Group I (n=10)	Group II (n=10)	t/ $\chi^2$	P
Age (years) [Mean $\pm$ SD]		34.17 $\pm$ 7.35	37.50 $\pm$ 9.45	0.879	0.391
Gender (n, %)	Female	2 (20%)	3 (30%)	0.392	0.531
	Male	8 (80%)	7 (70%)		
BMI (kg/m <sup>2</sup> ) [Mean $\pm$ SD]		25.74 $\pm$ 2.96	26.12 $\pm$ 3.57	0.259	0.798

**Table (2): Fracture characteristics between the two studied groups**

		Group I	Group II	$\chi^2$	P
Side	Right	7 (70%)	6 (60%)	0.219	0.639
	Left	3 (30%)	4 (40%)		
Mode	Direct trauma	4 (40%)	2 (20%)	1.74	0.418
	Fall on the shoulder	6 (60%)	7 (70%)		
	Fall on outstretched	0 (0.0%)	1 (10%)		

**Table (3): Outcome and pain VAS between the studied groups according to constant shoulder score.**

		Group I	Group II	$\chi^2$	P
Outcome	Excellent	4 (40%)	7 (70%)	4.87	0.034*
	Good	2 (20%)	2 (20%)		
	Fair	2 (20%)	1 (10%)		
	Poor	2 (20%)	0(0.0%)		
Pain	[VAS] Mean $\pm$ SD	4.2 $\pm$ 0.758	3.11 $\pm$ 0.947	2.84	0.011*

**Table (4): The strength of abduction among studied groups**

The strength of abduction	Group I	Group II	$\chi^2$	P
> 10 kg	4 (40%)	7 (70%)	4.25	0.032*
10 kg	2 (20%)	2 (20%)		
5 – 9 kg	2 (20%)	1 (10%)		
< 5 kg	2 (20%)	0		

**Table (5): The extent of internal rotation among the studied groups**

Extent of internal rotation	Group I	Group II	$\chi^2$	P
Thumb reaching the interscapular region	0	7 (70%)	12.6	0.014*
Thumb reaching the dorsal T12 vertebra	6 (60%)	1 (10%)		
Thumb reaching the waist	2 (20%)	2 (20%)		
Thumb reaching the lumbosacral Junction	1 (10%)	0		
Thumb reaching buttock	1 (10%)	0		

In the next, we present the radiology of two patients. The first presented patient was a male patient, 35years old. This patient was treated conservative. He had a direct trauma in his left shoulder. Patient injury is Robinson type 2B1. Follow up durations are 6 months (fig.2 a-e). The second presented patient was a female patient, 19years old. This patient was treated operative by plate fixation. She had direct fall on the left shoulder. Patient injury is Robinson type 2B1. Follow up duration are 6 months (fig 3 a-f)

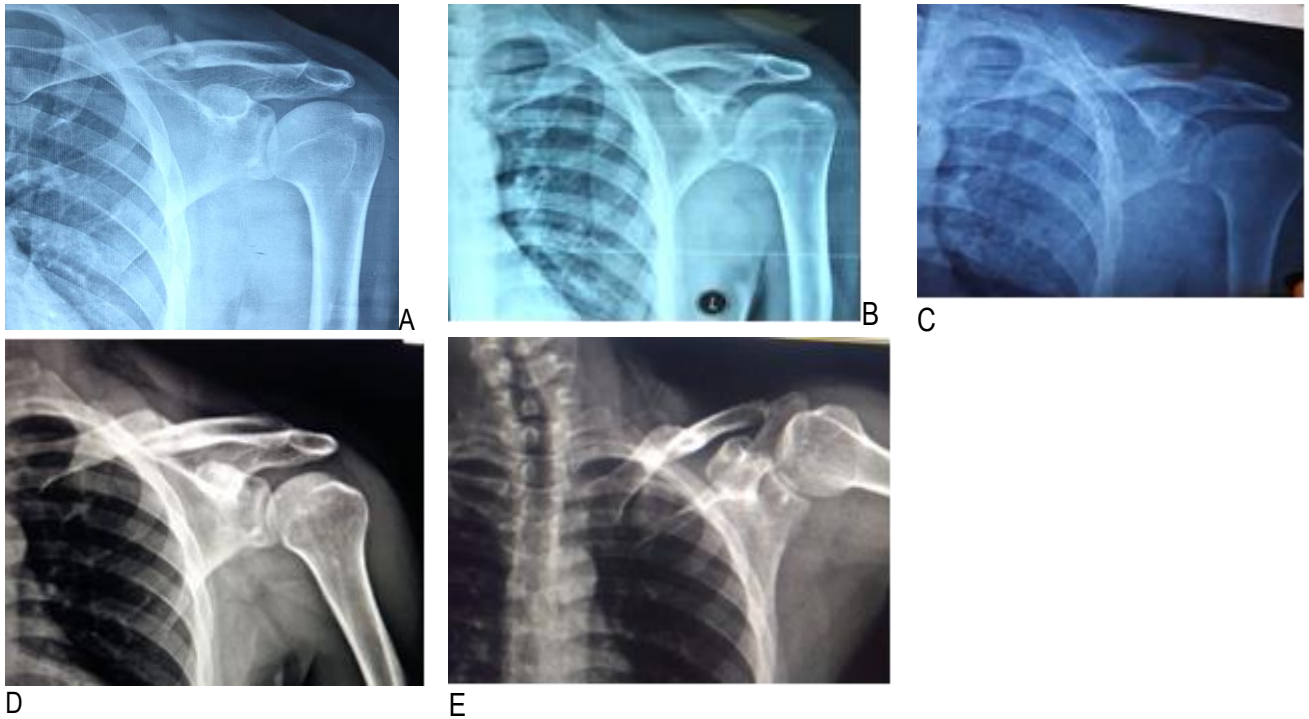


Figure (2): The first patient treated conservatively: here are the x-rays at the first day of trauma (A), One (b), Two (C), Four (D) and Sixth (E) months after treatment

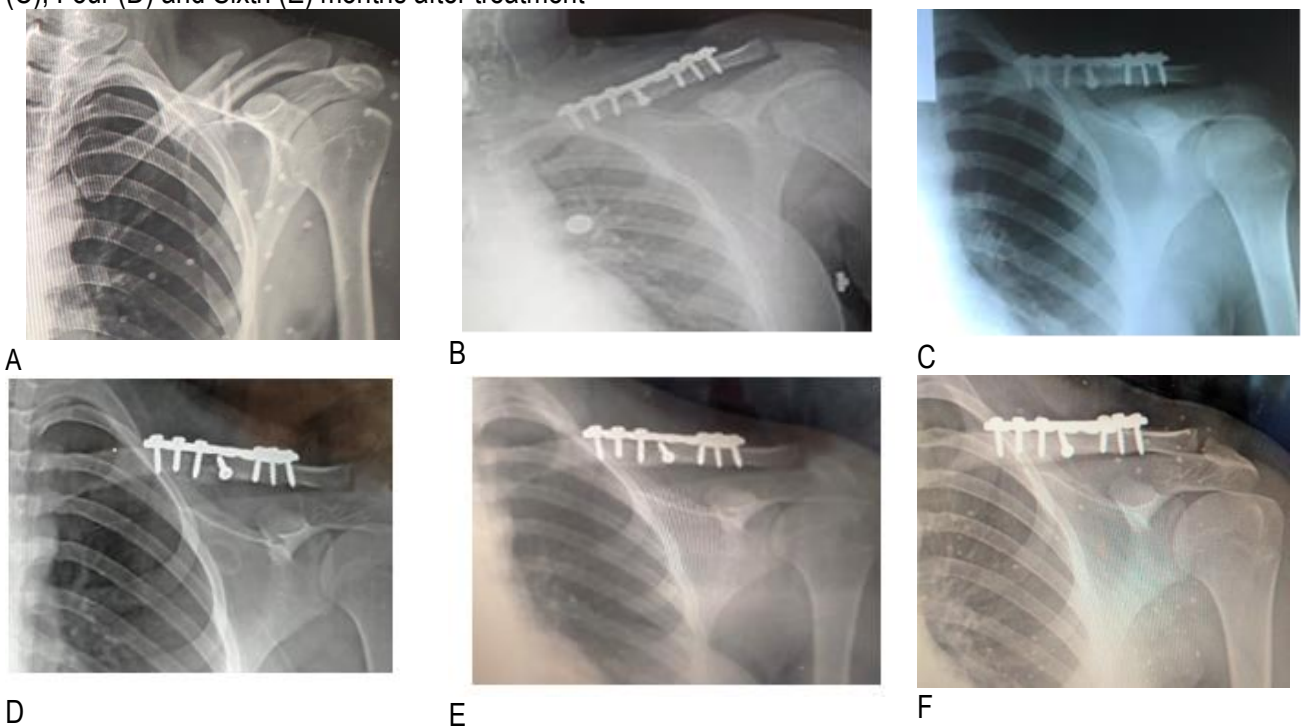


Figure (3): The second patient treated by plate fixation: here are the x-rays: preoperative (A), Four days (b), One month (C), two months (D) four months (E) and six months (F) after treatment



## DISCUSSION

Here, we presented the results of 20 adult patients diagnosed as having displaced midshaft clavicular fracture. These patients were divided into group I for conservative treatment and group II for operative treatment with Plate fixation.

Patient demographic in the current study is comparable with the study of Qvist et al. [13] in which Mean age, was 39 ranged between (18 to 60), and in operative group the mean age was 40 ranged between (18 to 60), Male vs female, in non-operative group was 55:16, and was 64:11 in operative group, and there was no significant difference found between the groups.

Regarding fractures characteristics, our results are in line with the results of the study of Salama et al. [14] in which 16 patients with acute displaced fracture midshaft clavicle, treated primarily by plate and screw. There were nine (56.25%) right side fractures and seven (43.75%) fractures on the left side. There were six (37.5%) cases of sport injuries, four (25%) cases of motorcycle accidents, one case (6.25%) of car accidents, and five cases (31.25%) of falling.

Regarding the outcome, this comes in line with the study of Naveenet al. [15]. They reported the union of the fracture was about 93% of the cases in group 1, whereas the union of the fracture was about 100% of the cases in group 2. The union of the fracture was good and early seen in more cases of group 2 than group 1. About 73% of cases were highly satisfied with the treatment at the end of 6 months in group 1, compared with group 2 where 83% of cases were highly satisfied with the treatment, nonunion and Mal-union rates were higher in nonoperative group compared with operative group.

Furthermore, in the current study, the pain score was higher in group I than group II. These results are supported by the study of Eden et al. [16], who used three different therapeutic modalities for patients with displaced midshaft clavicular fractures. They showed good or excellent results after one year. However, one can observe advantages of surgical treatment than nonoperative treatment for special characteristics. The reduction of pain was higher in operative than

conservative treatment in the early postoperative phase.

The results of abduction strength in the current work are supported by the study of Mckee et al. [17], who found a decrease in the strength in the arm that was treated nonoperatively. The strength of abduction was (67%) of that of the other arm. In another study, Nowak et al. [18], found that 46% of conservative treatment cases were not satisfied and not considered themselves fully recovered, 29% of them had pain with activity and 9% had pain at rest.

Moreover, regard extent of internal rotation, our results are comparable to Matsumura et al. [19]. They reported shortening of the clavicle which decreased external rotation of the clavicle and posterior tilting with elevation. The mal-union of the clavicle occurs with shortening >15 mm.

**Conclusion:** Operative treatment with plate and screws was better than non-operative treatment of midshaft clavicular fractures in adults due to high union rate, reduction of pain, good functional outcomes, and return to activities of daily living. However, the small sample size is a limiting step that prevent generalization of results.

### Financial and Non-financial Relationships and Activities of Interest

None

## REFERENCES

1. Smekal V, Oberladstaetter J, Struve P, Krappinger D. Shaft fractures of the clavicle: current concepts. Arch Orthop Trauma Surg. 2009 Jun;129(6):807-15. doi: 10.1007/s00402-008-0775-7.
2. Amer KM, Congiusta DV, Suri P, Choudhry A, Otero K, Adams M. Clavicle fractures: Associated trauma and morbidity. J Clin Orthop Trauma. 2020 Aug 26;13:53-56. doi: 10.1016/j.jcot.2020.08.020.
3. Bahk MS, Kuhn JE, Galatz LM, Connor PM, Williams GR Jr. Acromioclavicular and sternoclavicular injuries and clavicular, glenoid, and scapular fractures. Instr Course Lect. 2010; 59:209-26. PMID: 20415381.
4. McKee RC, Whelan DB, Schemitsch EH, McKee MD. Operative versus nonoperative care of displaced

- midshaft clavicular fractures: a meta-analysis of randomized clinical trials. *J Bone Joint Surg Am.* 2012 Apr 18;94(8):675-84. doi: 10.2106/JBJS.J.01364.
5. Rojas J, Familiari F, Bitzer A, Srikumaran U, Papalia R, McFarland EG. Patient Positioning in Shoulder Arthroscopy: Which is Best? *Joints.* 2019 Oct 11;7(2): 46-55. doi: 10.1055/s-0039-1697606.
  6. Abuzeid ME, Khairy HM, Eladawy AM, Elmalt AE. Conservative management and plate fixation of midshaft clavicular fractures in adults: comparative study. *ZUMJ* 2020; 26(2): 239-247. doi: 10.21608/zumj.2019.10215.1105
  7. Rommens PM, Kùchle R, Hofmann A, Hessmann MH. Intramedullary Nailing of Metaphyseal Fractures of the Lower Extremity. *Acta Chir Orthop Traumatol Cech.* 2017;84(5):330-340. PMID: 29351533.
  8. Chu JY, Yeh KT, Lee RP, Yu TC, Chen IH, Peng CH, Liu KL, Wang JH, Wu WT. Open reduction and internal fixation with plating is beneficial in the early recovery stage for displaced midshaft clavicular fractures in patients aged 30-65 years old. *Ci Ji Yi Xue Za Zhi.* 2018 Oct-Dec;30(4):242-246. doi: 10.4103/tcmj.tcmj\_25\_18.
  9. Prsic A, Friedrich JB. Postoperative Management and Rehabilitation of the Replanted or Revascularized Digit. *Hand Clin.* 2019 May;35(2):221-229. doi: 10.1016/j.hcl.2019.01.003.
  10. Savoie FH, Salas E, O'Brien M. Multidirectional Instability/Hyperlaxity of the Glenohumeral Joint. In *Shoulder Instability Across the Life Span* (pp. 21-34). Springer, Berlin, Heidelberg, 2017; pp 21-34.
  11. Hanby CK, Pasque CB, Sullivan JA. Medial clavicle physis fracture with posterior displacement and vascular compromise: the value of three-dimensional computed tomography and duplex ultrasound. *Orthopedics.* 2003 Jan;26(1):81-4. PMID: 12555840.
  12. Constant CR, Murley AH. A clinical method of functional assessment of the shoulder. *Clin Orthop Relat Res.* 1987 Jan;(214):160-4. PMID: 3791738.
  13. Qvist AH, Væsel MT, Jensen CM, Jensen SL. Plate fixation compared with nonoperative treatment of displaced midshaft clavicular fractures: a randomized clinical trial. *Bone Joint J.* 2018 Oct;100-B(10): 1385-1391. doi: 10.1302/0301-620X.100B10-BJJ-2017-1137.R3.
  14. Salama FH. Surgical treatment of acute displaced midshaft clavicular fractures with plates. *Egypt Orthop J [serial online]* 2015 Jan [cited 2020 Nov 26]; 50:144-7. doi: 10.4103/1110-1148.177915
  15. Naveen BM, Joshi GR, Hari Krishnan B. Management of mid-shaft clavicular fractures: comparison between non-operative treatment and plate fixation in 60 patients. *Strategies Trauma Limb Reconstr.* 2017 Apr;12(1):11-18. doi: 10.1007/s11751-016-0272-4.
  16. Eden L, Ziegler D, Gilbert F, Fehske K, Fenwick A, Meffert RH. Significant pain reduction and improved functional outcome after surgery for displaced midshaft clavicular fractures. *J Orthop Surg Res.* 2015 Dec 24; 10:190. doi: 10.1186/s13018-015-0336-z.
  17. McKee MD, Pedersen EM, Jones C, Stephen DJ, Kreder HJ, Schemitsch EH, Wild LM, Potter J. Deficits following nonoperative treatment of displaced midshaft clavicular fractures. *J Bone Joint Surg Am.* 2006 Jan;88(1):35-40. doi: 10.2106/JBJS.D.02795.
  18. Nowak J, Holgersson M, Larsson S. Can we predict long-term sequelae after fractures of the clavicle based on initial findings? A prospective study with nine to ten years of follow-up. *J Shoulder Elbow Surg.* 2004 Sep-Oct;13(5):479-86. doi: 10.1016/j.jse.2004.01.026.
  19. Matsumura N, Ikegami H, Nakamichi N, Nakamura T, Nagura T, Imanishi N, Aiso S, Toyama Y. Effect of shortening deformity of the clavicle on scapular kinematics: a cadaveric study. *Am J Sports Med.* 2010; 38:1000-6. doi: 10.1177/ 0363546509355143.

# International Journal

<https://ijma.journals.ekb.eg/>

Print ISSN: 2636-4174

Online ISSN: 2682-3780

# of Medical Arts