

---

## Surgical Effects of Internal Limiting Membrane Peeling with Vitrectomy for Vitreo-Macular Traction in Diabetic Patients

Eman M. Musa, Sherief E. El Khouly, Mohammed A. Gad, Sahar M. El Tarshouby, Mohammed S. Settin.

Ophthalmology department, Faculty of Medicine, Mansoura University, Mansoura

---

**Correspondence to:** *Sherief E. El Khouly*. Ophthalmology department, Faculty of Medicine, Mansoura University, Mansoura, Egypt PO.35516. E mail: [elkhouly\\_eye\\_clinics@yahoo.com](mailto:elkhouly_eye_clinics@yahoo.com)

Received: 4-1-2021, Accepted: 3-3-2021, Published online: 11/3/2021

EJO(MOC) 2021;1:12-22.

**Running title:** Vitrectomy for vitreo-macular traction in diabetic patients.

---

### Abstract

**Aim:** To evaluate the surgical effects of internal limiting membrane (ILM) peeling with parsplana vitrectomy in diffuse diabetic macular edema with vitreo-macular traction as regard the best corrected visual acuity, central foveal thickness, residual epiretinal membrane and recurrent traction.

**Methods:** The study included twenty eyes of twenty patients with diffuse diabetic macular edema and vitreo-macular traction. Seven eyes underwent vitrectomy with ILM peeling (group I) and thirteen eyes underwent vitrectomy without ILM (group II). The inclusion criteria were diffuse diabetic macular edema with optical coherence tomography evidence of vitreo-macular traction with or without epiretinal membrane. Exclusion criteria involved any ocular disease can cause macular edema rather than diabetes mellitus and eyes with macular ischemia. The effect of ILM peeling was evaluated on the surgical outcomes as regard best corrected visual acuity, central foveal thickness, residual epiretinal membrane and recurrent traction at postoperative one, three and six months.

**Results:** Statistically significant improvement of best corrected visual acuity and reduction of central foveal thickness occurred in all eyes postoperatively and over time with statistically insignificant difference between both groups. No eyes in group I and eight eyes in group II showed residual epiretinal membrane with a statistically significant difference between both groups. No eyes in group I and two eyes in group II showed recurrent traction due to residual epiretinal membrane with a statistically insignificant difference between both groups.

**Conclusion:** ILM peeling has an important role in complete removal of epiretinal membrane and prevention of recurrent traction.

**Keywords:** Diabetic macular edema, Vitreomacular traction, Vitrectomy.

---

### Introduction

The vitreous plays an essential role in macular edema development through multiple physiological and mechanical mechanisms.<sup>1</sup> In patients with diabetes, the posterior hyaloid of the vitreous is greatly attached to the macula.<sup>2</sup>

In Addition, the vitreo-macular interface

abnormalities play a major inducing factor in diabetic macular edema.<sup>2</sup> The vitreo-retinal interface is formed of the cell membrane of the Müller cells, the internal limiting membrane and the vitreous cortex.<sup>3</sup>

Internal limiting membrane is thickened in diabetic macular edema due to proliferation of cells on the posterior hyaloid and increase the content of

---

Egyptian Journal of Ophthalmology, a publication of Mansoura Ophthalmic Center.

Address: Mansoura Ophthalmic Center, Mansoura University, Mansoura, Egypt.

Website: <https://ejomos.journals.ekb.eg>

Tel. 0020502202064. Fax. 0020502202060.

E-mail: [ejo@mans.edu.eg](mailto:ejo@mans.edu.eg)

extracellular matrices.<sup>4</sup>

The thickened internal limiting membrane contributes in the functional and structural disorder of water movement between the retina and the vitreous resulting in keeping the proteins in the inter-cellular space and inhibiting its movement to the vitreous inducing macular edema.<sup>4,5</sup>

Moreover, the thickened internal limiting membrane retards the diffusion of oxygen from the vitreous into the retinal tissue. In addition, the surgical removal of internal limiting membrane speeds up the clearance of cytokines and vascular endothelial growth factors from the retina to the vitreous cavity.<sup>6,7</sup>

As well, internal limiting membrane acts as a reservoir for vascular endothelial growth factors either in or on its vitreal side. Moreover, internal limiting membrane removal allows sure removal of all vitreous elements that may remain after vitreous separation alone<sup>[8]</sup> especially that, Vitreo-macular traction in diabetic patients usually associated with vitreoschisis and epiretinal membrane formation.<sup>9</sup> However, internal limiting membrane peeling with vitrectomy remains a controversial treatment for diffuse diabetic macular edema.<sup>10</sup>

## **Patients and methods:**

### **Patient enrollment**

This is a prospective comparative interventional study on diabetic patients with diffuse macular edema attended clinics of Mansoura Ophthalmic Center, Mansoura University in the period from december 2012 to december 2015. The study protocol was approved by the committee of institution review board and medical research ethics committee, faculty of medicine, Mansoura University. Written consent was obtained from every patient and they were informed about risks of surgery and consequences of the study. The inclusion criteria were diffuse diabetic

macular edema with optical coherence tomography evidence of vitreo-macular traction with or without epiretinal membrane. Exclusion criteria involved any ocular disease can cause macular edema rather than diabetes mellitus and eyes with macular ischemia.

### **Preoperatively:**

Pre-operative history was obtained for all patients including: age, gender, duration of diabetic disease, insulin therapy, presence or absence of systemic hypertension, cardiac or renal disease, Previous pan-retinal or macular photocoagulation treatment, previous intra-vitreous injection either triamcinolone or anti-vascular endothelial growth factors and previous ocular surgery. Full ophthalmic examinations of the patients were done including assessment of best corrected visual acuity by Snellen's chart, slit-lamp biomicroscopy for anterior segment and fundus examination using either contact or non-contact lens (90 diopters or 78 diopters) and indirect ophthalmoscopy. Ultrasonic examination, fundus fluorescein angiograms and spectral-domain optical coherence tomography were done to evaluate the central foveal thickness and the vitreo-retinal interface.

### **The study samples were classified into two groups:**

Group I: underwent vitrectomy with internal limiting membrane peeling.

Group II: underwent vitrectomy without internal limiting membrane peeling.

### **Surgical techniques:**

A standard pars plana vitrectomy was performed in all patients. Three port 23 gauge sclerotomies and core vitrectomy were done then Suction is applied by vacuum of the vitrectomy probe to separate the posterior vitreous face assisted with triamcinolone injection [Kenacort-A (40 Suspension), Bristol-Myers Squibb injection] and continued peripherally. Removal of the vitreous remnant confirmed by

repeated triamcinolone injection especially in patients of vitreoschisis. In eyes that encountered an epiretinal membrane, it was peeled from the retina with intra-ocular forceps or Tano scraper. In group I, internal limiting membrane peeling was done using Brilliant blue G stain (Brilliant Peel<sup>®</sup>, DORC, Rotterdam, Netherlands).

After partial fluid air exchange, dye is injected then removed after 60 seconds. An edge of the internal limiting membrane is achieved in the temporal macular area near the arcade using a 23 gauge symmetrical end gripping microforceps [0.6mm] [Eckardt forceps, DORC, Rotterdam, Netherlands] then the peeling technique is completed to make a maculorhexis centered around the central macula by about two disc diameter. In addition, peripheral retinal indentation for detection of any breaks, peripheral holes, or localized detachment was done. Endo-laser photocoagulation was performed in proliferative diabetic retinopathy and discovery of peripheral retinal breaks.

Ocular tamponade was needed in selected patients using air or silicon injection. The sclerotomies were closed by applying local pressure or massage, vicryl 7/0 suture was used in some patients.

**Postoperatively:** Examination visits were scheduled at postoperative first, third and sixth months using the same preoperative clinical parameters and investigation tools.

**Statistical analysis of the data:** Data were entered and analyzed using SPSS software (Statistical Package for Social Sciences) (version 20) (Chicago, SPSS Inc, 2008) and Graphpad prism (version 5). For the statistical analyses, best corrected visual acuity values were converted to logMAR unit.

Qualitative data were expressed as count and percent. Quantitative data were initially tested for

normality using Kolmogorov-Smirnov and Shapiro-Wilk test with data being normally distributed if  $p > 0.050$ . Quantitative data were expressed as mean  $\pm$  standard deviation if normally distributed or median and interquartile range if not qualitative data for two groups (2X2 table) are compared using Chi-Square test

## **Results:**

### **Demographic data and clinical characteristics**

The data were collected and recorded from December 2012 to December 2015. The study included twenty eyes of twenty patients with diffuse diabetic macular edema and vitreo-macular traction. Seven eyes underwent vitrectomy with internal limiting membrane peeling (group I) and thirteen eyes underwent vitrectomy without internal limiting membrane peeling (group II) The median of the age was sixty one years. The study included seven males (35.0 %) and thirteen females (65.0%).

The higher proportion of patients were females which was statistically significant ( $P=0.008$ ). The median of diabetic duration was fifteen years. Seventeen patients (85%) were on insulin therapy and three patients (15.0%) were on oral hypoglycemic therapy with a significant higher proportion ( $P < 0.0001$ ). Nine patients (45.0%) were hypertensive, while eleven patients (55.0 %) were not, that was statistically insignificant ( $P=0.133$ ). One patient (5.0%) had renal disease and one patient (5.0%) had cardiac disease. No significant association was present with renal or cardiac disease. Twelve patients (60.0%) had proliferative diabetic retinopathy revealed by fundus fluorescein angiography. (Table 1)

Previous treatments received by the patients included: five eyes (25.0%) underwent panretinal photocoagulation, two eyes (10.0%) received macular laser photocoagulation, three eyes (15.0%) eyes underwent intra-vitreous injection of

triamcinolone, and four eyes (20.0%) eyes had anti-vascular endothelial growth factor intra-vitreally. (Table 2).

Statistically significant postoperative improvement of best corrected visual acuity occurred in all eyes ( $p < 0.0001$ ). The median pre-operative best corrected visual acuity was  $1.127 \pm 0.433$  LogMAR, the median postoperative best corrected visual acuity was  $1.039 \pm 0.374$  LogMAR at first month,  $1.0 \pm 0.415$  LogMAR at third month and  $0.778 \pm 0.4$  LogMAR at sixth month. Best corrected visual acuity showed statistically significant improvement overtime ( $p < 0.0001$ ). Pairwise comparisons revealed that, statistically significant difference existed between the preoperative data and that of postoperative third and sixth months while there was statistically insignificant difference between the pre-operative data and that of postoperative first month and in-between the first, third and sixth months postoperatively (Table 3).

The median Delta change in best corrected visual acuity between the preoperative and the postoperative sixth month was  $0.39 \pm 0.29$  LogMAR. The minimum delta change was 0.08 and the maximum delta change was 1.18. The mean percent change was  $33.86\% \pm 16.74$  with minimum percent change (7.32%), and maximum percent change (70.0%).

Statistically significant postoperative reduction of central foveal thickness was evidenced in all eyes by optical coherence tomography ( $p < 0.0001$ ). The median preoperative central foveal thickness was  $532\mu \pm 269\mu$ . The median postoperative central foveal thickness was  $311\mu \pm 101\mu$  at first month,  $274\mu \pm 77\mu$  at third month, and  $235\mu \pm 48\mu$  at sixth month. Pairwise comparisons revealed that, there was highly significant difference between data of the pre-operative and that of post-operative first, third and

sixth months and in-between the postoperative first and sixth months. (Table 3)

The mean Delta change in central foveal thickness between the pre-operative and the postoperative sixth month was  $308.94\mu \pm 156.39\mu$  with mean percent change  $52.65\mu\% \pm 18.05\mu$ . The minimum delta change was  $79.0\mu$  and the maximum delta change was  $566.0\mu$  with minimum percent change (25.4%) and maximum percent change (88.85%).

In group I, the median preoperative best corrected visual acuity was  $1.3 \pm 0.3$  LogMAR, the median postoperative best corrected visual acuity was  $1.0 \pm 0.07$  LogMAR at first month,  $1.0 \pm 0.1$  LogMAR at third month, and  $1.0 \pm 0.5$  LogMAR at sixth month. In group II, the median pre-operative best corrected visual acuity was  $1.0 \pm 0.3$  LogMAR, the median post-operative best corrected visual acuity was  $1.0 \pm 0.7$  LogMAR at first month,  $1.0 \pm 0.5$  LogMAR at third month and  $0.6 \pm 0.3$  LogMAR at sixth month. Best corrected visual acuity showed statistically significant improvement overtime ( $p < 0.0001$ ). Pairwise comparisons revealed that, statistically significant difference existed between the preoperative data and that of postoperative third and sixth months while there was statistically insignificant difference between the pre-operative data and that of postoperative first month and in-between the first, third and sixth months postoperatively (Table 4).

In group I, five eyes (71.4%) showed  $< 30\%$  and two eyes (28.6%) showed  $> 30\%$  improvement in best corrected visual acuity while in group II, five eyes (38.5%) showed  $< 30\%$  and eight (61.5%) eyes showed  $> 30\%$  improvement in best corrected visual acuity. There was statistically insignificant difference between both groups ( $P = 0.35$ ).

In group I the median pre-operative central

foveal thickness was  $520 \mu \pm 262 \mu$ , the median postoperative central foveal thickness was  $280 \mu \pm 151 \mu$  at first month,  $249 \mu \pm 32 \mu$  at third month, and  $232 \mu \pm 6 \mu$  at sixth month. In group II the median pre-operative central foveal thickness was  $587 \mu \pm 336 \mu$ , the median postoperative central foveal thickness was  $332 \mu \pm 92 \mu$  at first month,  $298 \mu \pm 154 \mu$  at third month, and  $250 \mu \pm 104 \mu$  at sixth month.

In group I, three eyes (42.9%) showed  $< 50\%$ , and four eyes (57.1%) showed  $> 50.0\%$  central foveal thickness reduction. While in group II, seven eyes (53.8%) showed  $< 50.0\%$  and six eyes (46.2%) showed  $> 50.0\%$  central foveal thickness reduction. There was statistically insignificant difference between both groups, ( $P=0.64$ ). (fig. 1,2)

No eyes in group I and eight eyes in group II showed residual epiretinal membrane with a statistically significant difference between both groups ( $P = 0.015$ ). No eyes in group I and two eyes in group II showed recurrent traction due to residual epiretinal membrane with a statistically insignificant difference between both groups, ( $P = 0.521$ ).

**Table 1: Pre-operative clinical data of the study group.**

Parameter	Descriptive statistics	P. value
Gender		
Male:	7 (35.0%)	0.008
Female:	13 (65.0%)	
Age	61 (56-65)	
Duration of diabetes	15 y (10-20)	
Insulin therapy		
No	3 (15.0%)	$<0.0001$
Yes	17 (85.0%)	
Associated Hypertension		
No	11 (55.0%)	0.133
Yes	9 (45.0%)	
Associated renal disease		
No	19 (95.0%)	$<0.0001$
Yes	1 (5.0%)	
Associated cardiac disease		
No	19 (95.0%)	$<0.0001$
Yes	1 (5.0%)	
Proliferative diabetic retinopathy		
No	8 (40.0%)	0.908
Yes	12 (60.0%)	

**Table 2: Descriptive statistics of the previous treatment.**

Parameter	Descriptive statistics
<b>Previous Pan- retinal photo coagulation</b>	
No	15 (75.0 %)
Yes	5 (25.0 %)
<b>Previous macular laser</b>	
No	18 (90.0%)
Yes	2 (10.0 %)
<b>Previous Intra- vitreal injection of triamcinolone</b>	
No	17 (85.0 %)
Yes	3 (15.0 %)
<b>Previous anti- vascular endothelialgrowth factor</b>	
No	16 (80.0%)
Yes	4 (20.0%)

**Table 3: Best corrected visual acuity and central foveal thickness all over the study**

Parameter	Preoperative		Postoperative		P. value
		1 <sup>st</sup> month	3 <sup>rd</sup> month	6 <sup>th</sup> month	
<b>Visual acuity (Log MAR)</b>	(A) 1.127± 0.433	(AD) 1.039± 0.374	(BD) 1.0± 0.415	(CD) 0.778± 0.4	<0.0001
<b>Central thickness</b>	(A) 532± 269	(B) 311± 101	(BE) 274± 77	(DE) 235± 48	<0.0001

Pairs with the same letter have no statistically significant difference while pairs with different letters have statistically significant difference. P value by Friedman test

**Table 4: Pre-operative and post-operative best corrected visual acuity in both groups**

Parameter	group	Preoperative		Postoperative		P. value
			1 <sup>st</sup> month	3 <sup>rd</sup> month	6 <sup>th</sup> month	
<b>Visual acuity (Log MAR)</b>	<b>Group I</b>	1.3 ± 0.3	1.0± 0.07	1.0± 0.1	1.0± 0.5	<0.0001
	<b>Group II</b>	1.0 ± 0.3	1.0± 0.7	1.0± 0.5	0.6± 0.3	<0.0001

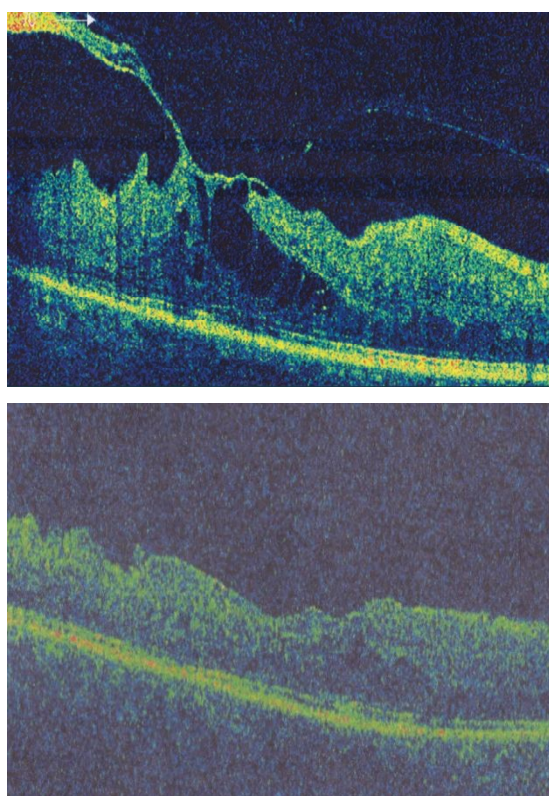


Figure 1: Optical coherence tomography evidence of central foveal thickness reduction in eye of group I (A) preoperatively (B) postoperatively

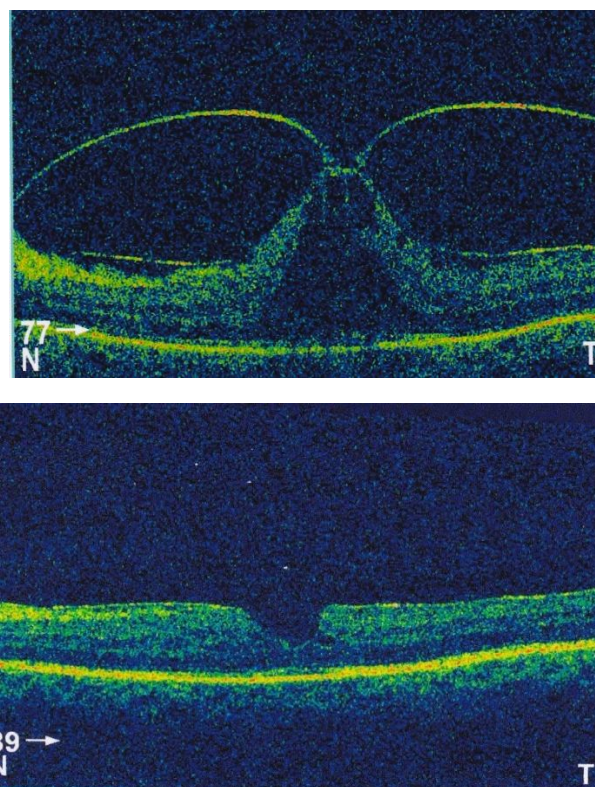


Figure 2: : Optical coherence tomography evidence of central foveal thickness reduction in eye of group II (A) preoperatively (B) postoperatively

## Discussion

Internal limiting membrane peeling with vitrectomy was a controversial treatment for diffuse diabetic macular oedema. Some studies reported that vitrectomy and internal limiting membrane peeling improve the visual acuity and decrease macular thickening even in cases without taut posterior hyaloid or in patients that achieved a previous vitrectomy without internal limiting membrane peeling.<sup>10</sup>

Moreover, internal limiting membrane removal in cases of epiretinal membrane with macular edema decreases the recurrence of epiretinal membranes and allows complete removal of the membrane, especially in diabetic patients as the incidence of vitreoschisis and sticky cortical vitreous is high.<sup>11</sup>

Internal limiting membrane peeling may thus be

able to remove all cortical vitreous and relieve vitreomacular traction that otherwise may not be eliminated simply by vitrectomy alone.<sup>12</sup>

The current study included twenty eyes of diffuse diabetic macular edema and vitreo-macular traction. Internal limiting membrane peeling was done in seven eyes (35.0%) (group I), while thirteen eyes (65.0%) underwent parsplana vitrectomy without internal limiting membrane peeling (group II).

In this study, statistically significant postoperative improvement of best-corrected visual acuity occurred in all eyes. The median pre-operative best-corrected visual acuity was  $1.127 \pm 0.433$  LogMAR, the median post-operative best corrected visual acuity was  $1.039 \pm 0.374$  LogMAR at first month,  $1.0 \pm 0.415$  LogMAR at third month and  $0.778 \pm 0.4$  LogMAR at sixth month.

The median Delta change in best corrected visual acuity between the pre-operative and the postoperative sixth month was  $0.39 \pm 0.29$  LogMAR. The minimum delta change was 0.08 and the maximum delta change was 1.18. The mean percent change was  $33.86\% \pm 16.74$  with minimum percent change (7.32%), and maximum percent change (70.0%).

It was comparable with the electronic medical record database study of Jackson et al. in 2016 that studied vitrectomy for vitreo-macular traction. The diabetic group analysis showed that, the median best corrected visual acuity improved from 0.7 logMAR at surgery to 0.5 log MAR at six to twelve months post-surgery with 33% improvement in best corrected visual acuity at least 0.3 log MAR (approximately two snellen lines). This is similar to a value of 33% reported in a systematic review about vitrectomy for vitreo-macular traction by Jackson et al in 2013.<sup>13,14</sup>

Massin et al. have also proposed an encouraging outcome of vitrectomy for diffuse diabetic macular edema with vitreo-macular traction. Best corrected visual acuity was preoperatively [median = 20/100] and reached at the final follow [median=20/80].<sup>15</sup>

In the current study, best-corrected visual acuity showed statistically significant improvement overtime. Pairwise comparisons revealed that, statistically significant difference existed between the pre-operative data and that of postoperative third and sixth months while there was statistically insignificant difference between the pre-operative data and that of postoperative first month and in-between the first, third and sixth months postoperatively. This means that, best corrected Visual acuity needed up to six months to be improved.

The vitrectomy impact on eyes with diffuse diabetic macular edema associated with vitreo-macular traction assessed also by diabetic retinopathy

clinical research network study. It conducted a prospective one year study at 35 sites involving 87 subjects to evaluate the anatomic and functional outcomes, patients with moderately vision loss was included. Three letters improvement in vision is achieved six months postoperatively on average. In 38% of cases vision increased  $\geq 10$  letters 6 months postoperatively and 22% of cases showed a reduction of vision by  $\geq 10$  letters.<sup>16</sup> Although visual acuity is an accepted measure of visual function, patients with vitreo-macular traction may benefit from reduction of metamorphopsia even without marked improvement in visual acuity.<sup>13</sup>

In the present study, statistically significant postoperative reduction of central foveal thickness was evidenced in all eyes by optical coherence tomography. The median pre-operative central foveal thickness was  $532\mu \pm 269\mu$ . The median post-operative central foveal thickness was  $311\mu \pm 101\mu$  at first month,  $274\mu \pm 77\mu$  at third month, and  $235\mu \pm 48\mu$  at sixth month.

It was comparable with Massin et al. who have proposed an encouraging outcome of vitrectomy for diabetic macular edema with vitreo-macular traction. The mean preoperative macular thickness decreased significantly from  $661 \pm 181\mu$  to  $210 \pm 32\mu$  at the final follow-up, which was statistically significant [P= 0.018].<sup>15-17</sup>

Our study showed that, the mean Delta change in central foveal thickness between the pre-operative and the postoperative sixth month was  $308.94\mu \pm 156.39\mu$  with mean percent change  $52.65\mu\% \pm 18.05\mu$ . The minimum delta change was  $79.0\mu$  and the maximum delta change was  $566.0\mu$  with minimum percent change (25.4%) and maximum percent change (88.85%).

In diabetic retinopathy clinical research network study, a reduction in the postoperative retinal



thickening after parsplana vitrectomy was observed in the majority of cases. Central foveal thickness reduced to be less than 250  $\mu$  as presented in ocular coherence tomography in almost half of the patients, and majority of the eyes had a reduction in the macular thickness of  $\geq 50\%$ .<sup>16</sup>

This study demonstrated that, in group I, five eyes (71.4%) showed  $< 30\%$  and two eyes (28.6%) showed  $> 30\%$  improvement in best corrected visual acuity while in group II, five eyes (38.5%) showed  $< 30\%$  and eight (61.5%) eyes showed  $> 30\%$  improvement in best corrected visual acuity. There was statistically insignificant difference between both groups.

Lewis and associates, Harbour and coworkers, and Ikeda and coworkers, all have shown improvement or resolution of diabetic macular edema with parsplana vitrectomy and removal of the posterior hyaloid face. Most of these eyes were refractory to focal and grid laser treatment. Visual acuity improved by one or more lines in 50 -100% of cases. Favorable results also have been reported by Otani and Kishi even in the presence of cystoid macular edema.<sup>17-21</sup>

Pendergast et al,<sup>21</sup> mentioned that, parsplana vitrectomy in eyes with persistent diffuse diabetic macular edema with a taut premacular posterior hyaloid face, vitrectomy with removal of the posterior hyaloid appeared to be beneficial in some cases. The mean preoperative best-corrected visual acuity was 20/160 and the mean final best corrected visual acuity was 20/80 ( $P < 0.0001$ ) with 27 (49.1%) of the fifty five eyes demonstrating improvement in best-corrected visual acuity of 2 or more lines. Fifty-two (94.5%) of the fifty five vitrectomized eyes showed improvement in clinically significant macular edema and in forty five eyes (81.8%), the macular edema resolved completely during a mean period of 4.5 months (range, 1 to 13 months).<sup>21</sup>

Otani and Kishi performed a controlled, nonrandomized, comparative clinical trial on fourteen eyes to compare the effectiveness of parsplana vitrectomy with observation for diabetic macular edema (follow-up range 5-7 months, mean 6.2 months). In the eyes that underwent parsplana vitrectomy, foveal thickness was significantly less at the last follow-up visit compared with preoperative values. In the control group, there was insignificant difference in foveal thickness between initial and last follow up visits. Visual acuity improved in 57% and remained unchanged in 43% among eyes that underwent parsplana vitrectomy. In the control group, visual acuity improved in 14%, remained unchanged in 43% and decreased in 43% of eyes. There was a strong correlation between the preoperative and postoperative visual acuity in the operated eyes.<sup>20</sup>

Eight eyes in group II and no eyes in group I showed residual epiretinal membrane with a statistically significant difference between both groups. Eight eyes in group II and no eyes in group I showed recurrent traction due to residual epiretinal membrane with a statistically insignificant difference between both groups.

There is debate about the potential benefit of Internal limiting membrane peeling following the removal of epiretinal membrane. It has been proposed that removal of Internal limiting membrane at the time of surgery removes the scaffold for myofibroblast proliferation and any residual microscopic epiretinal membrane, thus reducing the risk of recurrence as well as improving visual outcomes.<sup>22, 23</sup>

Conversely, there are concerns that, loss of retinal tissue and damage to Müller cell footplates may adversely affect visual function and that rates of recurrence are not affected.<sup>23, 24</sup>

Internal limiting membrane peeling has an important role in complete removal of epiretinal membrane and

prevention of recurrent traction.

#### **ACKNOWLEDGEMENTS**

Mansoura Ophthalmic Center Nursing staff.

**Conflicts of Interest:** Non

#### **References:**

1. Zhang X, Zeng H, Bao S, Wang N, Gillies M. Diabetic macular edema: new concepts in pathophysiology and treatment. *Cell Biosci* 2014;4:27.
2. Das A, McGuire PG, Rangasamy S. Diabetic macular edema: pathophysiology and novel therapeutic targets. *Ophthalmology* 2015;122:1375-1394.
3. Bhagat N, Zarbin M. Recent innovations in medical and surgical retina. *Asia Pac J of Ophthalmol* 2015;3:171-179.
4. Domalpally A, Gangaputra S, Danis RP. Anatomy and physiology of the vitreo macular interface. In: Girach A, Smet M D(eds), *Diseases of the vitreo macular interface, Essentials in Ophthalmology* 2014;21-27.
5. Saravia M. Persistent diffuse diabetic macular edema. The role of the internal limiting membrane as a selective membrane: the oncotic theory. *Med Hypotheses* 2011; 76:858–860.
6. Schumann RG, Gandorfer A. Pathophysiology of vitreo macular interface. In: Girach A, Smet MD (eds) *Diseases of the vitreo macular interface Essentials in Ophthalmology*. Springer, Heideberg 2014:43-52.
7. Hoerauf H1, Brüggemann A, Muecke M, Lücke J, Müller M, Stefánsson E, et al. Pars plana vitrectomy for diabetic macular edema. Internal limiting membrane delamination vs posterior hyaloid removal. A prospective randomized trial. *Graefes Arch Clin Exp Ophthalmol* 2011; 249:997–1008.
8. Gandorfer A1, Rohleder M, Grosselfinger S, Haritoglou C, Ulbig M, Kampik A. Epiretinal pathology of diffuse diabetic macular edema associated with vitreomacular traction. *Am J Ophthalmol* 2005; 139:638– 652.
9. Bhagat N, Grigorian R A, Tutela A, Zarbin M A. Diabetic Macular Edema: Pathogenesis and Treatment. *Surv Ophthalmol* 2009; 54:1-32.
10. Rosenblatt BJ, Shah GK, Sharma S, Bakal J. Pars plana vitrectomy with internal limiting membranectomy for refractory diabetic macular edema without a taut posterior hyaloid. *Graefes Arch Clin Exp Ophthalmol*. 2005; 243: 20-5.
11. Arevalo JF. Diabetic macular edema: Current management 2013 *world J Diabetes* 2013;4:231-233.
12. Todorich B, Flynn Hw. Mahmoud Th. Vitrectomy for Diabetic Macular Edema. *Curr Ophthalmol Rep* 2014; 2:167-174.
13. Jackson LT, Donachie PHJ, Johnston RL. Electronic medical record database study of vitrectomy and observation for vitreomacular traction. *Retina* 2016; 36: 1897-1905.
14. Jackson TL, Nicod E, Angelis A, Grimaccia F, Prevost AT, Simpson AR, et al. Parsplana vitrectomy for vitreomacular traction syndrome: a systematic review of safety and efficacy. *Retina* 2013; 33: 2012-2017.
15. Massin P, Duguid G, Erginay A, Haouchine B, Gaudric A. Optical coherence tomography for evaluating diabetic macular edema before and after vitrectomy. *Am J Ophthalmol* 2003; 135: 169-177.
16. Diabetic retinopathy clinical research network writing committee, Haller JA, Qin H, Apte RS, Beck RR, Bressler NM, et al. Vitrectomy outcomes in eyes with diabetic macular edema and vitreomacular traction. *Ophthalmology* 2010; 117: 1087-1093.
17. Harbour JW, Smiddy WE, Flynn HW Jr, Rubsamen PE. Vitrectomy for diabetic macular

- edema associated with a thickened and taut posterior hyaloid membrane. *Am J Ophthalmol* 1996; 121: 405-413.
18. Lewis H, Abrams GW, Blumenkranz MS, Campo RV. Vitrectomy for diabetic macular traction and edema associated with posterior hyaloidal traction. *Ophthalmology* 1992; 99: 753-759.
19. Ikeda T, Sato K, Katano T, Hayashi Y. Vitrectomy for cystoid macular oedema with attached posterior hyaloid membrane in patients with diabetes. *Br J Ophthalmol* 1999; 83: 12-14.
20. Otani T, Kishi S. Tomographic assessment of vitreous surgery for diabetic macular edema. *Am J Ophthalmol*. 2000; 129: 487-94.
21. Pendergast SD, Hassan TS, Williams GA, Cox MS, Margherio RR, Ferrone PJ, et al. Vitrectomy for diffuse diabetic macular edema associated with a taut premacular posterior hyaloid. *Am J Ophthalmol* 2000; 130: 178-86.
22. Bovey EH, Uffer S, Achache F. Surgery for epimacular membrane: impact of retinal internal limiting membrane removal on functional outcome. *Retina* 2004; 24: 728-735.
23. Park DW, Dugel PU, Garda J, Sipperley JO, Thach A, Sneed SR, et al. Macular pucker removal with and without internal limiting membrane peeling: pilot study. *Ophthalmology* 2003; 110: 62-64.
24. Lim JW, Cho JH, Kim HK. Assessment of macular function by multifocal electroretinography following epiretinal membrane surgery with internal limiting membrane peeling. *Clin Ophthalmol* 2010;4: 689-94.