

Versatility of Local Skin Flaps in Facial Reconstruction after Resection of Malignant Cutaneous Tumors**Basma M. Ali^a, Ahmed A. A. Ali^a, Asmaa Gaber R^b, Samia M. A. Saied^c**^aPlastic Surgery, Faculty of Medicine, South Valley University, Qena, Egypt^bGeneral Surgery, Faculty of Medicine, South Valley University, Qena, Egypt^cPlastic Surgery, Faculty of Medicine, Sohag University, Sohag, Egypt**Abstract**

Background: The most prevalent malignant tumors of the human face are basal cell carcinoma (BCC), squamous cell carcinoma (SCC) and malignant melanoma. BCC constitutes more than three quarters of skin cancers of the face and the rest primarily consist of SCC.

Objectives: The aim of our study is to describe different types of local cutaneous flaps that are versatile and reliable in reconstruction of post-oncological facial defects.

Patients and methods: This prospective study was conducted on patients admitted to the Plastic Surgery Department, Qena Faculty of Medicine, South Valley University from May 2019 to May 2020 (one-year duration). A total of fifty patients with malignant tumors of facial skin were included in our study.

Results: Twenty nine patients had reconstructed their defects by local random flaps, while 21 patients had reconstructed their defects by local axial flaps. The most random flap applied was rhomboid flap in 14 (28%) patients. The most axial flap applied was forehead flap in 6 (12%) patients and nasolabial flap in 6 (12%) patients.

Conclusion: The reconstruction of post ablative face defects, using local flaps, is a real challenge from the perspective of surgical techniques, considering the difficulties determined by the restoring of three dimensional structures and the complexity of reconstructive methods.

Keywords: skin flaps, facial reconstruction, malignant cutaneous tumors

DOI: 10.21608/svuijm.2021.66180.1110.

***Correspondence:** b.elnkeeb@gmail.com.

Received: 7 February, 2021.

Revised: 20 February, 2021.

Accepted: 14 March, 2021.

Cite this article as: Basma M. Ali, Ahmed A. A. Ali, Asmaa Gaber R, Samia M. A. Saied. (2022). Versatility of Local Skin Flaps in Facial Reconstruction after Resection of Malignant Cutaneous Tumors. *SVU-International Journal of Medical Sciences*. Vol.5, Issue 2, pp: 17-26.

Introduction

The reconstruction of soft tissue facial defects following tumor excision represent a real challenge in terms of suitable surgical techniques, that able to restore complex anatomical facial structures (Crăcană et al., 2016).

The choice of an optimal reconstructive method for each patient is paramount to obtain excellent aesthetic and functional results (Yotsuyanagi et al., 2000).

Malignant cutaneous lesions of the face are variant with the most common in descending manner includes: basal cell carcinoma (BCC), squamous cell carcinoma (SCC), and malignant melanoma (Baser and Pradhan, 2007).

Malignant facial skin cancers are almost always curable when detected and treated early (Fritsch, 2002). Several treatment modalities that have been described as a reliable option for tumor ablation, such as, Mohs microsurgery, cryosurgery, radio ablation, electro cauterization and curettage ; however, the surgical excision has been reported to be the most definitive line of management of skin cancers (Moehrle et al., 2010).

Post ablative defects may concern any structure or anatomical subunit of the face. Furthermore, the characteristics of the skin and the capacity of wound healing are variable between patients (Daya-Grosjean et al., 2005).

Following tumor excision of the face, various reconstructive methods are available for reconstruction ,including primary closure, skin graft , local skin flaps, distant and free flaps. The primary closure of the defect is a simple and the most implemented technique and convenient in small defects, otherwise it has the risk of extreme wound tension along with an aggressive linear scar (Gloster, 2000).

Skin grafts cannot provide the same texture and color like normal skin of the face with low aesthetic results (Hurvitz et al., 2006).

Local skin flaps provide convenient option for facial defects reconstruction with a good color and texture match, along with a good success rate especially with small and medium sized defects and without donor site morbidity (Al-Sheikh et al., 2017).The study aims to evaluate the outcomes of types of local flaps that used in the coverage of facial cutaneous defects after the excision of skin tumors and explains its versatility over other methods of reconstruction.

Patients and methods

A. Patients:

Study design: This prospective study was conducted on patients admitted to the department of plastic surgery, Qena Faculty of Medicine, South Valley University from May 2019 to May 2020 (one-year duration). A total of fifty patients with malignant skin tumors in the face were included in the study.

The study was approved by the local Ethics Committee for research in human studies. Informed consent and written releases from patients for their photos were signed.

Inclusion criteria: Patients with early-stage cancer that is curable by radical resection and patients with compliance for follow up.

Exclusion criteria: Late stage or metastatic tumor that is not amenable to radical resection, patient refusal to surgery and medically unfit patients.

Study group: Our patients were classified into six groups according to the principle of facial esthetic units for facial defects reconstruction and included the following: Forehead, nasal, cheek, periorbital, perioral and periauricular.

B. Methods:

Special data sheet for all of patients was performed and included:

I. Full complete history:

Name, age, sex, occupation, marital state and special habits, admission date, discharge date, type

of malignancy, comorbidities: diabetes, coronary artery disease and hypertension and history of medications: anti-coagulants, antihypertensive.

II. General examination: General condition of the patient and vital signs.

III. Local examination:

Tumor: type, number, site and lymph nodes, defect: Site: Six regions (forehead, nose, periorbital, cheek, ears and lips), size and depth of the defect, number: single or multiple defects, extent of defect (presence of exposed structures): bones and Flap: type of flap, method of transfer,

IV. Investigations: Routine lab investigations: CBC, blood sugar, preoperative tissue biopsy and histopathology confirmation.

V. Photography

Surgical technique: Flaps were raised using their standard technique.

Preoperative Preparation: Preoperative flap design marking with marking pen or methylene blue paint. In case of axial flaps, a handheld Doppler was used before flap marking to predetermine the feeding perforators.

Anesthesia: Patients were underwent both general and local anesthesia. General anesthesia was used in fit patients with large sized defect and inoperable patients. While local anesthesia was used with operable, unfit patients with small sized lesions.

Position of the patient: All patients underwent their procedures in the supine position.

Operative details

Forehead Region: There were nine patients presented with of BCC in the forehead region. They were excised with adequate safety margin (5mm). variable types of local flaps were applied for defect reconstruction: rhomboid, rotation and advancement flaps.

Nasal Region: There were seventeen patients presented with of BCC in the nasal region. They were excised with adequate safety margin (5mm). Different types of local random and axial flaps were applied for reconstruction and included: forehead flap, nasolabial, dorsal nasal, and glabellar flaps

Cheek region: There were eleven patients presented with the three types of malignant tumors of the skin (8 cases had BCC, 2 had SCC and 1 case had melanoma) in the cheek region. They were excised with adequate safety margin (5mm for BCC 10, 1 mm for SCC and 2 cm for

melanoma). variable types of local random and axial flaps were applied for reconstruction and included: cheek advancement, transverse forehead flap, island nasolabial, rhomboid flap and advancement ", V-Y".

Periorbital region: There were three patients presented with of BCC in the periorbital region. They were excised with adequate safety margin (5mm). variable types of local random flap were performed: V-Y advancement, cheek advancement and glabellar flaps

Peri oral region: There were eight patients presented with BCC and SCC in the lips and chin region. cases had BCC and 4 cases had SCC. They were excised with adequate safety margin. Different types of local random and axial flaps were applied for reconstruction and included: Karapandzic, Abbe, nasolabial, V-Y advancement, bilobed

Peri Auricular region: There were two patients presented in the periorbital region. One case had BCC and the other had SCC.

Postoperative care:

1. A sterilized light dressing is applied.
2. Postoperative medications: antibiotics, antiedematous and analgesics.
3. Removal of stitches after two weeks.

Flap monitoring: Clinical evaluation was the best standard method for flap assessment:

1. Temperature: Should be as the body temperature.
2. Color: pink, not to be white nor blue/purple.
3. Capillary refill: about 2 seconds.
4. Consistency (turgor): Should be soft, but with some appreciable turgor.
5. Point bleeding: fresh blood should be present after introduction of fine needle.

Special Instructions: In case of lip reconstruction with Abbe flap and Karapandzic flap: the patient is started on a soft or liquid diet to minimize tension forces placed on the pedicle and to avoid excessive mouth opening.

Statistical analysis: Data were verified, coded by the researcher and analyzed using IBM-SPSS 21.0 (IBM-SPSS Inc., Chicago, IL, USA) *. Descriptive statistics: Means, standard deviations, medians, ranges and percentages were calculated. Test of significances: we used chi-square test to compare the difference in distribution of frequencies among

different groups. For continuous variables; ANOVA test analysis was carried out to compare the means of dichotomous data. A significant p-value was considered when it is equal or less than 0.05.

Results

Age and sex: A total of 50 patients with early-stage malignant skin tumors in the facial skin were underwent operation in the study. The age of patients ranged from 22- 77 years old with mean 49.5 years old. 40 patients were males and 10 patients were females with ratio (M: F = 4:1).

Type of tumors: The most prevalent type of malignant lesions of skin reported was basal cell carcinoma in 40 patients then squamous cell carcinoma in 9 cases and only one case with lentigo malignant melanoma.

Site of tumors: Nasal region was the most aesthetic facial subunit that affected by the tumor and reported in 17 patients then cheek in 11 patients, forehead in 9 patients, lip and chin in 8 patients, periorbital region in 3 patients and lastly auricular region in 2 patients.

Type of anesthesia: 30 patients were undergone operation under general anesthesia and 20 patients were treated under local anesthesia.

Size and site of defects: Size of defects ranged from 1.5x 1.5 cm to 7x 8 cm in diameter. donor sites were closed primary except in 3 patients with forehead flap that needed harvesting split thickness skin graft.

Forehead defects were lateral in 7 patients and central in 2 patients. Nasal subunit defects included 4 lateral sidewalls, 3 combined lateral sidewall and dorsum, 3 nasal roots, 3 nasal alae, 2 nasal dorsum and 2 nasal tips defects. Cheek subunit defects included 6 suborbital and 5 buccomandibular defects. In periorbital region defects included 2 lower eyelid and 1 medial canthal defects. Lip defects included 2 lower lip, 3 upper lip, 2 commissure and 1 combined commissure with upper lip defects. In auricular region, defects included 1 in helix and 1 earlobe defects.

Types of flaps: Reconstruction of defects of the face was performed by both local random and axial flaps. 29 patients had reconstructed their defects by local random flaps and 21 patients had

reconstructed their defects by local axial flaps. The most random flap applied was rhomboid flap in 14 patients then V-Y advancement flap in 5 patients, cheek advancement flap in 3 patients, bilobed flap in 3 patients, semicircular rotation in 2 patients, bilateral M flap advancement in one patient and bilateral H flap advancement in one patient.

The most axial flap applied was forehead flap in 6 patients (3 median, 2 paramedian and 1 transverse) nasolabial flap in 6 patients (4 superiorly based, 1 inferiorly based, 1 island), glabellar in 3 patients, dorsal nasal flap in 2 patients, Karapandizic flap in 2 patients and Abbe flap in 2 patients.

Wound closure: Primary closure was the most procedure performed except in 3 patients that underwent reconstruction by forehead flap by STSG.

Staged reconstruction: Forty patients had one stage flap procedure. But, 9 patients had two stage flap procedure: 5 patients with pedicled forehead flaps (second stage for flap separation in median and paramedian forehead flap and excision of dog ear deformity in patient with transverse forehead flap), 2 patients with Karapandizic flaps (second stage for treatment of microstomia) and 2 patients with Abbe flaps (second stage for flap separation).

Follow up: Follow up of the patients was done for a period from 6 to 12 months (mean 9 months).

Complications: Complications were reported in ten patients. two patients had wound infection and treated by frequent daily dressing and antibiotic medications. wound dehiscence occurred in two patients and they underwent restitching the wound. Also, hematoma was developed in two patients and then evacuated. Undesired cosmetic outcome due to scalp hair in one case of transverse forehead flap "2%" and this was managed by laser treatment. There was one patient that had partial flap ischemia and underwent coverage by split thickness skin graft. One patient had total flap ischemia and underwent surgical debridement and another flap procedure. Lastly, only one patient had recurrent tumor after 3 months and underwent wide resection and another flap procedure, shown in **table (2)**.

Table 1: Ratio between axial & random flaps

	Frequency	Percent
random	29	58.0%
axial	21	42.0%
Total	50	100.0%

Table 2: Complications

Complications	Number of cases	percent
Infection	2	0.04%
Wound dehiscence	2	0.04%
Hematoma	2	0.04%
Undesired cosmetic outcome	1	0.02%
Partial ischemia of the flap	1	0.02%
Total ischemia of the flap	1	0.02%
Recurrence of the tumor	1	0.02%

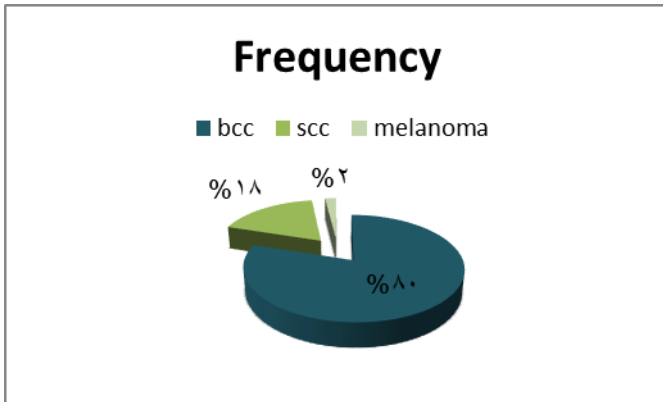


Fig. 1: type of tumor

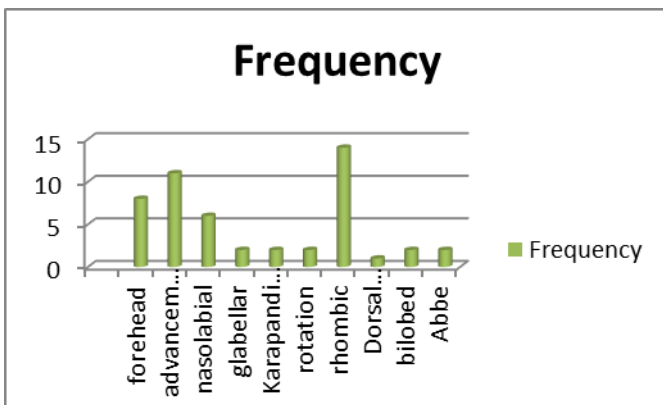


Fig. 2: percent of flap type

Table3: Relation between tumor type & face subunit

T. site		T.type			P value
		bcc	scc	melanoma	
nose	Count	15	2	0	0.1
	% within T.type	37.5%	22.2%	0.0%	
cheek	Count	8	2	1	
	% within T.type	20.0%	22.2%	100.0%	
forehead	Count	9	0	0	
	% within T.type	22.5%	0.0%	0.0%	
lip	Count	4	4	0	
	% within T.type	10.0%	44.4%	0.0%	
ear	Count	1	1	0	
	% within T.type	2.5%	11.1%	0.0%	
Periorbital area	Count	3	0	0	
	% within T.type	7.5%	0.0%	0.0%	

**Chi-square test was used to compare data

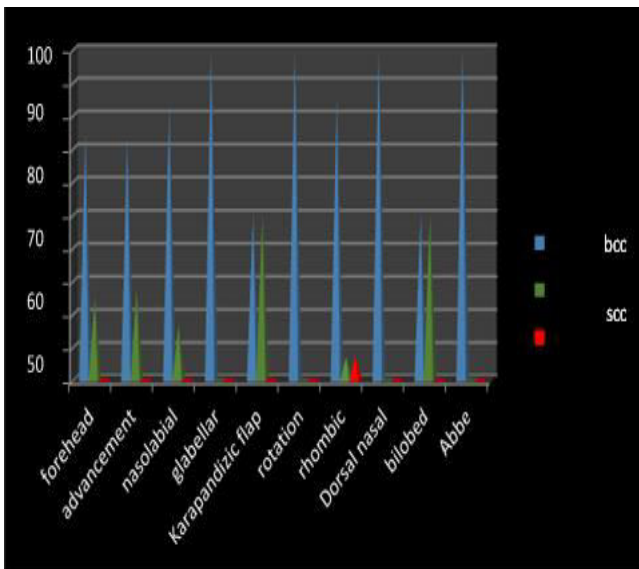


Fig. 3: Relation between flap type & T.type

Table 4: The relation between type of flab & age of patients

Variable	Mean \pm SD of age	P value
Forehead	65.5 \pm 6.3	0.05*
Advancement	63.2 \pm 11	
Nasolabial	59 \pm 14	
Glabellar	61 \pm 11	
Karapandizic flap	51.1 \pm 154	
Rotation	52 \pm 14.2	
Rhombic	62 \pm 11.3	
Dorsal Nasal	51.1 \pm 154	
Bilobed	59 \pm 13	
Abbe	61.5 \pm 11.7	

**ANOVA test was used to compare data

CASE PRESENTATION

Case 1:

A 57-year-old male presented with basal cell carcinoma on forehead. Under local anesthesia, the carcinoma was widely excised with 5 mm margin. The defect was circular in shape and 2*2 cm sized Khombic flap was elevated and transposed to the defect without tension Donar site closed primary, there is no complications detected. There was satisfaction with the final result.

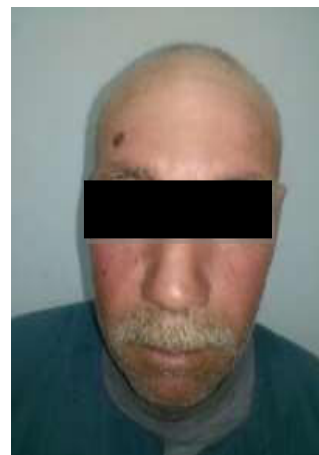

Fig.4(a): Preoperative bcc at lat. Forehead

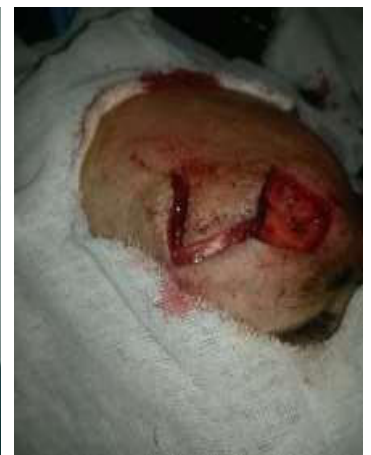

Fig.4 (b): Elevation of the flap

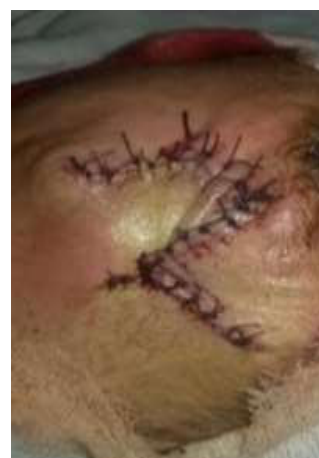

Fig.4 (c): immediate post operative

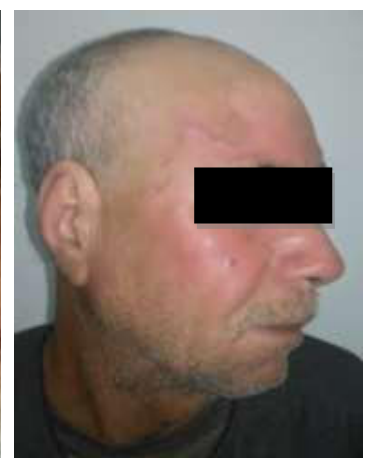

Fig.4 (d): 6 months post-operative

Case 2:

A 61-year-old male presented with basal cell tumor on the root of nose. Under general anesthesia, the lesion was widely excised with 5 mm margin. Nasal bone was exposed after radical excision of the tumor base. The defect was circular in shape and 2*2.5 cm sized. We identified left supratrochlear artery on the forehead. Considering simple closure of the donor site and the size of the defect, a 3 • 4 cm sized pedicled flap was elevated and transposed to the defect without tension. After 3 weeks separation of the base of the flap was done. There was satisfaction with the final result.

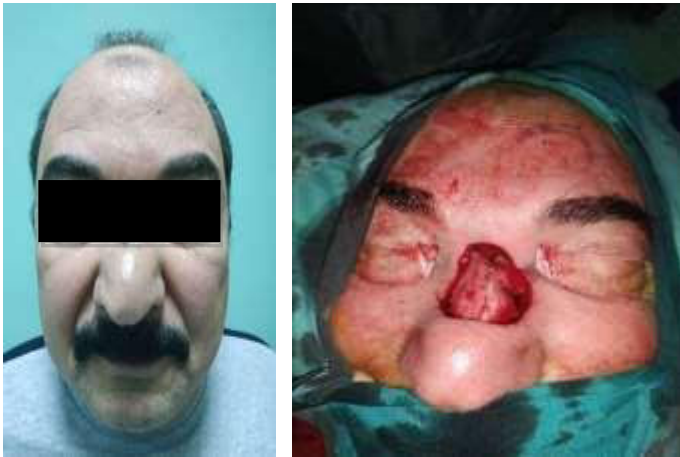

Fig. 5(a): pre-operative bcc , defect after excision nasal root .

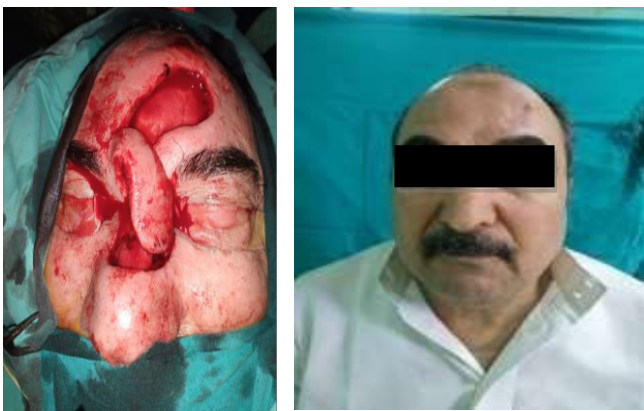

Fig. 5 (c): intraoperative flap insetting **Fig. 5 (d):** 9 month post-operative

Discussion

The most prevalent malignant cutaneous tumors of the face are basal cell carcinoma (BCC), squamous cell carcinoma (SCC) and malignant melanoma (McNay et al., 1997). BCC constitutes more than three quarters of skin cancers of the face and the rest primarily consist of SCC (McCraw et al., 1979).

The aim of treatment is curing the disease with a low recurrence rate along with better functional and cosmetic outcomes.

In our study, fifty patients with different malignant skin tumors had reconstructed with local facial flap. Reconstruction was based on aesthetic subunits of the face.

The forehead can be divided into three subunits. Anatomically, the central forehead is an extension of the scalp and has many similar characteristics. Central forehead skin is non stretchable , thick , and adherent to the underlying frontalis muscle. On either side of the central part

of the forehead is the lateral forehead or what is called temple region, which is more elastic and often acts as a reservoir of tissue for reconstruction (Lee et al., 2017).

The frontalis muscle is absent in the temple, and the skin is poorly attached to the underlying temporalis fascia. In addition, whereas the convexity of central forehead is present , the temple has its concavity. The relaxed skin tension lines (RSTLs) run horizontally in the central forehead, as demonstrated by the normal forehead wrinkles. Upon reaching the temporal scalp, they curve inferiorly (Ehrenfeld et al., 2012).

Closure of surgical defects of the forehead offers several challenges to the reconstructive surgeon. First, the forehead skin is relatively thick and has limited mobility. Second, the forehead is bounded by 2 important facial landmarks that, if altered, cause an obvious visual flaw: the brow and the hairline (Fatah, 1991).

There were nine patients presented with BCC in the forehead region, which located in the lateral forehead in 7 patients and in central forehead in 2 patients. . We applied 5 rhomboid, 2 rotation and 2 advancement flaps for defect reconstruction.

For central forehead defects, we believe that the advancement flap is the best choice for reconstruction of such defects. The advancement flap design, which is based on an incision that allows “sliding” movement of the tissue, is relatively simple and can be successfully applied to repair wide variety of small- or moderate-sized forehead defects. .

A study done by Mofiyinfolu Sokoya, Jared Inman, and Yadranko Ducic (mention the correct reference, like Ali et al, in 2017) reported that local flaps are advantageous in reconstructing scalp and forehead defects because of its ability to replace the defect with similarly appearing tissue (Ransom and Jacono, 2012). Moreover, local flaps are associated with very low complication rates of 3.4 % (Sokoya et al., 2018). Options for local flap closure include rotation, advancement, and transposition flaps. Ransom and Jacono, in 2012 advised that the design of local flaps in the forehead reconstruction should follow certain tenets, which include using wide bases and wide

undermining, as well as minimal use of cautery (**Ransom and Jacono, 2012**).

A study done by **Nicola et al in -----** on 200 cases for forehead reconstruction showed that the most common flap that was used for reconstruction lateral forehead defects and area above eyebrow was the advancement flap, accounting for 51.7 and 62.5% of reconstructions, respectively. Other methods include A-to-T flaps & rotation flaps (**Newman et al., 2004**).

In our study, nasal subunit defects included 4 lateral sidewalls, 3 combined lateral sidewall and dorsum, 3 nasal roots, 3 nasal alae, 2 nasal dorsum and 2 nasal tips defects. For these nasal defects reconstruction, we used 7 forehead flaps "4 median & 3 paramedian", 4 superiorly based nasolabial flap, 2 rhomboid, 1 bilobed, 1 dorsal nasal, 1 glabellar flap & 1 cheek advancement flap.

Forehead flap "median & paramedian" is the first choice for dorsum & lateral nasal wall defects reconstruction. It can achieve both (same meaning like the previous statement). aesthetic and functional nasal reconstruction that blends well with the face (**Gloster, 2000**).

The forehead flaps were used in reconstruction of 5 cases. The donor site was closed primary in 3 cases, while 2 cases needed a STSG. There were 4 cases that needed a 2nd stage operation for flap separation. We reported one case of total ischemia, for which reconstruction in other session was performed. Otherwise, there was no other complications reported.

For nasal root reconstruction, glabellar flap is our first choice flap. It provides similar texture match and has low complication rate..

Morrison and colleagues in 1955 described the reverse glabellar flap for distal defects (nasal tip, alar lobule, columella, and even the upper lip) and **Seyhan in 2009** used this reverse flap to reconstruct the lower eyelid, nose, medial canthal and malar region (**Millard, 1966**).

A study, in which 10 constructive surgeons chose their favorable technique for each esthetic unit, Showed that the selection of flaps were based on each one own experience. Several factors have been taken into their considerations during flap selection such as suitability of the

reconstruction method for the each defect, the last esthetic result, surgical difficulty, and hazard of complications (**Heller et al., 2008**). In the majority of cases, the infraorbital cheek was reconstructed using the Mustardé flap, followed by the rotation flap from lower areas of the cheek (the Blascovicz flap), and the Limberg flap. (**Heller et al., 2008**).

A study made by **Heller et al in 2008** on cheek reconstruction showed that local flaps such as the advancement, transposition, and rotational designs are versatile options in cheek reconstruction. The local flaps provide the best result due to the perfect matching of the skin in color, texture, thickness and adherence to one of the basic principles of plastic surgery, which is "Replace like with like" (**Heller et al., 2008**).

A Review of over 400 cases of post-Mohs' cheek reconstruction demonstrated that cervicofacial advancement flaps are the preferred choice for large defects that cannot be closed directly.. This technique has been popularized over the past 30 years because of mobilizing skin from an adjacent facial subunit with similar color and texture. of the cheek. (**Wells and Pap, 1995**).

All reconstructed patients had acceptable functional results and healed without complication except for one case of abbe flap which showed signs of infection and managed by daily dressing and antibiotic. Another case of karapandizik flap, which presented with minor dehiscence and managed by restitch. Otherwise, there was no flap failure and the cosmetic was acceptable in all cases.

A multicenter study in which 10 experienced constructive surgeons chose their favorable maneuver for each esthetic unit, showed that the A-T flap is the best option in reconstruction of the middle area (philtrum) of the upper lip, followed by the flag flap and the island flap (**Newman et al., 2004**).

In the lateral zones of the upper lip, the island flap was that of choice, followed by the A-T flap and the Bernard-Webster flap (**Heller et al., 2008**).

The bilateral peri alar horizontal advancement flap described by Celsus is widely used for upper lip vermilion defect when a simple

wedge is insufficient to repair all vermilion layer, followed by Abbe flap, and the inverted Karapandzic flap, which is a rotation-advancement flap of skin near the nasolabial sulcus (Heller et al., 2008).

Sun et al, reported that defects involving less than a third of the lip can be closed primarily (Singh et al., 2012).

A multicenter study in which 10 plastic surgeons with extensive experience in reconstructive surgery chose their preferred technique for each cosmetic unit was done and the result was as follows, Concerning periauricular defects the result was that the flap that received most votes for the helix of the ears was the helical advancement flap, followed by the retroauricular advancement flap and the Trendelenburg reduction plasty. The rhomboid flap was the flap of choice for the antihelix, followed by the single or double (O-Z) rotation flap and the A-T flap in third place. The majority of participating surgeons used a revolving door flap to repair the concha of the ear. In third place, the preauricular transposition flap in 2 stages (Heller et al., 2008).

Comparing our results with other studies , we conclude that local facial flaps are the simple and best option to reconstruct the small, medium & relatively large size facial defects. In addition, it provides excellent skin colour and texture match, and gives a good aesthetic result.

In our study there were some limitations: firstly, the limited number of patients that reported as large number is needed to provide a wide basic algorithm for reconstruction, secondly, some patients were non-compliant for regular follow up visits that need for flap monitoring and assurance of tumor clearance.

Conclusion:

The reconstruction of postoperative face defects after resection of locally malignant cutaneous tumors using local flaps is a real challenge from the perspective of surgical techniques, considering the difficulties determined by the restoring of three dimensional structures and the complexity of reconstructive methods.

References:

- Al-Sheikh, A. E. F. (2017).** Survival and aesthetic outcome of local flaps used for reconstruction of face defects after excision of skin malignancies: Multi-institutional experience of 175 cases. *International Journal of Current Research in Medical Sciences*, 3(5), 129-137.
- Crăcană, A., Costan, V. V., Nicolau, A., Popescu, E. (2016).** local flaps used in facial reconstruction after the excision of cutaneous carcinomas—retrospective study. *romanian journal of oral rehabilitation*, 8(2).
- Daya-Grosjean, L., Couvé-Privat, S. (2005).** Sonic hedgehog signaling in basal cell carcinomas. *Cancer letters*, 225(2), 181-192.
- Ehrenfeld, M., Cornelius, C. P. (2012).** Gestielte Gewebetransplantation. In *Mund-, Kiefer- und Gesichtschirurgie*. Springer, Berlin, Heidelberg, (pp. 589-643).
- Fatah, M. F. (1991).** Innervation and functional reconstruction of the forehead. *British journal of plastic surgery*, 44(5), 351-358.
- Fritsch, M. H. (2002).** Reconstruction following lateral skull base surgery with introduction of facial incisionless reanimation surgery. *Otolaryngologic Clinics of North America*, 35(2), 425-444.
- Gloster Jr, H. M. (2000).** The use of full-thickness skin grafts to repair non perforating nasal defects. *Journal of the American Academy of Dermatology*, 42(6), 1041-1050.
- Heller, L., Cole, P., Kaufman, Y. (2008).** Cheek reconstruction: current concepts in managing facial soft tissue loss. In *Seminars in plastic surgery*. Thieme Medical Publishers. 22(4):294-305
- Hurvitz, K. A., Kobayashi, M., Evans, G. R. (2006).** Current options in head and neck reconstruction. *Plastic and reconstructive surgery*, 118(5), 122e-133e.
- Lee, K. S., Kim, J. O., Kim, N. G., Lee, Y. J., Park, Y. J., Kim, J. S. (2017).** A comparison of the local flap and skin graft by location of face in reconstruction after resection of facial skin cancer. *Archives of craniofacial surgery*, 18(4), 255.
- McCraw, J. B., Magee Jr, W. P., Kalwaic, H. (1979).** Uses of the trapezius and sternomastoid myocutaneous flaps in head and neck reconstruction. *Plastic and Reconstructive Surgery*, 63(1), 49-57.
- Baser, B., Pradhan, K. A. (1988).** Bipedal myocutaneous flap for one-stage reconstruction of the cheek after cancer surgery. *The Journal of Laryngology & Otology*, 102(7), 601-602.
- McNay, A. T., Ostad, A., Moy, R. L. (1997).** Surgical pearl: modified rhombic flap. *Journal of the American Academy of Dermatology*, 37(2), 256-258.
- MILLARD Jr, D. R. (1966).** Total reconstructive rhinoplasty and a missing link. *Plastic and reconstructive surgery*, 37(3), 167-183.
- Moehrle, M., Breuninger, H., Schippert, W., Häfner, H. M. (2010).** Imiquimod 5% cream as adjunctive therapy for primary, solitary, nodular basal cell carcinomas before Mohs micrographic surgery: a randomized, double-blind, vehicle-controlled study. *Dermatologic Surgery*, 36(3), 428-430.
- Newman, M. I., Hanasono, M. M., Disa, J. J., Cordeiro, P. G., Mehrara, B. J. (2004).** Scalp reconstruction: a 15-year experience. *Annals of plastic surgery*, 52(5), 501-506.
- Ransom, E. R., Jacono, A. A. (2012).** Double-opposing rotation-advancement flaps for closure of forehead defects. *Archives of facial plastic surgery*, 14(5), 342-345.
- Singh, S., Singh, R. K., Pandey, M. (2012).** Nasolabial flap reconstruction in oral cancer. *World journal of surgical oncology*, 10(1), 1-5.
- Sokoya, M., Inman, J., Ducic, Y. (2018).** Facial Mohs Reconstruction: Scalp and Forehead Reconstruction. In *Seminars in plastic surgery* (Vol. 32, No. 2, p. 90). Thieme Medical Publishers. 32(2): 90–94
- Wells, D. M., Pap, G. S. (1995).** Sequentially linked free flaps in head and neck reconstruction. *Clin. Plast. Plastic and Reconstructive Surgery*, 96(1), 246.
- Yotsuyanagi, T., Yamashita, K., Urushidate, S., Yokoi, K., Sawada, Y. (2000).** Nasal reconstruction based on aesthetic subunits in Orientals. *Plastic and reconstructive surgery*, 106(1), 36-44.