

Topical Treatment of Feline Dermatophytosis

A.S. Hind^{1*}, H. S. Farag², M.M. Abdel Haleem², H.M. Elsaid²

1. Researcher.

2. Department of Internal Medicine and Infectious Diseases (Infectious Diseases), Faculty of Veterinary Medicine, Cairo University, Giza, Egypt.

* Correspondence author; H. S. Farag, e.mail: potta_amr@hotmail.com; tel: +201061862825

Abstract

Dermatophytosis is one of the most frequent fungal skin diseases of pet animals, with high cost of treatment, and difficult control measures. Also, the disease has an important public health consequence.

In our study, during a period of 2 year, 183 cats with cutaneous lesions were examined using direct microscopic examination and by fungal culture on Sabouraud Dextrose Agar (SDA). Out of 183 suspected samples, 94 cultured positive (51.4%). Where 73 samples showed colonies of *M. canis* (77.7%), while 13 showed *T. mentagrophytes* colonies (13.8%) and only 4 samples (4.3%) yielded mixed infection (*M. canis* and *T. mentagrophytes*). One sample (1.1%) was positive for *M. gypseum*, one sample (1.1%) for *T. verrucosum*, one sample (1.1%) for *T. phaseoforme* and one sample (1.1%) for *T. violaceum*.

Randomly, 25 dermatophytes-infected cats were allocated into 5 groups (5 cats each) where they are treated using topical antifungal agents; Terbinafine, Miconazole, Enilconazole, Ketoconazole as well as combined essential oils (EOs) where they were tested for their curative antifungal effects.

Results showed that topical treatment with combined essential oils have had a very effective antifungal curative effect. Also, antifungal agents showed clinical improvement of skin lesions in the following order: combined essential oils, Enilconazole, Miconazole, Terbinafine and Ketoconazole. The results also proved that local treatment appears to be effective in most cases with no need for systemic treatment.

Keywords

Dermatophytes, *T. phaseoliforme*, *T. verrucosum*, *M. canis*, Diagnosis, Treatment , oils (Eos)

1. Introduction

Dermatophytosis is a superficial fungal skin infection of pets and livestock animals with a potential zoonosis caused by pathogenic fungi dermatophytes [12]. Feline dermatophytosis is caused mainly by *Microsporum canis* (*M. canis*), with less frequent infections by *Microsporum gypseum* (*M. gypseum*) and *Trichophyton mentagrophytes* (*T. mentagrophytes*) [14, 32]. Also, *Trichophyton veruucosum* (*T. veruucosum*) has been isolated from different species including cats [3]. *Trichophyton violaceum* (*T. violaceum*) which is an anthropophilic fungus rarely isolated from animals has been reported from buffaloes, horses, cattle, cats, dogs, mice, sheep, a pigeon, and a mule [3, 49]. *Trichophyton phaseoliforme* (*T. phaseoliforme*) reported in soil in Poland, Switzerland and Venezuela also reported as saprophyte on small wild animals in Venezuela without any pathogenicity [8]. Scaling and crusting with or without alopecia; erythema; miliary dermatitis; onychomycosis and hyperpigmentation may be seen [51].

The most commonly used diagnostic tools include clinical examination, skin scrapings, (skin and hair cytology), and fungal culture. Cytologic examination of hairs plucked from lesions or the circumference of lesions may reveal fungal hyphae or chains of arthroconidia (ectothrix spores) in some affected animals [56].

Treatment is recommended for ethical and medical reasons to eliminate infective organisms from the skin and hair, and to prevent further dissemination of

the infective agent in the environment as well as zoonotic infection [26].

A variety of oral and topical antifungal agents are available to cure severe infections in animals and humans. One of the most effective procedures is a whole body treatment with a 0.2% Enilconazole solution performed twice weekly. Local or systemic side effects are seldom reported, provided that self-grooming is prevented (Elizabethan collar) until the cat is dry [22].

The antifungal action of allylamines is mediated by inhibition of ergosterol biosynthesis at a site much earlier in the pathway than the azole antifungal drugs [29, 30]. Allylamines are highly selective for the fungal enzyme and have a minimal effect on mammalian cholesterol synthesis, thus are more effective and less toxic to mammalian cells than azoles.

Ketoconazole is a systemically acting antimycotic drug belonging to the group of ketalized imidazoles. It has a broad spectrum antimycotic activity after topical or oral administration [58]. Miconazole nitrate is an agent with antifungal and antibacterial properties [20, 59]. Miconazole is licensed for use in dogs and cats and is included in an otic preparation for treatment of otitis externa (combination with polymyxin B and prednisolone; Surolan; Janssen, Elanco).

It is also effective as topical adjuvant on top of oral griseofulvin for treatment of dermatophytosis [48, 28, 55].

Plant-derived essential oils (EOs) and extracts are considered as non-phytotoxic compounds with antimicrobial and anti-dermatophytic properties [15].

The small molecular structure of the coconut oil allows easy absorption through the skin. The antiseptic fatty acids in the coconut oil helps to prevent fungal and bacterial infections in the skin when it is consumed and to some extent, when it is topically applied directly to the skin [31]. Topical application of olive oil on mice with pressure ulcers improves wound healing through its anti-inflammatory effect, reducing oxidative damage, and promoting dermal reconstruction [17].

Flax (*Linum usitatissimum*, LU), a member of the Linaceae family and a well-known herbal medicine, is an economically important oilseed crop cultivated worldwide. Omega-3 fatty acids and α -linolenic acid have potential anti-inflammatory, antihistaminic, antimicrobial, and anti-bradykinin activities [24].

Turmeric oil inhibited dermatophytes and pathogenic molds in vitro [6].

Studies have shown turmeric to be an excellent anti-inflammatory, antioxidant, antifungal, antibacterial, anticoagulant, antiseptic, astringent, helps with liver function, bile production and externally for wound healing [1]. Summarized that curcumin is safe in rodents, primates, horses, rabbits, cats, and humans [21].

The seeds of *Nigella Sativa* (*N. Sativa*) (black cumin) (Ranunculaceae) are commonly used in herbal medicine all over the world for treatment and prevention of several skin diseases and conditions [4]. Anti-dermatophyte activity of ether extract of *N. Sativa* and thymoquinone [TQ] which is major active chemical component of the essential oil was tested against eight species of dermatophytes: four species of *Trichophyton rubrum*, *Trichophyton interdigitale*,

Trichophyton mentagrophytes, *Epidermophyton floccosum* and *Microsporum canis* using Agar diffusion method with serial dilutions of ether-extract of *N. sativa*, TQ and griseofulvin. The MICs of the ether extract of *N. sativa* and TQ were between 10-40 and 0.125-0.250 mg/ml, respectively, while those of griseofulvin ranged from 0.00095 to 0.01550 mg/ml. These results denote the potentiality of *N. sativa* as a source for antidermatophyte drugs and support its use in folk medicine for the treatment of fungal skin infections [5].

Our study investigates the epidemiological features of dermatophytoses affecting cats in Giza governorate, and to study the distinctive characteristics of the local etiological isolates. Moreover, the in vivo evaluation of mixtures of essential oils in comparison to some commercial therapeutic agents for the treatment of dermatophytes-infected cats.

2. Material and methods

Animals and samples

One hundred eighty-three cats were subjected to the current study collected from shelters (Giza governate) and cats admitted to the small animal teaching hospital, Faculty of Veterinary Medicine, Cairo University, Giza, during the period from 2017 to 2019. The examined cats showing skin lesions such as scales, crusts, alopecia and erythema, located mainly on ear pinna, above eyes, legs, tail and abdomen. Crusts and plugged hairs were collected from the periphery of the lesion using sterile disposable scalpel blade and forceps .

Direct microscopic examination of skin lesions:

Crusts and plugged hairs were mounted on a clean glass slide with several drops of potassium hydroxide (KOH) 20%. A clean coverslip was applied, and the slides were scanned firstly under low power objective (10X) then switched to high power objective (40X) looking for the spherical arthrospores on the surfaces of the hairs (ectothrix) or within the hairs (endothrix) [25].

Isolation and identification of dermatophytes:

All collected samples were submitted for cultural examination according to [40]. Sabouraud's dextrose agar (SDA) was prepared according to [19], containing chloramphenicol and cycloheximide (to suppress bacterial and saprophytic fungal growth, respectively). Plucked hairs and crusts were inoculated in the center of the agar plate and pressed tightly with sterile bent needle to ensure firm contact with the medium. The plates were incubated at 28-30°C and observed for any evidence of fungal growth for 3 to 4 weeks before being considered as negative.

A small portion of the colony was placed with teasing needle on a clean microscopic slide containing few drops of lactophenol cotton blue (LPCB) stain, cover slipped, and examined microscopically under the low and high-power objectives for the presence of hyphae, microconidia and macroconidia. Identification of the dermatophytes species was done according to the key of [13].

Antifungal therapeutic trial:

A total number of 25 cats were allocated into five equal groups, as shown at (Table 1). Each group was subjected for topical antifungal therapy. Fungal

culture was performed 1 and 2 months after beginning of therapy to evaluate the clinical response. Before the application of drugs, the site of lesion was prepared by removal of scales by scraping of the moistened scales (with warm water and soap) with the aid of hard brush after clipping of the surrounding hairs, to get rid of infected material and to facilitate penetration of the topical remedy to come in-contact with causative agent. The removed scales were collected and burned to remove any source of infection.

The therapeutic agents applied in the study includes (Daktarin cream 2% (Miconazole), Imaverol 0.2% solution (Enilconazole), Lamisil 1% cream (Terbinafine), Nizoral 2% cream (Ketoconazole).

The oil mixture used as a topical treatment includes Coconut oil 50 ml, Olive oil 25 ml, Turmeric oil 5 ml, Nigella sativa oil 5 ml, and Flax-seed oil 15 ml)

Evaluation of the treatment efficacy of the employed therapeutic agents according to score system shown at table (6)

3. Results

The current study was carried out on 183 cats suffered from skin problem, 94 out of 183 cats were found culture positive for dermatophytes (51.4%). 83 cases of the 94 culture positive cats (88.3%) were positive for fungal elements by direct microscopic examination as demonstrated by endothrix and ectothrix present in the infected hairs.

The cats' age and sex factor also have impact on the disease prevalence, where the highest infection rate was recorded among cats below one year of age,

followed by cats between 1-3 years, (Table 2). Females showed higher affection rate than males (Table 3).

According to the breed, prevalence rate was higher in Persian breed cats followed by mixed breeds, Tortoise shell, Siamese, and then other breeds (Table 4). We also notice the effect of season on the prevalence, where higher number of affected cats was recorded in winter, followed by autumn, spring then summer (Table 5). Infection was also higher among sheltered cats than owned cats.

Physical examination revealed that, lesions were most commonly found on muzzle, lips, peri-ocular area, in and around the ear, the ear margins, digits, medial aspects of the limbs and tail. One or more areas of partial alopecia with scaling, crusting and erythema are the most common lesions.

Regarding concomitant infections, history taking and clinical examination of cats revealed some clinical problems (Table 7).

Out of the 94 cultured positive samples, 73 samples showed colonies of *M. canis* (77.7%), while 13 samples were showing colonies for *T. mentagrophytes* (13.8%). Four samples were mixed infections between *M. canis* and *T. mentagrophytes* (4.3%). One sample was positive for each of *M. gypseum* (1.1%), *T. verrucosum* (1.1%), *T. phaseoliforme* (1.1%) and *T. violaceum* (1.1%).

For Microscopic appearance of colonies, Lactophenol cotton blue (LPCB) was used as a mounting fluid to study the morphological characteristic of the isolated fungi (demonstrate the presence of hyphae, macroconidia, chlamydospores and other fungal structure).

After treatment, hair starts to re-grow within 7-14 days as shown in table 6. Fungal cultures were negative after one month of treatment except for 2 infected cats, one with ketoconazole and one with oil mixture. Repeated cultures one month later revealed negative results. Treatment stopped in all cases after 2 consecutive negative cultures (Table 6).

4. Discussion:

The main clinical signs observed among cats with dermatophytosis were erythema, alopecia, scaling, and crusting, while pseudo-mycetoma was not observed and this come in agreement with [51, 34] who reported similar skin lesions in cats with dermatophytosis.

Many predisposing factors were noted during this study like young age (39.4%) and old age (33%), prolonged therapy with antibiotics (12.8%), feline lower urinary tract diseases (7.4%) as (demonstrated by ultrasonography), pregnancy and recent parturition (6.3%), cortisone therapy (3.2%), flea infestation (74.5%), ear mites (33%). These predisposing factor agreed with [51] who mentioned that predisposing factors include stress, poor nutrition, debilitating disease, compromised immune status, or young age .

Infection was also high among sheltered cats and this may be attributed to poor nutrition, high density of animals, poor management, and lack of an adequate quarantine period for infected cats [11].

Pre-existing diseases will cause an increase in surface humidity, cause microtrauma to the skin and/or compromise host immune defenses. Once a nidus of infection has been established, the fungal species proceeds to invade the keratin of hair and skin to establish an infection [42].

Concerning age susceptibility, our results agreed with [33, 36] who reported that the predominant risk factor found to be significantly associated with dermatophytosis was age in which cats younger than one year of age showed a statistically significant higher prevalence of infection than older animals. Increased susceptibility to dermatophytosis in young animals can be explained by several factors, including lack of previous immunity, skin microtrauma (from siblings or ectoparasites), as well as frequent close contact with other cats during socialization periods [44].

Regarding gender, our results revealed that female cats showed higher infection rates than males, this finding was agreed with [38]. However, our results were not compatible with some studies as reported with [11, 36] who found that males showed significantly higher occurrence of dermatophytes than females and they attributed this to different composition of sebum of males when compared with females. Meanwhile, [27, 52] found that any sex was susceptible to dermatophytosis and there was no correlation between sex and the presence of infections.

Our results may be attributed to that the females were frequently exposed to various stress factors including estrus, pregnancy, nursing and close confinement with kittens which may predispose infection.

Discussing the breed susceptibility, the results agreed with findings of [11, 14, 23] who reported that Persian cats are more prone to dermatophytosis than other breeds.

In the same way, the prevalence varied according to location and season, mainly because of differences in climate [53]. Data on the seasonality of dermatophytosis in the literature revealed that dermatophytosis was more common in winter and autumn followed by spring then summer.

On the contrary, several authors found that, there is no correlation between the season and the occurrence of dermatophytosis [10,46]. In our study, autumn and summer were the periods with the highest and lowest risk for infection by dermatophytes, respectively. This comes in accordance with [11, 36, 39]. Warm temperatures favor the germination of spores beside moisture could explain why dermatophytosis is more common in Egypt.

Concerning the mycological examination, it was found that 94 out of 183 cats (51.4%) were infected with dermatophytes. Higher prevalence was recorded in Italy 27% to 50%, by [38], in Pakistan 25.6%, by [50], in Portugal 29.4% by [18] and in Tehran, Iran 55.9% by [43].

Lower prevalence was recorded in the UK 5% by [47]. The prevalence of animal ringworm varies according to climate and natural reservoirs [14]. Also, this may be attributed to the type, age and number of examined animals, location and environmental conditions [37].

In our study, *M. canis* was the most common dermatophyte isolated from cats (77.7%) followed by *T. mentagrophytes* (13.8%). as obtained by [54] who isolated *T. mentagrophytes*, *M. canis* and *M. gypseum* from domestic cats. Also *M. canis* isolated from (77%) of cats, followed by *M. gypseum* (10%) [11]. *M. canis* was identified in 98% of infected cats [41].

M. canis isolated from cats with percentage of 55.9% [43]. *M. canis* isolated with percentage of (69.7%), *M. gypseum* (6.1%), *T. mentagrophytes* (6.1%) by [52].

In accordance with [9], our investigation revealed that *M. canis*, *T. mentagrophytes* and *M. gypseum* are responsible for almost all the feline infections. Among the isolates *M. canis* was predominant species [9, 11].

Regarding other isolated species, *T. violaceum* was isolated from only one cat 1.1% of cases. *T. violaceum* was isolated from human patients with ringworm in Ismailia and Port Said Provinces [2]. Twenty of those patients (32.8%) had a history of contact with pet animals. This result agreed with reports by [47]. *T. verrucosum* was also isolated from 2 samples (2.1%). Calves and cows are the infection source *T. verrucosum* transmitting disease mainly to agricultural workers, children, and adolescents who are vacationing on a farm. The organism sometimes infects other animals like horses, pigs, dogs, and cats [35]. *T. phaseoliforme* was isolated from one cat (1.1 %); this organism was reported as non-pathogenic to humans or animals with worldwide distribution [57]. More studies are needed to investigate this species as a potential pathogen for animals and humans.

During our investigation we found that 83 out of 183 cats (22.3%) were positive for direct microscopic examination while 94 cats (51.4%) were culture positive. So, direct microscopy of samples was positive in 83 out of 94 cats that positively cultured (88.2%) . The positivity value (88.2%) found by direct examination was in accordance with those

described by [16, 10]. Our study correlates with other studies where microscopy was proved to be less sensitive than culture methods which remain the gold standard for the diagnosis of animal dermatophytosis. However, direct microscopy is the only method for the phenotypic identification of the causative dermatophyte species. Also, it is a highly efficient screening technique as it allows the veterinarian to start treatment independent of the culture report.

Skin lesions were topically treated with oil mixtures and 4 classes of antifungal topical drugs (Table 1). This approach of topical therapy was acceptable by [33] who suggested that many cases of dermatophytosis will respond to topical therapy without having to add in systemic drugs. Also, this approach was emphasized by [45] who indicated that topical therapy is preferred to oral drug administration because it is safe, effective and easily applied.

The therapeutic efficacy of a topical formulation depends on the nature of the vehicle and the physicochemical properties of the therapeutic agent. To attain the same local drug concentration, a higher oral dose is required, hence increasing the risk of adverse side effects. Topical therapy is indicated for animals with dermatophytosis and may be the sole therapy for local, non-diffuse lesions [7]. But it was not acceptable by several authors who considered topical therapy is unlikely to be effective on its own in eliminating infection. However, it may help reducing contamination of the environment and the spread of infection to owners and other animals. A combination of topical and systemic therapy is best in most cases [56].

All treated cats show evidence for hair growth within 7-14 days after treatment. One-month later samples of these cats were submitted for fungal culture to evaluate the effectiveness of therapy. Because clinical signs may improve before the animal is culture negative, treatment was stopped after the second negative culture. In the present study a mixture of essential oils applied once daily gave the best results followed by Enilconazole 0.2% solution twice weekly followed by Miconazole cream 2% twice daily then Terbinafine cream 1% once daily finally Ketoconazole cream 2% twice daily and all for four weeks (Table 6).

We concluded that; oil mixture causes faster hair growth and removal of scales and erythema. Commercial topical antifungal drugs are effective in treatment and can be used alone without systemic treatment. This comes in accordance with [12,32]. Although, dermatophyte infections generally are self-limiting, treatment helps to speed the resolution of the disease and minimize the risk of spread of infective spores to the environment [51].

5. Conclusion:

Although *M. canis* was the predominant fungal species isolated from cats with ringworm, in this study we report the isolation of other species like *T. verrucosum*, *T. violaceum* and *T. phaseoliforme* which are rarely reported in cats. Further studies regarding these organisms should be done.

The results of this field study with different therapeutic agents have shown that essential oils are efficacious in the treatment of clinical signs of dermatophytosis as measured by the reduction of the

number and severity of lesions beside the results of fungal culture. Essential oils were able to stimulate healing and shorten the clinical course of the disease besides softening of the skin, which are clear benefits from its use. However, no published literatures studied the use of combined EOs with each other as antimicrobial agents. Thus, further studies are needed to establish optimal treatment protocols to achieve reliable results using combined essential oils.

6. References:

1. <https://www.thepurringtonpost.com/turmeric-for-cats/> accessed at 13/9/2020.
2. Aboueisha, A.M. and El-Mahallawy, H. (2013) Public health significance of dermatophytes in Ismailia and Port Said Provinces, Egypt. *Med Mycol J*, 54: 123-129.
3. Ainsworth, G.C., and Austwick, P.K.C. (1973) *Fungal Diseases of Animals*, 2nd ed. Farnham Royal, Slough, England, Commonwealth Agricultural Bureaux.
4. Ali, B.H. and Blunden G, (2003) Pharmacological and toxicological properties of *Nigella sativa*, *Phytother. Res*, 17: 299-305.
5. Aljabre, S.H., Randhawa, M.A., Akhtar, N., Alakloby, O.M., Alqurashi, A.M., Aldossary, A. (2005) Antidermatophyte activity of ether extract of *Nigella sativa* and its active principle, thymoquinone. *J Ethnopharm* 101(1-3): 116-119.
6. Apisadyakul, M., Vanittanakam, N. and Buddasukh, D. (1995) Antifungal activity of turmedc oil extracted from *Curcuma Ionga*. *J Ethnopharmacol*, 49:163-169.

7. Bond, R. (2010) Superficial veterinary mycoses. *Clin Dermatol*, 28:226-236.
8. Borelli, D. and Feo, M. (1966) *Trichophyton phaseoliforme*, nova species. *Medicina cutanea (Barcelona)* 2:165-172.
9. Brillhante, R.S.N., Cavalcante, C.S.P, Soares-Junior, F.A, *et al.*, (2003) High rate of *Microsporum canis* feline and canine dermatophytoses in Northeast Brazil: Epidemiological and diagnostic features. *Mycopathologia*, 156:303-308.
10. CABAÑES, F.J.; ABARCA, M.; BRAGULAT, M. (1997) Dermatophytes isolated from domestic animals in Barcelona, Spain. *Mycopathologia.*, v. 137, p. 107-113.
11. Cafarchia, C., Romito, D., Sasanelli, M., *et al.*, (2004) The epidemiology of canine and feline dermatophytoses in southern Italy. *Mycoses*, 47:508-513.
12. Carlotti, D.N., Guinot, P., Meissonnier, E., *et al.*, (2009) Eradication of feline dermatophytosis in a shelter: a field study. *Vet Dermatol*, 21:259-266.
13. Carter, G.R. and Cole, J.R. (1990) *Diagnostic Procedures in Veterinary Bacteriology and Mycology*, 5th Ed. Academic Press, San Diego, California, pp. 271-276.
14. Chermette, R., Ferreiro, L. and Guillot, J. (2008) Dermatophytoses in animals. *Mycopathologica*, 166:385-05.
15. Chuang, P.H., Lee, C.W., Chou, J.Y. *et al.*, (2007) Antifungal activity of crude extracts and essential oil of *Moringa oleifera* Lam. *Bioresour Technol.* 98:232-236.
16. Copetti, M.V., Santurio, J.M., Cavalheiro, A.S, *et al.*, (2006) Dermatophytes isolated from dogs and cats suspected of dermatophytes in Southern Brazil. *Acta Scientiae Veterinariae*, 34:119-124.
17. Donato-Trancoso, A., Monte-Alto-Costa, A. and Romana-Souza, B. (2016) Olive oil-induced reduction of oxidative damage and inflammation promotes wound healing of pressure ulcers in mice. *J Dermatol Sci*, 83:60-69.
18. Duarte, A., Castro, I., Pereira da Fonseca, I.M. *et al.*, (2010) Survey of infectious and parasitic diseases in stray cats at the Lisbon Metropolitan Area, Portugal, *J Feline Med Surg*, 12:441-446.
19. Fisher, F. and Cook, B.N. (1998) *Fundamentals of diagnostic mycology*, by W.B. saunders, Philadelphia, Pennsylvania.
20. Godefroi, E.F., Heeres, J., Van cutsem, J.B. *et al.*, (1969) The preparation and antimycoric properties of derivates of 1-phenethylimidazole. *J. Med. Chem.* 12, 784-791.
21. Gupta, S.C., Kismali, G., Aggarwal, B.B (2013) Curcumin, a component of turmeric: from farm to pharmacy. *Biofactors* 39:2–13 https://link.springer.com/chapter/10.1007/978-3-030-04624-8_1 Date accessed 13/9/2020 [PubMed](#) [Google Scholar](#) .
22. Hnilica, K.A. and Medleau, L. (2002) Evaluation of topically applied enilconazole for the treatment of dermatophytosis in a Persian cattery. *Vet Dermatol*; 13: 23–28.

23. Huisman, E.A.P. (2013) Risk factors of feline dermatophytosis in the Netherlands, Faculty of Veterinary Medicine Theses (Master thesis).
24. Kaithwas, G., Mukherjee, A., Chaurasia, A.K. *et al.*, (2011) Antiinflammatory, analgesic and antipyretic activities of *Linum usitatissimum* L. (flaxseed/linseed) fixed oil. *Indian J Exp Biol*, 49:932-938.
25. Larone, D.H. (2011) Medically important fungi: A guide to identification, 5th ed. American Society for Microbiology. Washington, D.C.
26. MacDonald, J. (2006) Antifungal drug therapy. *Proceedings of the North American Veterinary Conference, Orlando, Florida*, 20:391-392.
27. Mancianti, F., Nardoni, S., Cecchi, M. *et al.*, (2002) Dermatophytes isolated from symptomatic dogs and cats in Tuscany, Italy during a 15-year-period. *Mycopathologia*, 156:13-1.
28. Mason, K., Frost, A., O'Bolye, D. & Connole, M. (2000) Treatment of a *Microsporum canis* infection in a colony of Persian cats with griseofulvin and a shampoo containing 2% miconazole, 2% chlorhex-idine, 2% miconazole and chlorhexidine or placebo. 4th World Congress of Veterinary Dermatology, pp. 55 (poster p-43). SanFrancisco, USA.
29. Matusевич, A., Ivaskiene, M., Spakauskas, V. (2008a) Antifungal drugs. Part I. Fungal cell structure, function and susceptible targets for antifungal agents. *Review. Vet Med Zoot* 43: 3-13.
30. Matusевич, A., Ivaskiene, M., Spakauskas, V. (2008b) Part II. Antifungal drugs, antifungal substance, compounds and drugs. *Review. Vet Med Zoot* 44: 3-22.
31. Mercola J, 2006. Why Coconut Oil Is Said To Be The Healthiest Oil On Earth? http://www.mercola.com/forms/coconut_ol.htm. Date accessed 17/7/2020
32. Moriello, K.A. and DeBoer, D.J. (2012) Dermatophytosis. In: Greene CE (ed). *Infectious diseases of the dog and cat*. 4th ed. St Louis: Elsevier, pp 588-602.
33. Moriello, K.A. (2004) Treatment of dermatophytosis in dogs and cats: review of published studies. *Vet Dermatol*, 15:99-107.
34. Moriello, K.A., Coyner, K., Paterson, S. *et al.*, (2017) Diagnosis and treatment of dermatophytosis in dogs and cats. *Clinical Consensus Guidelines of the World Association for Veterinary Dermatology. Vet Dermatol*, 28:266-268.
35. Morrell, J. and Stratman, E. (2011) Primary care and specialty care delays in diagnosing *Trichophyton verrucosum* infection related to cattle exposure. *J Agromedicine* 16:244-250.
36. Murmu, S., Debnath, C., Pramanik, A.K. *et al.*, (2015) Detection and characterization of zoonotic dermatophytes from dogs and cats in and around Kolkata. *Vet World*, 8: 1078-1082.
37. Nassif, M.M. and Osman, S.A. (2003) An outbreak of dermatophytosis in goat kids. *Assiut Vet Med J*, 49: 142-155.
38. Natale, A., Regalbono, A.F.d., Zanellato, G. *et al.*, (2007) Parasitological survey on stray

- cat colonies from the Veneto Region. *Vet Res Commun*, 31:241-244.
39. Nikonov, V.A. (2018) Dermatophytosis in dogs and cats: molecular identification and epidemiology. Thesis, Faculty of Veterinary Medicine, University of Lisbon, 81 pages.
 40. Nilce, M., Martinez, R. and Nulu, T.A. (2008) Antifungal resistance mechanism in dermatophytes. *Mycopathologia*, 166:369-383.
 41. Nweze, E.I. and Eke, I.E. (2018) Dermatophytes and dermatophytosis in the eastern and southern parts of Africa. *Medical Mycol. Narnia*.
 42. Ogawa, H., Summerbell, R.C., Clemons, K.V, *et al.*, (1998) Dermatophytes and host defence in cutaneous mycoses. *Med Mycol*, 36:166-173.
 43. Omran, A.N., Hashemi, S.J. and Hashemi, F. (2010) Epidemiology of superficial and cutaneous mycosis in 5500 suspected patients in Tehran. *Tehran Uni Med J*.
 44. Ovchinnikov, R.S., Savinov, V.A., Gaynullina, A.A, *et al.*, (2020) Epidemiological survey of ringworm outbreak in cat shelter. *IOP Conf. Ser.: Earth Environ*.
 45. Ozcan, I., Abaci, O., Uztan, A.H, *et al.*, (2009) Enhanced topical delivery of terbinafine hydrochloride with chitosan hydrogels. *AAPS Pharm Sci. Tech.*, 10:1024-1031.
 46. Palumbo, M.I.P., De Araújo MacHado, L.H., Paes, A.C. *et al.*, (2010) Epidemiologic survey of dermatophytosis in dogs and cats attended at the dermatology service of the College of Veterinary Medicine and Animal Science of UNESP - Botucatu", *Semina:Ciencias Agrarias*, 31:459-468.
 47. Patel, A., Lloyd, D.H. and Lampion, A.I. (2005) Survey of dermatophytes on clinically normal cats in the southeast of England. *J.small Anim Prac*, 46: 436-439.
 48. Paterson, S., Pott, J. & Jones, A. (1996) The use of a 2% chlorhexi-dine 2% miconazole shampoo in the treatment of dermatophytosis. Abstract of the 3rd World Congress of Veterinary Dermatology. p. 72. Edinburgh, UK.
 49. Rebell, G. and Taplin, D. (1970) *Dermatophytes—Their Recognition and Identification*, 2nd ed. Coral Gables, Florida, University of Miami Press.
 50. Saleem MI, Mahmood AK, Qudus A, *et al.*, 2020. Prevalence of dermatophytosis and efficacy of antifungal agents against *Microsporum canis* in cats. *PAB*, 9:121-131.
 51. Scott, D.W., Miller, W.H. and Griffin, C.E. (2001) Fungal skin diseases. In: Muller and Kirk's *Small Animal Dermatology*, 6th edn. Philadelphia: W.B. Saunders, 336-361.
 52. Sekar, E. and Dogan, N. (2011) Isolation of dermatophytes from dogs and cats with suspected dermatophytosis in Western Turkey. *Prev Vet Med*, 98:45-51.
 53. Simpanya, M.E. and Baxter, M. (1996) Isolation of fungi from the pelage of cats and dogs using the hairbrush technique. *Mycopathologia*, 134:129-133.
 54. Soedarmanto, I., Purnamaningsih, H., Raharjo, S. *et al.*, (2014) Isolation and Identification of

- Microsporium canis from Dermatophytosis Dogs in Yogyakarta. *J Veteriner*. 15:212-216.
55. Sparkes, A., Robinson, A., MacKay, A. & Shaw, S. (2000) A study of the efficacy of topical and systemic therapy for the treatment of feline *Microsporium canis* infection. *Journal of Feline Medicine and Surgery*, 2, 135–142.
56. Sykes, J.E. and Outerbridge, C.A. (2014) Dermatophytosis. In: *Canine and Feline Infectious Diseases* (Eds. Sykes, J. E.), Elsevier Saunders Inc., St. Louis, Missouri, U.S., pp. 558-569.
57. Tchernev, G., Penev, P.K., Nenoff, P. *et al.*, (2013) Onychomycosis: modern diagnostic and treatment approaches. *Wien Med Wochenschr*, 163:1-1.
58. Thienpont, D., Van Cutsem, J., Van Gerven, F, et al., (1979) Ketoconazole 7a new broad spectrum orally active antimycotic. *Experientia*, 35, 606.
59. Van cutsem, J.B., Thienpont, D. (1971) Miconazole, a broad spectrum antimycotic agent with antibacterial activity (in preparation).

Table 1: classification of treatment groups according to drug used:

Treatment groups	Trade name and / form	Manufacture	Active principle and/or quantity used (per 100 ml of combined essential oils)	Treatment regimen
1	Daktarin 2% cream	MINAPHARMA	Miconazole nitrate	Twice daily
2	Nizoral 2% cream	MINAFPHARMA	Ketoconazole	Twice daily
3	Lamisil 1% cream	NOVARTIS	Terbinafine hydrochloride	Once daily
4	Imaverol 100mg/ml	ELANCO	Enilconazole 0.2% solution	Twice weekly
5	Parsudhi coconut oil	Nilamels	Coconut oil (50ml)	Once daily for four weeks
	Curcumin extract (turmeric) oil	ZAMZAM	Turmeric oil (5ml)	
	Linseed oil	EL-HAWAG	Linolenic acid, glycosides, vit E, and C (15ml)	
	Black seed oil	EL-CAPTIN	Organic nigella sativa (5ml)	
	Virgin olive oil	TORSINA	Virgin olive oil (25ml)	

Table 2: Prevalence of dermatophytosis in cats of different ages:

Age (Years)	No. of examined animals	No. of infected animals	Percentage of infected animals to the examined animals	Percentage of infected animals to the totally infected cases
< 1	48	37	77.1	39.4
1 - 3	69	26	37.7	27.7
> 3	66	31	47	32.9
Total	183	94	51.4	100

Table 3: Prevalence of dermatophytosis in cats according to sex:

Sex	No. of examined animals	No. of infected animals	Percentage of infected animals to the examined animals	Percentage of infected animals to the totally infected cases
Male	81	41	50.6	43.6
Female	102	53	33.3	56.4
Total	183	94	51.4	100

Table 4: prevalence of dermatophytosis of cats according to breed

Breeds	No. of examined animals	No. of infected animals	Percentage of infected animals to the examined animals	Percentage of infected animals to the totally infected cases
Persian	99	61	61.6	64.9
Mixed	38	15	39.5	16
Tortoiseshell	12	4	33.3	4.2
Siamese	4	3	75	3.2
Other breeds	30	11	36.7	11.7
Total	183	94	51.4	100

Table 5: prevalence of dermatophytosis of cats according to season

Season	No. of examined animals	No. of infected animals	Percentage of infected animals to the examined animals	Percentage of infected animals to the totally infected cases
Summer	45	13	28.9	13.83
Spring	49	21	42.9	22.34
Winter	46	33	71.7	35.11
Autumn	43	27	62.8	28.72
Total	183	94	51.4	100

Table 6: assessment of treatment groups according to scoring system of clinical improvements

Treatment groups	Weeks post treatment application								Result of dermatophytes isolation after treatment	
	1	2	3	4	5	6	7	8	First culture	Second culture
Group 1 / Miconazole	2	2	1	1	0	0	0	0	2	All negative
Group 2 / Ketoconazole	5	4	4	3	3	2	2	1	Four negatives and one positive	All negative
Group 3 / Terbinafine	3	2	1	1	0	0	0	0	All negative	All negative
Group 4 / Enilconazole	2	1	1	0	0	0	1	1	All negative	All negative
Group 5 / Combined Essential oils	2	1	0	0	0	0	0	0	Four negatives and one positive	All negative

0, Normal without lesion.

1, complete regrowth of hair.

2, Partial growth of hair without crusts or scale or exudate.

3, Partial growth of hair with mild crusts or scale or exudate.

4, Partial growth of hair with prominent crusts, scales and exudate.

5, Alopecia with prominent crust and scales and exudate.

Table 7: predisposing factors of dermatophytosis

Predisposing factors	Total number of cases
Prolonged antibiotic therapy	12 (12.8%)
Feline lower urinary tract diseases	7 (7.4%)
Pregnancy and recent parturition	6 (6.3%)
Cortisone therapy	3 (3.2%),
Flea infestation	70 (74.5%)
Ear mites	31 (33%)

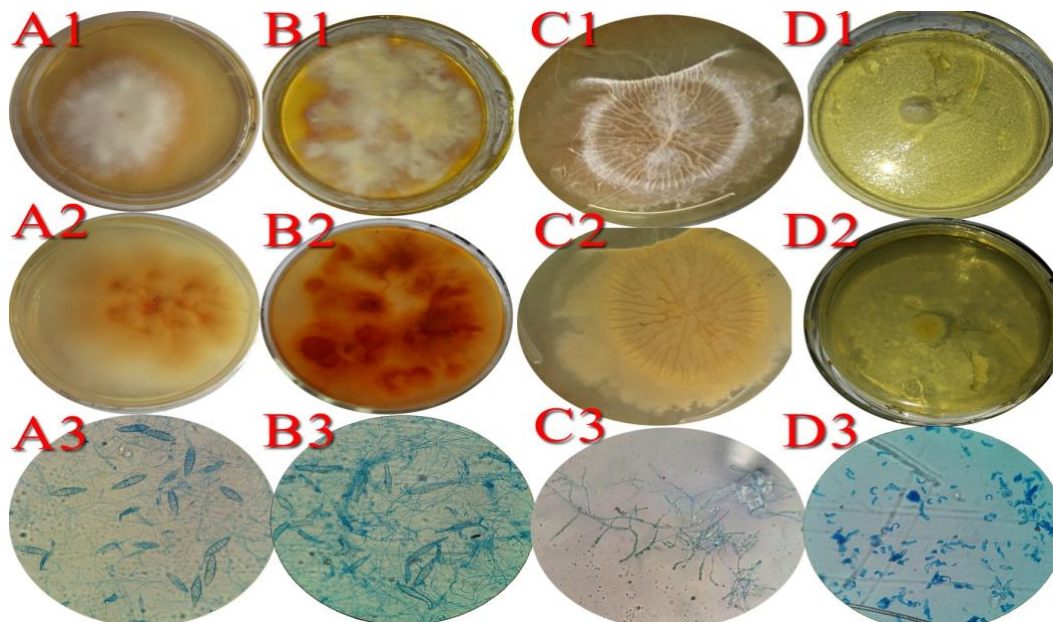


Fig. 1. On sabouraud dextrose agar and under high power (40X) respectively show A1,2,3 *M. canis*; B1,2,3 *M. distortum*; C1,2,3 *T. verrucosum*; D1,2,3 *T. phaseoliforme*

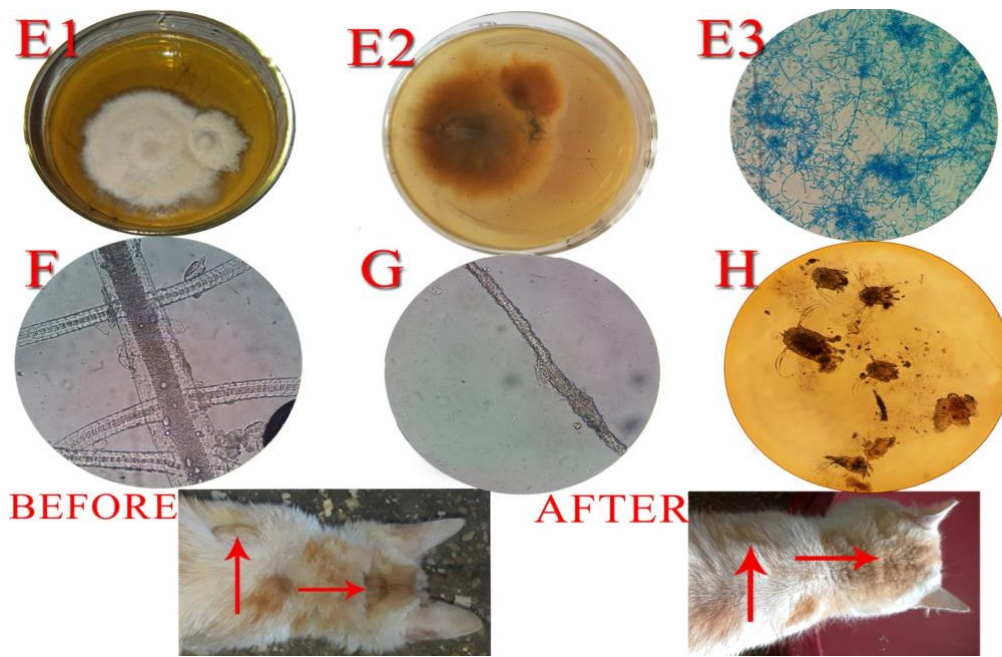


Fig.2. On sabouraud dextrose agar and under high power (40X) respectively show E1,2,3 *T. mentagrophytes*, F endothrix dermatophytes spores, G ectothrix dermatophytes spores, H different sizes of ear mites of cat, before dermatophytes infected cat at neck and scapular region, after treatment show hair growth after treatment by combined essential oils