

Anterior Temporal Eminectomy for Internal Derangement Of The Temporomandibular Joint with Local Anesthesia

Mohamed A. Hashem^{1*} M.B.B.Ch; Moustafa S. Meky¹ MD; Mahmoud A. Ameen¹ MD;

Salah Abd Elghany² MD

*Corresponding Author:

Mohamed A. Hashem

asem6064@gmail.com

Received for publication January 01, 2021; **Accepted** February 28, 2021; **Published online** February 28, 2021.

Copyright 2020 The Authors published by Al-Azhar University, Faculty of Medicine, Cairo, Egypt. All rights reserved. This is an open-access article distributed under the legal terms, where it is permissible to download and share the work provided it is properly cited. The work cannot be changed in anyway or used commercially.

doi: 10.21608/aimj.2021.62420.1417

¹Plastic surgery Department, Faculty of medicine, Al-Azhar university, Damietta, Egypt.

ABSTRACT

Background: Temporomandibular joint (TMJ) problems frequently characterized by pain and impairment of joint function and clicking sounds. TMJ internal derangement (ID) is the main widespread kind of temporomandibular disorders (TMDs), as 41.1% of suffers from TMD. Almost twenty-five percent of the population has an ID. TMJ ID's treatment regimens can be categorized into two subgroups: conservative and surgical. Early degrees of ID may be treated with medical or minimally invasive techniques according to Wilkes classification; however, the more advanced degrees (IV or V) may need open joint surgery.

Objective: Study assesses the effectiveness of anterior temporal eminectomy in management of the manifestation of the ID of the TMJ disorder.

Patients and methods: From Nov 2019 to Nov 2020. includes 10 patients with ID of the TMJ, presented to Plastic Surgery outpatient clinic, Damietta Al-Azhar University Hospital.

Results: We include 10 patients 3 males, 7 females with a mean age of 32.70 ± 8.69 years. Pain was presented in 5 patients, improved in 4 patients postoperatively. Clicking was present pre-operatively in 7 cases, which resolved in 5 patients after surgery.

Conclusion: Anterior eminectomy is a technique recommended for the management of ID. It enables the non-reducible disk to be a reducible disk, prevents pain inside of the TMJ, and promotes the flexible movement of TMJ. It's a safe, successful surgical technique that playing a role in the treatment as a 2nd-line surgical option in the treatment of ID of TMJ after other conservative medical options has fail.

Keywords: Eminectomy; Internal Derangement; Temporomandibular Joint, Disc displacement and Local Anesthesia.

Disclosure: The authors have no financial interest to declare in relation to the content of this article. The Article Processing Charge was paid for by the authors.

Authorship: All authors have a substantial contribution to the article.

INTRODUCTION

Two separate temporomandibular joints (TMJ) are linking the base of the cranium with the mandible to form the temporomandibular articulation. The TMJ is a complex joint in both morphologically and functional features.¹

The temporomandibular joint varies mostly in its sliding feature from other body joints and has joint surfaces and a fibro-cartilaginous disk. Ligaments that make rotation on the condyle during translational jaw motions are attached to the condyle by the disk.²

The issue of the temporomandibular joint (TMJ) is commonly characterized via pain and reduced joint function and the clicking sound of the joint. TMJ Internal Derangement (ID) is the most frequent kind of temporomandibular disorder (TMD) including 41.1 percentage of the cases with TMD.³

TMJ ID can be described as dysfunction of the joint combined with improper disk positioning. Moreover,

the description could be clarified as the joint dysfunction related to an improper disk location and disruption to the inner structures of the TMJ.⁴

More recently, findings using magnetic resonance imaging show that the articular disk is displaced in 35 percent of asymptomatic people. Approximately 25 percent of the entire population has an internal derangement.⁵

The therapeutic options of internal derangement of temporo-mandibular joint, could be categorized into 2 groups medical and surgical. As regard to Wilkes classification, early stages of ID could be treated through conservative or minimally invasive Procedures; moreover, late stages (IV or V) may need open joint surgery.³

Conservative management is the main treatment for TMJ ID. The two popular solutions are occlusal splint insertion and physical therapy. These

conservative approaches will effectively treat about 90 percent of all temporomandibular disorders (TMD). However, more invasive intervention, such as Eminectomy, is required for the 10 percent who are refractory to non-surgical procedures.⁶

A pre-auricular incision to exposing the eminence accompanied via total excision followed by re-contouring of the eminence used to be performed through eminectomy considering the standard surgical technique. This technique helps to minimize mechanical interference and enables the joint translation surface to operate smoothly.⁷

Unlike the other open TMJ surgeries, this technique is intra-capsular, and the disk is also not surgically repositioned, so there is no contact with the inner joint system.⁸

The main danger of damage to temporal and zygomatic divisions of the facial nerve is reported in the surgical intervention. Effectiveness of the surgery could be assessed by the following items: decline in pain sensation, improved function (no more limited mouth widening), and greater disappearance in clicks sound.⁹

PATIENTS AND METHODS

A prospective review of the reports of 10 individuals with ID of the TMJ throughout this clinical trial, presented to Plastic Surgery outpatient clinic, Damietta Al-Azhar University Hospital, insurance Hospital and Damietta Military Hospital. This took place from Nov 2019 to Nov 2020.

Patients were categorized according to the following inclusion criteria; 18 to 45 years old, disc displacement without reduction (DDWOR) with restricted oral opening grade 4 & 5 according to Wilkes classification; failure of previous conservative treatment, Pain, mild to major restriction of mandibular motion, disturbing joint clicking sounds, and confirmation of disc displacement by MRI report & films.

Patients with Previous temporomandibular joint surgery, trauma, congenital malformation, tumor and Systemic causes (as rheumatoid arthritis) were excluded.

Each participant was subjected to full history taking, clinical evaluation; especially assessing mouth opening, range of mandibular movement, crepitation, and muscle of mastication. Preoperative assessment was performed using panoramic radiography image, MRI, and computed tomography.

Surgical processes had been done for all patients with local anesthesia (the cartridge contain 2% lidocaine 1.8ml and epinephrine 1:100,000) was injected subcutaneously in the pre-auricular region. Sedation also may be used if the patient cannot tolerate the pain during surgery. Pre-auricular facial hair was shaved. All patients were given triple antibiotics IV, preoperative.

A permanent marker is used to marking the endural retro-tragal approach, around the skin crease, and to contour the incision across its tragal cartilage.

The marking of the incision originates from the highest point of the ear and continues below the tragal cartilage, and does not even reach to the ear pinna. Scrubbing of the surgical sites was done by povidone-iodine. An incision was made along the marked line by using a scalpel handle and blade number 15.

A skin flap was done to uncover the outer layer of the temporalis fascia. Blunt dissection with periosteal elevators was performed parallel to the external auditory cartilage. An incision at the fascia and blunt dissection were performed to expose the zygomatic arch and its articular eminence. Exposure to the inner component of the TMJ and its disc through entry into the superior joint cavity.

Anterior eminectomy was performed by using a rotating round bur until the bony surfaces of the eminence become flat and smooth with removing any irregularities and the mandible moved smoothly without any locking. Finally, the incision became sutured in layers.

Active mouth opening was done intraoperatively by telling the participants to open and close the mouth as much as they can to assess the clicking, maximum mouth opening, immediately after the removal of the articular eminence.

Excessive mouth opening and solid food plan were avoided for three weeks, and sutures were removed after 7 - 10 days. All patients have been recalled after one week for clinical assessment. The further clinical exam was scheduled after 1 and 3 months (figure 1).

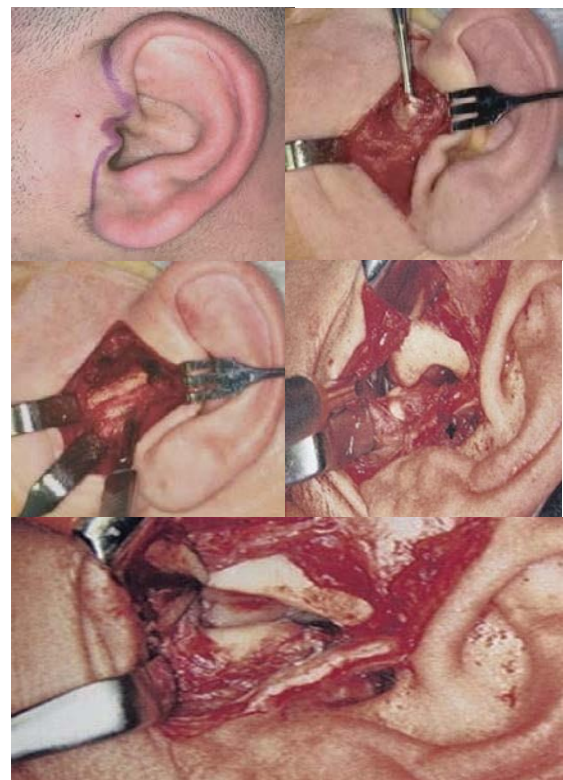


Fig.1: Procedures of Eminectomy

The facial nerve was bilaterally checked (especially the temporal and zygomatic branches) by asking the patients to frown and wrinkle forehead, to tightly close their eyes and to raise their eyebrows.

The pain was evaluated using a verbal numeric rating scale (VRNS) by asking the patient to evaluate their own pain on the VNRS from 0 to ten when 0 representing no pain and ten suggesting the worst ever pain has anyone ever seen. Participants can also show their score as 1/2 an integer (i.e., to 0.5).¹⁰

The maximal mouth opening was measured in all patients using a meter graduated ruler. Maximal inter incisal opening measured from the inter incisal contact point on the incisal edge of upper incisors to the corresponding point between the lower center (Figure 2).



Fig. 2: Pre and postoperative (RT) inter-incisal distance.

statistical analysis:

Data analysis was done by Statistical Package for Social Science (SPSS version 23) for windows. Numerical information had been summarized by mean ±SD. Categorical data percentage and paired t- test data have been utilized to compare pre and postoperative findings. Outcomes of the P valuation were less than 0.05 have been recognized to be significant.

RESULTS

We include in this trial 10 patients 3 (30%) of them were males 7 of them (70%) were females with an average age of 32.70 ± 8.69years

Most patients presented with mixed complaints from both pain and clicking or clicking with the restricted opening of the mouth. 4 of them (40%) have a combined symptom (Pain, clicking, and opening limitation), 3 (30%) had (Opening limitation and clicking), 2 (20%) had (Opening limitation) only and 1 (10%) had pain only. Table (1).

| Symptom | Preoperative | N | % |
|----------------------------------|--------------|---|-----|
| PAIN | | 5 | 50% |
| CLICKING | | 7 | 70% |
| OPENING LIMITATION | | 9 | 90% |
| DISABILITY OF MASTICATION | | 3 | 30% |

Table 1: Pre-operative symptoms

We found that the duration of symptoms among the study population is ranged from 7 to 38 months with a mean of 18.20 ± 10.08 months.

Only one case was presented by bilateral derangement and three cases at right with six cases atleft aspect.

The pain was presented in nearby half of the patients. The pain subjectively improved in four patients and stayed unaffected in one of the cases, but no one showed any pain worsening

In 7 (70 percent) cases, clicking was present preoperatively, and 3 (30 percent) cases had no clicking. After surgery, the clicking resolved in five patients, while the remaining two cases persisted to click after surgery

Improvements in the opening of the mouth are confirmed by calculating the inter-incisal length before and after surgery. The average preoperative IID was 22.9 millimeters, while the average postoperative IID was 35.6 millimeters Table (2) .

| Symptoms | Pre-operative | Post-operative | P-value |
|----------------------------------|---------------|----------------|---------------|
| PAIN | 5(50%) | 1(20%) | 0.05* |
| Clicking | 7(70%) | 2(28%) | 0.02* |
| Disability of mastication | 3(30%) | 0(0%) | 0.001* |
| IID | 22.9mm | 35.6mm | 0.000* |

Table 2: comparison of pre- and post-operative symptoms

As postoperative complications, we found one case (10%) of a wound infection that responded to an oral antibiotic and frequent dressing, one case (10%) of facial nerve weakness which improve with time, and two cases (20%) of auriculotemporal paresthesia one of them resolved spontaneously over time see table (3).

| Complication incidence | N | % |
|-------------------------------|---|-----|
| Facial nerve weakness | 1 | 10% |
| Auriculotemporal nerve | 2 | 20% |
| Wound infection | 1 | 10% |

Table 3: post-operative complications

DISCUSSION

Several people all over the world have temporomandibular joint (TMJ) disorders that are mostly identified by joint dysfunction and pain. TMJ's internal disorder includes 41.1 percent of patients with TMD, which is the greatest widespread condition of TMJ problems.¹¹

At first, treatment of internal disorder requires conservative medical management, like the use of splints which work to relieve pain, and do not affect the oral opening. Stiesch Scholz reported 40 patients, treated use two types of splint both of them produced effective management of the irreducible anterior disk dislocation.¹²

Total eminectomy that was described for the first time by Myraugh in 1951 showed satisfactory results by improving auto-reduction of persistently repeated

displacement. Surgeons used it to resect the eminence that helps removal of the restriction.¹³

Eminectomy is a technique recommended to manage and control the TMJ ID and correct the disc dislocation. The concept of eminectomy as if the eminence has been excised, the head could also circulate openly inside & outside the fossa of the joint without the hazard of displacement.¹⁴

In Stassen et al Study of 18 patients who underwent eminectomy was improved by an average of 17.9 millimeters in the incisal opening. Eminectomy value in the conversion of a non-reducing disk into a reducing disk, which helps to eliminate joint pain and facilitates TMJ Transportation. This technique isn't as destructive as condylectomy or condylar shaving.⁸

This study agrees with Stassen finding and showed statistically significant improvement in the opening of the mouth (IID) in which the p-value had been quantified for being <0,000, via an average IID of 35.6 millimeters post-operative at the outpatient clinic, 3 months after the operation.

Many studies come with this study findings.¹²⁻¹⁶ Rahman et al. in 2017 have published a case series that demonstrated the participant became pleased via the eminectomy procedure of the non-reducible articular disk displacement. Through comparison, sixty-four percent of patients with the non-reducible articular disk displacement had better oral opening up to twenty-five millimeters (variation from seven to twenty-five millimeters, average eight millimeters).¹²

Also, article published by Williamson et al. on 20 ID patients observed that the maximum oral opening had improved through a median of 12 millimeters by eminectomy.¹⁵

In this study surgery has enabled the free movement of the condyles through obstruction removal, eminectomy has long been included in the control and management of recurrent articular disc dislocation. Also, the same was reported by Stassen et al. and explained how the technique is easy and safe to use. Eminectomy removes the articular disk barrier and thus eliminates the compression from intra-capsular space, providing a wider ventral gap at the upper cavity.⁸

Description of eminectomy is also being re-engineered to be eminoplasty, because it includes the mechanical release by removing the bony restriction of eminence. It also enables better opening of the

mouth and eventual improvement of the manifestations.⁷

This is necessary to consider that the surgical eminectomy/eminoplasty technique requires providing medially adequate bony clearance and smoothing contouring including its articular fossa to allow easy joint translation. Also, it is significant to mention that, despite MRI findings, a few cases via the anterior dick displacement could also haven't any symptoms, but these could perhaps be identified via gradual, auto-resorption of the ventral aspect of the condylar head or the dorsal of articular eminence portion providing enough gap to transfer the stuck disk-natural eminoplasty.¹⁵

An absolute contraindication to eminectomy was reported with a high danger of intracranial transmission of infection as well as a high danger of breaking of the temporal bone if there was a pneumatization of the articular eminence.¹²

This study also found that 72 percent of the cases had full resolution of clicking and a decrease in personal pain symptoms proceeded to satisfactory discharge in 80 percent of cases.

The most common complaints after joint surgeries that involve the articular eminence are joint pain and noise. TMJ noise may be attributed to the roughness caused by surface remodeling, irregularities of the eminence, or the remaining part of the eminence.¹³

In this study, postoperative TMJ pain and noise had no significant statistical importance. It showed moderate TMJ pain after one week. The pain declined significantly with time, almost all the patients have no pain after six months.

There's only a few records of eminectomy done under local anesthesia and conscious sedation. Our case series study describe that TMJ ID was treated with eminectomy with local anesthesia and conscious sedation.

The muscle relaxants which used during general anesthesia causes posterior mal-positioning of the condyle compared to when the patient is awake, and the joint movements are not realistic, so the observations made during the evaluation of joint movement intraoperatively including the mouth opening, are inaccurate. also, The condyle may be sub-luxated or pulled out of the glenoid fossa to give the appearance of a natural mouth opening.⁸

Using of such local anesthesia with or without conscious sedation offers anxiolysis for the participant as well as facilitating verbal communication in between patient and the surgeon, allowing the patient to follow operator orders and functionally evaluate the mouth opening with a natural, non-paralyzed movements of the mandibular joint in its physiologic activity, which can be observed during the operations.¹⁸ Functional surgery is based on this idea.⁸

Eminectomy with local anesthesia technique was modified to deal with the medically compromised patients whom general anesthesia used to be considered as a contraindication and could be made serious problems from exposure to the general anesthesia.¹⁹

It also helps us to visualized the current position of the meniscus and its movements in a non-asleep

patient, helping us to correct the anteriorly displaced meniscus and preventing the posterior mal-positioning of the condyle that induced by general anesthesia.¹⁸

CONCLUSION

Anterior eminectomy, is a technique recommended for the management of ID. It enables the non-reducible disk to be a reducible disk, prevents pain inside of the TMJ, and promotes the flexible movement of TMJ. It's a safe, successful surgical technique that playing a role in the treatment as a 2nd-line surgical option in the treatment of ID of TMJ after other conservative medical options have fail.

REFERENCES

1. Bordoni B, Varacallo M. Anatomy, head and neck, temporomandibular joint. *StatPearls Publishing*. 2019.
2. Ivkovic, N., & Racic, M. Structural and Functional Disorders of the Temporomandibular Joint (Internal Disorders). In *Maxillofacial Surgery and Craniofacial Deformity - Practices and Updates. IntechOpen*. 2020
3. Tatli, U., & Machon, V. Internal derangements of the temporomandibular joint: diagnosis and management." *Temporomandibular joint pathology-current approaches and understanding. Intech Open*. 2017;436-76.
4. Maini, K., & Dua, A. . Temporomandibular Joint Syndrome . In *StatPearls Publishing [Internet]. StatPearls Publishing*. 2020
5. Abboud W, Yahalom, R., & Givol, N.. Treatment of Intermittent Locking of the Jaw in Wilkes Stage II Derangement by Arthroscopic Lysis and Lavage. *Journal of Oral and Maxillofacial Surgery*. 2015; 73(8), 1466–72. <https://doi.org/10.1016/j.joms.2015.02.027>
6. AL-Said, S. ., Shawky, N., & Ragab, H. . Comparative Study of Arthrocentesis With or Without Using Piroxicam in the Management of Temporomandibular Joint Disorders. *Alexandria Dental Journal*. 2015;40(2), 160–5. <https://doi.org/10.21608/adjalexu.2015.59142>
7. Shah, K., Brown, A. N., Clark, R., Israr, M., Starr, D., & Stassen, L. F. A. Is Eminectomy Effective in the Management of Chronic Closed Lock. *Journal of Maxillofacial and Oral Surgery*. 2020; 19(1), 67–73. <https://doi.org/10.1007/s12663-019-01216-x>
8. Stassen, L. F., & O'Halloran, M.. Functional surgery of the temporomandibular joint with conscious sedation for “closed lock” using eminectomy as a treatment: A case series. *Journal of Oral and Maxillofacial Surgery*. 2011 ; 69(6),e42–e9.
9. Moin, A., Shetty, A. D., Archana, T. S., & Kale, S. G. Facial nerve injury in temporomandibular joint approaches. *Annals of Maxillofacial Surgery*. 2018 ;8(1), 51–5.
10. Ismail, A. K., Abdul Ghafar, M. A., Shamsuddin, N. S. A., Roslan, N. A., Kaharuddin, H., & Nik Muhamad, N. A. The Assessment of Acute Pain in Pre-Hospital Care Using Verbal Numerical Rating and Visual Analogue Scales. *Journal of Emergency Medicine*. 2015; L49(3), 287–93.
11. Marqués-Mateo M, Puche-Torres M, Iglesias-Gimilio M-E. Temporomandibular chronic dislocation: the long-standing condition. *Medicina oral, patología oral y cirugía bucal*. 2016; 21(6). e776.
12. Rahman Z, Chand M, Breeze J, Stocker J. Success rates and complications of eminectomies: a retrospective case series. *Oral Surgery*. 2018; 11(1). 28-32.
13. El Gengehy MT, Ali S, Ashraf M. Eminectomy versus eminoplasty for treatment of recurrent temporomandibular dislocation: Randomized controlled clinical trial. *Egyptian Dental Journal*. 2019; 65(3-July (Oral Surgery)). 2095-102.
14. Chakraborty S. Eminectomy for the management of closed lock of temporomandibular joint. *Medical journal, Armed Forces India*. 2007; 63(4). 384.
15. Young AL. Internal derangements of the temporomandibular joint: A review of the anatomy, diagnosis, and management. *The Journal of the Indian Prosthodontic Society*. 2015; 15(1).
16. Williamson R, McNamara D, McAuliffe W. True eminectomy for internal derangement of the temporomandibular joint. *British Journal of Oral and Maxillofacial Surgery*. 2000; 38(5). 554-60.
17. Okeson JP. Management of temporomandibular disorders and occlusion-E-book. *Elsevier Health Sciences*. 2019
18. Iwanaga, Joe, et al. "Eminectomy for habitual luxation of the temporomandibular joint with sedation and local anesthesia: A Caseseries." *Case reports in dentistry* 2016
19. Segami, N. "A modified approach foreminectomy for temporomandibular joint dislocation under local anaesthesia: report on a series of 50 patients." *International journal of oral and maxillofacial surgery* 47.11 (2018): 1439-44.