

External Fixation Using External Fixation Plate In Proximal Tibial Fracture

Wael Ahmed Abd Alraheem^{1*} MSc; Kamal Abd El-rahman¹ MD ; Ahmed Ibrahim Akar¹ MD

*Corresponding Author:

Wael Ahmed Abd Alraheem

waelahmedabdelraheem@gmail.com

Received for publication February 6, 2021; Accepted March 2, 2021; Published online March 2, 2021.

Copyright 2020 The Authors published by Al-Azhar University, Faculty of Medicine, Cairo, Egypt. All rights reserved. This an open-access article distributed under the legal terms, where it is permissible to download and share the work provided it is properly cited. The work cannot be changed in anyway or used commercially.

doi: 10.21608/aimj.2021.60672.1411

¹Orthopedic Surgery Department, Faculty of Medicine, Al-Azhar University, Cairo , Egypt.

ABSTRACT

Background: Proximal tibial fractures with compromised soft tissue envelop may lead to significant complications .The optimal management of these injuries remains controversial .

Aim of work: to evaluate the results of external fixation using the external fixation plate in proximal fractures of the tibia. .

Patient and Methods: : We prospectively evaluated 50 patients(35 males and 15 females) with age (range, 20-50 years) who presented with proximal tibial fractures .According to the (AO/OTA) classification, type41-A2 in 35 cases and type 41-A3 in 15 cases .

The state of the soft tissue were classified according to Tscherne classification : (O 1 in 10 cases , O 2 in 20 cases . C 0 in 5 cases and C 1 in 15 cases.)

The external fixation plate was used to fix these fractures.Which was placed on the tibia as an external fixator. The mean follow up was 9.2 months .

Results: All fractures healed in a mean time of 27.9 weeks. There were no cases of deep infection, nonunion and loosening or failure of the plates and screws. According to the modified Ramussen Criteria knee scoring system the mean score was 26.2 and (AOFAS) ankle scoring system , the mean score was 96.2.

Conclusion: For proximal fractures of the tibia, external fixation using the external fixation plate is a safe and reliable technique with minimal complications and excellent outcomes.Its advantages include ease of performing surgery and ease of removing plate after fracture healing. **Keywords:** Locked plate,external fixator, tibia.

Keywords: external; fixation; plate,proximal; tipia.

Disclosure: The authors have no financial interest to declare in relation to the content of this article. The Article Processing Charge was paid for by the authors.

Authorship: All authors have a substantial contribution to the article.

INTRODUCTION

Proximal tibial fractures with compromised soft tissue envelop pose a treatment challenge for the orthopedic surgeon.

Open reduction & internal fixation of these fracture requires extensive soft tissue disruption which may be associated with complications such as skin necrosis and nonunion .¹

Minimally invasive percutaneous plate osteosynthesis (MIPO) minimizes the soft tissue trauma to the injured zone, however ,the plate may be prominent under the skin .

In the tibial metaphyseal fracture with an hourglass shape of the intramedullary canal, Intramedullary nailing is a technically challenging procedure , which has a specific risk of malalignment and anterior knee pain.²

There has been renewed interest in using external fixation in modern trauma management either alone or with limited internal fixation as a temporary fixator or definitive treatment for lower extremity fractures with compromised soft tissue envelop.^{3,4}

The use of LCP as an external fixation has advantages of angular stability from the locking-head mechanism and less irritation when compared with traditional external fixatores due to their low profiles.

The benefits of using the locking plate as a final external fixation include minimal soft tissue dissection with preservation of the vascular integrity of the fracture ,immediate osseous stabilization without crossing the knee, low-profile rigid fixation, access to the wounds, better patient comfort, ease of subsequent definitive fixation, early range of motion of the joint ,shorter hospitalization time , high rate of union and good clinical results.^{5,6,7,8,9}

In contrast to the tibial locking plate, the external fixation plate is thicker and the diameter of screws in the external fixation plate is larger than that of the tibial plate, which can increase the stability of fixation. The purpose of this study was to evaluate the results of external fixation using the external fixation plate in proximal fractures of the tibia with compromised soft tissue injury.¹⁰

PATIENTS AND METHODS

The study was approved by the Department of Orthopaedic Surgery of EL Hussein University hospital. Informed consent was given by the patients. Inclusion criteria were isolated proximal tibial fractures, fractures with compromised soft tissue injury, open fractures Gastilo type 1 and 2. Exclusion criteria were Pathological fractures, Gastilo type IIIB, type IIIC open fractures, tibial fractures accompanied by a soft tissue on the anteromedial aspect of the tibia, multiple fractures with spinal injury, and lower limbs with a pre-existing neurological deficit or vascular disease.

During the period between December 2015 and December 2018, 50 patients sustained 50 tibial fractures were admitted to EL Hussein University hospital or Sahil training hospital. There were 15 females and 35 males, with the mean age of the patients was 34.9. Thirty five patients sustained a fracture due to motor car accident, five patients sustained a fracture due to work related accident & direct trauma, five patients sustained a fracture due to home related accident, five patients sustained a fracture due to gunshot. (Table.1)

The fractures were classified according to the (AO/OTA) guidelines: type 41-A2 in 35 cases and type 41-A3 in 15 cases. The state of the soft tissue were classified according to Tscherne classification: type O 1 in 10 cases, type O 2 in 20 cases, type C 0 in 5 cases and type C 1 in 15 cases.

The time between injury (admission) and definitive surgery was 5.2 days. For open fractures, external plating was performed after debridement during the emergency operation.

Variable	Value
Mode of trauma	
RTA	35 (70.0%)
Gunshot	5 (10.0%)
Direct trauma	5 (10.0%)
Home falls	5 (10.0%)
Tscherne soft tissue classification	
C0	5 (10.0%)
C1	15 (30.0%)
O1	10 (20.0%)
O2	20 (40.0%)
AO soft tissue classification	
IC1	5 (10.0%)
IC2	15 (30.0%)
IO1	10 (20.0%)
IO2	20 (40.0%)
OTA classification	
41.A2	40 (80.0%)
41.A3	10 (20.0%)
Associated femoral fracture	
No associated femoral fracture	40 (80.0%)
Associated femoral fracture	10 (20.0%)

Table 1: Characteristics of the fracture

The patient was placed supine on a radiolucent operating table. Under anesthesia, the affected lower limb was prepared and draped. No tourniquet was used. The external fixation plate was used. The broad end of the plate was placed close to the knee joint since it can allow insertion of more screws for stabilization of the short proximal segment. For closed displaced oblique and spiral fractures, a small incision (2 to 4 cm) was made to expose and clean the fracture gap. (Fig.1)

The fracture was anatomically reduced. A clamp or two K-wires were used to temporarily fix and maintain the anatomic reduction. Definitive external fixation was achieved with external fixation plate (12 or 19 holes). The plate was placed on the anteromedial aspect of the tibia as close to skin as possible (the plate-bone distance should be less than 30mm). folded towel (or use stopper screw) was placed under the plate to keep the plate away from the skin. Successive holes were drilled through stab incisions where the overlying soft tissue envelope was

intact. Locking screws of the corresponding length were inserted. All screws were bicortical. At each end of the fracture, four to five bicortical locking screws were inserted. The position and orientation of the screws were checked with fluoroscopy.

Screw tracks were cleaned twice a day with alcohol, sterile saline. Early ROM of the knee and ankle is started from the second to the fifth postoperative day.

Depending on the stability of the reconstruction, toe-touch or partially weight bear was encouraged for the patients 4-6 weeks after surgery. Patients were instructed to visit the clinic for examination every 4 weeks.

At each follow-up, Xrays of the tibia were taken and the patients were evaluated using a Modified Ramussen Criteria knee scoring system. (Table 2)¹¹

Fracture healing was defined as the presence of cortical bridging on biplanar radiographs. Complications were defined by fixation failure, infection, and nonunion.

Once fracture was healed, the patient were allowed to walk with full weight-bearing for one month before removing the plate. The time to fracture healing and post operative complications were observed and documented.

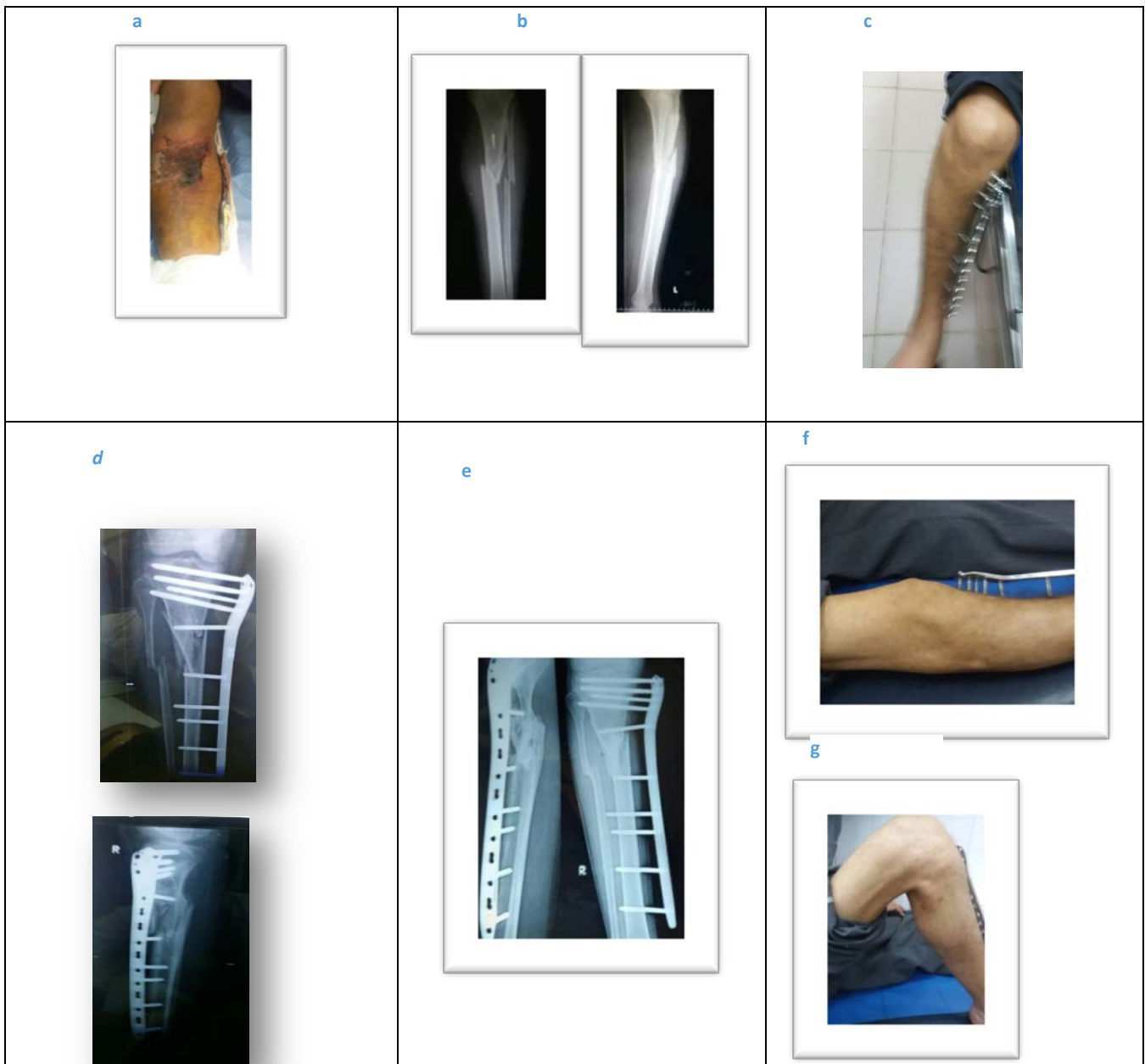

Fig.1 a- A 30 years male sustained Gustilo type I of right leg. b-Xray films(AP-Lateral) showed RT proximal tibial fracture(AO/OTA)(41 A3) c- The fracture was stabilized with femoral LISS plate..d) AP &Lateral xray after surgery.e) Follow up xray at 6 months showing fracture healing .f,g) Joint with full range of motion just before removal of plate

Pain	Non Occasional	6
	Stab& certain position	5
	Constant after activity	3
	Significant rest pain	1
		-3
Walking capacity	Normal	6
	Outdoor > 1hour	5
	Outdoor 15min-1hour	3
	Outdoor < 15min	1
	Indoor	0
	Wheelchair-bedridden	-3
Knee extension	Normal	4
	Lack < 10degree	2
	Lack > 10degree	0
	Lack > 20 degree	-2
ROM	Full	6
	120 degree	5
	90 degree	3
	60 degree	1
	< 60 degree	-3
Stability	Normal in ext. & 20 flex.	6
	Abnormal in 20 flex.	4
	Instability in ext. < 10	2
	Instability in ext. > 10	0
Power of quadriceps	G.5	2
	G.3-5	1
	G. less than 3	-2

Excellent : 28-30 - Good : 24-27 - Fair : 20-23 - Poor : < 20

Table 2: Modified Rasmussen Criteria(MRS) (Neil Rohra,2016) 11

RESULTS

The mean age of the patients was 34,9 years .Ten cases with associated fractures (ipsilateral fracture femurs) were fixed using I.M.locking nail. (table3)

Variable	Value
Operative time (min)	50.8 ± 8.7 (30.0 - 65.0)
Follow up time (months)	9.2 ± 1.9 (7.0 - 12.0)
Time to healing (weeks)	27.9 ± 7.6 (20.0 - 40.0)

Data are mean ± SD (range).

Table 3: Operative time, follow-up time and time to healing

The mean time between injury (admission) and definitive surgery was 5.2 days. The mean duration of surgery for closed fractures was 44 minutes and for open fractures it was 52 minutes. The mean follow-up was 9.2 months. All fractures healed without any complications. (fig.2)

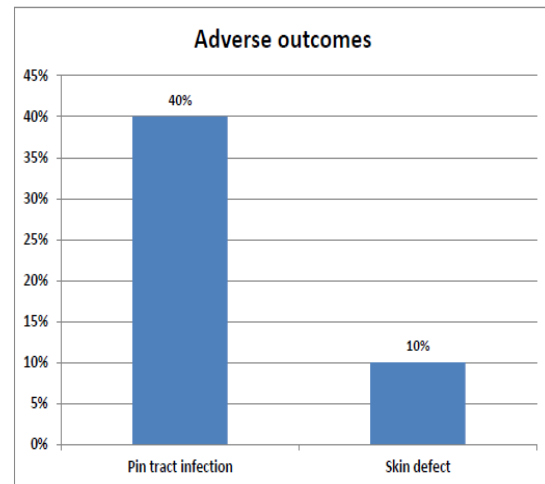


Fig.2: incidence of adverse outcomes

The mean time to fracture healing was 27.9 weeks. Most of the fractures healed in an acceptable position . There were no cases of deep infection . Pin tract infection was seen in 20 patients, and the infection was resolved by removing the plate and screws , a thorough debridement and oral antibiotic therapy.

Five (10 %) patients with open fractures (Gastillo II –Tschrine O2-AO/ASIF IO3 M1 NV1) had skin defects few days after surgery and had been operated by skin grafts and removing of one or two screws with complete healing in follow up.No loosening or failure of the external fixator plates and screws After walking with full weight -bearing for one month, some patients (n=20)underwent smooth plate removal in the clinic within 5 minutes .

At the most recent follow up , and according to the Modified Ramussen Criteria (MRC)knee scoring system ,the mean score was 26.2 and (AOFAS)ankle scoring system ,the mean score was 96.2 . All patients were satisfied with the outcome, and were fully weight bearing with a well-healed tibia at the final follow-up.(fig.3,4)

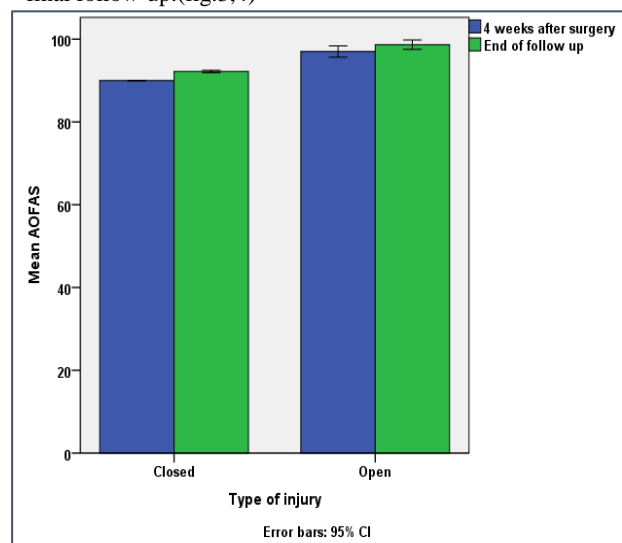


Fig.3: Mean MRC 4 weeks after surgery and at end of follow up in patients with open or closed injury. Error bars represent 95% confidence interval (95% CI)

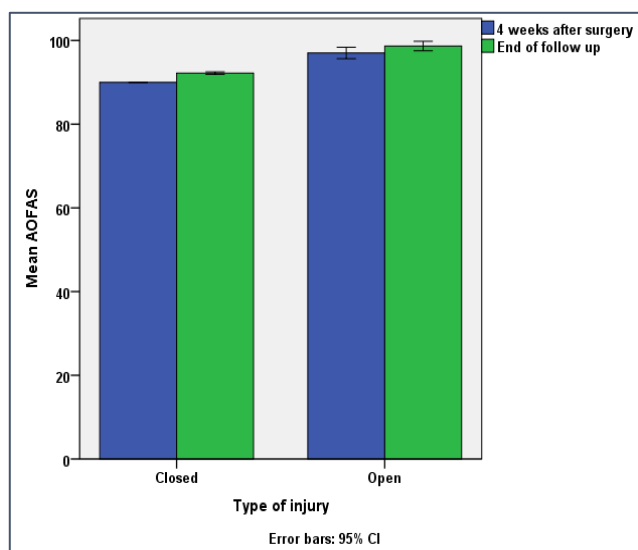


Fig.4: Mean AOFAS 4 weeks after surgery and at end of follow up in patients with open or closed

DISCUSSION

Proximal tibial fractures are challenging to treat because of the frequency of substantial soft-tissue injury, subcutaneous surface, the strong deforming forces involved, and the need for accurate alignment. Reduction and stability are dependent on control of the proximal fragment.

Soft tissue compromise can present as a component of the injury, or can result from surgical dissection.

None of the treatment options available perfectly fulfill requirements of fracture characteristics of proximal tibia. The conventional surgical treatment for tibial fractures includes nailing and plating.

It is not easy to achieve rigid stability using nailing in a metaphyseal fracture. Although some techniques have been reported to augment the fixation with nailing, such as blocking screw, the placement of a blocking screw is not always easy and would increase the time of surgery. The incidence of malunion (5-58%) and implant failure (5-39%). Another common complication of nailing is anterior knee pain.^{12,13}

The clinical series with the use of an internal locking plate demonstrated favorable results, however, complications such as non union, delayed union and infection are reported with the range of 8.3-35%, 8.3-25% and 10-55% respectively.¹⁴

MIPO may offer more biological advantages, but still has high rate of infection (7-10%) and nonunion (4%).¹⁵

With the development of technique of external fixation using a plate which preserve extraosseous blood supply, respect osteogenic fracture haematoma, biologically and stable fixation method is available for proximal tibia fracture. Indirect reduction method and fixation of the plate screws with small skin incisions in external fixation using plate technique prevents iatrogenic injury to vascular supply of the bone, which finally leads to decreased infection rate better fracture healing. A mechanically stable fracture - bridging osteosynthesis can be obtained

without significant dissection and surgical trauma to the bone and surrounding soft tissues.

Recently, with the advance of locking plates with fewer moving parts, this technique was used in the management of open fractures, septic arthritis and in infected nonunion and was called the supercutaneous plating technique.¹⁶

In the present study included 50 patients, the external fixation plate was used as an external fixator to fix both closed and open Gustilo type I,II proximal tibial fractures. We evaluated the bone union rate, deformity, leg-length discrepancy, ROM of the ankle and infection or other complications rate after external plate fixation.

Xu-sheng Qiu¹⁷ treated 12 proximal tibial fractures using locking plate as a definitive external fixator. Jingwei Zhang¹⁸ treated 35 proximal tibial fractures using femoral LISS plate as a definitive external fixator.

The plate was placed on the anteromedial aspect of the tibia, with its broad end close to the knee joint. The broad end of the external fixation plate offers greater versatility for inserting the screws as it has 7 holes that allow more precise modulation to obtain the greatest bone purchase in the proximal segment.

The anteromedial aspect of the tibia is not covered by bulky muscles and important neurovascular structures, and hence, the surface can be clearly palpated, thus, facilitating fast and accurate insertion of screws with less risk of neurovascular injuries.

The plate-bone distance was 20-30 mm, which can increase the stability of fixation. According to the report by Stoffel¹⁹, on the biomechanics of the locking plate, the axial stiffness and torsional rigidity were mainly influenced by the working length. The number of screws also significantly affected the stability. In the present study, an external fixation plate with 12-19 holes was used. All screws were bicortical. All these features can increase both the axial and torsional stability.²⁰ The external fixation plate was placed on the anteromedial aspect of the tibia and this ensured the motility of muscles and good ROM. Because of its low profile, the external fixation plate can be easily concealed under the stockings. The patients could walk wearing normal trousers and there was much less tendency for the locking plate to strike the contralateral lower leg during ambulation.²¹

In the current study, the mean time between injury and operation was 5.2 days. The mean duration of surgery for closed fractures was 44 minutes and 52 minutes for open fractures. The mean period of follow up was 9.2 months. (50%) of the cases showed radiological union in 20-24 weeks, (20%) in 32-38 weeks and (30%) in 38-40 weeks, the mean time of union was 27.9 weeks (20-40 weeks).

Xu-sheng Qiu¹⁷ reported the mean time between injury and operation was 10 days. the mean bone healing time was 37.8 weeks. Jingwei Zhang¹⁸ reported the mean time between injury and operation was 3 days. The mean duration of surgery for closed fractures was 32 minutes. The mean bone healing time was 14 weeks.

In the current study , depending on the stability of the reconstruction , toe-touch or partially weight bear was encouraged for the patients 4-6 weeks after surgery. Non of the patients complained of pain caused by the screws. The mean MRC score was 26.2, and the mean AOFAS score was 96.2 at final follow up.The functional recovery of the adjacent joint was satisfactory . Xu-sheng Qiu et al, reported that all patients had excellent or good functional results. No clinically relevant malrotation or limb-length discrepancies were observed. Jingwei Zhang et al reported the mean HSS score was 98 and the mean AOFAS score 94 at final follow-up.

In the present study ,the locking plate used as external fixator was a joint-sparing frame, physical therapy could begin early postoperatively (on the 2nd- to 5th postoperative day). Therefore ,all patients had excellent or good functional results. Furthermore, most of the fractures healed in acceptable position. No clinically relevant malrotation or limb-length discrepancies were observed . On the other hand , Papadokostakis ²²reported that patients treated with spanning frames had significantly greater incidence of malunion compared with patients treated with sparing frame.

After fracture healing, the external plate was removed easily In our study, some patients (n=20)underwent smooth plate removal in the clinic within 5 minutes . In contrast, the operation for removal of nail and internal locking plate could be troublesome in some cases.

In the current study, all of the 30 open fractures underwent external fixation using the external fixation plate during the emergency operation. There were 20 cases of pin-site infections in one or two sites which were under control. Five (10 %) patients with open fractures had skin defects few days after operation and had been operated by skin grafts and removing of one or two screws with complete healing in follow up.There was no case of deep infection, nonunion, and loosening or breakage of plates and screws.

Xu-sheng Qiu, reported one case (8.3%) of pin tract infection and resolved after removing the plate and screws and a thorough debridement. Jingwei Zhang ,reported two cases (5.7%) of pin tract infection,also resolved after removing the plate and screws and a thorough debridement .There was no case of deep infection, malaligned union, nonunion, and loosening or breakage of plates and screws.

CONCLUSION

Our study has several limitations: First, the lack of a control group does not allow the formulation of definitive statements and guidelines. Second, the cost of external fixation plate tends to be higher than a standard external fixator and the use of the LCPplate, which was originally designed for internal fixation of the tibia, as an external fixator to fix a tibial fracture is also controversial.

REFERENCES

1. Tejwani NC, Finkemeier CG, Woliinsky PR. High energy proximal tibial fractures.*Instr Course Lect.*2006; 55:367-79.
2. Nork SE, Schwartz AK , Agel J . Intramedullary nailing of the distal tibial fractures . *J B J Surg. Am.* 2005;87:1213-21
3. Watson JT, Moed BP, Karges DE. Pilon fractures.Treatment protocol based on severity of soft tissue injury.*Clin Orthop Relat .Res.*2000 :375; 78-90.
4. Qiu XS, Yuan H, Zheng X. Locking plate as a definitive external fixation for treatment tibial fractures with compromise soft tissue envelope. *Arch. Orthop. Trauma Surg.* 2014 : 134;383-8.
5. Ma CH, Wu CH, Yu SW, Yen CY. Staged external and internal less invasive stabilization system plating for open proximal tibial fractures. *Injury.* 2010;41(2): 190-6.
6. Ma CH, Wu CH, Tu YK. Lin TS. Metaphyseal locking plate as a definitive external fixator for treatment open tibial fractures-clinical outcome and a finite element study.*Injury.*2013; 44(8)1097-101 .
- 7.Tulner SA, Strackee SD, Kloen. P. Metaphyseal locking compression plate as external fixator for the distal tibia.*Int Orthop:*2012; 36 (9) : 1923 -7.
8. Kloen P . Supercutaneous plating :use of locking compression plate as an external fixator . *J Orthop Trauma:*2009; 23(1):72-5.
9. Ma CH, Tu YK, Yen JH, Yang SC. Using external and internal locking plates in a two-stage protocol for treatment of segmental tibial fractures.*J Trauma:* 2011;71(3):614-9.
- 10.Jingwei Zhang, Nabil Ebraheim , Ming LI, Yihui Yu. External Fixation using femoral LISS plate in proximal Tibial Fractures. *Clinics in Orthop Surg* :2015;78-84
- 11.Neil Rohra, Harprect Singh Suri, Kewal Gangrade.Functional and Radiological Outcome of Schatzker type V and VI Tibial Plateau Fracture Treatment with Dual Plates: A Prospective Study.*J Clin Diagn Res.* 2016;v 10(5):RC5-10.
- 12.Ricci WM, Borrelli J, Bellabarba C, Sanders R. Fractures of the proximal third of the tibial shaft treated with;15 (4):264-70 intramedullary nails and blocking screws.*J Orthop Trauma* :2001.
- 13.RC Meena, UM Kumar, CL Gupta, S Gaba. IM nailing versus proximal plating in management of closed extra-articular proximal tibial fractures:a randomized control trial.*Journal of Orthop. & Traumatology:*2015;16;203-8.
- 14.Vaisto O,Toivanen J, Kannus P, Jarvinen M. Anterior knee pain and thigh muscle strength after intramedullary nailing of tibial shaft fractures :. *J OrthopTrauma* :2004;8(1):18-23.
- 15.Namazi H, Mozaffarian K. Awful considerations with LCP instrumentation :a new pitfall *Arch Orthop Trauma Surg.*:2007;127(7)573-5.
- 16.Kloen P. Supercutaneous plating: use of a locking compression as an external fixator. *J Orthop Trauma* :2009;23(1)72-5.

17. Xu-sheng Qiu ,H Yuan, X Zheng, J F Wang,J Xiong. Locking plate as a definitive external fixator for treating tibial fractures with compromised soft tissue envelop.*Arch Orthop Trauma Surg*:2014;134:383-8.
- 18.Jingwei Zhang , N Ebraheim, J Liu, L Zhu, Y Yu. External Fixation Using Femoral Less Invasive Stabilization System in tibial proximal metaphyseal fracture. *Clinics in Orthop. Surg* :2015 ;7:8-14.
- 19.Stoffel K, Dieter U, Stachowiak G, Gachter A. Biomechanical testing of the LCP :how can stability in locked internal fixators be controlled?. *Injury*:2003;34 suppl 2:b 11-9.
- 20.Dougherty PJ, Kim DG, Meisterling S,Yeni Y. Biomechanical comparison of bicortical versus unicortical screw placement of proximal tibia locking plates ; a cadaveric model. *J Orthop Trauma* :2008;22(6):399-403.
- 21.Tulner SA, Strackec SD,Kloen P. Metaphyseal locking compression plate as an external fixator for the distal tibia. *Int Orthop* :2012 ;36 (9):1923-7.
- 22.Papadokostakis G, Kontakis G,Giannoudis P, Hadjipavlou A. External fixation devices in the treatment of fractures of the tibial plafond: a systematic review of the literature. *J Bone Joint Surgery Br.*:2008;90(1):1-6.