

Therapeutic Effect of *Sepia pharaonis* Ink Extract and Ellagic Acid on the Toxicity Induced by Cyclophosphamide in Male Albino Rats

Naglaa R. A. Kasem^{1,2}, Dalia S. Hamza^{1,3}, Mona S. Azab^{1,3}, Sherifa H. Ahmed^{1,4}

¹Biology Department, College of Science, Jouf University, Sakaka 2014, Saudi Arabia.

²Zoology Department, Faculty of Science, South Valley University, Qena 83523, Egypt.

³Department of Zoology, Faculty of Science, Benha University, Benha 13518, Egypt.

⁴Department of Biotechnology, Faculty of Science, Port Said University, Port Said 42521, Egypt.

*Corresponding Author: nrhares@ju.edu.sa & naglaa.hares@sci.svu.edu.eg

ARTICLE INFO

Article History:

Received: Feb. 19, 2021

Accepted: March 21, 2021

Online: March 23, 2021

Keywords:

Cyclophosphamide,
Sepia pharaonis,
Sepia ink extract,
Ellagic acid,
hematological analysis,
liver, kidney.

ABSTRACT

Combination between anticancer drugs and natural products has a great attention aiming at exploiting their efficiency and reducing systemic toxicity. Subsequently, the current study was constructed to evaluate the potential curative role of crude *Sepia* ink extract (SIE) and Ellagic acid (EA) against cyclophosphamide (CP) toxicity. Male albino rats were divided into five groups ($n = 10$). All groups except group I received CP. Group I served as control group, group II received a single dose of CP (200 mg/kg, i.p.) and served as CP group, rats of group III received CP + SIE (200 mg/kg body weight), group IV received CP + EA (60 mg/kg) and group V received CP + SIE (200 mg/kg body weight) + EA (60 mg/kg). Data showed that, CP administration significantly decreased RBCs, WBCs, PLTs count, PCV% and Hb content. Post administration of SIE and EA caused a significant elevation in the hematological values. Also, SIE and EA treated groups reduced the hepatic and renal toxicity induced by CP treatment, where liver and kidney functions (AST, ALT, ALP, creatinine, urea and uric acid) significantly decrease. On the other hand, serum albumin and T. protein levels increased compared to CP treated groups. The current results revealed that CP induced hematological alterations and various tissues injury. Natural products as SIE and EA eliminated the CP toxicity.

INTRODUCTION

Cyclophosphamide (CP), an alkylating agent, is chemotherapy for cancer that suppress the immune system (Ahlmann and Hempel, 2016). This drug was used for the treatment of chronic and acute leukemia, multiple myeloma, lymphoma, and rheumatic arthritis (Nelius *et al.*, 2010). Hepatic cytochrome P450 (CYP) isoenzyme activity can be affected by CP in animals through the induction of gene expression of this enzyme (Xie *et al.*, 2002). Low counts of white blood cells, appetite loss, hair loss, vomiting, and bladder bleeding are the common side effects of CP. Furthermore, allergic reactions, pulmonary fibrosis and infertility are severe side effects of the drug (Wang *et al.*, 2009).

The negative roles of CP on male reproductive functions have been widely recognized resulting in reduced dosage of anti-tumor drugs (**Elangovan *et al.*, 2006**). CP therapy causes toxicity through excessive production of reactive oxygen species (ROS) leading to increased oxidative stress (**Alenzi *et al.*, 2010**). The cytoprotectors will be used as adjuvant drugs for chemotherapy to weakness the toxic damage on normal tissues, (**Le *et al.*, 2015**).

The integrating anticancer drugs with natural products have a great interest to maximize their effectiveness and reduce systemic toxicity through the introduction of lower drug dosages (**Hanan *et al.*, 2015**). Freshwater and marine Products become important source material for the development of drugs and specific health foods (**Fahmy and Soliman, 2013**). Cuttlefish *Sepia* ink (a black suspension sprayed by *Sepia* to deter predators) has been established beneficial and a kind of multi-functional bioactive marine material as an antioxidant (**Vate *et al.*, 2015**), anti-inflammatory, anti-ulcer (**Fangping *et al.*, 2018**), anti-retroviral (**Israa *et al.*, 2019**), antimicrobial (**Zakaria *et al.*, 2019**), anti-radiation reagent (**Lei *et al.*, 2007**), and to have anticancer properties (**Kumar *et al.*, 2018**), besides hematopoietic (**Lei *et al.*, 2007**), immunoregulatory (**Liu *et al.*, 2011**), and chemoprophylactic activities (**Wang *et al.* 2010**). Proteins, amino acids, melanin, lipids, metals, tetrodotoxin and peptidoglycans are included in *Sepia* ink (**Derby, 2014**).

The carbohydrate fraction of peptidoglycan (polysaccharide; SIP and oligopeptide; SIO) extracted from *Sepia* ink (SIE) has demonstrated antitumor activity (**Jismi *et al.*, 2018**). Hence, it can induce cyclophosphamide-induced chemotherapy in model animals (**Wang *et al.*, 2010**). SIE is proven to be an alternative medicine because of containing a variety of melanin-generating enzymes including tyrosinase, an enzyme that rearranges dopachrome (**Soliman, 2011**). Also, it helps to prevent cancer by boosting the action of killer cells and improves WBC production during chemotherapy (**Zong *et al.*, 2013**).

Ellagic acid (EA) is a natural phenol that is found in various vegetables and fruits such as raspberries, cloudberries and strawberries (**Muthukumaran *et al.*, 2017**). It has major health benefits against hepatotoxicity due to its antioxidant, antiproliferative activities and pharmacological properties which increase the activity of the antioxidant defense system (**Sarker and Oba, 2019**). EA has shown a protective effect on testicular, pulmonary and nephrotoxicity induced by CP (**Rehman *et al.*, 2012 and Saba *et al.*, 2013**). Therefore, the present study aimed to investigate the complications of the damage induced by CP and the potential therapeutic role of SIE and EA against hepatic and renal disturbances induced by CP in male rats.

MATERIALS AND METHODS

Chemicals and reagents

Cyclophosphamide and Ellagic acid were purchased from Sigma–Aldrich (St. Louis, MO, USA). Kits for all biochemical parameters were purchased from Bio-diagnostic Company (Giza, Egypt).

Collection of cuttlefish

The specimens of cuttlefish (*Sepia pharaonis*, Ehrenberg, 1831) were collected from Hurghada (Red Sea). The specimens were preserved in ice box and were brought to the laboratory through few hours of capture.

Preparation of *Sepia* ink extract

The collected specimens were washed by distilled water then dissected to get the ink sac. The collected ink was diluted with an equal volume of distilled water and mixed sufficiently. The admixture was concentrated and lyophilized to a black residue using a lyophilizer (LABCONCO, shell freeze system, USA).

Animals

Male Wistar albino rats weighing between 180-250 g were obtained from the animal house of the Egyptian Organization for Biological Products and Vaccines (VACSERA), Helwan, Cairo, Egypt. All animals were housed under standard conditions at ($26 \pm 3^{\circ}\text{C}$) with 12:12 h day and night cycle. The investigation conforms to the guide for the care and use of laboratory animals according to the ethical guidelines of the institutional Animal Ethical Committee of the Faculty of Science, South Valley University, Egypt.

Experimental Design

Male albino rats were divided into five groups, ($n=10/\text{group}$). The first control group rats were intraperitoneal (ip) injected with 0.9% isotonic solution at a dose of 2 ml/kg body weight. Second group were ip injected with a single dose of cyclophosphamide (CP) (200 mg/kg b.w.). The rats in third group were ip injected with a single dose of CP (200 mg/kg b.w.) following treated orally with SIE (200 mg/kg b.w.) daily for 30 days. Fourth group were ip injected with a single dose of CP (200 mg/kg b.w.) then orally administrated with EA at dose of (60 mg/kg) daily for 30 days. Finally rats in the fifth group were ip injected with a single dose of CP (200 mg/kg b.w.) then treated with both SIE (200 mg/kg b.w.) and EA (60 mg/kg) daily for 30 days.

At the end of the experiment, blood samples were collected then divided into two portions. The first portion was taken in EDTA containing tubes for hematological analysis which done by Automated Hematology Analyzer (Diagon LTd - D cell 60). The other one was left without anticoagulant at room temperature then serum was separated by centrifugation for 20 minutes at 3000 rpm and stored at -20°C until used for biochemical analysis.

Biochemical Analysis

Activity of hepatic biomarkers aspartate aminotransferase (AST), alanine aminotransferase (ALT) (IFCC, 1986) and alkaline phosphatase activity (ALP) (Moss, 1982), serum total protein (Gornal *et al.*, 1949), serum albumin levels (Dumas *et al.*, 1971) and renal biomarkers creatinine, urea (Fawcett and Scott, 1960) and uric acid (Fossati *et al.*, 1980) were determined using Bio-diagnostic assay kits according to the manufacturer's instructions (Giza, Egypt).

Statistical analysis

The variability degree of results was expressed as means \pm standard deviation of means (Mean \pm SD). The data were statistically analyzed by ANOVA, unpaired t-test (prism program) and the least significant difference was used to test the difference between treatments. Results were considered statistically significant when $P \leq (0.05)$.

RESULTS

1. Hematological results

Intake of CP (200 mg/kg, i.p.) induced severe alteration of hematological biomarkers. Figure (1) indicated that CP significantly reduced the RBCs count which is accompanied by a Hb content and PCV% decline compared to the control group. In the meantime, WBCs and platelets count were significantly decreased with the percentage of change 53.7% and 36.5% respectively. Post-treatment with (200 mg/kg) SIE alleviated the toxicity induced by CP by increasing the values of the RBCs count, Hb content and PCV% with the percentage of change 31.8%, 32.6% and 41.5% respectively. Also, the treatment with (200 mg/kg, i.p.) SIE resulted in a significant increase the WBCs and platelets count ($P \leq 0.01$ & $P \leq 0.05$) respectively as compared to CP treated group but it was not reach to normal animals. Furthermore, post-treatment with (60 mg/kg) EA for 30 days reduced the toxicity of CP treatment since it significantly increased the RBCs count, Hb content and PCV% ($P \leq 0.01$). Values of WBCs were elevated ($P \leq 0.01$) and non-significantly alteration of platelets count was noticed as compared to the CP treated group but still unremarkable change comparing with normal animals. Combined- therapy with SIE extract and EA normalize blood alteration induced by CP treatment and significantly restore all the hematological biomarkers ($P \leq 0.01$) almost near to normal values when compared with normal animals.

2. Liver function biomarkers

CP (200 mg/kg, i.p.) caused hepatic deterioration which could be represented by elevation of liver function biomarkers. The activity of ALT and AST, ALP significantly increased after CP treatment with the percentage of change 77%, 49.5% and 51.5% respectively. While, it significantly decreased both of albumin and total protein ($P \leq 0.01$) as compared to control group. Fig. (2a, b, c, d, e) clarifying the hepatoprotective activity of SIE against the CP induced hepatotoxicity. As observed, ALT, AST, and ALP activity were reduced with the 38%, 24% and 29.5% compared to the CP treated group and these result still higher than normal animals. On the other hand, SIE significantly increased albumin and total protein content ($P \leq 0.01$, $P \leq 0.05$) compared to CP treated group but this increase still not reachable to normal animals, but this increase still not reachable to normal animals. Similarly, (60 mg/kg) EA post-treatment improved the hepatic status by declining the liver function enzymes ($P \leq 0.01$) and significantly rising albumin level with non-considerable change in total protein level compared to CP treated group as well as, this increase in Albumin and total protein levels were nearly reachable to normal levels.

Combined- therapy with SIE and EA ameliorate the hepatic injury induced by CP treatment and significantly restore all the hepatic biomarkers ($P \leq 0.01$) as revealed in Fig. 2.

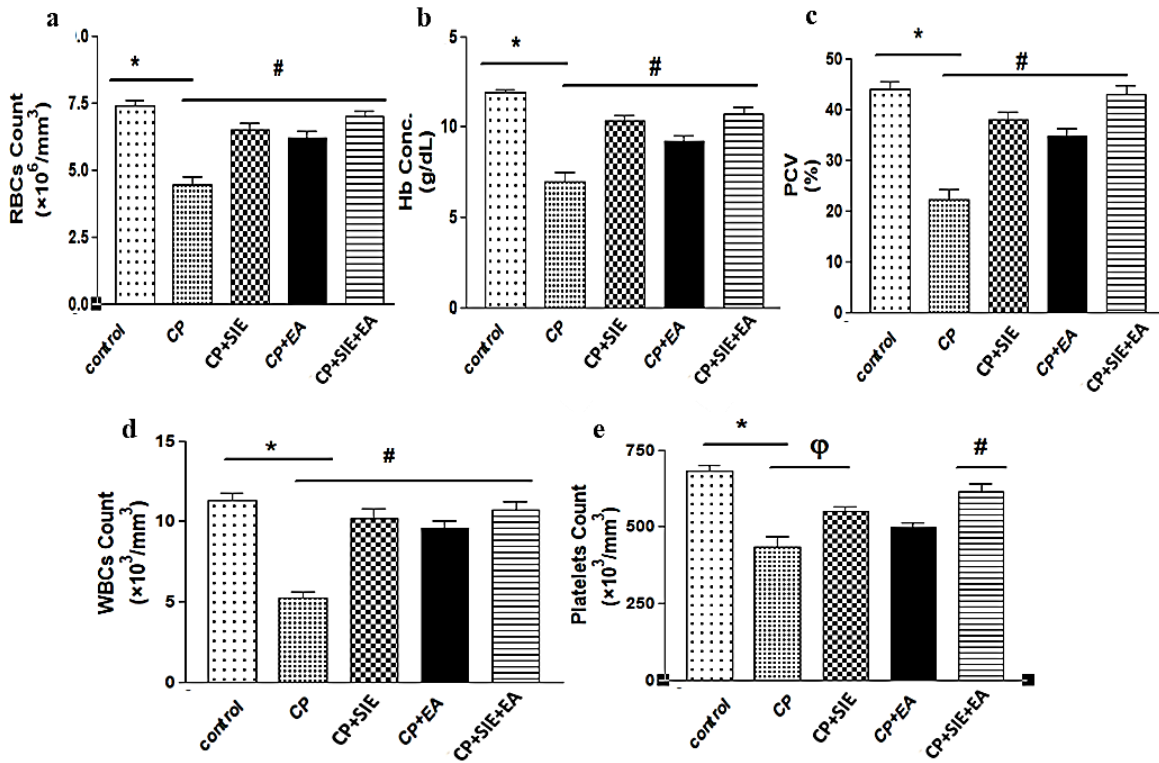


Figure 1. Therapeutic effects of SIE (200 mg/kg), EA (60 mg/kg) and SIE (200 mg/kg) + EA (60 mg/kg) on the hematological alterations induced by CP (200 mg/kg). (a) RBCs count, (b) Hb concentration (g/dl) (c) PCV%, (d) WBCs count and (e) Platelets count. * $P \leq 0.01$ as compared to control group. ϕ $P \leq 0.05$, # $P \leq 0.01$ as compared to CP treated group.

3. Biomarkers for renal Function

The current results revealed that CP treatment significantly increased the levels of creatinine, urea and uric acid ($P \leq 0.01$) as compared to the corresponding control group. Post-treatment either with SIE (200 mg/kg) or EA (60 mg/kg) improved the renal function biomarkers, where it significantly decreased the levels of creatinine, urea and uric acid ($P \leq 0.01$) as compared to CP treated group, this indicated an improved but not approached to the normal level. The same effect was observed in combined post-treatment group. Figs. (3a, b, c) pointed to the level of renal function biomarkers in the control and experimental groups. The result recorded a remarkable improvement, they become near to normal animals.

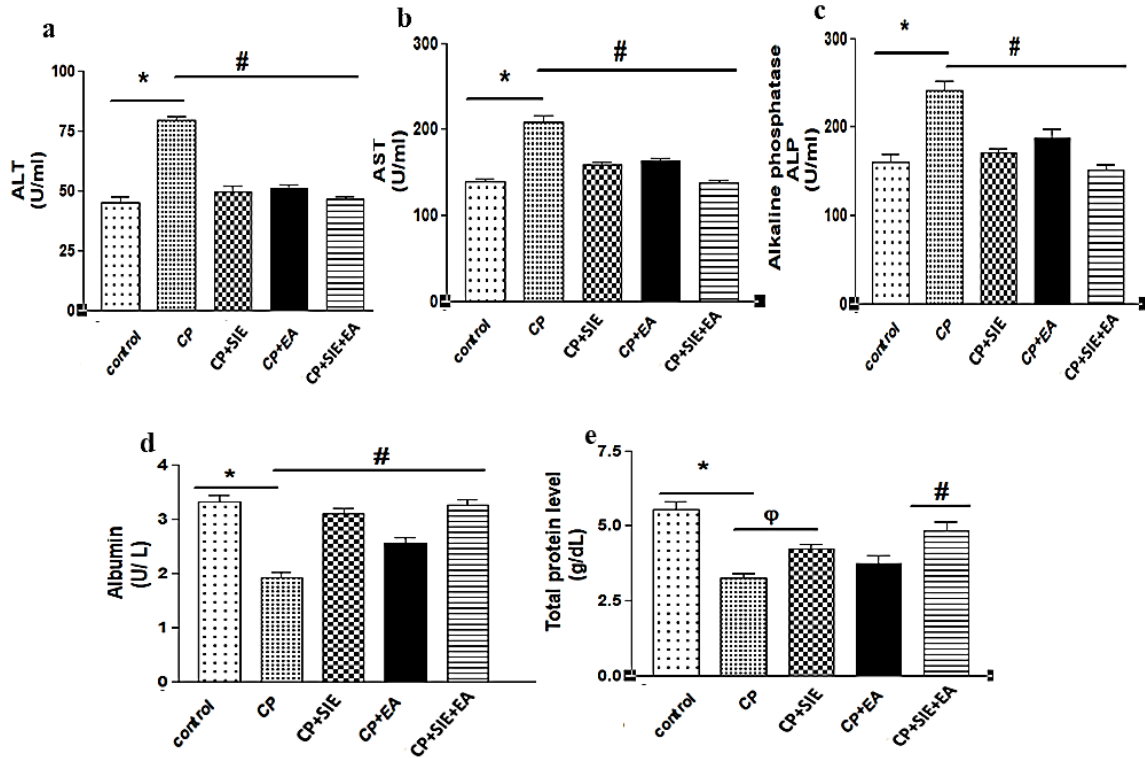


Figure 2. Therapeutic effects of SIE (200 mg/kg), EA (60 mg/kg) and SIE (200 mg/kg)+ EA (60mg/kg) against CP (200 mg/kg) on the hepatic biomarkers. (a) ALT (U/mL), (b) AST (U/mL), (c) ALP (U/mL), (d) Albumin (U/L) and (e) Total protein (g/dl)* $P \leq 0.01$ as compared to control group. ω $P \leq 0.05$, # $P \leq 0.01$ as compared to CP. treated group.

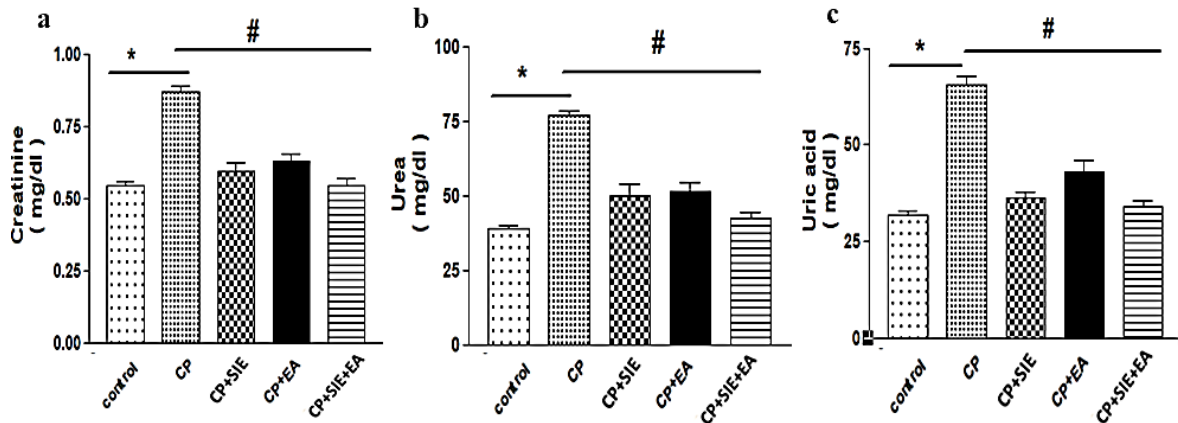


Figure 3. Therapeutic effects of SIE (200 mg/kg), EA (60 mg/kg) and SIE (200 mg/kg)+ EA (60 mg/kg) on the renal biomarkers alteration induced by CP (200 mg/kg). (a) Creatinine (mg/dl), (b) Urea (mg/dl) and (c) Uric acid (mg/dl).* $P \leq 0.01$ as compared to control group. # $P \leq 0.01$ as compared to CP treated group.

DISCUSSION

Anticancer medications are used under strict supervision because of their narrow therapeutic window, high toxicity profile and significance of drug interaction. The drugs especially affect vital organs like kidney or liver and those who undergo rapid cell division (**Raschi *et al.*, 2010**).

CP is an alkylating agent with extreme cytotoxic and immunosuppressive activity (**Vasiliou and Nebert, 2005**). The electrophilic alkyl group allows the drug to react with nucleophilic constituents of DNA or proteins, this leads to the covalent transfer of an alkyl group. CP requires activation by cytochromes (P450) in the liver (**Marchitti *et al.*, 2008**). The institution of hydroxyl group to the oxazaphosphorine ring produces 4-hydroxy cyclophosphamide, which co-occurs in equilibrium with its isomer, aldophosphamide. Then, aldophosphamide is converted into phosphoramidate mustard and acrolein. Acrolein is the cause of hemorrhagic cystitis, one of the major toxicities of CP therapy. Other toxicities with cumulative doses include bone marrow suppression, cardiotoxicity and gonadal toxicity (**Xie *et al.*, 2013**).

Generally, some antioxidant agents are considered useful to reduce the toxic adverse effects and oxidative stress induced by anticancer drugs. Accordingly, a treatment regimen with potential antioxidant agents could be an approach to ameliorate chemotherapeutic toxicity (**Selim *et al.*, 2018**). So this study focused on the therapeutic activity of SIE and EA as natural products against CP toxicity.

From the mentioned results it is clear that CP treatment resulted in disorders in the hematological constituents as manifested by severe decline in the RBCs count, remarkable fall in hemoglobin content (Hb) and highly significant drop in PCV value, WBCs and PLTs count, which may be owing to alteration in hemopoietic system of the animals. Similar observations were obtained by (**Kennedy *et al.*, 2014**). Many chemotherapeutic agents including CP have been implicated in short-term damage of the bone marrow which results in abnormally low numbers of leukocytes, erythrocytes and platelets regarded as bone marrow suppression (**Friberg *et al.*, 2002**).

The reduction in erythrocytes count could be consequent to a drop in their production and/or increased destruction where, the property of chemotherapeutic drugs is to kill rapidly dividing cancer and normal cells including RBCs. Results of the present study were in harmony with those of **Vinoy *et al.* (2013)** who suggested that bone marrow ability to produce new ones was inhibited by CP treatment. From the present results, the highly significant decrease of Hb content might be related to the decrease of RBCs count. Furthermore, ROS induced by CP may be caused hemoglobin oxidation and denaturation (**Puchala *et al.*, 2004**).

Leucopenia which was reported in the CP treated animals might be the consequence of CP-induced lipid peroxidation and damage of their cell membranes. CP affects the immune system by causing acute damage to the hemopoietic tissue, thus causing transient reduction in circulating leukocytes (**Hickman-Davis *et al.*, 2001**). It was also found that,

there is a highly significant decrease in platelets count. This is in agreement with **Ayhanci *et al.* (2009)**. The least toxic effect of CP was observed on the circulating thrombocytes, reduction in blood platelet count. A similar result was reported, indicating that reduction in platelets occurs only at high doses of CP (**Korkmaz *et al.*, 2007**). Besides that, the present recorded results in this study showed a highly significant drop in PCV value. The depression in the hematocrit value can be attributed to the total cell depletion in peripheral blood aided by disturbances in steady state mechanisms in blood forming organs after CP injection. The observed result runs in full agreement with **Zhang *et al.* (2017)**.

One of the aims of the present study is to evaluate the deleterious effects of CP and the therapeutic role afforded by SIE, EA and (SIE+ EA). The sepia ink extract administrated to rats injected with CP, improved the hematological parameters indicated by increasing of the RBCs count, hemoglobin contents (Hb) and PCV%, besides a remarkable improvement in WBCs and PLTs count.

EA is a naturally occurring polyphenolic compound that exhibits antioxidative, antiinflammatory, anti-hyperlipidaemic and anticarcinogenic activities (**Devipriya *et al.*, 2007**). In the current results RBCs, Hb and PCV%, WBCs and PLT count, obtained from administration of EA were approximately near to those of control group. These results might be attributed to the antioxidant activity of EA. **Jie-Ping *et al.* (2009)** revealed that SIE elevated leukocyte quantity due to improve hemopoiesis of marrow in mice but not reach to normal animals.

The current study revealed that hepatic damage induced by i.p treatment of CP, which is emphasized by highly significant elevation in serum levels of ALT, AST and ALP enzymes, while serum albumin and T. protein recorded a highly significant decline, which are considered to be the most sensitive biomarkers of liver injury (**Kim *et al.*, 2008**), where leakage of AST, ALT and ALP hepatic enzymes into the systemic circulation are routinely used as a reliable biochemical index for hepatocellular necrosis as cell damage (**Haldar *et al.*, 2011**). These deleterious changes in liver enzyme levels indicate a loss of tissue integrity with consequent apoptosis and necrosis of hepatocytes (**Amália *et al.*, 2007**). The present results are in agreement with other studies (**Germoush and Mahmoud, 2014**). CP treatment leads to the formation of toxic metabolite causes liver tissues injury as represented by an increase serum liver function enzymes (**Shokrzadeh *et al.*, 2014**).

High level of serum alkaline phosphatase is related to synthesis increased of it by cells lining bile canaliculi usually in response to cholestasis and increased biliary pressure (**Kanchana and Sadiq, 2011** and **Kasem, 2019**). In addition, **Senthilkumar *et al.* (2006)** found that hypo-proteinemia was observed in rats injected with CP for two days and attributed to the CP exerts a direct impact on plasma cells where, it inhibits protein synthesis and results in a liver damage cells. So that, the decreased level of serum total proteins and albumin in CP injected animals evidenced hepatotoxicity.

Albumin is the most important protein in plasma synthesized by the liver and is a useful indicator of hepatic function (**Singh and Khan, 2013**). Our study revealed that the serum albumin concentration of CP rats decreased significantly throughout the experimental periods. This decrease in serum albumin concentration could be related to hepatic dysfunction and decreased protein synthesis (**Helal et al., 2012**).

In parallel, previous reports have described CP induced hepatotoxicity. CP elevated circulating liver marker enzymes and produced a marked depression in antioxidant defense mechanism which was described as a major mechanism of CP induced hepatic damage. DNA damage is another proposed mechanism for CP hepatotoxicity (**Tuorkey, 2017**). CP could induce inflammation in liver tissue via regulation of pro-inflammatory cytokines (**Mahmoud et al., 2017**).

SIE was able to ameliorate injury induced by CP in model animals (**Wang et al., 2010**). A pronounced decrease in the activities of serum AST, ALT and ALP of rats treated with SIE throughout the experiment, as compared to CP group, indicates its ability to maintain hepatic function and structure of hepatic cells. Similarly, treatment with SIE caused general decreases in serum ALP activity in CP rats. The lowering of enzyme activity is a definite indication of hepatoprotective action and denotes functional integrity of the hepatic cell membrane (**Fahmy and Hamdi, 2011**). On the other hand, the serum albumin concentration of rats treated with SIE increased significantly after all experimental periods. This effect may be related to the antioxidant properties of SIE (**Lee et al., 2013**). Moreover, this increase may be due to enhanced synthesis of proteins and albumin, which works to accelerate the regeneration process, thus affording protection to the liver (**Murali et al., 2012**).

The present study also revealed that, administration of rats with EA ameliorated the liver biomarkers (ALT, AST and ALP). EA was reported to have hepatoprotective activity in experimental animals being useful in arresting hepatic fibrosis, reducing inflammation (**Girish and Pradhan, 2008**). It has also been reported that oral administration of EA decreases the activities of liver marker enzymes during toxicity (**Devipriya et al., 2007**).

Administration of EA significantly decreased the AST, ALT and ALP activities, suggesting that they offer protection by preserving the structural integrity of the hepatocellular membrane (**Priyadarsini et al., 2002**). Furthermore, EA protects hepatocytes from damage by inhibiting mitochondrial production of reactive oxygen species, also protects against cell death and elevation of ALT and AST in mice induced liver damage (**Hwang et al., 2010**). In addition, **Barch et al. (1996)** reported that EA induces cellular enzymes which detoxify carcinogens by increasing the expression of glutathione S-transferase-Ya gene through increasing total hepatic GST activity by inducing transcription of the GST-Ya gene. In addition, it caused alleviation in albumin and total protein disturbed by CP treatment. **Kannan et al. (2012)** showed that, pretreatment with EA improved serum albumin and total protein.

Our results disclosed that, serum creatinine increased significantly in CP treated group. Elevation of serum creatinine may be due to the hepatic damage which evolved into a stage with features of hepatorenal syndrome (Arroyo and Jimenez, 2000) including reduction in creatinine clearance and low glomerular filtration rate (Briglia and Anania, 2002). Also, concentration of serum uric acid significantly increased in CP treated rats. Oxidative stress is reported to play an important role in CP-induced renal damage (Abraham and Rabi, 2011). Increased triglyceride synthesis in individuals with metabolic abnormalities would also accelerate serum uric acid production and accumulation (Choi and Diehl, 2008).

On the other hand, supplementation with either IE or EA ameliorated the serum creatinine, urea and uric acid concentration after CP treatment in comparison with CP group. Atessahin *et al.* (2007) showed that, EA treatment provides a significant protection against nephrotoxicity and reduces plasma creatinine and urea levels. Decrease in the level of serum urea and creatinine biomarkers of renal damage in EA treated rats suggested that EA was effective in improving kidney function in treated rats (Amel *et al.*, 2014).

CONCLUSION

In conclusion, the present study demonstrated an evidence for the therapeutic effect of either IE or EA against the toxicity of CP anticancer drug. By combining CP treatment with natural products, the therapeutic effect could be represented by improvement the hematological, hepatic and renal status.

REFERENCES

- Abraham, P. and Rabi, S. (2011). Protective effect of amino guanidine against cyclophosphamide-induced oxidative stress and renal damage in rats. *Redox. Rep.*, 16 (1): 8–14.
- Ahlmann, M. and Hempel, G. (2016). The effect of cyclophosphamide on the immune system: implications for clinical cancer therapy. *Cancer Chemo. Ther. Pharmacol.*, 78:661–671.
- Alenzi, F. Q.; El-Bolkiny, Y. E. S. and Salem, M. L. (2010). Protective effects of *Nigella sativa* oil and thymoquinone against toxicity induced by the anticancer drug cyclophosphamide. *Br. J. Biomed. Sci.*, 67(1):20-8.
- Amália, P. M.; Possa, M. N.; Augusto, M. C. and Francisca, L. S. (2007). Quercetin prevents oxidative stress in cirrhotic rats. *Dig. Dis. Sci.*, 52, 2616-21.
- Amel, M.; Mohamed-Assem, S.; Hanan, M. and Ayman, S. (2014). Assessment of sepia ink extract role against the kidney dysfunction induced by bile duct ligation. *The Journal of Basic Appl. Zool.*, 67(5): 173-181.
- Arroyo, V. and Jimenez, W. (2000). Complications of cirrhosis. II. Renal and circulatory dysfunction. Lights and shadows in an important clinical problem. *J. Hepatol.* 32, 157–170.
- Atessahin, A.; Ceribasi, A. O.; Yuce, A.; Bulmus, O. and Cikim, G. (2007). Role of ellagic acid against cisplatin-induced nephrotoxicity and oxidative stress in rats. *Basic Clin. Pharmacol. Toxicol.*, 100(2): 121-6.

- Ayhanci, A.; Yaman, S.; Appak, S. and Gunes, S. (2009).** Hematoprotective effect of seleno-L-methionine on cyclophosphamide toxicity in rats. *Drug Chem. Toxicol.*, 32(4): 424-428.
- Barch, D. H.; Rundhaugen, L. M.; Stoner, G. D.; Pillay, N.S. and Rosche, W. A. (1996).** Structure-function relationships of the dietary anticarcinogen ellagic acid. *Carcinogenesis*, 17: 265-269.
- Briglia, A. E. and Anania, F. A. (2002).** Hepatorenal syndrome: definition, pathophysiology, and intervention. *Crit. Care. Clin.*, 18 (2): 345–373.
- Choi, S. S. and Diehl, A. M. (2008).** Hepatic triglyceride synthesis and nonalcoholic fatty liver disease. *Curr. Opin. Lipidol.*, 19 (3): 295– 300.
- Derby, C. D. (2014).** Cephalopod ink: Production, chemistry, functions and applications. *Mar. Drugs.*; 12:2700–2730.
- Devipriya, N.; Srinivasan, M.; Sudheer, A. R. and Menon, V. P. (2007).** Effect of ellagic acid, a natural polyphenol, on alcohol- induced prooxidant and antioxidant imbalance: a drug dose dependent study. *Singapore Med. J.*, 48(4): 311-8.
- Dumas, B. T.; Watson, W. A. and Biggs, H. G. (1971).** Albumin standards and the measurement of serum albumin with bromocresol green. *Clin. Chim. Acta.*, 258(1): 21-30.
- Elangovan, N.; Chiou, T. J.; Tzeng, W. F. and Chu, S. T. (2006).** Cyclophosphamide treatment causes impairment of sperm and its fertilizing ability in mice. *Toxicology*; 222:60-70.
- Fahmy, S. and Hamdi, S. (2011).** Curative effect of the Egyptian marine *Erugosquillamassavensis* extract on carbon tetrachloride-induced oxidative stress in rat liver and erythrocytes. *Eur. Rev. Med. Pharmacol. Sci.*, 15: 303-12.
- Fahmy, S. R. and Soliman, A. M. (2013).** *In vitro* antioxidant, analgesic and cytotoxic activities of *Sepia officinalis* ink and *Coelaturaa egyptiaca* extracts. *Afr. J. Pharm. Pharmacol.*, 7: 1512-1522.
- Fangping, L.; Ping, L. and Huazhong, L. (2018).** A potential adjuvant agent of a hemotherapy: *Sepia* ink polysaccharides. *Mar. Drugs*, 16, 106.
- Fawcett, J. and Scott, J. E. (1960).** A rapid and precise method for the determination of urea. *J. Clin. Pathol.*, 13: 156-169.
- Fossati P.; Prencipe, L. and Berti, G. (1980).** Use of 3,5- dichloro-2-hydroxybenzenesulfonic acid/4-aminophenazone chromogenic system in direct enzymic assay of uric acid in serum and urine. *Clin. Chem.*, 26(2): 227-231.
- Friberg, L. E.; Henningson, A.; Maas, H.; Nguyen, L.; and Karlsson, M. O. (2002).** Model of chemotherapy-induced myelosuppression with parameter consistency across drugs. *J. Clin. Oncol.*, 20(24): 4713-4721.
- Germoush, M. O. and Mahmoud, A. M. (2014).** Berberine mitigates cyclophosphamide induced hepatotoxicity by modulating antioxidant status and inflammatory cytokines. *J. Cancer Res. Clin. Oncol.*, 140(7): 1103-1109.
- Girish, C. and Pradhan, S. C. (2008).** Drug development for liver diseases: focus on picroliv, ellagic acid and curcumin. *Fundam. Clin. Pharmacol.*, 22(6): 623-32.
- Gornal, A. G.; Bardwil, G.S and David, M. M. (1949).** Determination of serum proteins by means of the biuret reaction. *J. Biol. Chem.*, 177: 751.
- Haldar, P. K.; Adhikari, S.; Bera, S.; Bhattacharya, S.; Panda, S. P. and Kandar, C. C. (2011).** Hepatoprotective efficacy of *Swieteniamahagoni* L. Jacq. (Meliaceae) bark against paracetamol-induced hepatic damage in rats. *Ind. J. Pharm. Edu. Res.*, 45(2): 108-113.

- Hanan, S.; Amel, M. S.; Ayman, S. M. and Mohamed-Assem S. M. (2015).** Antioxidant effect of *Sepia* ink extract on extra hepatic cholestasis induced by bile duct ligation in rats. *Biomed. Environ. Sci*, 28(8): 582-594.
- Helal, E. G.; El-Wahab, S. M. A. and Sharaf, A. M. M. (2012).** Effect of *Zingiber officinale* on fatty liver induced by oxytetracycline in albino rats. *Egy. J. Hospit. Medic*, 46: 26-42.
- Hickman-Davis, J. M.; Lindsey, J. R. and Matalon, S. (2001).** Cyclophosphamide decreases nitrotyrosine formation and inhibits nitric oxide production by alveolar macrophages in mycoplasmosis. *Infect. Immun.*, 69(10):6401-6410.
- Hwang, J. M.; Cho, J. S.; Kim, T. H. and Lee, Y. I. (2010).** Ellagic acid protects hepatocytes from damage by inhibiting mitochondrial production of reactive oxygen species. *Biomed. Pharmacol. Ther.*, 64(4): 264-70.
- IFCC (1986).** expert panel on enzymes part 3. *J. Clin. Chem.*, 24: 481-495.
- Israa, H. K.; Dhamia, K. S. and Balsam, A. H. (2019).** Cytotoxic effect of ink extracted from cephalopoda on cancer cell line. *Sci. J. Med. Res.*, 3(12): 139 – 145.
- Jie-Ping, Z.; Guang, W.; Jiang-Hua, S.; Jiang-Qiu, P.; Kun, L.; Yan, H. and Hua-Zhong, L. (2009).** Protective effects of squid ink extract towards hemopoietic injuries induced by cyclophosphamide. *Mar. Drugs*: 7, 9-18.
- Jismi, J.; Krishnakumar, K. and Dineshkumar, B. (2018).** Squid ink and its pharmacological activities. *GSC Biologic. Pharmace. Sci.*, 2(3): 017–022.
- Kanchana, N. and Sadiq, A. M. (2011).** Hepatoprotective effect of *Plumbago zeylanica* on paracetamol induced liver toxicity in rats. *Int. J. Pharm. Pharm. Sci.*, 3(1):151-154.
- Kannan, M. M.; Quine, S. D. and Sangeetha, T. (2012).** Protective efficacy of ellagic acid on glycoproteins, hematological parameters, biochemical changes, and electrolytes in myocardial infarcted rats. *J. Bio. Chem. Mol. Toxicol.*, 26(7): 270-5.
- Kasem, N. R. A. (2019):** Ameliorative Effects of *Annona muricata* (Graviola) and Fullerene C60 Against Toxicity Induced by Carboplatin in Male Albino Rats. *Egypt. Acad. J. Biolog. Sci.*, 11(3): 149- 168.
- Kennedy, C.; Erebi, P. and Adaobi, C. (2014).** Protective Potential of Aqueous Leaf extract of *Vernonia amygdalina* in Cyclophosphamide – Induced Myelotoxicity. *IOSR J. Pharma.*, 4(3):06-14.
- Kim, W. R.; Biggins, S. W. and Kremers, W. K. et al. (2008).** Hyponatremia and mortality among patients on the liver-transplant waiting list. *N. Engl. J. Med.*, 359: 1018-26.
- Korkmaz, A.; Topal, T. and Oter, S. (2007).** Pathophysiological aspects of cyclophosphamide and ifosfamide induced hemorrhagic cystitis; implication of reactive oxygen and nitrogen species as well as PARP activation. *Cell. Biol. Toxicol.*, 23(5): 303-312.
- Kumar, P.; Kannan, M.; ArunPrasanna, V.; Vaseeharan, B. and Vijayakumar, S. (2018).** Proteomics analysis of crude squid ink isolated from *Sepia esculenta* for their antimicrobial, antibiofilm and cytotoxic properties. *Microb. Pathog.*, 116: 345–350.
- Le, X.; Luo, P.; Gu, Y.; Yexing, T.Y and Liu, H. (2015).** Squid ink polysaccharide reduces cyclophosphamide-induced testicular damage via Nrf2/ARE activation pathway in mice. *Iran. J. Basic Med. Sci.*, 18(8): 827- 831.
- Lee, J. W.; Cho, H. B. and Nakayama, T. (2013).** Dye-sensitized solar cells using purified squid ink nanoparticles coated on TiO₂ nanotubes/nanoparticles. *J. Ceramic Soc. Japan*, 121, 123-7.

- Lei, M.; Wang, J. F.; Wang, Y. M.; Pang, L.; Wang, Y.; Xu, W. and Xue, C. H. (2007).** Study of the radio-protective effect of cuttlefish ink on hemopoietic injury. *Asia Pac. J. Clin. Nutr.*, 16(1):239–243.
- Liang, W. Z.; Chou, C. T.; Cheng, J. S.; Wang, J. L.; Chang, H. T. and Chen, I. S. (2016).** The effect of the phenol compound ellagic acid on Ca⁽²⁺⁾ homeostasis and cytotoxicity in liver cells. *Eur. J. Pharmacol.*, 780:243-51.
- Liu, H. Z.; Luo, P.; Chen, S. H. and Shang J. H. (2011).** Effects of squid ink on growth performance, antioxidant functions and immunity in growing broiler chickens. *Asian Austral. J. Anim. Sci.*, 24:1752–1756.
- Mahmoud, A. M.; Germoush, M. O.; Alotaibi, M. F. and Hussein, O. E. (2017).** Possible involvement of Nrf2 and PPAR γ up-regulation in the protective effect of umbelliferone against cyclophosphamide-induced hepatotoxicity. *Biomed. Pharmacol. Ther.*, 86: 297–306.
- Marchitti, S. A.; Brocker, C.; Stagos, D. and Vasiliou, V. (2008).** Non-P450 aldehyde oxidizing enzymes: the aldehyde dehydrogenase superfamily. *Expert. Opin. Drug. Metab. Toxicol.*, 4 (6): 697–720.
- Moss, D. W. (1982).** Alkaline phosphatase isoenzymes. *Clin. Chem.*, 28: 2007-2016.
- Murali, A.; Ashok, P. and Madhavan, V. (2012).** Protection against CCl₄ induced hepatotoxicity by pretreatment with methanol extract of *Hemidesmus indicus* var. pubescens leaf in Wistar rats. *Int. J. Appl. Res. Natur. Prod.*, 5, 5-13.
- Muthukumar, S.; Tranchant, C. and Shi, J. (2017).** Ellagic acid in strawberry (*Fragaria* spp.): Biological, technological, stability, and human health aspects. *Food Qual. Saf.*, 1(4): 227–252.
- Nelius, T.; Klatter, T.; de Riese, W.; Haynes, A. and Filleur, S. (2010).** Clinical outcome of patients with docetaxel-resistant hormone-refractory prostate cancer treated with second-line cyclophosphamide-based metronomic chemotherapy. *Med. Oncol.* 27 (2): 363–367.
- Priyadarsini, K. I.; Khopde, S. M.; Kumar, S. S. and Mohan, H. (2002).** Free radical studies of ellagic acid, a natural phenolic antioxidant. *J. Agric. Food Chem.* 50(7):2200-6.
- Puchala, M.; Szwed-Lewandowska, Z. and Kiefer, J. (2004).** The influence of radiation quality on radiation-induced hemolysis and hemoglobin oxidation of human erythrocytes. *J. Radiat. Res.*, 45(2): 275-280.
- Raschi, E.; Vasina, V.; Ursino, M. G.; Boriani, G. and Martoni, A. (2010).** Anticancer drugs and cardiotoxicity: insights and perspectives in the era of targeted therapy. *Pharmacol. Ther.*, 125(2): 196-218.
- Rehman, M. U.; Tahir, M.; Ali, F.; Qamar, W.; Lateef, A.; Khan, R.; Quaiyoom, A.; Oday-OHamiza and Sultana, S., (2012).** Cyclophosphamide-induced nephrotoxicity, genotoxicity, and damage in kidney genomic DNA of Swiss albino mice: the protective effect of Ellagic acid. *Mol. Cell. Biochem.*, 365 (1-2): 119–127.
- Saba, K. S.; Parvez, S.; Chaudhari, B.; Ahmad, F.; Anjum, S. and Raisuddin, S. (2013).** Ellagic acid attenuates bleomycin and cyclophosphamide-induced pulmonary toxicity in Wistar rats. *Food Chem. Toxicol.*, 58:210–219.
- Sarker, U. and Oba, S. (2019):** Antioxidant constituents of three selected red and green color *Amaranthus* leafy vegetable. *Sci. Rep.*, 9(1):18233.
- Selim, M. S.; Amer, S. K.; Mohamed, S. S.; Mounier, M. M. and Rifaat, H. M. (2018).** Production and characterization of exopolysaccharide from *Streptomyces carpaticus* isolated from

marine sediments in Egypt and its effect on breast and colon cell lines. *J. Genet. Eng. Biotechnol.*, 16 (1): 23–28.

Senthilkumar, S.; Devaki, T.; Manohar, B. M. and Babu, M. S. (2006). Effect of squalene on cyclophosphamide- induced toxicity. *Clin. Chim. Acta.*, 364(1-2): 335–342.

Shokrzadeh, M.; Ahmadi, A.; Naghshvar, F.; Chabra, A. and Jafarinejad, M. (2014). Prophylactic efficacy of melatonin on cyclophosphamide induced liver toxicity in mice. *Biomed. Res. Int.*, 2014: 470425.

Singh, P. and Khan, S. (2013). Prevalence of jaundice based on liver function test in western nepal. *Bali Med. J. (Bmj)*, 2.

Soliman, A. M. (2011). The extract of *Coelatura aegyptiaca*, a freshwater mussel, ameliorates hepatic oxidative stress induced by monosodium glutamate in rats. *Afr. J. Pharm. Pharmacol.*, 5: 398-408.

Tuorkey, M. J. (2017). Therapeutic potential of *Nigella sativa* oil against cyclophosphamide induced DNA damage and hepatotoxicity. *Nut. Cancer*, 69 (3):498–504.

Vasiliou, V. and Nebert, D. W. (2005). Analysis and update of the human aldehyde dehydrogenase (ALDH) gene family. *Hum. Genomics*, 2(2):138–43.

Vate, N. K.; Benjakul, S. and Agustini, T. W. (2015). Application of melanin-free ink as a new antioxidative gel enhancer in sardine surimi gel. *J. Sci. Food Agric.*, 95:2201–7.

Vinoy, S. K.; Sheetla, C.; Nargis, K.; Rajendra, C. and Arun, R. K. (2013). Cyclophosphamide induced changes in certain hematological and biochemical parameters of adult male *Rattus norvegicus*. *Int. J. Appl. Biol. Pharm. Tech.*, 4(2):74-78.

Wang, G.; Guo, Y. Z.; Guan, S. B.; Zhong, J. P.; Pan, J. Q.; Huang, Y. and Liu, H. Z. (2009). Protective effects of sepia ink extract on cyclophosphamide-induced pulmonary fibrosis in mice. *Chin. J. Mar. Drugs.*, 28:36–40.

Wang, G.; Liu, H. and Wu, J. (2010). Study of sepia ink extract on protection from oxidative damage of cardiac muscle and brain tissue in mice. *Chin. J. Mod. Appl. Pharm.*, 2: 95-9.

Xie, H.; Lundgren, S.; Broberg, U.; Finnstnim, N.; Rane, A. and Hassan, M. (2002). Effect of cyclophosphamide on gene expression of cytochromes P450 and B-actin in the HL-60 cell line. *Eur. J. Pharmacol.*, 449(3): 197-205.

Xie, Y.; Wang, M.; Zhang, Y.; Zhang, S.; Tan, A.; Gao, Y.; Liang, Z.; Shi, D.; Huang, Z. and Zhang, H. (2013). Serum uric acid and nonalcoholic fatty liver disease in non-diabetic chinese men. *Plos One* 8 (7): e67152.

Zakaria, F.; Fadjar, M. and Yanuhar, U. (2019). Cuttlefish (*Sepia* sp.) ink extract as antibacterial activity against *Aeromonas hydrophila*. *Int. j. Sci. Technol. res.*, 8(11): 1175-77.

Zhang, L.; Gong, A. G.; Riaz, K.; Deng, J. Y.; Ho, C. M.; Lin, H. Q.; Dong, T. T.; Lee, Y. K. and Tsim, K. W. (2017). A novel combination of four flavonoids derived from *Astragali radix* relieves the symptoms of cyclophosphamide-induced anemic rats. *FEBS Open Bio.*, 7(3):318-323.

Zong, A.; Zhao, T.; Zhang, Y.; Song, X.; Shi, Y. and Cao, H. *et al.*, (2013). Anti-metastatic and anti-angiogenic activities of sulfated polysaccharide of *Sepiella maindroni* ink. *Carbohydr. Polym.*, 91:403–409.