

EFFECT OF POMEGRANATE PEEL ON THE BLOOD LIPID PROFILE OF EXPERIMENTAL RATS

*Wafai Z.A. Mikhail, * Hassan M. Sobhy, ** Sahar A. Khairy,
**Magda Ramzy **Ola Ail Ail

* Institute of African Research and Studies, Cairo University** National Nutrition Institute, Cairo Egypt

ABSTRACT

Background: This study was carried to investigate the effects of pomegranate peels (*Punic granatum L*), on the blood lipid level, some physiological parameters as liver function, kidney function, histological properties of Heart in hypercholestrmic.

Rats were divided into 2 groups first group as negative group and the second group thypercholestrmic group which divided into 4 groups positive control, and 3 thypercholestrmic groups, fed on several diets containing 5%, 10%,15% of pomegranate peels for 28 days. Peel was cleaned from impurities and washed with tap water. Drying Oven air dry at 45 °C was used for 48 hours to dry the peel, then ground in a Multi Mill apparatus to passé through a 50 mesh sieve to obtain a fine peel powder . Bodyweight gain, feed intake and feed efficiency ratio were calculated at the end of experiment. Fasting blood sample were taken on day 28 for the determination of serum total cholesterol (TC) , serum triglycerides (TG) , HDL cholesterol,LDL cholesterol ,creatinine, serum urea, aspartate aminotransferase (AST) and glutamic pyruvic transaminase (GPT). The heart of all animals were carefully removed and slices from them were fixed in 85% alcohol for 24 hours, and then processed for paraffin embedding. Histological sections, 7 micron-thick, were cut and stained with heamatoxylin and eosin. They were then microscopically examined to evaluate the effects of the three differ concentration of formalin on these organs.

It was concluded that treatment using pomegranate peel (*Punic granatum L*), reduced significantly LDL-c ,Serum triglycerides in hypercholestrmic rats which fed different levels of pomegranate peel and the decrease was the best as the level of supplement peels increased.

تأثير قشور الرمان علي مستوي دهون الدم لفئران التجارب

*وفائي زكي عازر ميخائيل، * حسن محمد صبحي، ** سحر عبد العزيز خيرى،

** ماجدة رمزي قسطندي، ** علا علي علي

قسم الإحتياجات الغذائية والنمو- المعهد القومي للتغذية- القاهرة**

*معهد البحوث الافريقية قسم الموارد الطبيعية، جامعة القاهرة

الملخص العربي

يهدف هذا البحث إلى إمكانية استخدام بعض مخلفات الثمار مثل قشور الرمان لإعداد وجبات غنية بالألياف عن طريق إضافتها بنسبة ٥%، ١٠%، ١٥% من القشور. فى هذه التجربة تم تقسيم الفئران إلى خمسة مجموعات المجموعة الأولى هى الكنترول السالب والأربع مجموعات الأخرى فتم إصابتها بارتفاع الكوليسترول وذلك بتغذيتها على ١,٥% كوليسترول لمدة أسبوعين وتركت إحداهما كمجموعة ضابطة موجبة والثلاث مجموعات الأخرى تم إضافة مسحوق قشور الرمان (بعد تنظيفها بالماء وتجفيفها على درجة حرارة ٤٥م لمدة ٤٨ ساعة وطحنها) بنسب ٥%، ١٠%، ١٥% وتم تغذية الفئران على الوجبات لمدة ٢٨ يوم. فى نهاية التجربة تم ذبح الفئران وقياس مستوى الدهون في الدم والجليسريدات الثلاثية (TG) والكوليسترول، HDLC، ووظائف الكلى والكبد وإجراء الفحص الهستولوجى للقلب.

أوضحت النتائج انخفاض وزن الفئران عند تغذيتهم على القشور ولوحظ أيضا أن الألياف الموجودة فى القشور أدت الى انخفاض مستوى كلا من الكوليسترول الكلى والجليسريدات الثلاثية. وقد وجد ان تناول النسب العالية من القشور تؤدي إلى نتائج أفضل .

الكلمات الكاشفة :-

قشور الرمان - الكوليسترول- تراي جليسيريد- وظائف الكلى- وظائف الكبد

INTRODUCTION

Pomegranate (*Punica granatum* L.) is an important fruit crop of tropical and subtropical regions of the world. Pomegranate fruit is consist of three parts: the seeds (about 3% of the weight of the fruit); the juice (about 30% of the fruit weight) and the peels which include the husk and interior network membranes. Health benefits of pomegranate peel (antioxidant, antimicrobial, anti inflammatory, anticancer and other biological activities) recently reviewed by **Prakash and Prakash (2011)**.

Hyperlipidemia contributes significantly in the manifestation and development of atherosclerosis and coronary heart diseases (CHD). Cardiovascular diseases, including atherosclerosis are the most common cause of mortality and morbidity worldwide (**Yokozawa et al., 2003**). Several factors, such as diet rich in saturated fats and cholesterol, age, family history, hypertension and life style play a significant role in causing heart failure. The high levels of cholesterol particularly LDL cholesterol are mainly responsible for the onset of CHDs (**Farias et al., 1996 and Yokozawa et al., 2003**).

AIM OF THE STUDY

This study aimed to evaluate the effect of pomegranate peel on the blood lipid level, some physiological parameters as liver function, kidney function, and histological properties of Heart in hypercholestrmic rats.

MATERIALS AND METHOD:

MATERIAL:

Pomegranate fruits (*punica granatum L*) were obtained from local market. Preparation of peel was cleaned from impurities and washed with tap water. Drying Oven air at 45 °C was used for 48 hours to dry peels, then it was ground in a Multi Mill apparatus and passed through a 50 mesh sieve to obtain a fine peel powder.

Rats :- Fifty four adult male albino rats, Sprague dawley strain, mean weight was 200±10 g were obtained from Research Institute of Ophthalmology Medical Analysis Department, Giza, Egypt. The animals were divided into five groups and housed individually in stainless steel cages, fitted with a wire mesh bottoms and front in room maintained at 25 – 30°C with about 50% relative humidity. The room was lighted daily photoperiod of 12 h light and 12 h dark. During the conditioning period and throughout the trial food and tap water were provided adlibitum.

Rats were divided into 2 groups and were housed individually in the wire cage. First group: fed on basal diet. Second group (hypercholestrmic rats). Hypercholesterolemia was induced in normal healthy adult male albino rats by feeding on hyperlipidemic diet (1.5% cholesterol and +10% lard) for 2 weeks, then fasting blood serum obtained and total cholesterol, VLDL, LDL, HDL and TG level were estimated.

Grouping of rats: - **First group:** 6 rats fed on basal diet only (G1) the negative control.

Second group (hypercholestrmic rats): hypercholestrmic albino were divided in to 4 group 6 rats in each group as follows:

The positive control (G2): Fed on basal diet as (hypercholestrmic control).

Group G3: Fed on basal diet +5% pomegranate peel instead of starch.

Group G4: Fed on basal diet +10% pomegranate peel instead of starch.

Group G5: Fed on basal diet +15% pomegranate peel instead of starch.

Diet: The basal diet was prepared according to **AIN(1993)**. The vitamin mixture and the salt mixture were prepared according to **AIN(1977)**.

The organ weight was taken on the day of sacrifice (final). The testicles were separated through dissection after trimming off the attached tissues and weighed using volume displacement method.

Biochemical analysis Blood:

At the start of the experimental period the animals were fasted for 12 h. Weekly blood samples were taken from retro orbital. Blood samples were collected in a clean dry centrifuge tube from hepatic vein, and try these in 1 week and in 2 week of experimental period.

At the end of the 4 weeks of experimental period, the animals were fasted for 12 h. They were anesthetized with diethyl ether. Incisions were made into the abdomen and blood was drawn from hepatic vein. Blood sample was taken on EDTA as whole blood sample for determination blood petsher. Blood samples were immediately collected in dry clean tubes form the portal vein and left to clot at room temperature. Another part tube without anticosulant takes for separation of serum by centrifugation at 4000 r.p.m for 10 minutes. The collected samples were analyzed for the following Biochemical parameters. Serum Cholesterol **Allain et al (1974)**. Determination of serum triglycerides **Fossatip and Prancipel(1982)**, high density lipoprotein (HDL) Cholesterol **Burstein(1970)**, Determination of phospholipids **Zolliner and Eberhagal, (1965)** Determination of free fatty acids. (**Falholt et al1973**) and Total Lipids of liver the method which was used according to **Bligh and Dyer (1959)**. Creatinine was determined according to the method described by **Bohmer (1971)**. Urea was determined according to the method described by **Patton and Crouch (1977)**. Aspartate aminotransferase (AST) and Alkaline phosphate (ALT) activities were measured according to method described by **Reitman and Frankel (1957)**.

Histological study: All animals were sacrificed under anathesia on the 4th week of experiment. The heart of all animals was dissected removed and fixed in 10% formalin solution. The fixed specimens were then trimmed, washed and dehydrated in ascending grades of alcohol. These specimens were cleared in xylene, embedded in paraffin, sectioned at 4 – 6 microns thickness and stained with Hematoxylen and Eosin (H&E) then examined microscopically according to **Carle`ton (1979)**.

Statistical analysis: Statistical analysis was carried out according to **Snedecor and Cochran (1972)**, as the mean \pm standard deviation (SD). Statistical analyses was preformed with statistical package for social science for windows (spss , version 11.0, Chicago , DL-USA).The data were analyses by one- way analyses

of variance (ANOVA). To compare the difference between groups, post hoc listing was performed by L.S.D test.

RESULTS AND DISCUSSION

Data In Table (1) show the effect of feeding different levels of pomegranate peel on feed intake, efficiency ratio (FER) and Body weight gain (BWG) in hypercholestrmic rats. FI decrease in all groups when compared with positive and negative control groups. On the other hand ,FER in all hypercholestrmic groups increased when compared with the positive group, especially G4 (10% peels). BWG showed a gradual increase as the level of supplement increased. These results are in accordance with those of **Abdel-Rahim, et al., (2013)**.

Data In Table (2) reflects the effect of feeding different levels of pomegranate peel on relative weight of the organs of hypercholestrmic rats. The obtained data illustrated that hypercholestrmic rats had a gradual decrease of relative kidney weight ,heart weight and liver weight .But spleen weight in G3,G4 increased while decrease in G5. The statistical analysis showed a low significant correlation between treatments and organs ratio compared with the positive control. On the other hand, the supplemented hypercholestrmic groups had a significant decrease in liver and kidney by feeding rats on pomegranate peel. This may be due to peels polyphenols which increased the antioxidant capacity against the free radical in some organs. These results are in accordance with those of **Oluremi et al., (2008)**

Table (3) showed the feeding effect of different levels of pomegranate peel on liver lipids of hypercholestrmic rats. Lipids of hypercholestrmic rats which fed on different levels of pomegranate peels showed a gradual decrease as the level of supplemented increased. The Table illustrated a decrease of liver phospholipids, varies among pomegranate peel feeding levels. The obtained data showed a gradual decrease of liver content of free fatty acids as a result of increased feeding pomegranate peel as supplemented in the diets. HDL-cholesterol of liver showed a gradual increase as the feeding supplemented pomegranate peel increased when compared with the positive control. These results are in agreement with those reported by **Abdel-Rahim et al.(2013)** , **Neyrinck et al. (2013)** and **Zhou Zhong; et al. (2012)**.

Dietary supplementation of pomegranate peel could be used to have a favorable effect on improved CF digestibility coefficient, blood level profile, the semen quality and antioxidant status. Addition of pomegranate peel may have an extra protective effect according to its contents of natural antioxidants **Fayed, et al.,(2012)**. These results suggest that WIFF (The water-insoluble fiber-rich fraction). Could be a potential cholesterol-lowering ingredient in human diets or new formulations of fiber-rich functional foods. **Chau et al.,(2004)**.

Table (4) showd the effect of feeding different levels of pomegranate peel on liver functions of hypercholestrmic rats. There were decreases in aspartame amino transferase (AST) levels ,and a gradual decrease of alanine amino transferase (ALT) level as supplement level increased compared with the

positive control group. **Chau *et al.* (2004)** reported that pomegranate Peel is rich in polyphenols that exhibit antioxidant and anti-inflammatory capacities in vitro.

Table (5) reflects the effect of feeding on different levels of pomegranate peel supplement on kidney functions of hypercholestrmic rats. Data recorded a gradual decrease in serum creatinine , as the feeding level of pomegranate peel increased . Urea showed a gradual decrease with the increase of supplement peels level when compared with the positive control group. These results are in agreement with those reported by **Adler *et al.* (2007)**.

Data in Table (6) recorded the effect of feeding on different levels of pomegranate peel on blood lipid in hypercholestrmic rats ,showed a gradual decrease in blood lipid as the level of supplement increased. Also, a gradual decrease of triglyceride, VLDL as a result of increased feeding pomegranate peels in the diets. While LDL decreased in G3 and G4 but increased in G5. Also total cholesterol decreased in G4, but increased in G5. HDL-cholesterol showed a gradual increase as the feeding supplement pomegranate peel increased when compared with the positive control. These results are in agreement with those reported by **Adler *et al.* (2007)** and **Allain (2004)** who reported that pomegranate peel decreased blood lipid profile.

In conclusion, supplementation with pomegranate peels reduced serum cholesterol and triglycerides concentration and the reduction was better with the increase in peel concentrations.

Table (1): Effect of feeding on different levels of pomegranate peels on feed intake, food efficiency ratio (FER) and body weight gain (BWG) of hypercholesterolemic rats.

Groups Parameter	G1 (-ve)	G2 (+ve)	G3 5%	G4 10%	G5 15%	LSD
FI	14.32 ^a ±	9.67 ^b ±	8.54 ^b ±0.	8.38 ^b ±0.	9.78 ^b ±0.	1.405
Mean±SD	0.56	0.72	83	84	86	
FER	0.14 ^a ±0.	0.10 ^d ±0.	0.10 ^d ±0.	0.13 ^b ±0.	0.11 ^c ±0.	0.0041
Mean± SD	002	001	001	002	004	
BWG(g/d)	42.27 ^a ±	29.12 ^c ±	28.28 ^c ±	30.12 ^c ±	33.17 ^b ±	2.262
Mean± SD	1.22	1.84	0.99	0.98	0.96	

*Mean± SD

Different letters on the numbers mean significant differences at P<0.05.
Feed intake (FI). Food efficiency ratio (FER). Body weight gain (BWG).

Table (2): Effect of feeding on different levels of pomegranate peel on relative organs weight of hypercholesterolemic rats (g).

Groups Feeding period	G1 (-ve)	G2 (+ve)	G3 5%	G4 10%	G5 15%	LSD
Liver	5.92 ^b ± 0.05	8.34 ^a ± 0.18	6.12 ^b ±0. 43	6.58 ^b ± 0.87	5.02 ^c ± 0.03	0.804
Kidney	0.98 ^c ± 0.01	1.78 ^a ± 0.02	1.15 ^{bc} ±0 .33	1.27 ^b ± 0.19	0.9 ^c ± 0.03	0.3113
Spleen	1.43 ^a ± 0.18	0.76 ^c ± 0.19	1.03 ^b ±0. 12	1.00 ^b ± 0.01	0.53 ^c ± 0.02	0.235
Heart	0.75 ^a ± 0.19	0.76 ^a ± 0.15	0.64 ^d ± 0.04	0.67 ^c ± 0.03	0.77 ^a ± 0.08	0.0113

*Mean±SD

Different letters on the numbers mean significant differences at P<0.05.

Table (3): Effect of feeding on different levels of pomegranate peel on liver lipid of hypercholesterolemia (mmol/L).

Groups Lipid profile	G1 (-ve)	G2 (+ve)	G3 5%	G4 10%	G5 15%	LSD
Total cholesterol	2.01 ^d ± 0.93	3.10 ^a ± 0.95	2.80 ^b ± 0.56	2.55 ^c ± 0.78	2.33 ^c ± 0.46	0.243
Triglycerides	1.11 ^b ± 0.22	1.62 ^a ± 0.43	1.38 ^{ab} ±0.19	1.32 ^{ab} ± 0.16	1.15 ^{ab} ±0.17	0.464
Phospholipids	1.14 ^d ±0.13	1.55 ^a ± 0.14	1.40 ^b ± 0.34	1.31 ^c ± 0.56	1.14 ^d ± 0.78	0.113
Free fatty acids	1.52 ^a ± 0.66	1.77 ^a ± 0.33	1.61 ^b ± 0.34	1.52 ^b ± 0.67	1.42 ^a ± 0.18	0.153
HDL-cholesterol	0.98 ^a ± 0.13	0.88 ^e ± 0.05	0.92 ^d ± 0.03	0.94 ^c ± 0.02	0.96 ^b ± 0.04	0.010

**Mean± SD

Different letters on the numbers mean significant differences at P<0.05.

Table (4): Effect of feeding on different levels of pomegranate peels on liver functions of hypercholesterolemic rats.

Groups Liver functions	G1 (-ve)	G2 (+ve)	G3 (5%)	G4 (10%)	G5 (15%)	LSD
GPT(ALT)	27.70 ^c ±1.2	35.00 ^a ±0.9	31.63 ^b ± 0.9	31.40 ^b ±0.3	25.95 ^c ±0. 8	1.888
GOT(AST)	28.00 ^e ±1.5	68.00 ^b ±0.5	61.33 ^c ± 1.02	77.50 ^a ±1.3	48.28 ^d ±1. 11	2.068

*Mean± SD

Different letters on the numbers mean significant differences at P<0.05.

Table (5): Effect of feeding on different levels of pomegranate peels on kidney functions of hypercholesterolemic rats.

Groups	G1 (-ve)	G2 (+ve)	G3 (5%)	G4 (10%)	G5 (15%)	LSD
Kidney functions						
Creatinine (mg/100ml)	0.57 ^a ±0.03	0.52 ^{ab} ±0.02	0.47 ^b ±0.04	0.49 ^b ±0.03	0.45 ^b ±0.06	0.1329
Urea (mg/100ml)	51.17 ^d ±1.1	61.40 ^a ±0.95	54.30 ^c ±1.2	59.00 ^b ±0.18	55.17 ^c ±0.56	1.476

*Mean±SD

Different letters on the numbers mean significant differences at P<0.05.

Table (6): Effect of feeding on different levels of pomegranate peel on blood lipid of hypercholesterolemic rats (mmol/L).

Groups	G1 (-ve)	G2 (+ve)	G3 (5%)	G4 (10%)	G5 (15%)	LSD
Lipid profile						
Total cholesterol	67.17 ^c ±1.18	70.00 ^b ±1.20	71.67 ^b ±0.78	61.83 ^a ±0.98	78.00 ^a ±1.04	1.905
Triglycerides	84.67 ^b ±1.02	261.00 ^a ±2.18	78.67 ^c ±1.02	68.33 ^a ±1.04	78.50 ^c ±1.43	2.469
HDL-c	48.83 ^c ±0.91	29.60 ^c ±0.88	63.17 ^a ±0.65	41.50 ^a ±0.56	58.50 ^b ±0.34	0.858
LDL-c	45.50 ^c ±0.25	54.60 ^b ±0.35	40.17 ^a ±0.33	36.17 ^a ±0.40	57.17 ^a ±0.25	4.089
VLDL-c	16.90 ^b ±0.33	52.20 ^a ±0.32	15.73 ^c ±0.43	13.66 ^a ±0.36	15.70 ^c ±0.77	0.8605

*Mean± SD

Different letters on the numbers mean significant differences at P<0.05

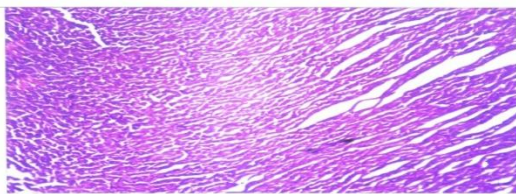


Photo (1): Heart of rat from group G1 showing heart tissue with normal preserved elongated spindle cells cardiac cells arranged transverse and long tvdinal pattern with normal vascular arrangement. (H& E.× 100).

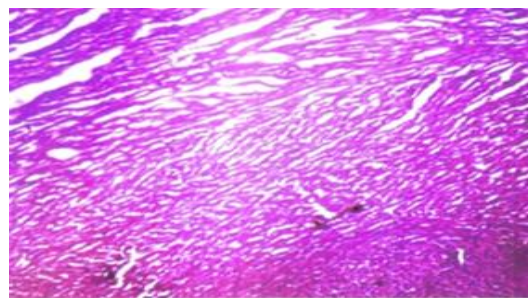


Photo (2): Heart of rat from group G2 photomicrography showed heart tissue with normal preserved elongated spindle. Cells cardiac cells arranged transverse and long tvdinal pattern with normal vascular arrangement (H& E. × 100).

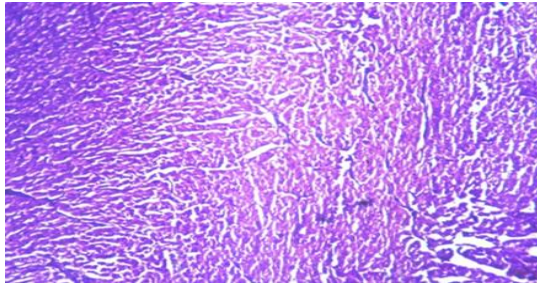


Photo (3) : Heart of rat from group G3 showing heart tissue with normal preserved elongated spindle cells cardiac cells arranged transverse and long tvdinal pattern with normal vascular arrangement (H& E .× 100).

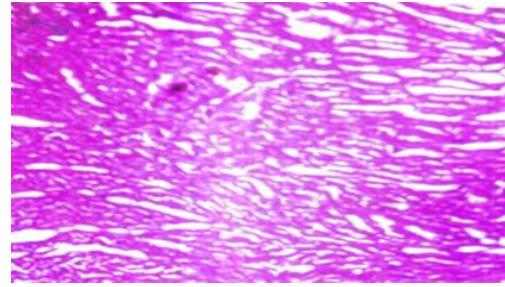


Photo (4): Heart of rat from group G4 photomicrography showed heart tissue with normal preserved elongated spindle .cells cardiac cells arranged transverse and long tvdinal pattern with normal vascular arrangement. (H& E. × 100).

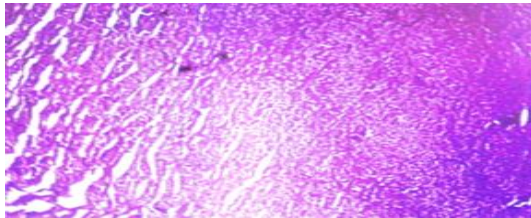


Photo (5): Heart of rat from group G5 photomicrography showed heart tissue with normal preserved elongated spindle .cells cardiac cells arranged transverse and long tvdinal pattern with normal vascular arrangement. (H& E. × 100).

Microscopically, Heart of rat from all groups (negative positive and hpositive and hypercholestrmic groups) showed no histopathological changes were mentioned.

References

- Abdel-Rahim, E. A.; El-Beltagi, H. S. and Romela, R. M.,(2013).** White bean seeds and pomegranate peel and fruit seeds as hypercholesterolemic and hypolipidemic agents in albino rats.
- Adler,A,I .;Stratton,I.M. and Neil, H.A.(2007).** Association of systolic blood pressure with macrovascular and microvascular complications of type 2 diabetes 33 (6): 395 – 402.
- AIN (1993)** .American Institute of Nutrition (AIN), Purified diet for Laboratory Rodent. J. Nutr. 123:1939-1951.
- AIN (1977).** American Institute of Nutrition (AIN), Committee on Standard Nutritional Studies. J. Nutr. 107:1340-1348.
- Allain, C. Z.; Poon, L. S. and Chan, C. S. (1974).** Enzymatic determination of total serum cholesterol. Clin. Chem., 20:470 – 475
- Allain, M. R (2004).** Polyphenolic flavonoids inhibit macrophage-mediated oxidation of LDL-c and attenuate atherogenesis, *Atherosclerosis*, 137: 545.
- Bligh, E. G. and Dyer, W. J. (1959).** A rapid method of total lipid extraction and purification. *Can. J. of Biochem. And Physiol.* 37: 911.
- Bohmer, H.B.U. M. (1971).** Micro-determination of creatinine. *Clin. Chem. Acta*, 32: 81-85.
- Burstein, M. (1970).** HDL cholesterol determination after Separation high-density lipoprotein-lipid Res., 11: 583.
- Carleton,H .(1979).** In "Histological Techniques" ,4th Edition, London, Oxford University Press. NewYork, USA.
- Chau, C. F.; Huang, Y. L. and Lin, C. Y. (2004).** Investigation of the cholesterol-lowering action of insoluble fibre derived from the peel of *Citrus sinensis* L. cv. Liucheng. *Food Chemistry*. 87(3):361-366.
- Falholt, K.; Lund, B. and Falholt, W. (1973).** Determination of free fatty acids. *Clin.Chem. Acta*, 49,105.
- Farias ,R.A.F .;Neto, M.F.O .;, Viana, G.S.B.and Rao, V.S.N.I.(1996).** Effects of Croton Cajucara extract on serum lipids of rats fed a high fat diet . *Phytother Res* 10 : 697 - 699 .
- Fayed, A. M.; Azoz, A. A.; Zedan, A. H. and Basyony, M.(2012).**Effect of pomegranate peel as antioxidant supplementation on digestibility, blood biochemical and rabbit semen quality.*Egyptian Journal of Nutrition and Feeds*; 15(2):323-334.
- Fossatip and Prancipel (1982).** Triglycerides determination after enzymatic hydrolysis.*Clin Chem* 28: 2077.
- Neyrinck, A. M.; Hee, V. F. Van; Bindels, L. B.; Backer, F. de; Cani, P. D. and Delzenne, N.M.(2013).**Polyphenol-rich extract of pomegranate peel alleviates tissue inflammation and hypercholesterolaemia in high-fat diet-induced obese mice: potential implication of the gut microbiota. *British Journal of Nutrition*;.109(5):802-809.

- Oluremi, O. I. A.; Mou, P. M. and Adenkola, A. Y.(2008).** Effect of fermentation of sweet orange (*Citrus sinensis*) fruit peel on its maize replacement value in broiler diet. *Livestock Research for Rural Development*. 20(2):20020.
- Patton, C. and Crouch, S. R. (1977).** Determination of urea. *Anal. Chem.* 149:464-469.
- Prakash, C. V. S. and Prakash, I. (2011):** Preexisting diabetes and gestational diabetes mellitus among a racially/ ethnically diverse. *Int. J. Res. Chem. Environ*, 1, 1-8.
- Reitman, S. and Frankel, S. (1957).** A color metric method for the determination of serum glutamic oxaloacetic and glutamic pyruvic transaminases. *Am. J. Clin. Path*, 28: 56 – 63.
- Snedecor, G. W. and Cochran, W. G. (1972).**Statistical Methods 6th Ed. The Iowa State University Press. Ames. IA
- Yokozawa,T.;Ishida ,A .; Cho, E. J.and Nakagawa, T. (2003):** The effects of Coptidishrizoma extract on a hypercholesterolemia animal model . *Phytomedicine*10 : 17 – 22
- Zhou Zhong; Jiao, Y.; Lian, Z.; Han, C.; Yang, W.; WenNing, F.; DanLu, L.; Lei, C.; JunHong, L. and Guan, Y.(2012).**The influence of pomegranate peel extract on blood glucose and blood lipids of rats. *Journal of Xinjiang Medical University*;35 (5):570-574.
- Zolliner and Eberhagal. (1965).** Determination of phospholipids. *Ann.Clin. Biochem.* 6: 538 – 544.