

## Study of the effect of ginger and turmeric on osteoporosis in female rats

Eman G. Mohamed<sup>1\*</sup>, Zenab M. Mosa<sup>1</sup>, Samah M. Esmail<sup>1</sup> Adel Bakeer Khloussy<sup>2</sup>, Sahar O. Ahmed<sup>3</sup> and Naglaa A. Abdelkader<sup>4</sup>

1-Nutrition and Food Sciences, Home Economics Dept., Fac. of Education. Ain-Shams

2- Pathology Dept., Fac. of Veterinary, Cairo University.

3- Food Technology Research Institute.

4- Surgery, Anaesthesiology and Radiology Dept., Fac. of Veterinary, Cairo University

\*Email; eman.gamal.mohamed.gs@sedu.asu.edu.eg

**Received: Dec. 12, 2020; Accepted: Feb. 28, 2021; Available online: March 10, 2021**

### ABSTRACT

Osteoarthritis is the most common form of arthritis, involving inflammation and major structural changes of the joint, causing pain and functional disability. Pain and stiffness, particularly after exercise, are the major symptoms, resulting in considerable impact on ability to perform activities of daily living. There is discordance between symptoms and radiographic changes, with some sufferers not experiencing symptoms, but showing osteoarthritic changes on X-ray. The present study was performed to examine the effect of ginger and turmeric consumption on liver function (ALT, AST), phosphorus, total calcium, ionized calcium, x-ray and histopathology on osteoporosis rats induced by prednisone acetate at a dose of 4 mg / kg bw three times a week for three weeks. On the other hand, the chemical constituent's moisture, protein, fat, crude fibre, total digestible nutrients, ash, carbohydrate, phosphorus, calcium was determined for the tested ginger and turmeric. In addition to, volatile compounds and analysis of phytochemicals was determined for the tested ginger and turmeric.

This work was carried out on 48 non-pregnant female albino rats (age 6 to 8 weeks and about 160 to 210g body weight) classified into two main groups. The first main group (6) fed on basal diet and the second main group (42 rats) injected with prednisone acetate at a dose of 4 mg / kg bw three times a week for three weeks to cause osteoporosis and divided into seven subgroups such as each group consists of (6rats). Then fed on basal diet containing 10% -15% ginger, 10% -15% turmeric and 10% -15% ginger and turmeric. Results revealed that all osteoporosis groups administered with different levels of ginger and turmeric (10-15%) had significant decrease liver function (ALT, AST), phosphorus, total calcium, ionized calcium comparing with the positive control group. On the other hand, x-ray and histopathology of the positive control group after two months revealed bone loss of different part such as fibula, tibia and femur in addition to bone demineralization and femoral fracture and fibula bone trabeculae showed dystrophy and resorption and osteoporosis. These findings revealed that ginger and turmeric treatment attenuated and treated degrees to osteoporosis in compare to positive control group.

**Keywords:** Medicinal Herbs, Osteoporosis, Ginger, Turmeric Rhizome, Phytochemicals Analysis, Biochemical Analysis.

### INTRODUCTION

Osteoarthritis (OA) is the most common form of arthritis, involving

inflammation and major structural changes of the joint, causing pain and functional disability. Pain and stiffness, particularly

after exercise, are the major symptoms, resulting in considerable impact on ability to perform activities of daily living. There is discordance between symptoms and radiographic changes, with some sufferers not experiencing symptoms, but showing osteoarthritic changes on X-ray. It is known that OA is more common in women than in men, and the prevalence of OA increases steeply with age (Busija *et al.*, 2010). Osteoporosis is worldwide defined as a systemic skeletal disease characterized by low bone density and micro architectural deterioration of bone tissue, which leads to increased bone fragility and risk of fracture (Genant *et al.*, 1999; Anbinder *et al.*, 2006). In healthy rats, both simvastatin and fenofibrate treatment showed a negative effect on the trabecular bone located at the level of femoral diaphysis. These results are consistent with other studies which concluded that to a certain extent, statins inhibit bone resorption and promote bone formation (Chang *et al.*, 2011; Gradosova *et al.*, 2011). Glucocorticoids act directly on bone cells and one of their principal actions is to reduce osteoblasts function and number by apoptosis (Chang *et al.*, 2009). The Bax expression by osteoblasts increase in the glucocorticoid-induced osteoporosis (GIO) as showed by (Lucinda *et al.*, 2013). It's well known that apoptosis is regulated by an intrinsic process involving activation of genes that can promote cell death (Bras *et al.*, 2005).

Ginger (*Zingiber officinale* Roscoe, Zingiberaceae) is widely used around the world in foods as a spice. For centuries, it has been an important ingredient in Chinese .Ayurvedic and Tibb-Unani herbal medicines for the treatment of catarrh, rheumatism, nervous diseases, gingivitis toothache, asthma, stroke, constipation and diabetes (Awang, 1992; Wang and Wang, 2005; Tapsell *et al.*, 2006). The constituents of ginger are numerous and vary depending

on the place of origin and whether the rhizomes are fresh or dry. The odor of ginger depends mainly on its volatile oil, the yield of which varies from 1% to 3%. Over 50 components of the oil have been characterized and these are mainly monoterpenoids. Some of the oil components are converted into less odor-defining compounds on drying (Langner *et al.*, 1998; Evans, 2004). The pungency of fresh ginger is due primarily to the gingerols, which are a homologous series of phenols. Ginger and compounds isolated there from include immuno-modulatory, anti-tumorigenic, anti-inflammatory, anti-apoptotic, anti-hyperglycemic, anti-lipidemic and anti-emetic actions. Ginger is a strong anti-oxidant substance and may either mitigate or prevent generation of free radicals. It is considered a safe herbal medicine with only few and insignificant adverse side effects (Badreldin *et al.*, 2008)

Turmeric has anti-inflammatory (Jurenka, 2009) and anti-cancer (Ravindran *et al.*, 2009) properties, which have been mainly attributed to curcumin, a diarylheptanoid compound. However, turmeric oil containing ar-turmerone, turmerone and curone showed antioxidant effects and may provide an explanation for their antimutagenic action (Jayaprakasha *et al.*, 2002). This turmeric oil also has antibacterial activity (Negi *et al.*, 1999). Turmeric is a rich source of various volatile oils, including turmerone, atlantone, zingiberone, and other constituents such as sugars, proteins, resins, lignin, salts, resins. The root contains 10% resin which is a glucoside (Dulbecco *et al.*, 2014). Phytochemical studies of turmeric have shown the presence of curcumin, demethoxy curcumin, methoxy curcumin, zingiberene, curcumenol, curcumol, eugenol, tetrahydrocurcumin, triethylcurcumin, turmerin, turmerones, and turmeronols. Turmeric is made up three

## Study of the effect of ginger and turmeric on osteoporosis in female rats

curcuminoids: 75% diferuloyl methane (also called curcumin), 16% demethoxy curcumin, and 8% bisdemethoxy curcumin. The present data revealed that most of the therapeutic effects of Turmeric are due to presence of curcumin. Curcumin is also the component that gives turmeric its yellow colour. Curcumin, a polyphenol compound with a molecular formula  $C_{21}H_{20}O_6$ , can exist in two tautomeric forms: a keto form (an aldehyde) and a stable enol form (an alcohol) (Balaji and Chempakam, 2010).

Based on ginger and turmeric data from white ginger (rhizome root and leaf), yellow ginger (rhizome, root and leaf) and turmeric (rhizome and leaf released to the NCBI database), we selected putative mono- and sesquiterpene synthases and cloned and expressed them with GPP and FPP as substrates in *E. coli* or yeast. Although many of these enzymes were found to be insoluble when expressed in these systems, we were able to identify the functions for some of them. We also analyzed why some that are paralogs produce different products even though their sequences are very similar according to protein structural modeling. Both ginger and turmeric produce  $\alpha$ -zingiberene and  $\beta$ -sesquiphellandrene. However, only turmeric synthesizes  $\alpha$ -turmerone,  $\beta$ -turmerone, which is also described.  $\alpha$ -asturmerone and  $\alpha$ -curlone, respectively, in some papers (Hiserodt *et al.*, 1996). Curcuma-containing products consistently demonstrated statistically significant improvement in osteoarthritis-related endpoints compared with placebo, with one exception. When compared with active control, curcuma-containing products were similar to nonsteroidal anti-inflammatory drugs, and potentially to glucosamine (Kimberly *et al.*, 2017). The research aimed at study of effect of ginger and curcumin on osteoporosis in rats.

## MATERIALS AND METHODS

### Materials:

The fresh ginger and turmeric rhizomes were purchased from herbal market, the ginger and turmeric were dried and powdered in the air temperature. The betamethasone (4mg/1kg bw) three times a week for three weeks was purchased from Pharmaceutical industries El Obour City- in Egypt, Dexaglobe Ampoules.

### Biological experiment

#### Animal, housing and diets:

48 non-pregnant female albino rats (age 6 to 8 weeks and about 160 to 210g body weight) were obtained from the animal house in Agriculture Research Center, Cairo, Egypt were housed (6 rats per cage) in the animal room under controlled lighting (12-hour light:12-hour darkness) and temperature ( $20^{\circ}\text{C} \pm 2^{\circ}\text{C}$ ) conditions and had free access to laboratory food and tap water. They were kept under normal healthy conditions and fed on the commercial diet (Table 1) without any treatment for one week for acclimatization. Experimental diet (Table 2) and water were offered ad libitum all over the experimental period. The first group of rats, the control (-) fed on commercial diet for 8 weeks (total period of experimental). The remained 42 rats were injected with beta methasone at a dose of 4 mg / kg bw three time a week for three weeks to cause osteoporosis then divided to 7 groups of six rats each (Liao *et al.*, 2003). The second group after injected fed on commercial diet (control +). The third and fourth groups after injected fed on 10 and 15 % of ginger, respectively. Fifth and sixth groups after injected fed on 10 and 15 % of turmeric, respectively. Seventh and eighth groups after injected fed on mixture of 10 and 15% ginger and turmeric, respectively.

**Table (1): Composition of commercial diet.**

Ingredients	Percentage %
Protein: [soy flour meal+ sun flower meal + gluten]	21.00
Fat	03.26
Crude fibre	03.29
DL. Methionine	00.40
Vitamins mixed	01.00
Minerals mixed	04.00
Carbohydrates	67.05

**Table (2). Composition of Experimental diet as follows:**

Groups	Experimental diets
<b>Frist</b>	Commercial diet (control (-) group)
<b>Second</b>	Beta methasone + Commercial diet (control (+) group)
<b>Third</b>	Beta methasone + commercial diet contain 10% of the ginger.
<b>Fourth</b>	Beta methasone + commercial diet contain 15% of the ginger.
<b>Fifth</b>	Beta methasone + commercial diet contain 10% of the turmeric.
<b>Sixth</b>	Beta methasone + commercial diet contain 15% of the turmeric
<b>Seventh</b>	Beta methasone + commercial diet contain10% of ginger and turmeric
<b>Eighth</b>	Beta methasone + commercial diet contain15% of ginger and turmeric
<b>Nineth:</b>	were injected with Beta methasone at a dose of 4 mg / kg bw three time a week to three a week then slaughtering

At the end of the experiment after 8 weeks the rats mended before slaughtering and all the blood done from each rat separately after anesthesia and conduct a blood centrifuge to get the serum. Blood samples were withdrawn from orbital plexus venous by using fine capillary glass tubes. Blood samples were collected into plain tubes without anticoagulant and allowed to clot, Blood samples were centrifuged at 3000 rpm for 10 min at 4°C,

to obtain clear serum. Blood samples were centrifuged at 3000 rpm for 10 min at 4°C, to obtain clear serum. Serum was frozen at -18°C until analyzed. The animals were anesthetized with ether and sacrificed. Liver, kidney, and femoral bone will be separated from each rat and will be weighed to calculate the percentage of increase in organ weight. These organs were weighed and then kept until histological investigations.

## Methods:

### Chemical analysis

Moisture, protein, fat, crude fibre, total digestible nutrients and ash were determined according to the method of AOAC (2007). All determinations were done in triplicate. Phosphorous, calcium, atomic absorption spectrophotometer according to the method of AOAC (1998). All determinations were done in triplicate.

The carbohydrate contents were tested quantitatively by the phenol-sulphuric acid method (Chaplin and Kennedy, 1986).

The absorbance was measured at a wavelength of 490 nm using UV-Vis Shimadzu Spectrophotometer (UV-1601 PC).

### Volatile compounds

#### Hydro distillation (Extraction of essential oil)

About 100 g of cleaned and dried plant material was powdered using metal mortar and placed in a round bottom flask fitted with condenser hydro distilled for about 3hrs at atmospheric pressure and constant temperature. The strongly aromatic oil was separated from the water layer using

## Study of the effect of ginger and turmeric on osteoporosis in female rats

diethyl ether and the solvent was removed by sodium sulfate anhydrous and concentrated by rotary evaporator.

### Phytochemicals Analysis:

Phytochemical analysis for qualitative detection of alkaloids, tannins, saponins, flavonoids and phenol was performed on the powder of ginger and turmeric rhizome as follows:

Total tannins content in the lyophilized plant extract was determined by a modified method of Polshettiwar *et al.*, (2007). The total phenolic content was determined using Folin-Ciocalteu reagent (Mc-Donald *et al.*, 2001). The total flavonoids in the beverage were determined using aluminium chloride colorimetric method (El-Olemy *et al.*, 1994). Alkaloids and Saponins were determined using method of Oloyed (2005).

### Histopathology Technique

Autopsy samples were taken from the liver, kidney and femur bone of rats in different groups and fixed in 10% formal saline for twenty four hours. The bone was decalcified by formic acid. Washing was done in tap water then serial dilutions of alcohol (methyl, ethyl and absolute ethyl) were used for dehydration. Specimens were cleared in xylene and embedded in paraffin at 56 degree in hot air oven for twenty four hours. Paraffin bees wax tissue blocks were prepared for sectioning at 4 microns thickness by slide microtome. The obtained tissue sections were collected on glass slides, deparaffinized, stained by hematoxylin and eosin stain for routine examination through the light electric microscope (Banchroft *et al.*, 1996).

### Scanning X-ray

Determination the right femurs and LV5 of rats were wrapped with saline-saturated gauze to maintain their moisture

and stored at 20C. After thawed at room temperature, the bones were moisturized by soaking them in saline solution with the residual muscle removed. The whole femoral BMD was scanned with Prodigy Dual-Energy X-ray Absorptiometry scanner (GE Healthcare, Little Chalfont, UK) to measure the bone mineral content (BMC, g/cm<sup>2</sup>) and bone area (BA, cm<sup>2</sup>). The BMD was calculated as BMC/BA (Bagi *et al.*, 2011).

### Biological Determination

Biological evaluation of the different tested diets was carried by determination of body weight gain% (BWG %) and organs weight/body weight% according to Chapman *et al.* (1959).  $BWG\% = [(Final\ weight - Initial\ weight) / (Initial\ weight)] \times 100$   
 $Organ\ weight / body\ weight\ \% = (Organ\ weight / Final\ weight) \times 100$

### Biochemical analysis

Blood samples were withdrawn from orbital plexus venous by using fine capillary glass tubes, placed in centrifuge tubes without anticoagulant and allowed to clot. After the serum prepared by centrifugation (3000 rpm for 15 min), serum samples were analyzed by biodiagnostic kits:

- Alanine aminotransferase (ALT) activities were determined colorimetrically using spectrophotometer (model DU 4700) at 505 nm according to the method of Reitman and Frankel (1975).
- Aspartate Aminotransferase (AST) activities were determined colorimetrically using spectrophotometer (model DU 4700) at 540 nm according to the method of Reitman and Frankel (1975).
- Phosphorus, inorganic and calcium O-cpcactivities were determined colorimetrically using spectrophotometer at

340 nm according to the method of Young (1990).

- Calcium O-cpcactivities were determined calorimetrically using spectrophotometer (model DU 4700) at 540 nm according to the method of Young (1990).

## RESULTS AND DISCUSSION

According to the WHO Osteoporosis is a disease characterized by low bone mass and microarchitectural deterioration of bone tissues, leading to enhanced fragility and consequent increase in fracture risk that results in fractures with minimal trauma. There is imbalance between bone formation (osteoblastic activity) and bone resorption process (osteoclastic activity) due to various causes such as deficiency of estrogen hormone as in post-menopausal osteoporosis, aging and oxidative stress (Yan Zhang *et al.*, 2007). Ginger (*Zingiber officinale* Roscoe) is one of the most commonly consumed dietary condiments in the world. The main active phytochemicals present in ginger are gingerols, shogaols and paradols, and they have strong antioxidant and chemopreventive properties (Halvorsen *et al.*, 2002). The medicinal, chemical and pharmacological properties of ginger has been extensively reviewed (Ali *et al.*., 2008). Ginger extracts have been extensively studied for a broad range of biological activities including antibacterial, anticonvulsant, analgesic, antiulcer, gastric antisecretory, antitumor, antifungal, antispasmodic, antithrombotic, hypocholesterolemic, antiallergic, antiserotonergic, anticholinergic and other beneficial activities (Tchombé *et al.*., 2012).

Turmeric (*Curcuma longa*) is a dietary spice belonging to the family zingiberaceae. It is a coloring and flavouring agent in foods, and has been reported to possess antioxidant properties both in vitro and animal studies. Aqueous extracts of

turmeric showed antioxidant and antimicrobial activity due to the presence of curcumin (5%), a polyphenolic compound. It is known that the phenolic character of curcumin is responsible for its anti-oxidant properties (Varunraj *et al.*, 2011). Fresh root contains good levels of vitamin-C. Other phytochemicals in turmeric include tumerone, zingiberene, cineole, d-phellandrene, d-sabinene, borneol and other curcuminoids. The majority of the phytochemicals found in turmeric occur in the volatile oil that makes up 7 percent of its weight. Dry rhizomes yield 5.8% essential oil including sesquiterpene (e.g. Zingiberene), sesquiterpene alcohols and ketones, and monoterpenes. Fresh turmeric contains 0.24% oil containing zingiberene. The most Curcumin is a known bacteriostatic agent whereas the essential oil of turmeric is bactericidal and fungistatic. The active principle, curcumin is known for its inhibitory action on micro-organisms (Niamsa and Sittiwet 2009).

## Chemical composition

Results in Table (3) indicated that the chemical composition of ginger was 9.25%, 4.64%, 70.71%, 9.1%, 6.3%, 5.89% and 67.60% for protein, fat, Carbohydrates, moistures, ash, crud fiber and TDN respectively. On the other hand, the values of protein, fat, Carbohydrates, moistures, ash, crud fiber and TDN in turmeric were 7.56%, 3.73%, 72.81%, 12%, 3.9%, 2.95% and 69.32% respectively. The mean values of calcium and phosphorous were in ginger (0.30% and 0.21) while calcium and phosphorous were in turmeric (0.29% and 0.24%). Many studies have proved that ginger is endowed with strong antioxidant (Nirmala *et al.*, 2008; Nirmala *et al.*, 2012). Antigenotoxic, antimutagenic and anticarcinogenic properties both in vitro and in vivo studies Powdered ginger rhizome contains 3.6% fatty oil, 9% protein, 60-70%

### Study of the effect of ginger and turmeric on osteoporosis in female rats

carbohydrates, 3.8% crude fiber, 8% ash, 9-12% water and other terpenes and terpenoids. Fresh ginger contains 80.9% moisture, 23% protein, 0.9% fat, 1.2% minerals, 2.4% fiber, and 12.3% carbohydrates. Ginger has been shown to be

effective against the growth of both gram-positive and gram-negative bacteria including *Escherichia coli*, *Proteus vulgaris*, *Salmonella typhi*, *Staphylococcus aureus* and *Streptococcus viridians* (Mascolo *et al.*, 1989).

**Table (3): The Chemical composition of Ginger and Turmeric**

Chemical composition %	Samples	
	Ginger	Turmeric
Protein	9.25	7.56
Fat	4.64	3.73
Carbohydrates	70.71	72.81
Moistures	9.1	12
Ash	6.3	3.9
Crude Fiber	5.89	2.95
TDN	67.60	69.32
Calcium	0.30	0.29
Phosphorous	0.21	0.24

#### Phytochemicals

Phytochemicals are component of plant foods play an important role in the treatment of diseases and as a major. The type and amount of various phytochemical in ginger and Turmeric presented in Table (4). The obtained data showed that ginger is a rich source of alkaloids 9.76% and Tannins 2.59% as well as Saponins 0.38% While Flavonoids 4.12 % and total phenolic 0.13% addition of ginger showed high significant in Alkaloids in all phytochemicals then Flavonoids. The date also showed that Turmeric is a rich source of alkaloids 4.26% and Tannins 2.03% as well as Saponins 6.17% While Flavonoids 2.31% and total phenolic 3.05% addition of Turmeric showed high significant in Saponins in all phytochemicals then Alkaloids.

Phytochemicals are non-nutritive plant chemicals that have protective or disease preventive properties, they are found generally in plants. The Phytochemical screening in (Tijjani *et al.*, 2009) study were agree with our result, who showed that all

leaves contain phenolics, Tannins, Alkaloids, Saponins, Flavonoids, Steroid and does not contain phylobatanin, and triperthenes (Deokar *et al.*, 2016). The findings revealed that the knowledge of the antimicrobial activity of the extracts obtained from ginger can be very useful and can be applied in different areas of research such as the pharmaceutical and food industries Phytochemical constituents such as steroids, alkaloids, flavonoids, tannins, phenol and several other aromatic compounds are secondary metabolites of plants that serve a defense mechanism against predation by many microorganisms, insects and herbivores. These secondary metabolites exert antimicrobial activity through different mechanisms. The alkaloids contain in plants are used in medicine as anesthetic agents. Ginger rhizome extract and their components can be used as alternative and effective novel therapeutic strategy.

Turmeric (*Curcuma longa*) is a dietary spice coloring and flavouring agent in foods and has been reported to possess

antioxidant properties both in vitro and animal studies. Aqueous extracts of turmeric showed antioxidant and antimicrobial activity due to the presence of curcumin (5%), a polyphenolic compound. It is known that the phenolic character of curcumin is responsible for its anti-oxidant properties (Varunraj *et al.*, 2011). Fresh root contains good phytochemicals in turmeric include tumerone, zingiberene, cineole d-phellandrene, d-sabinene, borneol and other curcuminoids. The majority of the phytochemicals found in turmeric occur in

the volatile oil that makes up 7 percent of its weight. Dry rhizomes yield 5.8% essential oil including. Fresh turmeric contains 0.24% oil containing zingiberene. The most significant curcuminoid is curcumin. It has been reported that turmeric has an antimutagenic effect on bacteria in vitro. Curcumin is a known bacteriostatic agent whereas the essential oil of turmeric is bactericidal and fungistatic. The active principle curcumin is known for its inhibitory action on micro-organisms (Virendra *et al.*, 2013).

**Table (4): Phytochemical analyses of Ginger and Turmeric.**

Phytochemicals (%)	Ginger	Turmeric
Alkaloids	9.76±0.32	4.26±0.28
Tannins	2.59±0.08	2.03±0.19
Saponins	0.38±0.04	6.17±0.25
Flavonoids	4.12±0.17	2.31±0.16
Phenols	0.13±0.05	3.05±0.29

### Volatile compounds

The present data given in Tables (5 & 6) indicated the volatile compounds of ginger and turmeric essential oil. Volatile compounds of ginger essential oil (Concentration) as well as values are expressed as relative area percentage while (KI) Kovat index on DB5 were analyzed by compounds identified by GC-MS (MS) and (KI) of standard compounds run under similar GCMS conditions. Recorded the 29 volatiles were identified in Concentration the most abundant identified volatile compounds were Zingiberene which represent 41.05% then  $\alpha$ -Cubebene, which represent 21.31% respectively. But (KI) recorded the best result in  $\beta$ -Curcumene then  $\beta$ -Bisabolene which represent 1519, 1514 respectively. Also, Heptanol (0.03 %) was found in very low amounts. Volatile compounds of turmeric essential oil (Concentration) as well as values are expressed as relative area percentage while (KI) Kovat index on DB5 were analyzed by compounds identified by GC-MS because it

was recorded the best result in sensory evaluation. A total of 17 volatiles were identified in Concentration the most abundant identified volatile compounds were Tumerone which represent 43.87% then Zingiberenol, which represent 14.69% respectively. While (KI) recorded the Xanthorhizol then Curcumenol which represent 1748, 1731 respectively. Also Eudesmol (0.43%) was found in very low amounts. Shaguftanaz *et al.* (2010) indicated that these oils contain volatile substances which are terpenes and their oxygenated derivatives usually known as camphor. The chemical constituents of turmeric rhizomes include volatiles (ar-tumerone, zingiberene, tumerone and curlone) and non-volatiles which are colorings agents and rich source of phenolics. The aroma of the turmeric is curcumin and its analogues account for its bright yellow color. El-Baroty *et al.* (2010) indicated that ginger is a characterized oil (GEO) with high content of sesquiterpene hydrocarbons, including  $\beta$ -



### Study of the effect of ginger and turmeric on osteoporosis in female rats

sesquiphellandrene (27.16%), caryophyllene (15.29) % zingiberene (13.97%),  $\alpha$ -farnesene (10.52%) and ar-curcumin (6.62%). Fijelu Frank *et al.* (2013) found that the major components of essential oil

from *Curcuma longa* analysed by GC/MS were ar-turmerone (33.2%),  $\alpha$ -turmerone (23.5%) and  $\beta$ -turmerone (22.7%). The antifungal activities of the oil were studied with regard to *Aspergillus flavus* growth inhibition.

Table (5). Volatile compounds of ginger essential oil

Volatile compounds	KI <sup>a</sup>	Concentration <sup>b</sup>	Identification method <sup>c</sup>
Heptanol	897	0.03	MS, KI, SD
$\alpha$ -Pinene	936	0.88	MS, KI
Camphene	941	3.28	MS, KI
2-Methyl nonane	967	0.63	MS, KI, SD
Myrcene	971	1.82	MS, KI
Pinene	974	0.05	MS, KI
$\alpha$ -Phellandrene	982	0.05	MS, KI
Limonene	1013	0.04	MS, KI, SD
$\beta$ -Phellandrene	1017	4.43	MS, KI
1,8-ceneole	1031	2.16	MS, KI
$\alpha$ -Terpinolene	1062	0.08	MS, K
n-Nonenal	1129	0.58	MS, KI, SD
2-Methyl undecane	1165	0.16	MS, KI
3-Methyl butanol	1198	18.94	MS, KI
$\alpha$ -Cubebene	1345	21.31	MS, KI, SD
p-Menth-1-en-8-ol acetate	1349	1.25	MS, KI
Geranyl acetate	1381	0.07	MS, KI
Methyl eugenol	1402	0.06	MS, KI
Geranyl propionate	1428	0.27	MS, KI
$\alpha$ -Farnesene	1432	0.04	MS, KI, SD
$\gamma$ -Elemene	1439	0.04	MS, KI
Neryl acetone	1442	0.27	MS, KI
Germacrene D	1457	1.90	MS, KI
Zingiberene	1492	41.05	MS, KI
Valencene	1498	0.05	MS, KI
Citronellyl n-butyrate	1503	0.04	MS, KI
$\alpha$ -Bisabolene	1509	0.09	MS, KI
$\beta$ -Bisabolene	1514	0.05	MS, K
$\beta$ -Curcumene	1519	0.17	MS, KI

<sup>a</sup>: Kovat indices; <sup>b</sup>: Values are expressed as relative area percentage; <sup>c</sup>: compounds identified by GC-MS (MS) and / or Kovat index on DB5 (KI) and / or by comparison of MS and KI of standard compounds run under similar GCMS conditions.

Table (6). Volatile compounds of turmeric essential oil

Volatile compounds	KI <sup>a</sup>	Concentration <sup>b</sup>	Identification method <sup>c</sup>
Camphene	958	1.26	MS, KI, SD
-Fenchene	961	1.24	MS, KI
Pinene	976	1.69	MS, KI
$\alpha$ -phellanderene	983	1.82	MS, KI, SD
3-Thujene	992	3.03	MS, KI
Zingiberenol	1612	14.69	MS, KI
Turmerone	1629	8.00	MS, KI
Tumerone	1651	43.87	MS, KI, SD
Eudesmol	1658	0.43	MS, KI
Atlantone	1667	1.12	MS, KI
Eudesmol	1669	0.79	MS, KI
Curcumenone	1672	3.55	MS, KI, SD
Germacrone	1688	5.04	MS, KI
ZZ-Farnesol	1691	0.60	MS, KI
ZE-Farnesol	1702	2.90	MS, KI, SD
Curcumenol	1731	9.19	MS, KI
Xanthorhizol	1748	0.77	MS, KI

<sup>a</sup>: Kovat indices; <sup>b</sup>: Values are expressed as relative area percentage; <sup>c</sup>: compounds identified by GC-MS (MS) and / or Kovat index on DB5 (KI) and / or by comparison of MS and KI of standard compounds run under similar GCMS conditions.

### Biological Determination

Data in Table (7) indicated that the two groups of rats fed on 10% and 15% turmeric and ginger, respectively showed increase in their body weight gain comparing with the positive control group. The body weight gain was higher in group (4) with level 15% ginger (57.261±8.733), while it was lower in group (5) that fed on basal diet of 10% turmeric (30.077±10.59) comparing with the positive control group. This result was in agreement with that obtained by Saber Sakr *et al.* (2011).

Many studies were carried out on ginger and its pungent constituents, fresh and dried rhizome. Among the pharmacological effects demonstrated is anti-platelet, antioxidant, anti-tumour, anti-rhinoviral, anti-hepatotoxicity and anti arthritic effect (Fisher-Rasmussen *et al.*, 1991; Sharma *et al.*, 1994; Kamtchouing *et al.*, 2002). Ginger was found to have hypocholesterolaemic effects and cause decrease in body weight, blood glucose, serum total cholesterol and serum alkaline phosphatase in adult male rats.

Table (7): Effect of ginger and turmeric on weight gains of rats suffering from osteoporosis.

Groups	Parameters		
	Final weight (g)	Initial weight (g)	body weight gain %
<b>Group (1):</b> negative control	221.833 <sup>c</sup> ±110.241	177.677 <sup>a</sup> ±13.571	24.866 <sup>c</sup> ±7.391
<b>Group (2):</b> positive control	246.53 <sup>b</sup> ±17.833	177.333 <sup>a</sup> ±12.711	39.011 <sup>b</sup> ±7.192
<b>Group (3):</b> 10% ginger	262.833 <sup>a</sup> ±18.311	177.333 <sup>a</sup> ±12.471	48.211 <sup>ab</sup> ±9.211
<b>Group(4):</b> 15% ginger	277.833 <sup>a</sup> ±22.162	176.672 <sup>b</sup> ±11.691	57.261 <sup>a</sup> ±8.733
<b>Group (5):</b> 10% turmeric	230 <sup>c</sup> ±114.291	176.833 <sup>ab</sup> ±9.831	30.077 <sup>c</sup> ±10.59
<b>Group (6):</b> 15% turmeric	246 <sup>b</sup> ±122.652	176.831 <sup>ab</sup> ±10.311	39.112 <sup>b</sup> ±11.377
<b>Group (7):</b> 10% ginger and turmeric	238 <sup>bc</sup> ±117.281	177 <sup>a</sup> ±8.292	34.461 <sup>bc</sup> ±11.611
<b>Group (8):</b> 15% ginger and turmeric	272.172 <sup>a</sup> ±14.591	176.833 <sup>ab</sup> ±8.492	53.911 <sup>a</sup> ±12.477
<b>ANOVA ( F )</b>	<b>0.305</b>	<b>0.119</b>	<b>0.297</b>
<b>Sig.</b>	*	*	*

- Values are expressed as mean ± SD.

- Significant at p<0.05 using one way ANOVA test.

- Values which have different letters in each column differ significantly, while those with have similar or partially are not significant.

### Study of the effect of ginger and turmeric on osteoporosis in female rats

The results in Table (8) indicated the effect of ginger and turmeric on relative organs weight of rats suffering from osteoporosis. The mean values of relative weights of liver and kidney in positive control group was lower than the all experimental groups. But the mean values of liver and kidney for rats in group (6) were higher than those of the positive control group (8.491±1.552g, 5.342±0.591g and

1.728±0.165g, 0.957±0.746g, respectively). On the other hand, the mean values of relative weights of femoral bones in positive control group was similar to group (6) (3.917±0.493g and 3.962±1.162g) while the positive control group in relative weights of femoral bones was lower than group (8) (3.917±0.493g and 6.72±1.101g) the results agreed with that obtained by (Stanley Iheanacho *et al.*, 2017).

Table (8): Effect of ginger and turmeric on relative organs weight of rats suffering from osteoporosis.

Groups	Parameters					
	Relative weights of liver(g)	OW/BWG	Relative weights of kidney(g)	OW/ BWG	Relative weights of femoral bones (g)	OW/ BWG
<b>Group (1):</b> negative control	5.881 <sup>c</sup> ±0.551	2.648 <sup>b</sup> ±4.837	1.255 <sup>bc</sup> ±0.16	0.565 <sup>b</sup> ±5.115	3.57 <sup>c</sup> ±0.828	1.609 <sup>b</sup> ±4.641
<b>Group (2):</b> positive control	5.342 <sup>c</sup> ±0.591	2.164 <sup>c</sup> ±4.668	0.957 <sup>c</sup> ±0.746	0.388 <sup>c</sup> ±4.558	3.917 <sup>bc</sup> ±0.493	1.589 <sup>b</sup> ±4.737
<b>Group (3):</b> 10% ginger	5.766 <sup>c</sup> ±1.011	2.192 <sup>c</sup> ±5.798	1.392 <sup>b</sup> ±0.235	0.529 <sup>b</sup> ±6.347	4.462 <sup>b</sup> ±0.981	1.698 <sup>b</sup> ±5.819
<b>Group(4):</b> 15% ginger	6.811 <sup>ab</sup> ±0.462	2.449 <sup>b</sup> ±5.848	1.397 <sup>b</sup> ±0.181	0.503 <sup>b</sup> ±6.047	4.875 <sup>b</sup> ±0.666	1.755 <sup>b</sup> ±5.704
<b>Group (5):</b> 10% turmeric	6.471 <sup>b</sup> ±0.952	2.814 <sup>ab</sup> ±6.81	1.664 <sup>a</sup> ±0.233	0.723 <sup>a</sup> ±7.324	6.718 <sup>a</sup> ±0.582	2.921 <sup>a</sup> ±7.077
<b>Group (6):</b> 15% turmeric	8.491 <sup>a</sup> ±1.552	3.450 <sup>a</sup> ±6.947	1.728 <sup>a</sup> ±0.165	0.702 <sup>a</sup> ±7.928	3.962 <sup>bc</sup> ±1.162	1.611 <sup>b</sup> ±7.223
<b>Group (7):</b> 10% ginger and turmeric	6.681 <sup>b</sup> ±0.441	2.808 <sup>ab</sup> ±7.89	1.396 <sup>b</sup> ±0.216	0.587 <sup>ab</sup> ±8.057	6.628 <sup>a</sup> ±0.227	2.785 <sup>a</sup> ±8.049
<b>Group (8):</b> 15% ginger and turmeric	6.592 <sup>b</sup> ±0.391	2.424 <sup>b</sup> ±8.546	1.635 <sup>a</sup> ±0.173	0.601 <sup>a</sup> ±8.700	6.72 <sup>a</sup> ±1.101	2.469 <sup>ab</sup> ±8.044
<b>ANOVA ( F)</b>	<b>0.049</b>	<b>0.436</b>	<b>0.169</b>	<b>0.354</b>	<b>0.017</b>	<b>0.053</b>
<b>Sig.</b>	**	*	*	*	**	**

- Values are expressed as mean ± SD.

- Significant at p<0.05 using one way ANOVA test.

- Values which have different letters in each column differ significantly, while those with have similar or partially are not significant.

From the data shown in Table (9), it could be observed that the level of ALT in group (7) fed on 10% ginger and turmeric was lower than the positive control group (7.4±5.639 U/L, 13.667±4.589U/L) The results agreed with that obtained by Uma Bhandari *et al.* (2003). While the mean level of AST in group (8) fed on 15% ginger and turmeric was lower than the positive control group (14.2±3.421 U/L, 18.5±1.225 U/L). The results agreed with that obtained by (Stanley *et al.*, 2017). On the contrary, the mean value of P was similar in the experimental group except group (7) fed on 10% ginger and turmeric was higher than

the positive control group (5.367±0.907, 5.2±0.1). Treating animals with water extract of ginger and adriamycin led to an improvement in the histological changes induced by adriamycin together with significant decrease in ALT and AST activity. Moreover, ginger reduced the level of malondialdehyde and increased the activity of superoxide dismutase. The results of the present work indicated that ginger had protective effect against liver damage induced by adriamycin and this is due to its antioxidant activities.(Saber *et al.* , 2011).

Table (9): Effect of ginger and turmeric on liver function and phosphorus of rats suffering from osteoporosis.

Groups	Parameters		
	ALT U/L	AST U/L	P
<b>Group (1):</b> negative control	9.2 <sup>b</sup> ±7.120	21.4 <sup>a</sup> ±2.191	4.8 <sup>a</sup> ±0.3
<b>Group (2):</b> positive control	13.667 <sup>a</sup> ±4.589	18.5 <sup>a</sup> ±1.225	5.2 <sup>a</sup> ±0.1
<b>Group (3):</b> 10% ginger	10.833 <sup>b</sup> ±3.601	18 <sup>a</sup> ±1.549	4.733 <sup>b</sup> ±0.153
<b>Group(4):</b> 15% ginger	13.833 <sup>ab</sup> ±3.764	17 <sup>ab</sup> ±1.549	4.767 <sup>ab</sup> ±0.115
<b>Group (5):</b> 10% turmeric	8.833 <sup>c</sup> ±4.997	14.5 <sup>b</sup> ±5.282	4.867 <sup>a</sup> ±0.289
<b>Group (6):</b> 15% turmeric	14.2 <sup>a</sup> ±4.087	16 <sup>b</sup> ±3.0	4.633 <sup>b</sup> ±0.153
<b>Group (7):</b> 10% ginger and turmeric	7.4 <sup>c</sup> ±5.639	14.4 <sup>b</sup> ±4.979	5.367 <sup>a</sup> ±0.907
<b>Group (8):</b> 15% ginger and turmeric	9.8 <sup>b</sup> ±4.919	14.2 <sup>b</sup> ±3.421	4.667 <sup>b</sup> ±0.115
<b>ANOVA ( F)</b>	0.834	0.163	0.566
<b>Sig.</b>		*	*

- Values are expressed as mean ± SD.

- Significant at p<0.05 using one way ANOVA test.

- Values which have different letters in each column differ significantly, while those with have similar or partially are not significant.

The results in Table (10) indicated that the mean values of the total Ca in positive control group was higher than that in group (4) fed on 15% ginger (8±1.082 and 6.967±0.462, respectively), and Ca<sup>++</sup> in positive control group was higher than that in group (3) fed on 10% ginger (1.288<sup>a</sup>±0.081 and 1.236±0.021, respectively). On the other hand, total Ca and Ca<sup>++</sup> levels in all experimental groups fed on ginger and turmeric were significantly less than that in positive control group. On the contrary, the mean value of Ca/Ca<sup>++</sup> in the positive control group was significantly less than the all experimental groups fed on ginger and turmeric. In healthy rats, both simvastatin and fenofibrate treatment showed a negative effect on the trabecular bone located at the level of femoral diaphysis. These results are consistent with other studies which concluded that to a certain extent, statins inhibit bone resorption and promote bone formation, but have no significant effect on bone mineral density in healthy rats (Chang *et al.*, 2011; Gradosova *et al.*, 2011).

Effects of extra-skeletal estrogen deficiency are mainly based upon increased renal calcium excretion and decreased intestinal calcium absorption (Khosla *et al.*,

1997). Estrogen plays an important role in calcium absorption in the gut (Gennari *et al.*, 1990) and its reabsorption in the kidney (McKane *et al.*, 1995). The presence of estrogen receptors in the intestine has been reported and has been shown to increase intestinal calcium absorption in both rats and humans. Curcumin (Diferuloylmethane, 1, 7- bis (4-Hydroxy-3-methoxyphenyl)-1, 6-heptadiene-3, 5 - dione) is the active polyphenolic compound extracted from the rhizomes of turmeric (*Curcuma longa* L., Zingiberaceae), grown in tropical Southeast Asia (Jagetia and Aggarwal 2007; Padhye *et al.*, 2010). Some studies demonstrated the efficacy of turmeric extracts in the prevention of bone loss in animal models of rheumatoid arthritis and postmenopausal osteoporosis (Wright *et al.*, 2010). It was found in vitro investigations that the anti-inflammatory effects of curcumin prevent osteoclast differentiation (Bharti *et al.*, 2004; von Metzler *et al.*, 2009). Thus, curcumin produces beneficial changes in bone turnover and increase in bone strength using the ovary ectomized mature rat model of postmenopausal osteoporosis (Houet *et al.*, 2016).

## Study of the effect of ginger and turmeric on osteoporosis in female rats

Table (10): Effect of ginger and turmeric on total and ionized calcium of rats suffering from osteoporosis.

Groups	Parameters		
	Total Ca	Ca <sup>++</sup>	Ca/Ca <sup>++</sup>
<b>Group (1):</b> negative control	8.567 <sup>a</sup> ±2.369	1.323 <sup>a</sup> ±0.049	6.436 <sup>a</sup> ±1.519
<b>Group (2):</b> positive control	8 <sup>a</sup> ± 1.082	1.288 <sup>a</sup> ±0.081	2.999 <sup>c</sup> ±3.295
<b>Group (3):</b> 10% ginger	7.8 <sup>a</sup> ±0.781	1.236 <sup>b</sup> ±0.021	6.313 <sup>a</sup> ±0.709
<b>Group(4):</b> 15% ginger	6.967 <sup>b</sup> ±0.462	1.27 <sup>a</sup> ±0.017	5.488 <sup>b</sup> ±0.407
<b>Group (5):</b> 10% turmeric	7.8 <sup>a</sup> ±0.693	1.263 <sup>ab</sup> ±0.046	6.187 <sup>ab</sup> ±0.691
<b>Group (6):</b> 15% turmeric	7.133 <sup>b</sup> ±1.012	1.25 <sup>b</sup> ±0.026	5.716 <sup>b</sup> ±0.902
<b>Group (7):</b> 10% ginger and turmeric	7.733 <sup>ab</sup> ±1.168	1.253 <sup>b</sup> ±0.0321	6.173 <sup>ab</sup> ±0.957
<b>Group (8):</b> 15% ginger and turmeric	7.667 <sup>b</sup> ±1.026	1.24 <sup>b</sup> ±0.0458	6.205 <sup>a</sup> ±1.044
<b>ANOVA ( F)</b>	<b>0.168</b>	<b>0.176</b>	<b>0.588</b>
<b>Sig.</b>	*	*	*

- Values are expressed as mean ± SD.

- Significant at p<0.05 using one way ANOVA test.

- Values which have different letters in each column differ significantly, while those with have similar or partially are not significant.

### X-ray and Histopathology

In the present study; radiographic imaging of the negative control group radiographic view showed normal radiographic finding of tibia and distal

extermity of femur.and showing normal histological structure of the periosteum, compact shaft of long bone and bone trabeculae with bone marrow in between (Figs. 1,2, 3).

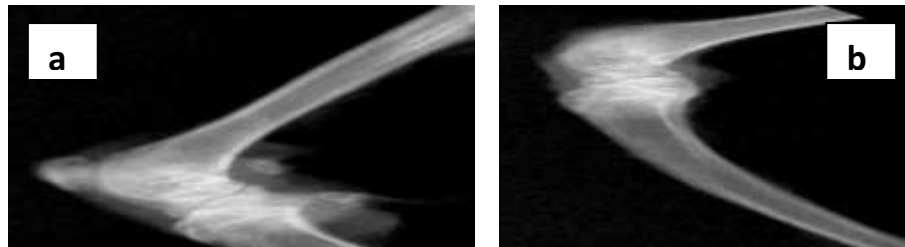


Fig.(1): Radiographic findings of group (1).

a- Lateral radiographic view showed Normalradiographic finding of femur.

b-Lateral radiographic view showed Normalradiographic finding of tibia and disital extermity of femur .

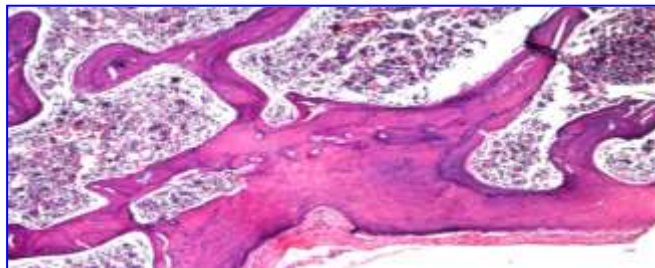


Fig.(2): L.S. of Femur bone of rat in group (1) showing normal histological structure of the periosteum, compact shaft of long bone and bone trabeculae with bone marrow in between. Stained Hx.E, X40.

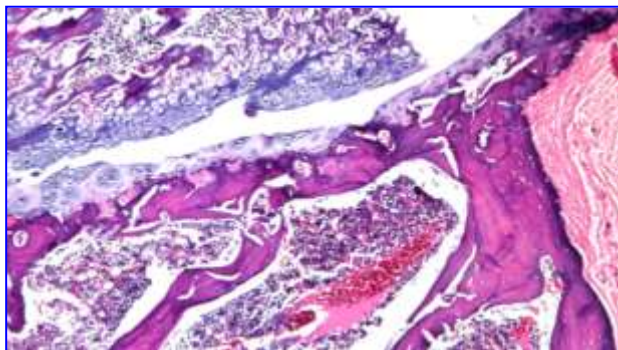


Fig.(3): L.S. of Femur bone of rat in group(1) showing normal histological structure of the cartilaginous articular surface of the condyle. Stained Hx.E, X40.

In the present study; radiographic imaging of the positive control group after glucocorticoids (GC) administration for three weeks revealed bone loss of different part such as fibula, tibia and femur in addition to bone demineralization and thinning of femoral cortex in rats, disappear of cortex of tibia in others and fibula and these agree with the observations of Hallberg *et al.* (2009), Weinstein (2001) and Sipos *et al.* (2015). Osteoporosis is characterized as a reduction in bone mass and an impairment of bone architecture resulting a bone thinning with direct effects on increased cortical porosity, bone fragility

and fracture risk. GC therapy is the most common cause of osteoporosis, leading to osteonecrosis of the femoral head and fractures, which may also be associated with fracture-related morbidity and a decreased quality of life.

Radiographic findings of group (2) show demineralization of tibia and bone loss of proximal part of fibula (Fig 4). Histopathologically, there were bone trabeculae osteoporosis and resorption associated with dystrophy of the articular cartilaginous surface and congestion of the blood vessels, these findings were confirmed the radiological findings (Figs. 5, 6).

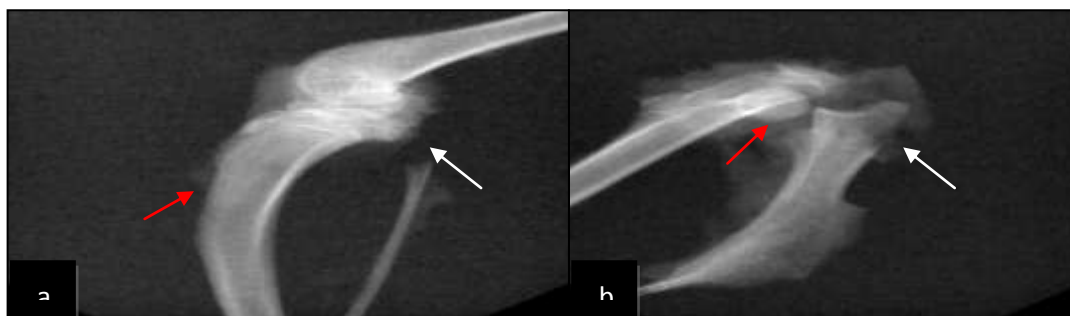

Fig.(4): Radiographic findings of group (2).

- a. Lateral radiographic view of tibia and fibula showing demineralization of tibia (red arrow) and bone loss of proximal part of fibula (white arrow).
- b. Lateral radiographic view of femur and pelvic bone showing demineralization and partial bone loss of ilium and femoral head fracture (white arrow).



## Study of the effect of ginger and turmeric on osteoporosis in female rats

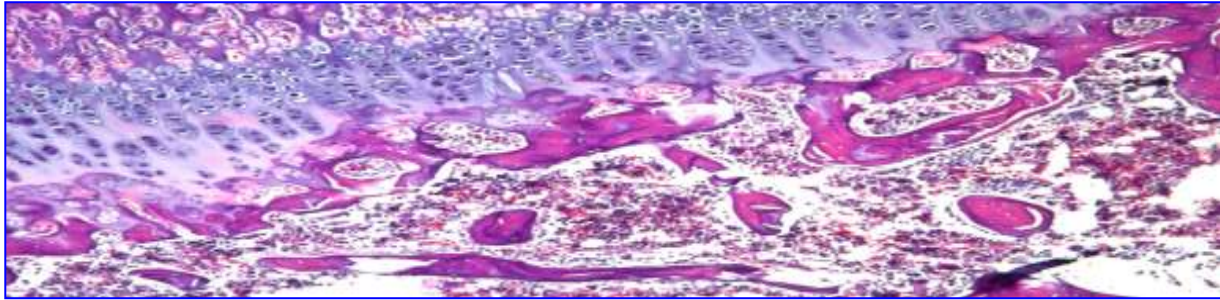


Fig.(5):L.S. of Femur bone of rat in group (2) showing osteoporosis and resorption of the bone trabeculae. Stained H&E, X16.

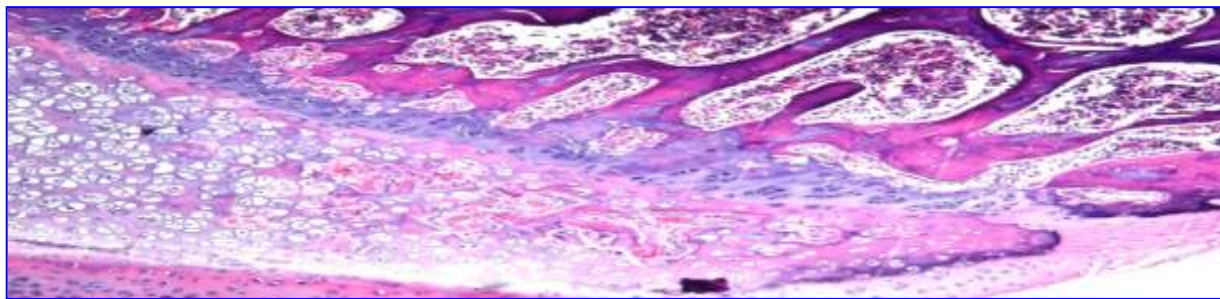


Fig.(6):L.S. of Femur bone of rat in group (2) showing cartilaginous dystrophy of the articular surface with congestion of the blood vessels. H&E, X16.

Radiologically in treated group by ginger 10% in group (3) after two months revealed mineralization improvement of bony loss and demineralized area as following remineralization at proximal extremity of femur and normal architecture without disruption at distal extremity of

femur, rebuilding of fibula with mineralization in compare to untreated group and Remineralization Bridge at tibia with different degree of callus formation but still there was thinning in fibula (Fig. 7). Histopathologically, there was no histopathological alteration (Figs.,8, 9).

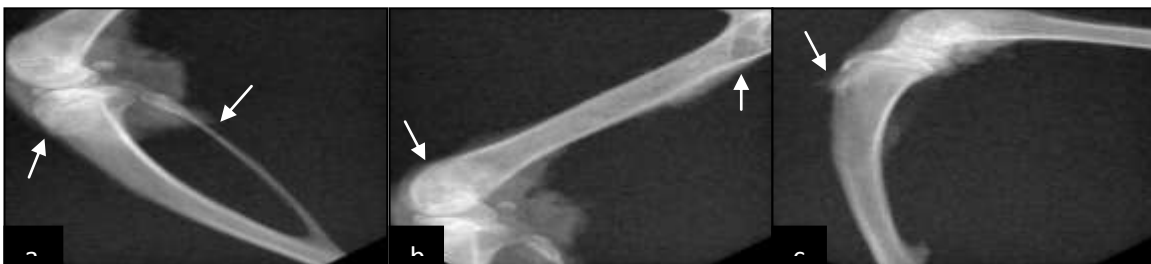

Fig. (7):Radiographic findings of group (3)

- a-Lateral radiographic view of tibia, fibula and distal extremity of femur showing normal radiographic findings and architecture (thinning in fibula) Remineralization Bridge at tibia
- b-Lateral radiographic view of femur showing remineralization at proximal extremity (black arrow) and normal architecture without disruption at distal extremity
- c-Lateral radiographic view of tibia showing remineralization and small callus formation at lost bony part (white arrow).

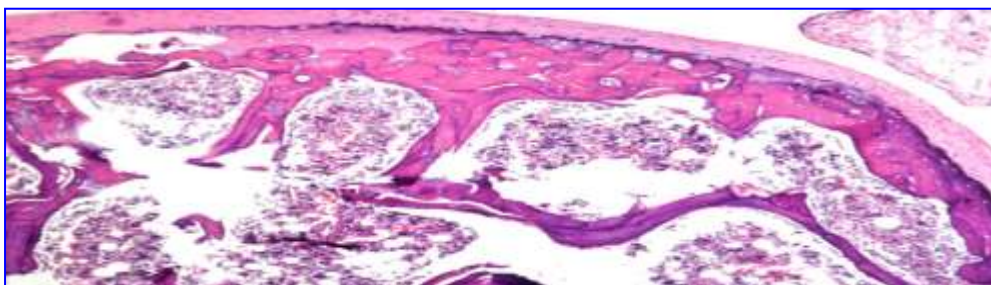


Fig.(8):L.S. of Femur bone of rat in group (3) showing normal histopathological structure of articular cartilaginous surface and under lying coupact bone. Stained H&E, X 16.

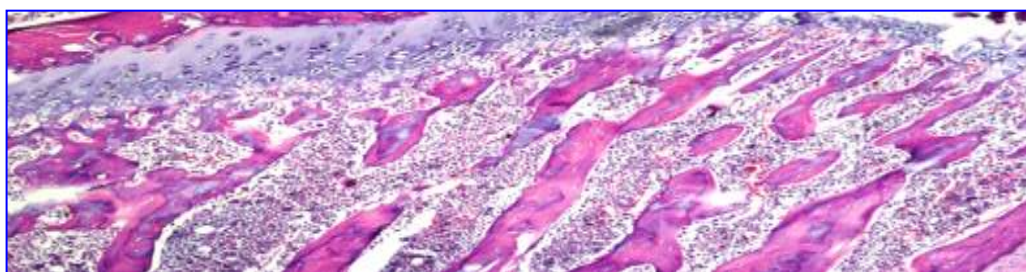


Fig.(9):Femur bone of rat in group (3) showing in fact normal histopathological structure of bone trabeculae. Stained H&E, X 16.

In parallel to it the treated group by ginger 15% in group (4) after two months revealed continuation of rebuilding of different demineralized parts such as difficult notification of remineralization and callus formation over epiphyseal fracture, traces of callus formation at tibial lost bony part, normal radiographic findings of fibula and femoral discontinuation of proximal cortical surface, and disital part but there was small callus formation at femoral lost bony part at distal epiphysis which confirmed histopathologically resorption of the bone trabeculae was detected. These findings revealed that ginger has important role in remineralization and improvement of osteoprotic changes of tibia, fibula and

femur especially at extremities of femur and tibia (articular surface) due to ginger has anti inflammatory effect in osteoarthritis cases in agree with Baer *et al.* (2005) and Amorndoljai *et al.* (2017) who indicated that ginger has been used for time immemorial for treatment of rheumatic disorder due to its anti-inflammatory properties and ability to inhibit arachidonic acid metabolism. It relieve joint pain and improve problematic symptoms and the quality of life in knee patients, it is effective as 1% Diclofenac gel and it can be considered as complementary therapy in patients with osteoarthritis of knee, in addition to it reduce the risk of systemic toxic (Figs. 10, 11).



## Study of the effect of ginger and turmeric on osteoporosis in female rats

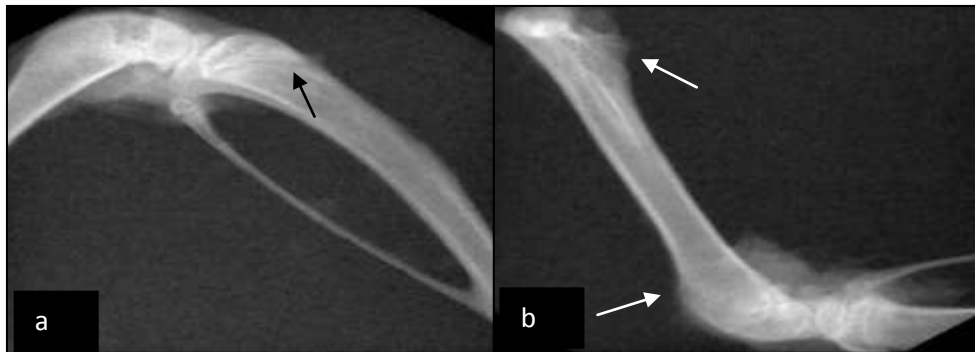


Fig.(10):Radiographic findings of group (4)

a-Lateral radiographic view of tibia showing remineralization and bridge formation over epiphyseal fracture (black arrow) and normal radiographic findings of fibula

b-Lateral radiographic view of femur showing discontinuation with small callus formation at lost bony part at distal epiphysis (white arrow)and discontinuation of proximal cortical surface (white arrow).

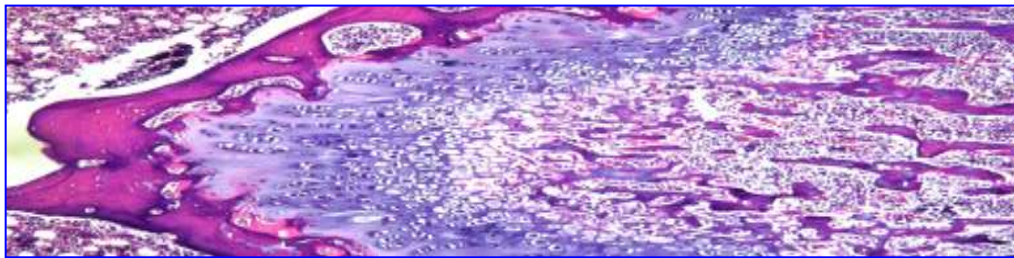


Fig.(11):L.S. of Femur bone of rat in group (4) showing bone resorption of the trabeculae.  
Stained H&E, X 16.

Radiologically in treated group by curcumina 10% in group(5) after two months revealed good mineralization improvement of bony loss and rebuilding bone process as following no radiographic findings of tibia, fibula, proximal femur and still there were moderate remineralization of tibial epiphysis and bridged callus formation at oblique epiphyseal fracture of tibia (Fig. 12), Histopathologically the bone trabeculae showed dystrophy and resorption.

these findings revealed that curcumin treatment attenuated and treated degrees to osteoporosis induced by GC in compare to untreated group in agree with (Yang *et al.*, 2011; Chen *et al.*, 2015) who demonstrated that curcumin improved bone microarchitecture and enhanced mineral density in APP/PS1 transgenic mice, and it attenuated GIOP by inhibiting osteocyticapoptosis (Fig.13).

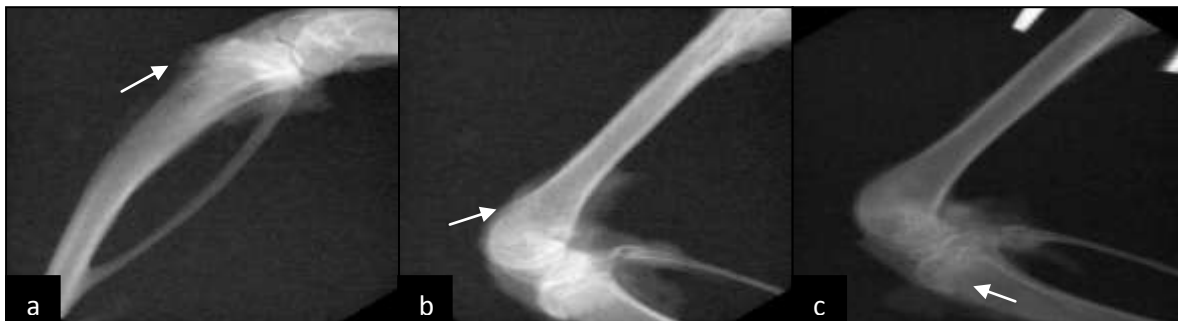

Fig.(12):Radiographic findings of group (5)

- a. Lateral radiographic view of tibia and fibula showing moderate remineralization of epiphysis and normal radiographic finding of fibula
- b.Lateral radiographic view of femur showing discontinuation of femoral cortex
- c.Lateral radiographic view of femur, tibia and fibula showing normal radiographic findings of femur, fibula and bridged callus formation at oblique epiphyseal fracture of tibia (white arrow) .




Fig.(13):Femur bone of rat in group (5) showing dystrophy and resorption of the bone trabeculae. Stained H&E, X 16.

While in the treated group by curcumina 15% in group (6) after two months revealed some repairs to damaged bony parts as normal radiographic findings of femur (Fig. 14). There was no histopathological alteration in the articular cartilaginous surface and bone trabeculae and thick radiopaque tibial cortex but there were also bony loss of proximal part of

fibula, in complete remineralization of fibula and discontinuation of femoral cortex, these findings in compare to untreated group revealed that the curcumina 15% stimulate rebuilding process (Yang *et al.*, 2011; Chen *et al.*, 2015) but not as curcumina 10%, the curcumina 10% was more effective (Figs. 15,16).

## Study of the effect of ginger and turmeric on osteoporosis in female rats

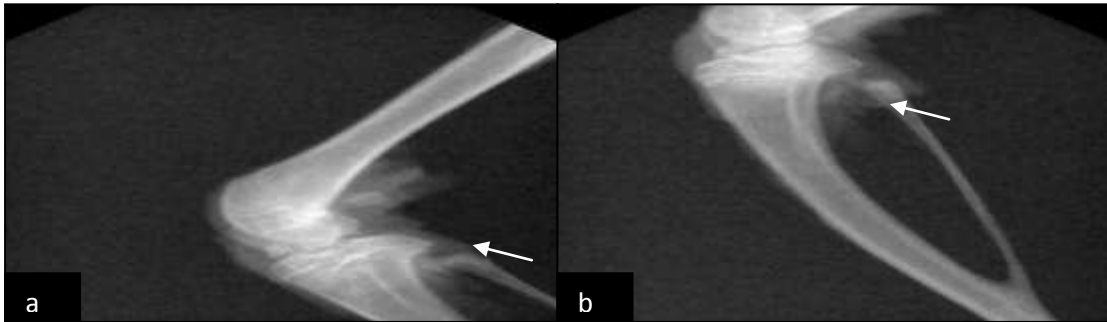


Fig.(14):Radiographic findings of group (6)

- Lateral radiographic view of femur, tibia and fibula showing normal radiographic findings of femur and incomplete remineralization of fibula (white arrow).
- Lateral radiographic view of tibia and fibula showing bony loss of proximal part of fibula (still incomplete remineralization).

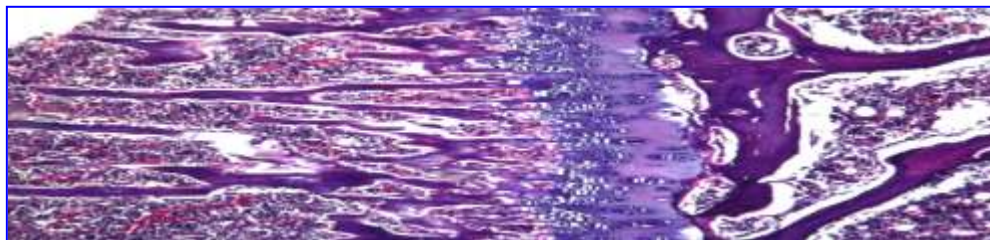


Fig.(15):L.S. of Femur bone of rat in group (6) showing normal histopathological structure of articular cartilaginous surface and treabeculae. Stained H&E, X 16.

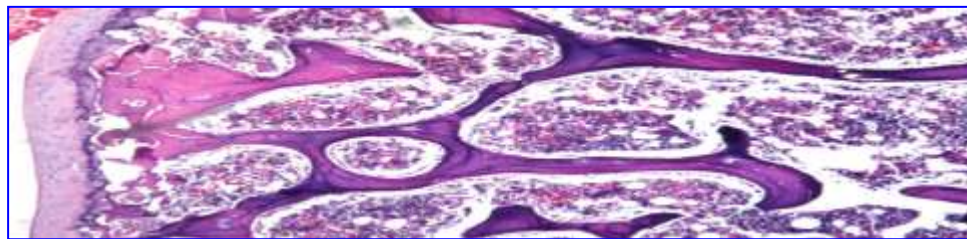


Fig.(16): L.S. of Femur bone of rat in group(6) showing the magnification of (T.G.65). Stained H&E, X40.

In the present study, the radiological findings of treated group by curcumina 10% and ginger 10% in group (7) indicated normal radiographic findings of femur, tibia and fibula (Fig. 17). Also, there was no histopathological alteration (Figs. 18, 19).

Along with moderate remineralization of tibial and femoral epiphysis. These findings revealed that the mixture of both curcumina 10% and ginger 10% has more compelling effect against osteoperotic changes than each one alone, in



contrast curcumina 10% acts on improved bone microarchitecture and enhanced mineral density while ginger strengths it by

acting on osteoarthritis changes (Chen *et al.*, 2015; Amorndoljai *et al.*, 2017).

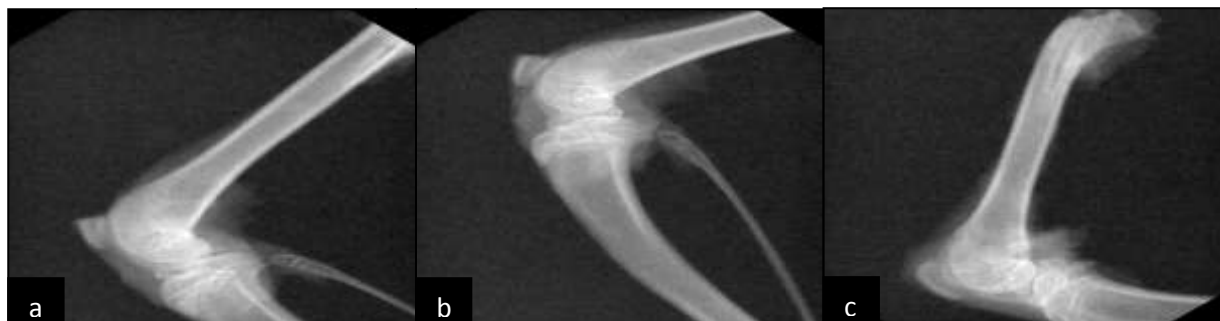

Fig.(17): Radiographic findings of group(7)

Lateral radiographic view of femur (a), tibia and fibula (b) showing normal radiographic findings. c-Lateral radiographic view of femur showing moderate remineralization of epiphysis (low radiodensity area) (white arrow) and normal radiographic finding of diaphysis and proximal epiphysis



Fig.(18):Femur bone of rat in group (7) showing normal histopathological structure of articular cartilaginous surface and bone trabeculae. Stained H&E, X16

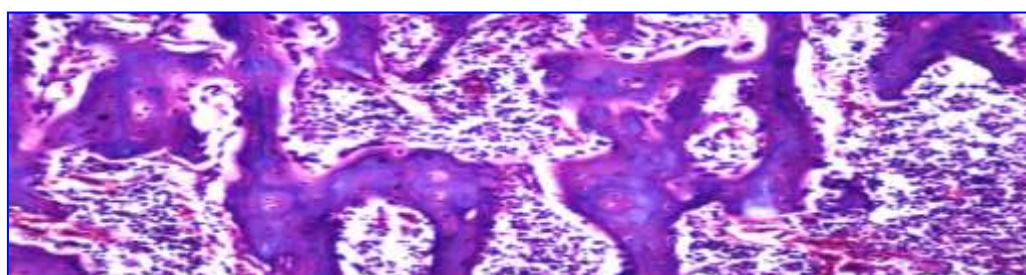


Fig.(19):L.S. of Femur bone of rat in group (7) showing the magnification of (T.G.71 ). Stained H&E, X 40

On the other hand, mixture of curcumina 10% and ginger 10% was less qualified in 15% percentage in group (8) due to the radiographic findings revealed that the most obvious radiographic finding, small

radiolucent area at epiphysis of femur and tibial (Fig. 20).

There was no histopathological alteration in the articular cartilaginous surface, compact bone and trabeculae (Figs.21,22, 23).

## Study of the effect of ginger and turmeric on osteoporosis in female rats

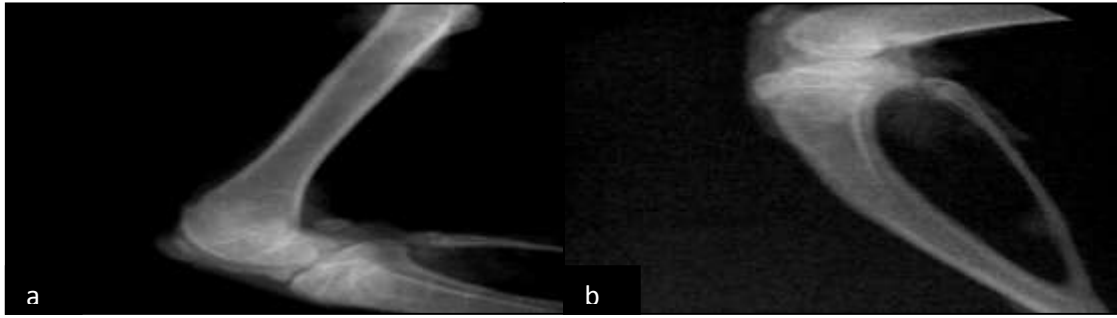


Fig.(20): Radiographic findings of group (8). a and b: Lateral radiographic view of femur, tibia and fibula showing normal radiographic findings.

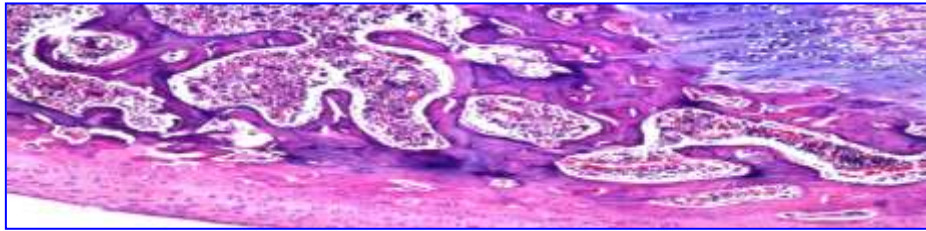


Fig.(21): L.S. Femur bone of rat in group (8) showing the magnification of (T.G.74) to identify the bone trabeculae. Stained H&E, X40

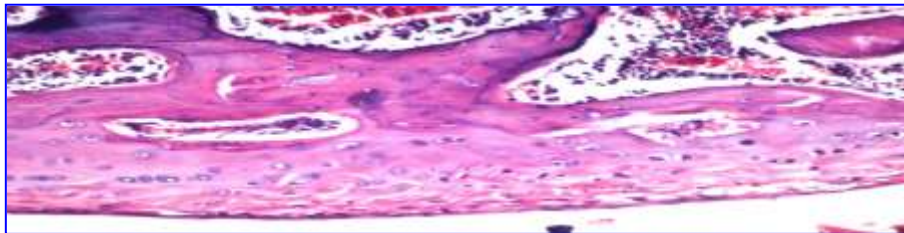


Fig.(22): L.S of Femur bone of rat in group (8) showing the magnification of (T.G.74) to identify the in fact compact bone. Stained H&E, X80

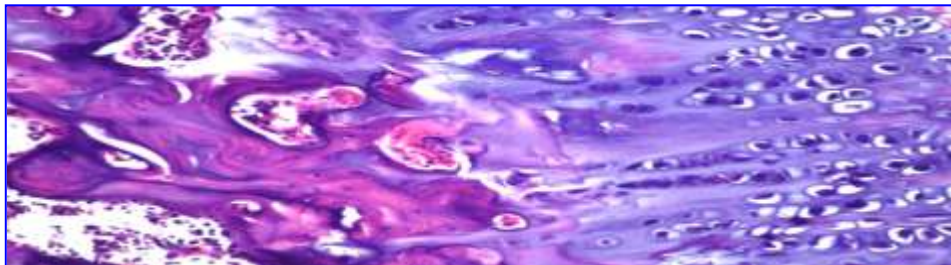


Fig.(23): L.S. Femur bone of rat in group (8) showing the magnification of (T.G.74) to identify the in fact bone cartilaginous structure. Stained H&E, X40.

On the other hand, the radiological and histological findings of the group (9) bone loss of different part such as fibula, tibia and femur in addition to bone demineralization and femoral fracture and fibula bone trabeculae showed dystrophy and resorption and osteoporosis (Figs. 24,

25, 26). This agrees with the findings of Henneicke *et al.* (2011) and Sipos, *et al.*(2015) who found that using of oral corticosteroids is associated with serious side effects, including osteoporosis and consequently an increase in fractures.

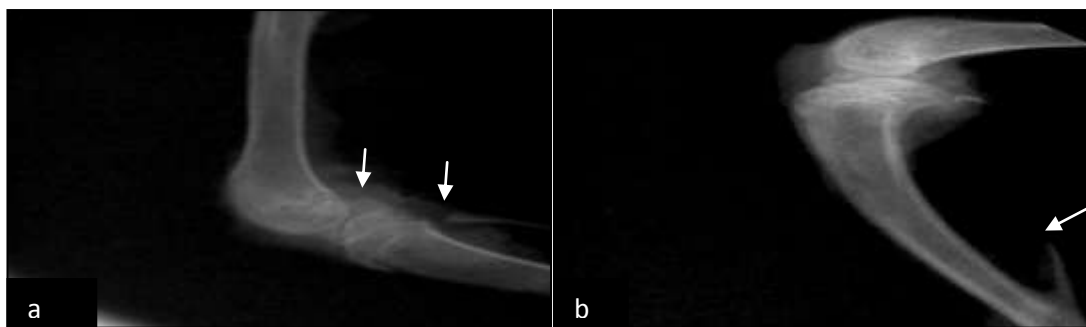


Fig.(24): Radiographic findings of group (9).

- a. Lateral radiographic view of femur and tibia showing fractured distal extremities of femur (white arrow) and demineralization and loss of proximal part of fibula (white arrow).
- b. Lateral radiographic view of tibia and fibula showing bony loss of fibula (white arrow).

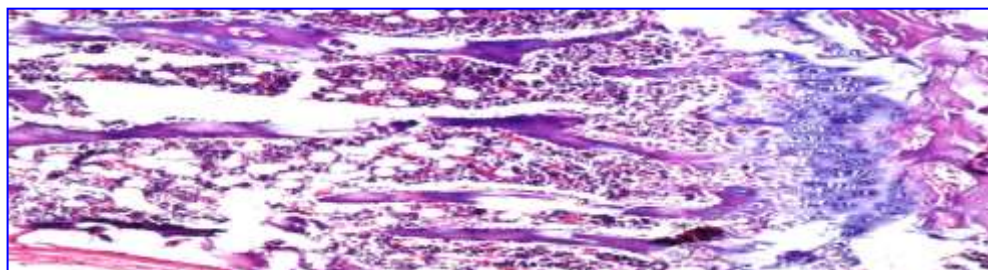


Fig.(25): L.S. of Femur bone of rat in group (9) showing resorption, dystrophy and osteoporosis of the bone trabeculae. Stained H&E, X16

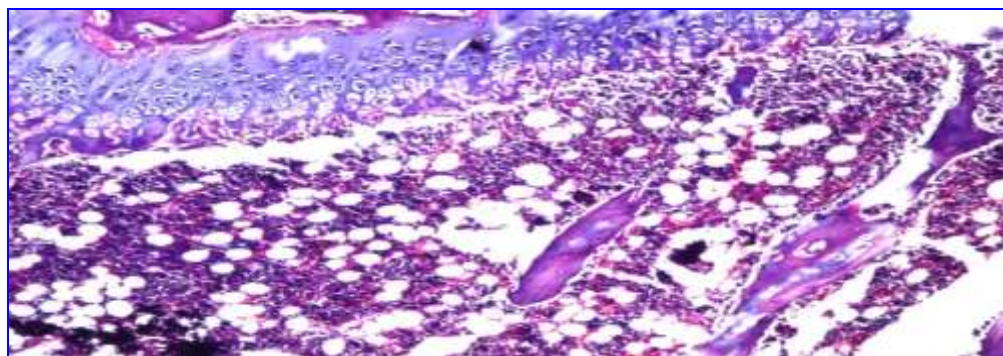


Fig.(26): L.S. of Femur bone of rat in group (9) showing resorption, dystrophy and osteoporosis of the bone trabeculae. Stained H&E, X16



## Study of the effect of ginger and turmeric on osteoporosis in female rats

### Conclusion

In the present study; Osteoporosis is characterized as a reduction in bone mass and an impairment of bone architecture resulting a bone thinning with direct effects on increased cortical porosity, bone fragility and fracture risk. GC therapy is the most common cause of osteoporosis, leading to osteonecrosis of the femoral head and fractures, which may also be associated with fracture-related morbidity and a decreased quality of life. ginger has important role in remineralization and improvement of osteoporotic changes of tibia, fibula and femur especially at extremities of femur and tibia (articular surface) due to ginger has anti-inflammatory effect in osteoarthritis cases. And also these findings revealed that curcumin treatment attenuated and treated degrees to osteoporosis induced by GC in compare to untreated group. Also findings revealed that the mixture of both curcumina and ginger has more compelling effect against osteoporotic changes than each one alone.

### REFERENCES

- Ali, B.H.; Blunden, G.; Tanira, M.O. and Nemmar, A. (2008). Some phytochemical pharmacological and toxicological properties of ginger (*Zingiber officinale* Roscoe): a review of recent research. *Food Chem. Toxicol.*, 20-409: (2)46.
- Anbinder, A.L.; Prado, M.A.; Spalding, M.; Balducci, I; Carvalho, Y.R. and Rocha, R.F. (2006). Estrogen Deficiency and Periodontal Condition in Rats- A Radiographic and Macroscopic Study. *Braz. Dent. J.*, 17(3): 201-207.
- Amorndoljai, P.; Taneepanichskul, S.; Niempoog, S. and Nimmannit, U. (2017). A Comparative of Ginger Extract in Nanostructure Lipid Carrier (NLC) and 1% Diclofenac Gel for Treatment of Knee Osteoarthritis (OA). *J. Med. Assoc. Thai.*, 100(4): 447-456.
- AOAC (1998). Official methods of Analysis of the Association of Official Analytical Chemists, 20<sup>th</sup>ed.
- AOAC. (2007). Official Methods of Analysis, 18<sup>th</sup> Ed. Association of Official Analytical chemists, Gaithersburg, MD, USA.
- Awang, D.V.C. (1992). Ginger. *Can. Pharm. J.*, 125:309–311.
- Badreldin, H. Ali.; G. B.; Musbah, O.T. and Abderrahim N. (2008). Some phytochemical, pharmacological and toxicological properties of ginger (*Zingiber officinale* Roscoe): A review of recent research. *Food Chem. Toxicol.*, 46:409–420.
- Baer, P.A.; Thomas, L.M. and Shainhouse, Z. (2005). Treatment of osteoarthritis of the knee with a topical diclofenac solution: a randomised controlled, 6week trial [ISRCTN53366886]. *BMC Musculoskeletal Disord*, 6: 44.
- Balaji, S. and Chempakam, B. (2010). Toxicity prediction of compounds from turmeric (*Curcuma longa* L). *Food Chem. Toxicol.*, 48(10):2951-2959.
- Banchroft, J.D.; Stevens, A. and Turner, D.R. (1996). *Theory and Practice of Histological Techniques*. Fourth Ed. Churchill Livingstone, New York, London, San Francisco, Tokyo.
- Bharti, A.C. and Takada, Y. B.B. (2004). Aggarwal Curcumin (diferuloylmethane) inhibits receptor activator of NF-kappa B ligand-induced NF-kappa B activation in osteoclast precursors and suppresses

- osteoclastogenesis. *J. Immunol.*, 172(10): 5940-7.
- Bras, M.; Queenan, B. and Susin, S. (2005). Programmed cell death via mitochondria: different modes of dying. *Biochemistry*, 70: 231-239.
- Bagi, C.M.; Berryman, E. and Moalli, M.R. (2011). Comparative bone anatomy of commonly used laboratory animals: implications for drug discovery. *Comp Med* 61:76-85
- Busija, L.; Bridgett, L.; Williams, S.R., *et al.* (2010). Osteoarthritis. *Best. Pract. Res. Clin. Rheumatol.*, 24:757-68.
- Chang, B.; Yang, J.; Li, H.; Lu, S.; Chen, L.; Fang, P. (2011). Effects of atorvastatin on bone metabolism and bone mineral density in Wistar rats, *Pharmazie*, 2011, 66(7), 535-7.
- Chaplin, M.F and Kennedy, J.F. (1986). Monosaccharides. In: Chaplin, M.F., Kennedy, J.F. (Eds.), *Carbohydrate Analysis A Practical Approach. The Practical Approach Series.* Oxford University Press, Oxford, pp. 1-42.
- Chen, Z.; Xue, J.; Shen, T.; Ba, G.; Yu, D.; Fu, Q. (2015). Curcumin alleviates glucocorticoid-induced osteoporosis by protecting osteoblasts from apoptosis in vivo and in vitro. *Clin. Exp. Pharmacol. Physiol.*, 30: pages 268-276.
- Chapman, D.G.; Castilla, R. ; Campbell, J.A. (1959). Evaluation of protein in food. I- A method for the determination of protein efficiency ratio. *Can. J Biochem. Physiol.*, 37: 679 - 686.
- Deokar, S.B.; Pawar R.M.; Tambe, A.R. (2016). Evaluation of antimicrobial activity and phytochemical analysis of *Zingiber officinale* (Ginger) rhizome extract. *IJAPRR*, 3(4):1-9.
- Dulbecco, P., and Savarino, V. (2014). Therapeutic potential of curcumin in digestive diseases. *World journal of gastroenterology: WJG*, 19(48): 9256.
- El-Baroty, G. S.; Abd El-Baky, H.H.; Farag, R.S. and M.A. Saleh (2010). Characterization of antioxidant and antimicrobial compounds of cinnamon and ginger essential oils. *Afr. J. Biochem. Res.*, 4(6):167-174. at <http://www.academicjournals.org/AJBR>.
- El-Olemy, M.M.; Farid, J.A. and Abdel-Fattah, A.A. (1994). Ethanol Extract of *P. stratiotes*. *NISEB J.* 1(1): 51-59.
- Evans, M. L.; Dick, M. J.; Lewallen, L. P.; & Jeffrey, C. (2004). Modified breastfeed-ing attrition prediction tool: Prenatal and postpartum tests. *Journal of Perinatal Education*, 13, 1-8. doi:10.1624/105812404X109348.
- Fisher-Rasmussen, W.; Kjaer, S.K.; Dahl, C.; Asping, U. (1991). Ginger treatment of Hyperemesis gravidarum. *Eur. J. Obstet. Gynecol. Rep. Biol.*, 38(1):19-24.
- Fijelu, F.; Yanshun, X.; Qixing, J. and Wenshui, X. (2013). Protective effects of garlic (*Allium sativum*) and ginger (*Zingiber officinale*) on physicochemical and microbial attributes of liquid smoked silver carp (*Hypophthalmichthys molitrix*) wrapped in aluminium foil during chilled storage. *Afr. J. Food Sci.*, 52:302-310. DOI: 10.5897/AJFS2013.1030.
- Genant, H.K.; Cooper, C.; Poor, R.; Reid, I.; Eilich, G.; Kanis, J., et al. (1999). Interim report and recommendations of the World Health Organization task-force for osteoporosis. *Osteoporos Int.*, 10:259-264.
- Gennari, C.; Agnusdei, D.; Nardoni P. and Civitelli, R. (1990). Estrogen preserves a normal intestinal



### Study of the effect of ginger and turmeric on osteoporosis in female rats

- responsiveness to 1,25-dihydroxy vitamin D3 in oophorectomized women. *J. Clin. Endocrinol. Metab.*, 71(5): 1288-1293.
- Gradosova, I.; Zivna, H.; Svejtkovska, K.; Palicka, V.; Pichy, A. and Zivny, P. (2011). The role of atorvastatin in bone metabolism in male albino Wistar rats. *Pharmazie*, 66(8): 606-10.
- Halvorsen, B.L.; Holte, K.; Myhrstad, M.C.; Barikino, I.; Hvattum, E.; Remberg, S.F.; Wold, A.B.; Haffner, A. (2002). A systemic screening of total antioxidants in dietary plants. *J. Nutr.*, 2002; 132:461-471.
- Hiserodt, R.; Thomas, G.H.; Chi-Tang, H. and Robert, T.R. (1996). Characterization of powdered turmeric by liquid chromatography mass spectrometry and gas chromatography mass spectrometry. *J. Chromatogr.*, 740(1):51-63.
- Hou, M.; Song, Y.; Li, Z.; Luo, C.; Ou J.-S.; Yu H.; Yan, J.; Lu, L. (2016). Curcumin attenuates osteogenic differentiation and calcification of rat vascular smooth muscle cells. *Mol. Cell Biochem.*, 420 (1-2):151-60.
- Hallberg, I.; Bachrach-Lindström, M.; Hammerby, S.; Toss, G.; Ek, A.C. (2009). Health-related quality of life after vertebral or hip fracture: a seven-year follow-up study. *BMC Musculoskelet. Disord.*, 10: 135, 2009.
- Henneicke-Holger, M.; Robert, K.; Tara, C.B.; Uta, H.; Nicky, B.; Robert, E.D.; Dörte, H.; Frank, B.; Colin, R.D.; and Hong, Z. (2011). Corticosterone selectively targets endocortical surfaces by an osteoblast-dependent mechanism. *Bone*, 49: 733-742.
- Jagetia, G.C. and B.B. (2007). Aggarwal "Spicing up" of the immune system by curcumin. *J. Clin. Immunol.*, 27(1):19-35.
- Jayaprakasha, G.K.; Bhabani, S.J.; Pradeep, S.N. and Kunnumpurath, K.S. (2002). Evaluation of antioxidant activities and antimutagenicity of turmeric oil: a byproduct from curcumin production. *Z. Naturforsch [C]*, 57(9-10): 828-35.
- Jurenka, J.S. (2009). Anti-inflammatory properties of curcumin, a major constituent of *Curcuma longa*: a review of preclinical and clinical research. *Altern. Med.*:141-153.)
- Kamtchouing, P.; Fandio, G.Y.M.; Dimo, T. and Jatsa, H.B. (2002). Evaluation of androgenic activity of *Zingiber officinale* and *Pentadiplandra brazzeana* in male rats. *Asian J. Androl.*, 4: 299-301.
- Khosla, S.; Atkinson, E.J.; Melton, L.J. and Riggs, B.L. (1997). Effects of age and estrogen status on serum parathyroid hormone levels and biochemical markers of bone turnover in women: a population-based study. *J. Clin. Endocrinol. Metab.*, 82 (5):1522-1527.
- Kimberly, P.; William, S.; Robert, D. and Beckett. (2017). Efficacy of Curcuma for treatment of osteoarthritis. *J. Evidence-Based Complementary & Alternative Med.*, 22(1) pages 156-165.
- Langner, E.; Greifenberg, S. and Gruenwald, J. (1998). Ginger: history and use. *Advances in Therapy*, 15: 25-44.
- Lucinda, L.M.; Vieira, B.J.; Peters, V.M.; Reis, J.E.P.; Oliveira, R. and Guerra, M.O. (2013). The effect of the *Ginkgo biloba* extract in the expression of Bax, Bcl-2 and bone mineral content of Wistar rats with glucocorticoid-induced osteoporosis. *Phytother. Res.*, 27: 515-520.

- Liao, E.Y.; Deng, X.G. and Zhou, Z.G.(2003). Study on the treatment of postmenopausal osteoporosis with the combination of nylestriol and progesterone. *Chin. J. Endocrin. Metabolism*, 18(2):95–98.
- Mascolo, N.; Jain, S.C. and Capasso, P. (1989). Ethnopharmacologic investigation of ginger (*Zingiber officinale*). *J. Ethnopharmacol.*, 27:129-140.
- McDonald, S.; Prenzler, P.D.; Autolovich, M. and Robards, K. (2001). Phenolic content and antioxidant activity of olive extracts: *Food Chem.*, 73: 73-84.
- McKane, W.R.; Khosla, S.; Burritt, M.F. ; Kao, P.C.; Wilson, D.M.; Ory, S.J. and Riggs B.L. (1995). Mechanism of renal calcium conservation with estrogen replacement therapy in women in early postmenopause - a clinical research center early postmenopause - a clinical research center study. *J. Clin. Endocrinol.Metab*, 80 (12), 3458.
- Negi, P.S., Jayaprakasha G. K.; Jagan M.; Rao, L. and Sakariah K. K. (1999). Antibacterial activity of turmericoil: a byproduct from curcumin manufacture. *J. Agric. Food Chem.*, 47(10): 4297-300.
- Niamsa, N. and Sittiwet, C. (2009). Antibacterial activity of *Curcuma longa* aqueous extract. *J. Pharmacol. Toxicol.*, 4(4):173-177.
- Nirmala, K.; Virendra ,V.P.; Rajakumar, A.K.; Bhaskar,V. and Polasa, K. (2012). Dose-dependent effect in the inhibition of oxidative stress and anticlastogenic potential of ginger in STZ induced diabetic rats, *Food Chem.*, 135:2954-2959.
- Nirmala, K.; Prasanna, K.T. and Polasa, K. (2008). Alterations in antioxidant status following intake of ginger through diet. *Food Chem.*, 106:991-996.
- Oloyed, O.I. (2005). Chemical profile of unripe pulp of *Carica pagaya*. *Pak. J. Nutr.*, 4: 379-381.
- Padhye, S.; Chavan, D.; Pandey, S.; Deshpande J.; Swamy, K.V.; Sarkar, F.H. (2010). Perspectives on chemopreventive and therapeutic potential of curcumin analogs in medicinal chemistry. *Mini Rev. Med. Chem.*, 10 (5): 372-387.
- Polshettiwar, S.A.; Ganjiwale, R.O.; Wadher, S.J.; Yeol, P.G. (2007). Spectrophotometric estimation of total tannins in some ayurvedic eye drops: *Ind. J. Pharm. Sci.*, 69(4): 574-76.
- Reitman, S. and Frankel, S. (1975). A colorimetric method for the determination of serum glutamic oxalacetic and glutamic pyruvic transaminases. *Am.J.Clin.Path*, 28:65.
- Ravindran, J.; Prasad, S. and B.B. (2009). Aggarwal, Curcumin and Cancer Cells: How Many Ways Can Curry Kill Tumor Cells Selectively? *Aaps. J.*, 10:10.
- Saber, A.; Sakr, Sobhy, E.; Hassab El Nabi.; Yosry, A.; Okdah.; Islam, M.; El-Garawani, I,M; Ahmed, M.; El-Shabka, H.A.(2016). Cytoprotective effects of aqueous ginger (*Zingiber officinale*) extract against carbimazole-induced toxicity in albino rats. *Dept. Zool. Eur. J. Pharm. Med. Res.*, ejpmr, 3(7): 489-497.
- Sharma , J.N.; Srivastava, K.C. and Gan , E.K. (1994). Suppressive effects of eugenol and ginger oil on arthritic rats. *Pharmacol.*, 49(5): 314-318.
- Shagufta, N.A.Z.; Saiqa,l.; Zahida, p, and Sumera, j. (2010). Chemical Analysis of essential oils from turmeric *Curcuma longa* Rhizome

### Study of the effect of ginger and turmeric on osteoporosis in female rats

- through GC-MS. Asian J. Chem., 22(4):3153-3158.
- Stanley, C.I.; Johnny, O.O.; Emmanuel, O.O.; Lucy, A.N.; Ifebundu, O Nnatuanya.; Stephen, N. O.; Christian. E.M.; Ibrahim, B.U. and Musa, H. (2017). Comparative assessment of ampicillin antibiotic and ginger (*Zingiber officinale*) effects on growth, haematology and biochemical enzymes of *Clarias gariepinus* juvenile. J. Pharmacognosy Phytochem., 6(3): 761-767.
- Sipos, R.S.; Fecete, R.; Moldovan, D.; Sus, I.; Szasz, S. and Pávai, Z. (2015). Assessment of femoral bone osteoporosis in rats treated with simvastatin or fenofibrate. Open Life Sci., 10: 379–387.
- Tchombé, N.L.; Louajri, A. and Benajiba, M.H. (2012). Therapeutic effects of Ginger. ISESCO J. Sci. Technol., 8(14):64-69.
- Tapsell, L.C.; Hemphill, I.; Cobiac, L.; Patch, C.S.; Sullivan, D.R.; Fenech, M.; Roodenrys, S.; Keogh, J.B.; Clifton, P.M.; Williams, P.G.; Fazio, V.A. and Inge, K.E. (2006). Health benefits of herbs and spices: the past, the present, the future. Med. J. Aust., 185(4): S4-24.
- Tijjani, M. B.; Bello, I. A.; Aliyu, A. B.; Olurische, T.; Maidawa, S. M.; Habila, J. D.; Balogun, E. O. (2009). Phytochemical and antibacterial studies of root extract of *Cochlospermum tinctorium* A. Rich (Cochlospermaceae). Res. J. Med. Plant, 3(1): 16-22.
- Uma. B. A.; Anwer, S. K.; Pillai, K. and M.S.Y. Khan. (2003). Antihepatotoxic Activity of ginger ethanol extract in rats. Pharm. Biol., 41(1): 68–71.
- Varunraj, S.; One, K.C.; Youngwoo, S.; Don-Shik, K. (2011). Antimicrobial and Antioxidant activities of polyphenols against *Streptococcus mutans* free radicals and antioxidants, 11; 1(3):48-55.
- Virendra, V.; Panpatil, .....; Shalini, T.; Nirmala, K.; Chetan, N. and Kalpagam, .....(2013). In vitro evaluation on antioxidant and antimicrobial activity of spice extracts of ginger, turmeric and garlic. J. Pharmacognosy Phytochem., 2 (3): 143-148.
- Von Metzler, I.; Krebbel, H.; Ulrike, K.; Heider, U.; Jakob ,C.; Kaiser, M.; Fleissner, C.; Terpos, E. and Seze, O. (2009). Curcumin diminishes human osteoclastogenesis by inhibition of the signalosome-associated I kappaB kinase. J. Cancer Res. Clin. Oncol., 135 (2): 173-9 .
- Wang, W.H. and Wang, Z.M. (2005). Studies of commonly used traditional medicine-ginger. Zhongguo Zhong Yao Za Zhi, 30: 1569–1573.
- Weinstein, R.S. (2001). Glucocorticoid-induced osteoporosis. Rev Endocr. Metab. Disord., 2: 65-73.
- Wright, L.E.; Beischel, Frye, J.; Timmermann, B.N. and Funk, J.L. (2015). Medicinal Zingiberaceae in the prevention of menopausal bone loss. Planta Med., 74 - PH10DOI: 10.1055/s-0028-1084855.
- Wright, L.E.; Fry, J.B.; Timmermann, B. N. and Funk, J.L. (2010). Protection of trabecular bone in ovariectomized rats by turmeric (*Curcuma longa* L.) is dependent on extract composition. J. Agric Food Chem., 58 (17): 9498-504.
- Young, D.S. (1990). Effects of drugs on clinical laboratory tests. Third edition 1990:3:6-12.

Yang, M.W.; Wang, T.H.; Yan, P.P.; Chu, L.W.; Yu, J.; Gao, Z.D.; Li, Y.Z. and Guo, B.L. (2011). Curcumin improves bone microarchitecture and enhances mineral density in APP/PS1 transgenic mice. *Phytomedicine*, 18: 205-213.

Yan, Z.; Xiao-Li, L.; Wan-Ping, L.; Bin, C.; Hung-Kay, C.; Chun-Fu, W.; Nai-Li, W.; Xin-Sheng, Y. and Man-Sau, W. (2007). Anti-osteoporotic effect of *Erythrina variegata* L. in ovary ectomized rats. *J. Ethnopharmacol.*, 109(1):165-169.

### دراسة تأثير الزنجبيل والكرم على مرض هشاشة العظام لدى أنثى فئران التجارب

إيمان جمال محمد<sup>1</sup>، زينب مصطفى موسى<sup>1</sup>، سماح محمد اسماعيل<sup>1</sup>، عادل بكير خلوصي<sup>2</sup>، سحر عثمان احمد<sup>3</sup>، نجلاء عبد القادر<sup>4</sup>

1 - تغذية وعلوم أطعمة- قسم الاقتصاد المنزلي- كلية التربية النوعية - جامعة عين شمس

2- قسم الباثولوجي ، كلية الطب البيطري. جامعة القاهرة

3- معهد بحوث تكنولوجيا الغذاء<sup>4</sup>- قسم الجراحة و التخدير و الأشعة. الطب البيطري جامعة القاهرة

### المستخلص

هشاشة العظام هو الشكل الأكثر شيوعاً لالتهاب المفاصل ، والذي يشمل التهابات الهيكلية الرئيسية للمفصل ، مما يسبب الألم والعجز الوظيفي. يعتبر الألم والتصلب ، خاصة بعد التمرين ، من الأعراض الرئيسية ، مما يؤدي إلى تأثير كبير على القدرة على أداء أنشطة الحياة اليومية. هناك اختلاف بين الأعراض والتغيرات الإشعاعية ، حيث لا يعاني بعض المصابين أعراضاً ، ولكن يظهرون تغيرات هشاشة العظام على الأشعة السينية. أجريت هذه الدراسة لفحص تأثير استهلاك الزنجبيل والكرم على وظائف الكبد ( ALT ، AST ) ، الفوسفور ، الكالسيوم المتأين والكلبي ، وتم استخدام الأشعة السينية والتركيب النسيجي لمعرفة تأثير استخدام الزنجبيل والكرم على الفئران المصابة بهشاشة العظام المحدث من خلال الحقن بريدنيزون أسيتيت بجرعة 4 ملجم / كجم من وزن الجسم ثلاث مرات في الأسبوع لمدة ثلاثة أسابيع. من ناحية أخرى ، تم تحديد التركيب الكيميائي الرطوبة والبروتين والدهون والألياف والمغذيات الكلية القابلة للهضم والرماد والكربوهيدرات والفوسفور والكالسيوم للزنجبيل والكرم المختبر. بالإضافة إلى ذلك ، تم تحديد المركبات المتطايرة وتحليل المواد الكيميائية النباتية للزنجبيل والكرم المختبر. تم اجراء الدراسة على ثمانية وأربعين فأر غير الحامل من الإناث البيضاء (العمر من 6 إلى 8 أسابيع وحوالي 160 إلى 210 جم من وزن الجسم) مصنفة إلى مجموعتين رئيسيتين. المجموعة الرئيسية الأولى (6) تتغذى على النظام الغذائي القاعدي والمجموعة الرئيسية الثانية (42 فأر) تم حقنها بريدنيزون أسيتيت بجرعة 4 ملجم / كجم من وزن الجسم ثلاث مرات في الأسبوع لمدة ثلاثة أسابيع لتسبب هشاشة العظام وتنقسم إلى سبع مجموعات فرعية تتكون كل مجموعة من (6 فئران). ثم تتغذى على نظام غذائي أساسي يحتوي على 10-15% زنجبيل ، 10-15% كرم و 10-15% زنجبيل وكرم. أظهرت النتائج أن جميع مجموعات هشاشة العظام التي تم تناولها بمستويات مختلفة من الزنجبيل والكرم ( 10-15%) أدت إلى انخفاض معنوي في وظائف الكبد ( ALT ، AST ) ، والفوسفور ، والكالسيوم الكلبي ، والكالسيوم المتأين مقارنة بمجموعة السيطرة الإيجابية. من ناحية أخرى ، كشفت الأشعة السينية والتشريح المرضي للمجموعة الضابطة الإيجابية بعد شهرين عن فقدان العظام لأجزاء مختلفة مثل الشظية والقصبية وعظم الفخذ بالإضافة إلى إزالة المعادن من العظام وكسر الفخذ وأظهرت ترابكسكولا عظم الشظية ضمور وارتشاف وهشاشة العظام. أظهرت النتائج أن علاج الزنجبيل والكرم يخفف ويعالج من مرض هشاشة العظام مقارنة بمجموعة السيطرة الإيجابية.

**الكلمات الدالة :** الأعشاب الطبية ، هشاشة العظام ، الزنجبيل ، الكرم ، التحليل الكيميائي ، التقطير المائي ، تحليل المواد الكيميائية النباتية ، التحليل الكيميائي الحيوي.