

Role of Multislice Dental CT in Assessment of Dental Implants

Safa A Elaty *, Ahmed M Monib *, Yasser A Mohamed *, Ahmed F Abd elghany *.

* Department of Radiodiagnosis: Faculty of Medicine, Ain Shams University.

Abstract

Introduction: The use of dental implants to restore missing teeth has become increasingly widespread over the past two decades. Dental MSCT plays an important role in the preoperative planning of dental implants because it provides accurate measurement of the width and depth of the edentulous ridge as well as the bone density. And postoperatively, dental MSCT images can show the failure of an endosseous implant to osseointegrate, improper placement of an implant, and violation of important structures.

Aim of the work: Is to determine the success of dental implants following pre-operative multi-slice dental CT planning and for early detection of post-operative complications.

Methods: The study included 25 patients that were divided in to 2 groups, Group I included 14 partially edentulous patients who underwent pre and post- operative dental MSCT, while group II included 11 patients that already have dental implants and underwent post-operative dental MSCT using 16-slice helical CT scanner.

Results: There is highly significant ($P < 0.001$) relation between preoperative dental MSCT assessment and postoperative results and dental MSCT was very accurate in the evaluation of osseointegration and very sensitive in the detection of postoperative complications.

Conclusion: Dental MSCT is a promising method that can be used as an imaging tool in the preoperative planning and postoperative assessment of dental implants.

Key words: Multi-slice CT, dental implants, bone density, preoperative evaluation, postoperative complication.

INTRODUCTION

Partial or total edentulism is not only a cosmetic impairment but may substantially affect oral and general health as well as overall quality of life. Self-esteem, speech, and dietary intake are affected ⁽¹⁾. In response to these problems, dentists developed non-removable bridges that are attached to oral implants ⁽²⁾.

Restoration using dental implants is now the most popular treatment in the field of dentistry ⁽³⁾. Dental implants are metal posts that are surgically implanted in the jaw to support a fixed dental prosthesis ⁽⁴⁾.

The successful outcome of any implant procedure requires a series of patient-related and procedure-dependent parameters. The volume of bone available and quality of the bone are highly associated with the type of surgical procedure and the type of implant, and both of these factors play a vital role in the success of dental implant surgery ⁽⁵⁾.

Dental MSCT has high spatial resolution images and capability of multi-planar reconstructions in high-quality that help in the preoperative planning of dental implants because it aids in the appropriate choice of implant size through accurate measurement of the width and depth of the edentulous area and helps to avoid injury of critical structures such as the mandibular canal or maxillary sinus ⁽⁴⁾. Dental MSCT is a useful tool to determine the

bone density in the implant recipient sites identifying sites suitable for implant placement and favorable for osseointegration ⁽⁵⁾.

Postoperatively, dental MSCT images can show the failure of an endosseous implant to osseointegrate, improper placement of an implant, and violation of important structures (e.g., the mandibular canal, nasal cavity, or maxillary sinus) ⁽⁶⁾.

THE AIM OF THE WORK

The aim of the work is to highlight the role of dental MSCT in the preoperative planning and postoperative assessment of dental implants.

METHODS

The study included 25 patients (8 males and 17 females, age range 17 ~ 66 years) that were divided into 2 groups; Group I included 14 partially edentulous patients planning for dental implantation (9 patients were planning for mandibular implant insertion and 5 patients were planning for maxillary implant insertion) having 28 edentulous areas (each edentulous area was considered a separate case), this group underwent pre and post- operative dental MSCT. Group II included 11 patients that already have dental implants (8 patients have maxillary implant and 3 patients have mandibular implant), this group underwent post-operative dental MSCT.

Scan protocol:

The scans were performed using 16-slice helical CT scanner (bright speed 16, General electric Medical Systems Co., Ltd., Milwaukee, USA) in a private radiology center.

Patient lie supine and should be motionless during scanning. In order to assure this, the patient's head should be firmly attached to the head holder.

The transaxial jaw region tomograms produced a lateral topogram of the skull base.

The transverse images are scanned parallel to the alveolar ridge or occlusal plane of the teeth by using a bone algorithm, 15-cm field of view, and 512 x 512 matrix. The mandible and maxilla are each imaged with separate studies.

Scan direction is caudocranial beginning with the mandible base and extends to include the alveolar crest for the mandible, whereas for the maxilla the scan plane starts with the alveolar crest and extends upward to include all root tips.

Parameters for Dental MSCT (Table. 1):

Parameter	16-Detector Row CT
Kilovolt peak	100–140
Effective mAs	200–300
Pitch	1
Matrix size	512x512
Field of view	15cm
section thickness and separation between sections	0.625

Post processing techniques:

Once the axial images have been obtained, the dental software program is performed on a dedicated workstation. The raw data from the axial sections are used to create.

1. Superimposed curve images (curved planar reformation).
2. Panoramic images.
3. Sagittal oblique images.

Interpretation of the Dental MSCT when planning for Dental Implant:

- For mandibular implant five anatomic parameters were assessed:
 1. The height of the alveolar bone.
 2. The buccolingual dimension of the ridge at the implant site.
 3. The anterior and posterior cortical thickness.
 4. The contour of the ridge.
 5. The average bone density at the implant site.

6. The position of the inferior alveolar nerve.

- For maxillary implant five anatomic parameters were assessed:

1. The height of the alveolar ridge.
2. The buccolingual dimension of the ridge.
3. The anterior and posterior cortical thickness
4. The contour of the alveolar ridge.
5. The maxillary sinuses, the incisive fossa and canals.

To decrease the probability of dental implant failure, it is estimated that the bone implant site needs to be at least 9 mm high and 5 mm wide. In addition, the minimum required distance from the implant to the adjacent cortical bone is 1 mm; the minimum required distance from the implant to contiguous dental or implant pieces is 1.5, and 1 to 2 mm of bone between the base of the fixture and adjacent structures, such as the nasal fossa, floor of the maxillary sinus, mandibular canal and inferior border of the mandible.

So when the measurements of the height and the buccolingual dimension of the alveolar ridge fulfill the previous criteria, the case is considered suitable for implant placement. And when these measurements don't fulfill the previous criteria, the case is considered not suitable for implant placement.

The quality of bone at the possible implant site was assessed and the bone density was evaluated and classified according to the MISCH classification as the following:

- MISCH D-1 and D-2 are considered suitable for implant placement.
- MISCH D-3 and D-4 are considered not suitable for implant placement.
- Post-operative cases are assessed for adequate osseointegration (fusion of the implant surface with the surrounding bone) and for possible anatomical complications including:
 1. Fenestration, the presence of a defect in the buccal or lingual bone overlaying the implant.
 2. Sinus perforation.
 3. No primary stability.
 4. Malposition of the implant in relation to the biomechanical and/or esthetic requirements

RESULTS

The study included 25 patients with 17 female and 8 male. The maximum age was 66 year and the minimum was 17 year.

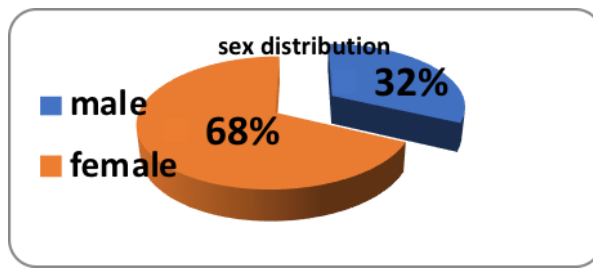


Figure (1): Pie chart showing sex distribution of the cases included in this study.

Results of group I

As regard the mandibular cases:

These are 9 cases having 20 edentulous areas with their age ranging from 26 to 54 years (mean \pm SD = 39.1 \pm 9.2844 years).

Descriptive Statistics of Mandibular cases (Table. 2):

	n	Min.	Max.	Mean	SD
Age	20	26	54	39.1	9.2844
Posterior cortical Thickness	20	2	2.7	2.285	0.272
Anterior cortical Thickness	20	1	2.8	1.69	0.4077
Width	20	6.6	11.5	8.41	1.3341
Length	20	13	28	15.835	3.5388

As regard the relation between Postoperative-follow up CT results and CT density of the edentulous area (table 12):

- Among the failure (n=1): 0% (D1), 0% (D2), and 100% (D4).
- While among the successful (n=19): 10,5% (D1), 89,5% (D2), and 0% (D4).
- (P < 0.001) which means it is highly significant.

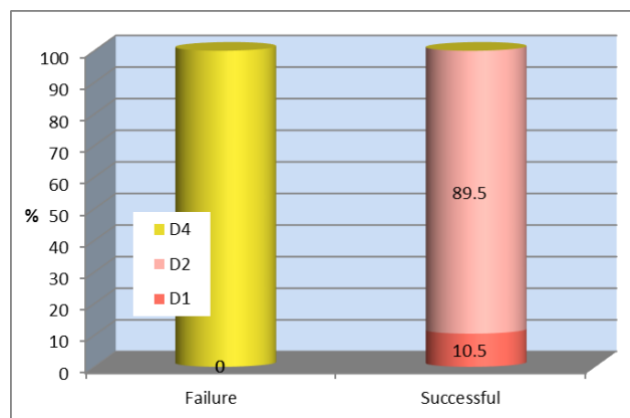


Figure (2): Bar chart; showing the relation between Postoperative follow up CT results and CT density of the edentulous area.

As regard the relation between Postoperative-follow up CT results and Preoperative CT results:

- Among the failure (n=1): 100% (not suitable), and 0% (suitable).
- While among the successful (n=19): 0% (not suitable), and 100% (suitable).
- (P < 0.001) which means it is highly significant.

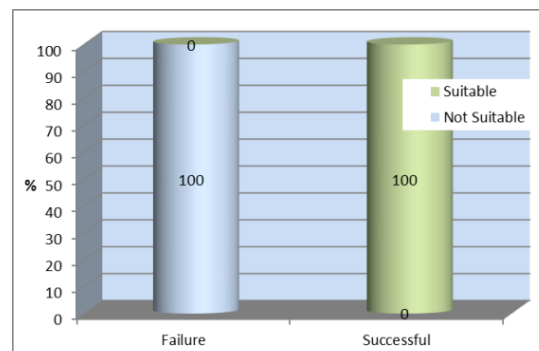


Figure (3): Bar chart; showing the relation between Post-follow up CT results and Preoperative CT results.

As regard the maxillary cases:

These are 5 cases having 8 edentulous areas with their age ranging from 17 to 66 years (mean \pm SD = 46.25 ± 18.896 years).

Descriptive Statistics of maxillary cases (Table. 3):

	n	Min.	Max.	Mean	SD
Age	8	17	66	46.25	18.8963
Posterior cortical Thickness	8	0.6	2	1.3	0.5425
Anterior cortical Thickness	8	0.5	1.5	0.95	0.378
Width	8	4	10	6.975	2.476
Length	8	5	24	13.638	5.8527

As regard the relation between Postoperative-follow up CT results and CT density at the edentulous area (table 17):

- Among the failure (n=6): 0% (D2), 66.7% (D3), and 33.3 % (D4).
- While among the successful (n= 2): 100 (D2), 0% (D3), and 0 % (D4).
- ($P < 0.05$) which means it is significant

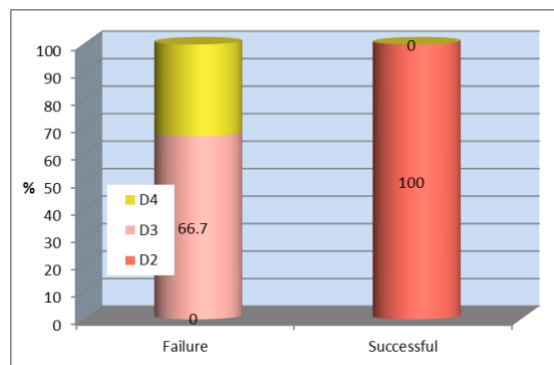


Figure (4): Bar chart; showing the relation between Postoperative follow up CT results and CT density at the edentulous area.

As regard the relation between Postoperative follow up CT results and Preoperative CT results (table 18):

- Among the failure (n=6): 100% (not suitable), and 0% (suitable),
- While among the successful (n=2): 0% (not suitable), and 100% (suitable),
- ($P < 0.05$) which means it is significant.

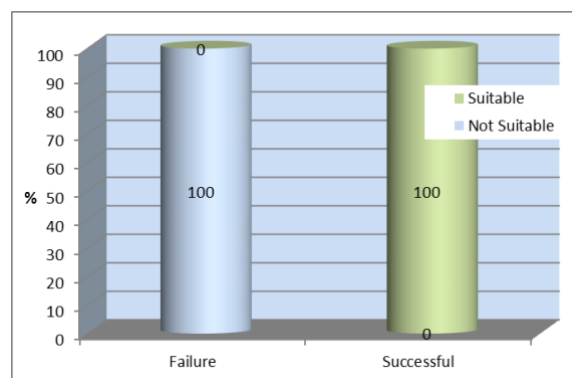


Figure (5): Bar chart; showing the relation between Postoperative follow up CT results and Preoperative CT results.

Results of group II

This group included 11 patients who had already undergone dental implant placement and came for assessment of osseointegration or for detection of postoperative complications due to presence of pain or swelling at the implant site.

(Table. 4): list of cases with maxillary implant insertion, cause of examination and postoperative dental MSCT results:

case	Cause of examination	Postoperative CT results
1	Post operative evaluation	Successful implant placement and osseointegration
2	Post operative evaluation	Successful implant placement and osseointegration
3	Post operative evaluation	Successful implant placement and osseointegration
4	Post operative pain at the site of the implant	Linear fracture of the alveolar bone
5	Post operative pain at the site of the implant	Failure of implant placement with the tip of implants at the right maxillary sinus
6	Chronic rhinitis	Failure of implant placement with the tip of implants at the right nasal cavity
7	Discomfort at the site of the implant	Incomplete osseointegration with small tracks noted at the surrounding cancellous bone
8	Swelling at the site of the implant	Failure of oseointegration due to infection at the implant site

(Table. 5): list of cases with mandibular implant insertion, cause of examination and postoperative dental MSCT results:

case	Cause of examination	Postoperative CT results
1	Discomfort at the site of the implant	No abnormality detected with successful implant placement and osseointegration
2	Post operative evaluation	Successful implant placement and osseointegration
3	Post operative pain at the site of the implant	Successful implant placement and osseointegration around 3 implants with failure of osseointegration around the 4 th implant

DISCUSSION

Radiographic evaluation of the dental and periodontal tissues is a critical segment of the comprehensive oral examination, especially for the implant patients where imaging is an important diagnostic adjunct to the clinical assessment ⁽⁷⁾.

Before implant placement and during treatment planning, the implant clinician must be able to measure the height and width of the alveolar process to ensure adequate bone and to select appropriately sized implants. In addition, the clinician must know the precise location of the mandibular canal (injury to the neurovascular bundle within the canal can

result in facial paresthesia) and the maxillary sinuses (perforation of the sinuses create the possibility of antral infections and increases the likelihood of implant failure) ⁽⁸⁾.

The use of MSCT for planning implants has been intensively advocated over the last few decades, and its superiority in relation to conventional radiographic examinations as well as to conventional tomography is demonstrated in the literature ⁽⁹⁾.

Dental MSCT provides advantages. It is noninvasive and easy to operate. It requires little transformation, i.e., we just take a set of multislice axial images, use the software to

measure, and reconstruct into the panoramic multiple and segmental views. The two views have little distortion and correspond almost equally to the real structure at the same proportion. Therefore, we can read numerical scale directly from the view; and this data can be used to locate the implanting site and determine its dimensions ⁽¹⁰⁾.

The evaluation of bone density is essential for implant planning and for the success of this treatment. An adequate radiographic examination is required to obtain this information. To this end, several studies have assessed the evaluation of bone density. Evaluation of bone density was performed initially by subjective analysis. Later, studies correlated HU and objective assessment of bone density ⁽¹¹⁾.

Studies have shown the relationship between high bone density and a high rate of success with implants. There is also good correlation between high bone density and the primary stability of the implants ⁽¹²⁾. This agrees with the results of our study, where successful implant placement occurred in high density bone (Misch D1 and D2), while implant failure occurred in low density bone (Misch D3 and D4).

Among the factors affecting implant success, Bone density and implant stability are key factors to take into account and important for implant osseointegration, which has been widely demonstrated by several authors. Clinical studies show greater implant survival in the mandible than in the maxilla, due to the area's characteristics of bone density; more type I, II, or III bones are observed in the mandible than in the maxilla ⁽³⁾. This agrees with the results of our study in which most of the failure cases occurred in the maxilla.

In our study: Group I included 14 partially edentulous patients planning for dental implantation (9 patients were planning for mandibular implant and 5 patients were planning for maxillary implant insertion) having 28 edentulous areas (each edentulous area was considered a separate case), this group underwent pre and post-operative dental MSCT.

As regard the patients planning for mandibular implant placement the results revealed that there is no significant ($P > 0.05$) relation between the preoperative measurements (including the width, length, anterior and posterior cortical thickness) and the postoperative CT results, and this may be due to the small size of the sample and the

small number of failure cases. In the other hand there was highly significant ($P < 0.001$) relation between bone density and postoperative CT results and highly significant relation between preoperative dental MSCT assessment and postoperative results. The failed case in the mandible was due to failure of osseointegration due to poor quality bone (Misch D4).

As regard the maxillary cases the results revealed that there is no significant ($P > 0.05$) relation between the preoperative measurements (including the width, length, anterior and posterior cortical thickness) and the postoperative CT results, and this may be due to the small size of the sample. In the other hand there was significant ($P < 0.05$) relation between bone density and postoperative CT results and significant relation between preoperative assessment and postoperative results. The failed cases in the maxilla are due to atrophy of the maxillary alveolar bone and diminished bone density.

In 2001, Akc *et al.* ⁽¹³⁾ stated that the anterior mandible was most frequently used for the placement of implants in completely edentulous patients at the same time that Tepper *et al.* ⁽¹⁴⁾ pointed out the importance of CT to evaluate that region. In 2002, Jacobs *et al.* ⁽¹⁵⁾ reaffirmed the validity of using cross-sectional CT in the evaluation of the anterior region in implant planning aiming at identifying the incisive canal in order to prevent potential sensory disturbances.

Concerning the premolar region, Cavalcanti *et al.* in 1998 ⁽¹⁶⁾, and Bou Serhal *et al.* in 2002 ⁽¹⁷⁾, conducted in vitro and in vivo experiments, respectively, and concluded that, by means of CT, accurate measurements could be performed in the mental foramen region, which is also considered to be of utmost importance for implant planning.

Nevertheless, no area has been the subject of so much discussion as the mandible's posterior region, which is where the mandibular canal is found. Its importance, its most frequent anatomical variations and particularly the accuracy of the measurements conducted in CT imaging for this specific area, have been extensively studied ⁽⁹⁾.

Many studies have evaluated the relationship between implant location and dental implant success rate ⁽¹⁸⁾. Tolstunov ⁽¹⁹⁾ had summarized the implant locations and related success rates from 51 previous studies and found That the implant location greatly affects the probability of implant success,

which is about 4% higher in the mandible than in the maxilla, and higher in the anterior region than in the posterior region (about 12% and 4% in the maxilla and mandible, respectively); in other words, dental implants are most successful in the anterior mandible and least successful in the posterior maxilla. This agrees with the results of our study in which the incidence of failure was higher in the maxilla than in the mandible.

Therefore, the dentist should be especially careful when inserting a dental implant into a region with poor-quality bone, such as the posterior maxilla ⁽²⁰⁾.

Cooper ⁽²¹⁾ described, in a study on 1084 implants, that there was a 6.43-fold lower risk of primary implant stability failure in the anterior mandible than in other locations. The maxilla had a 2.7-fold higher risk of primary stability failure versus the mandible this agree with the results of our study.

In our study: Group II included 11 patients who had already undergone dental implant placement and came for assessment of osseointegration or for detection of

postoperative complications due to presence of pain or swelling at the implant site. This group includes 8 patients with maxillary implant insertion and 3 patients with mandibular implant insertion.

As regard the patients with maxillary implants of group II: we reported 3 cases showed successful implant placement with adequate osseointegration, one case with the tip of implant seen at the right maxillary sinus, one case with the tip of implant at the right nasal cavity, one case with Linear fracture of the alveolar bone, and 2 cases showed failure of osseointegration.

As regard the patients with mandibular implants of group II: the 3 cases showed successful implant placement with adequate osseointegration.

So according to the results of our study we can say that dental MSCT is very helpful in the evaluation of osseointegration and very sensitive in detection of postoperative complications.

Case 1:

49 years old female patient with partially edentulous mandible in the form of loss of the left mandibular canine and the three left molars as well as loss of the right mandibular 2nd premolar and the three right molars.

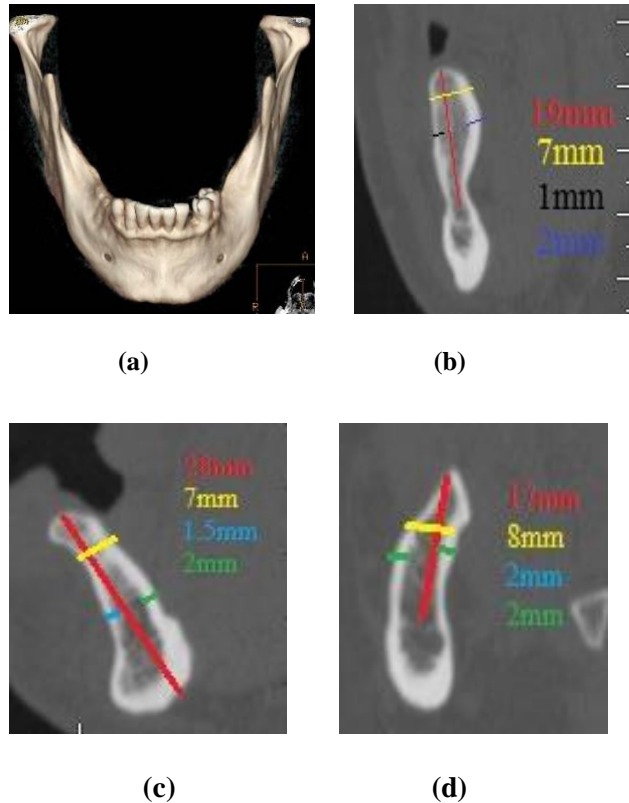


Figure (6): **a)** 3 D SSD reformatted image that shows the site of the lost teeth and location of the mental foramen. **b)** Sagittal reformatted image at the site of lost right mandibular molars showing the bone height to be 19mm (distance from the edge of alveolar margin down to the roof of the mandibular canal), the bone width to be 7mm the anterior cortical thickness to be 1mm and the posterior cortical thickness to be 2mm, the bone density is 230HU (Misch D-2) i.e suitable for implantation. **c)** Sagittal reformatted image at the site of lost left mandibular canine showing the bone height to be 28mm (measured from the top of the alveolar ridge to the bottom of the mandible), the bone width to be 7mm, the anterior cortical thickness to be 1.5mm and the posterior cortical thickness to be 2mm, Misch D-2 i.e suitable for implantation. **d)** Sagittal reformatted image at the site of lost left mandibular molars showing the bone height to be 17mm, (NB: there is some pointing of the alveolar ridge which may need alveoloplasty before implant placement) the bone width measured below the level of pointed alveolar ridge is 8mm the anterior cortical thickness is 2mm and the posterior cortical thickness is 2mm, the bone density is 220HU Misch D-2 i.e suitable for implantation.

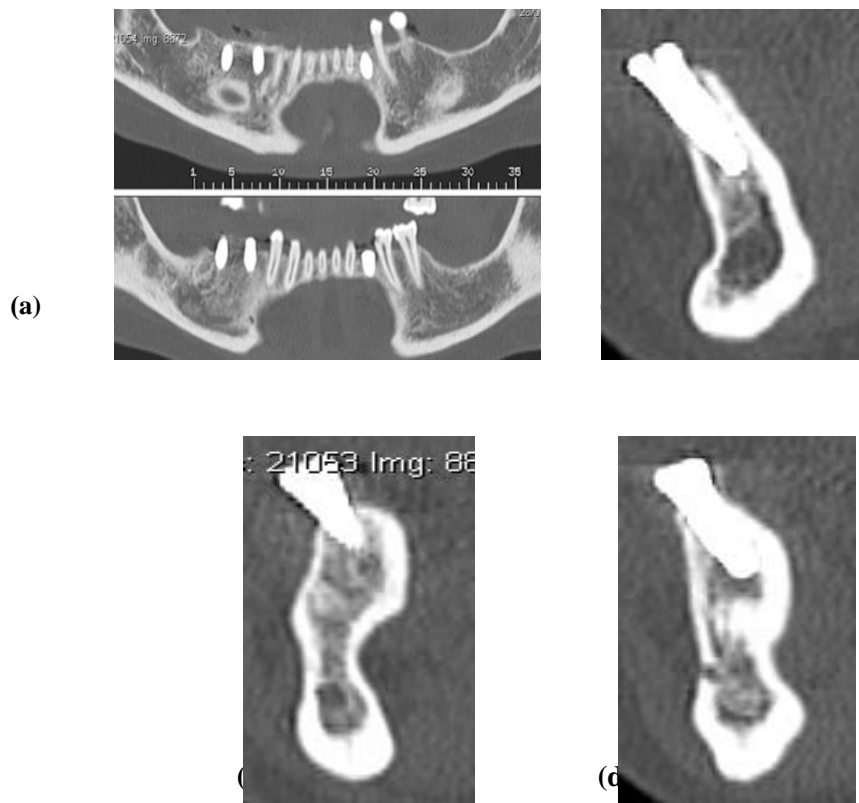


Figure (7): post operative study of the same patient showing: **a)** Panoramic CT image of the mandible showing one implant placed at the site of the lost left mandibular canine and 2 implants at the right mandibular edentulous area and showing their relation to the mandibular canal. **b)** Sagittal reformatted image at the site of lost left mandibular canine showing adequate implant placement and adequate osseointegration with no loosening. **c)** & **d)** Sagittal reformatted image at the site of right mandibular edentulous area showing also proper implant placement with adequate osseointegration around with no violation to the mandibular canal

Case 2:

38 years old male underwent implant insertion at the site of lost left maxillary first molar tooth, complaining of discomfort at the site of implantation.

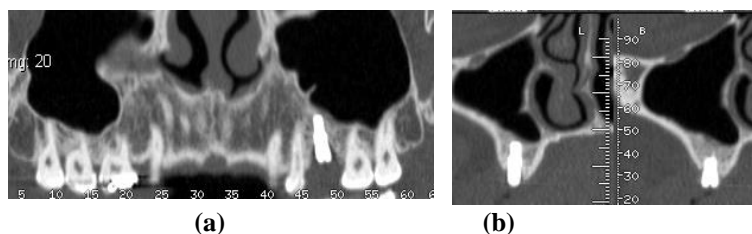


Figure (8): a) CT panoramic image of the maxilla showing adequate osseointegration around the root of the implant. **b)** CT sagittal reformatted image showing also adequate osseointegration around the implant root as well as intact floor of the left maxillary sinus i.e successful implant placement.

Case 3:

40 years old female patient underwent implant insertion in the mandible at the site of the right 1st premolar tooth and at the site of the left 1st & 2nd premolars and left 1st molar teeth, coming for postoperative assessment.

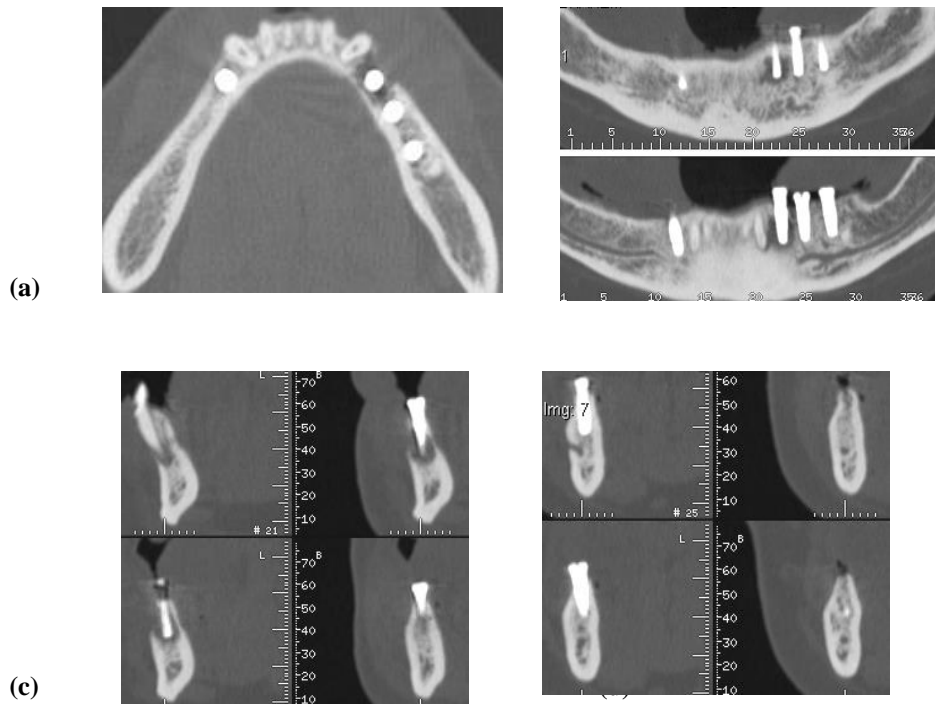


Figure (8): a) axial image of the mandible showing the implants at the site of lost right 1st premolar tooth and at the site of the lost left 1st & 2nd premolars and left 1st molar teeth, all show adequate osseointegration around except the implant at the site of lost left 1st premolar that is seen surrounded by a hypodense halo. b) CT panoramic image showing the implants with adequate distance between the inferior edge of the implant and the mandibular canal, there is adequate osseointegration around all implants except the implant that is inserted at the site of the left mandibular 1st premolar tooth that is seen surrounded by hypodense zone denoting lack of osseointegration. c) CT sagittal reformatted image at the site of lost left 1st premolar showing the hypodense halo around the implant. d) CT sagittal reformatted image at the site of lost left 2nd premolar and 1st molar showing adequate osseointegration and adequate distance between the inferior edge of the implant and the mandibular canal.

CONCLUSION

Applying the findings of the current study, it is concluded that dental MSCT is considered an excellent noninvasive imaging modality in the preoperative evaluation of dental implant patients and in the postoperative assessment of osseointegration and early detection of complications.

REFERENCES

- (1) **Saavedra JA, Balhen C, Zaragoza K, et al. (2010):** Dental Multisection CT for the Placement of Oral Implants: Technique and Applications. *Radiographics*. 30 (7):1975-91.
- (2) **Delbalso AM, Greiner FG, Licata N. (1994):** Role of diagnostic imaging in evaluation of the dental implant patient. *Radiographics*.,14:699–719.
- (3) **Yeon-Jo Choi, Sang-Ho Jun, Young-Dae Song,et al. (2011):** CT Scanning and Dental Implant, CT Scanning - Techniques and Applications, Dr. Karupppasamy Subburaj (Ed.), ISBN: 978-953-307-943-1
- (4) **Abrahams J. (2001):** Dental CT Imaging: A look at the jaw. *Radiology*, 219:334–345.
- (5) **Turkyilmaz I and McGlumphy E. (2008):** Influence of bone density on implant stability parameters and implant success: a retrospective clinical study. *BMC Oral Health*, 24:8-32.
- (6) **Sommer B: Dental CT. (2009):** pathologic findings in the teeth and jaws. In: Textbook of Multislice CT, Diagnostic Imaging, 3rd edition, Springer; pp: 170-172.
- (7) **Luthra R,Kaur P and Sharma P (2012):** Implant radiology: The journey so far. *Journal of dental implants*,2(2): 117-120.
- (8) **Neha V, Amarnath G, Muddugangadhar B (2012):** Cone Beam Computed Tomography : Third Eye In Diagnosis And Treatment Planning. *Indian Journal of dental sciences*, 4(2): 73-77.
- (9) **Dantas JA, Filho MA, Campos PS(2005):** Computed tomography for dental implants: the influence of the gantry angle and mandibular positioning on the bone height and width. *Dentomaxillofacial Radiology* 34, 9–15.
- (10) **Abrahams J, Vining EM, Friedman CD et al. (1993):** Dentscan imaging of the mandible and maxilla. *Head Neck*., 5: 1-7.
- (11) **Aksoy U, Eratalay K, Tözüm TF. (2009):** The possible association among bone density values, resonance frequency measurements, tactile sense, and histomorphometric evaluations of dental implant osteotomy sites: a preliminary study. *Implant Dent.*,18(4):316-25.
- (12) **Isoda K, Ayukawa Y, Tsukiyama Y, et al. (2012):** Relationship between the bone density estimated by cone-beam computed tomography and the primary stability of dental implants. *Clin Oral Implants Res.*,23(7):832-6.
- (13) **Akcı K, Iplikcioglu H. (2001):** Evaluation of the effect of the residual bone angulation on implant-supported fixed prostheses in mandibular posterior edentulism. Part I: Spiral computed tomography study. *Implant Dent.*,10: 216–222.
- (14) **Tepper G, Hofschneider UB, Gahleitner A, et al. (2001):** Computed tomographic diagnosis and localization of bone canals in the mandibular interforaminal region for prevention of bleeding complications during implant surgery. *Int J Oral Maxillofac Implants*, 16: 68–72.
- (15) **Jacobs R, Mraiwa N, Van Steenberghe D, et al. (2002):** Appearance, location, course, and morphology of the mandibular incisive canal: an assessment on spiral CT scan. *Dentomaxillofac Radiol.*, 31: 322–327.
- (16) **Cavalcanti MGP, Yang J, Ruprecht A et al. (1998):** Validation of spiral computed tomography for dental implants. *Dentomaxillofac Radiol.*, 27: 329–333.
- (17) **Bou Serhal C, Jacobs R, Flygare L, et al. (2002):** Perioperative validation of localisation of the mental foramen. *Dentomaxillofac Radiol.*, 31: 39–43.
- (18) **Moy PK, Medina D, Shetty V, et al. (2005):** Dental implant failure rates and associated risk factors. *Int J Oral Maxillofac Implants*,20: 569–577.
- (19) **Tolstunov L. (2007):** Implant zones of the jaws: implant location and related success rate. *J Oral Implantol.*,33: 211–220.
- (20) **Fuh LJ, Huang HL, Chen CS. (2010): J Oral Rehabil.** Variations in bone density at dental implant sites in different regions of jaw bone. *J of Oral Rehabilitation*; 37(5):346-51.
- (21) **Cooper, L.F. (2010):** Factors influencing primary dental implant stability remain unclear, the journal of evidence-based dental practice; 10 (1):44-45.